



GRAY'S

ATLAS  
OF ANATOMY

Richard L. Drake

Wayne Vogl

Adam W. M. Mitchell

Richard M. Tibbitts

Paul E. Richardson

ELSEVIER  
ANATOMY

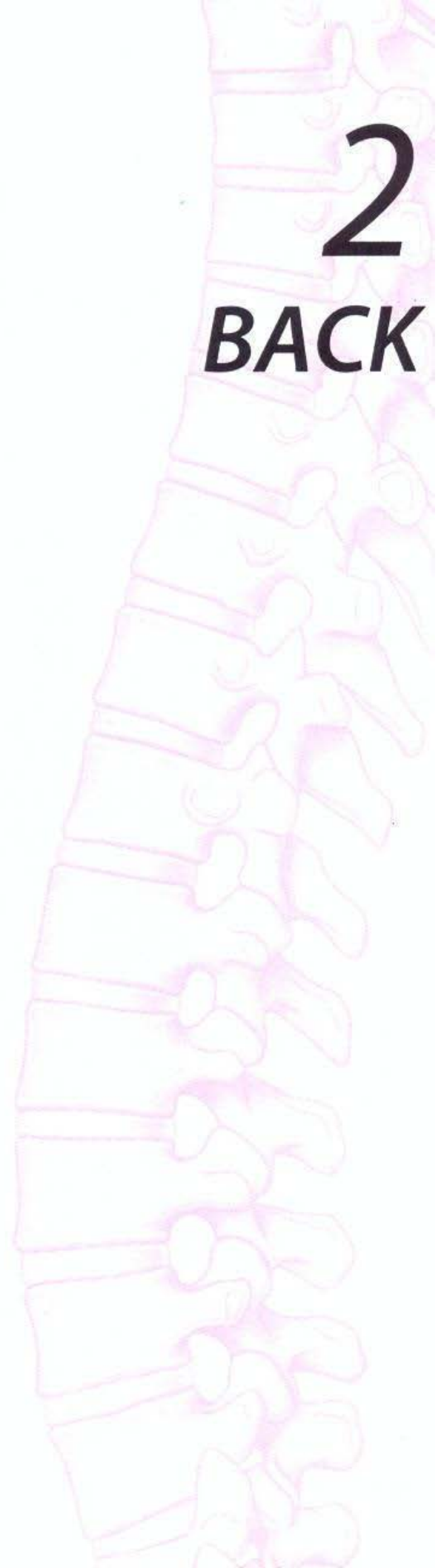
# 2

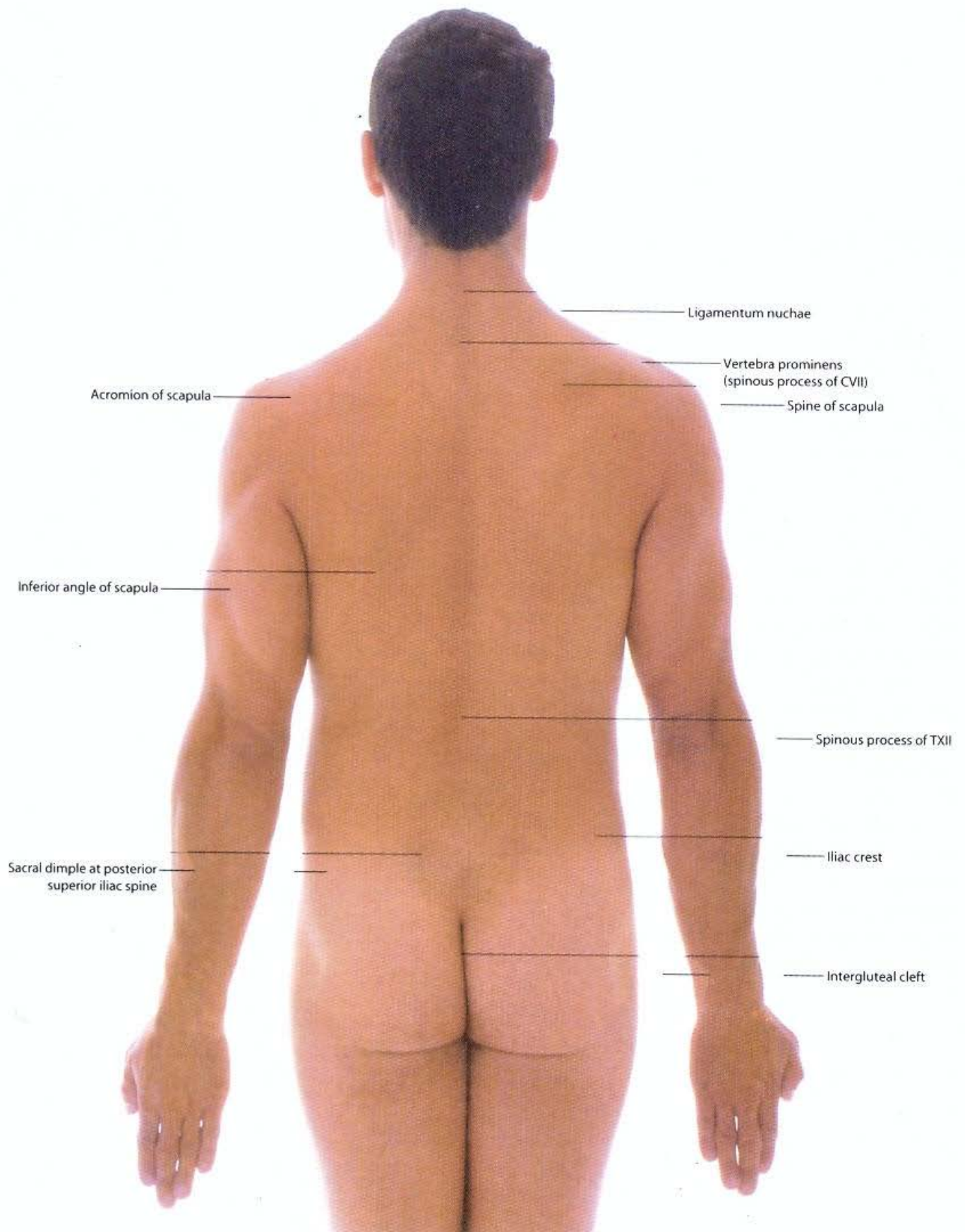
# BACK

## CONTENTS

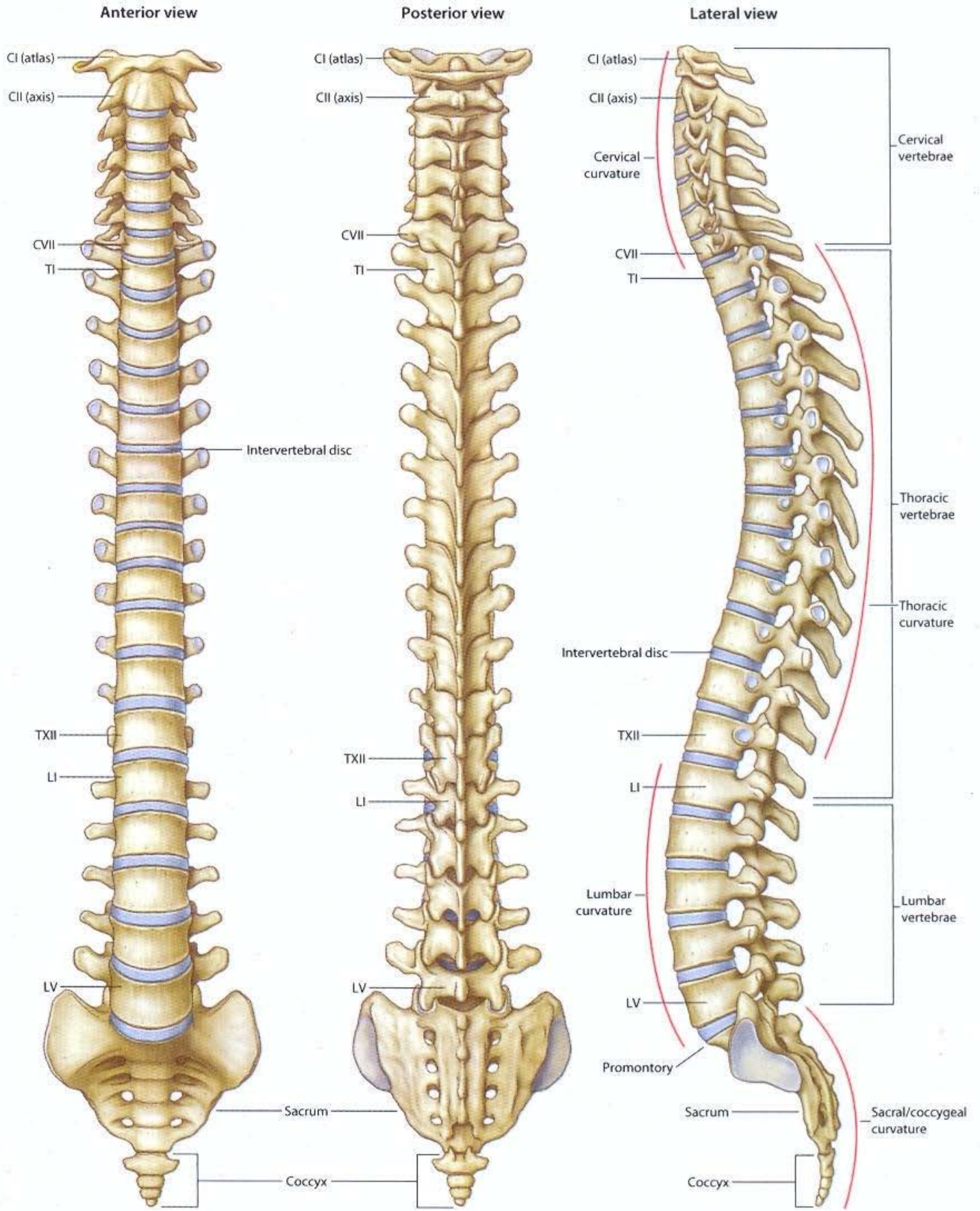
---

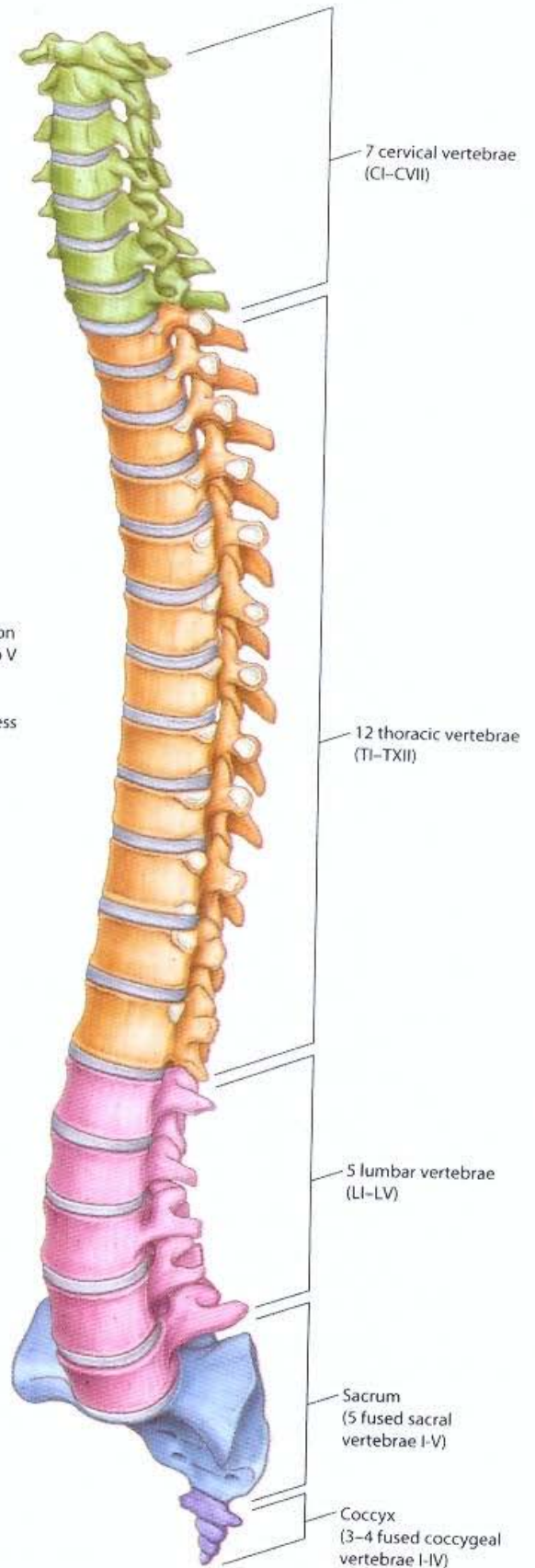
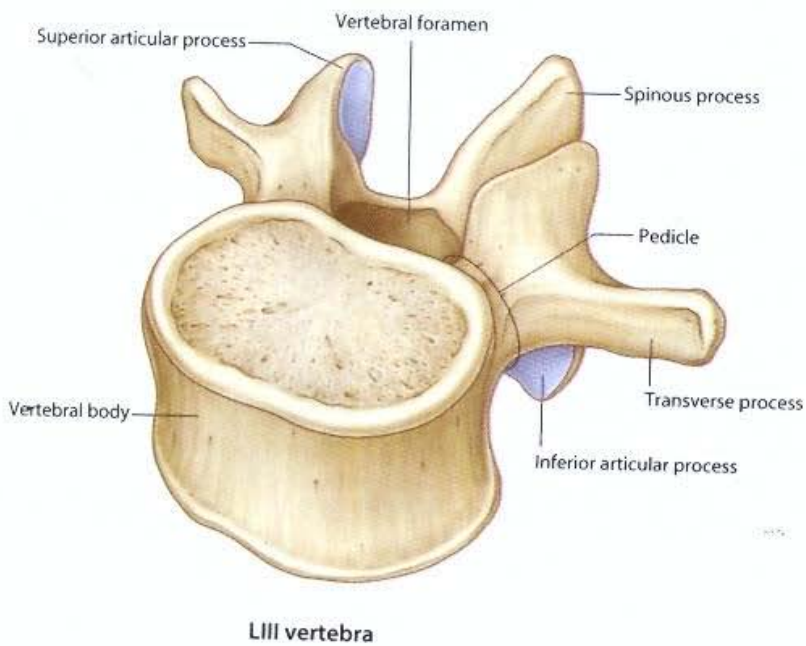
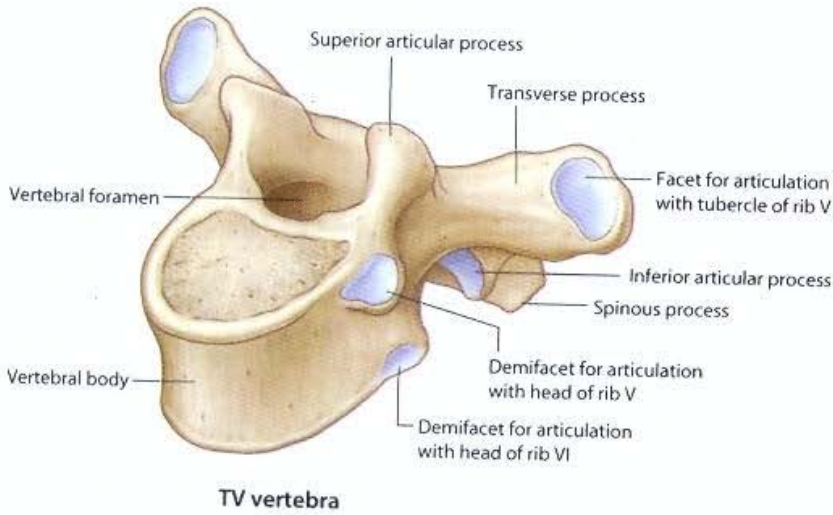
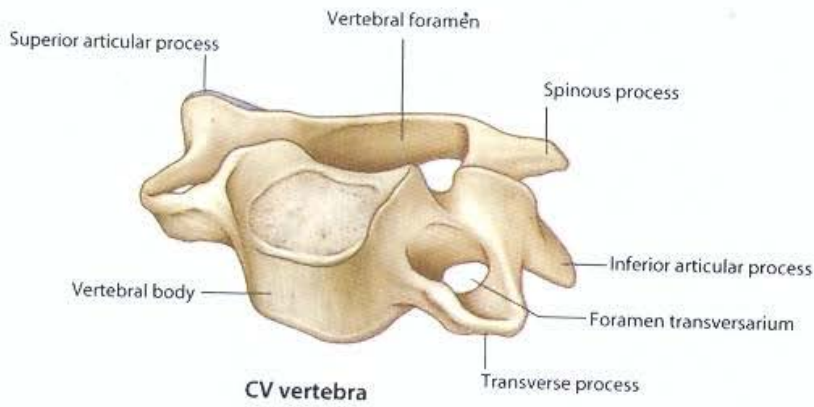
<i>Surface anatomy</i>	20
<i>Vertebral column</i>	21
<i>Regional vertebrae</i>	22
<i>Cervical vertebrae</i>	23
<i>Thoracic vertebrae</i>	26
<i>Lumbar vertebrae</i>	28
<i>Sacrum</i>	31
<i>Intervertebral foramina and discs</i>	32
<i>Intervertebral disc problems</i>	33
<i>Joints and ligaments</i>	35
<i>Back musculature: surface anatomy</i>	36
<i>Superficial musculature</i>	37
<i>Intermediate musculature</i>	39
<i>Deep musculature</i>	40
<i>Back musculature: transverse section</i>	42
<i>Suboccipital region</i>	43
<i>Spinal nerves</i>	44
<i>Spinal cord</i>	45
<i>Spinal cord vasculature</i>	46
<i>Venous drainage of spinal cord</i>	47
<i>Meninges</i>	48
<i>Spinal cord: imaging</i>	50
<i>Transverse section: thoracic region</i>	52
<i>Dermatomes and cutaneous nerves</i>	53

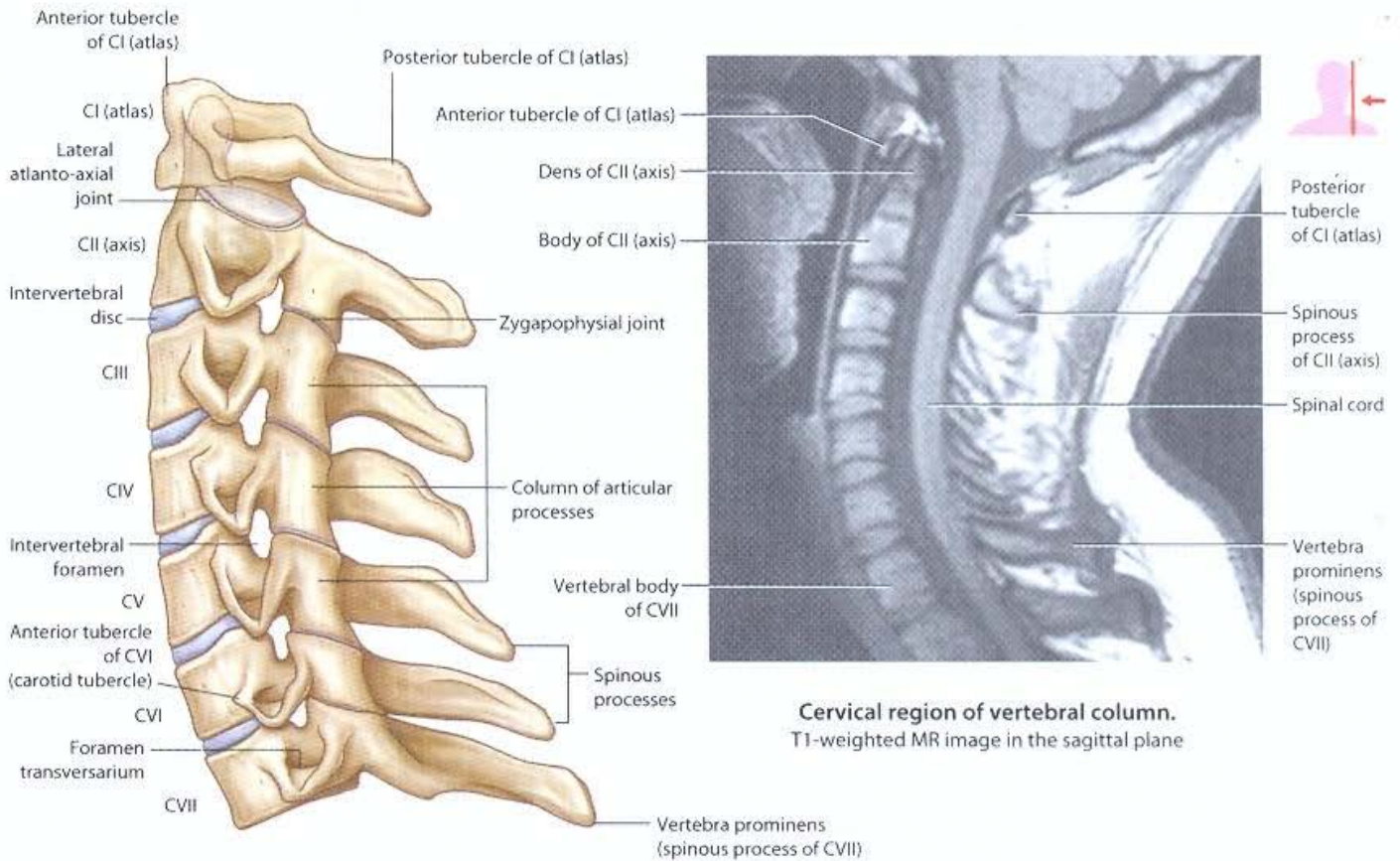




Surface anatomy of the back

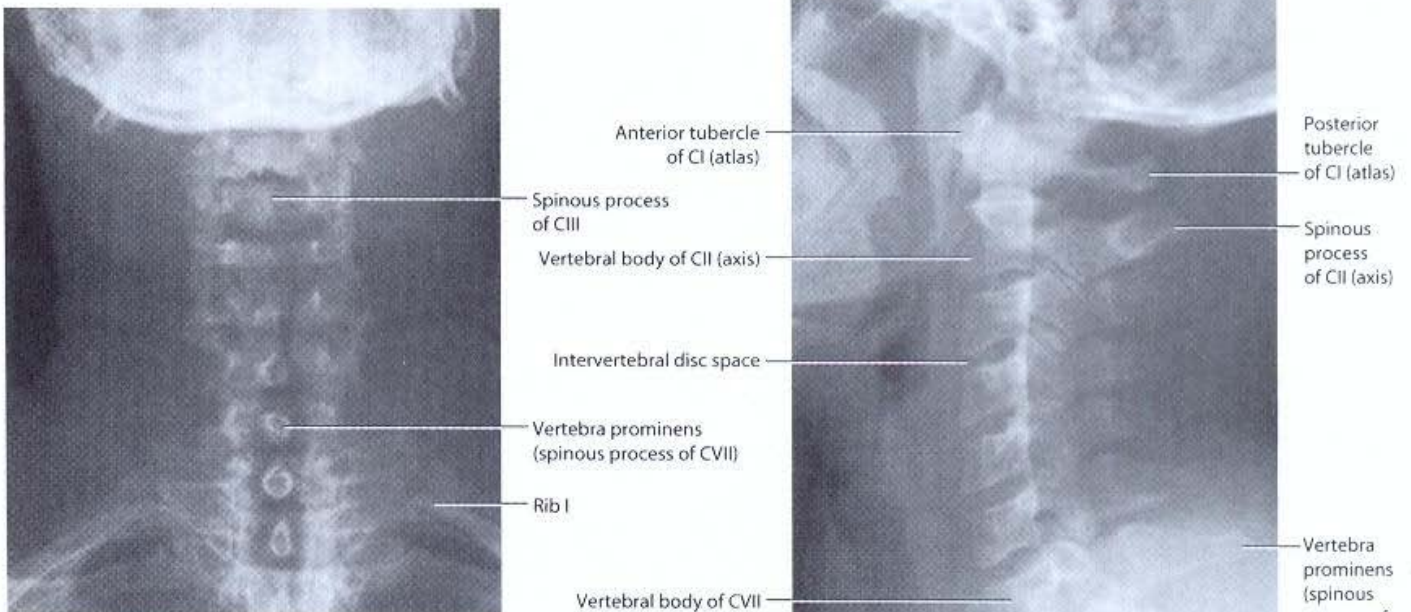






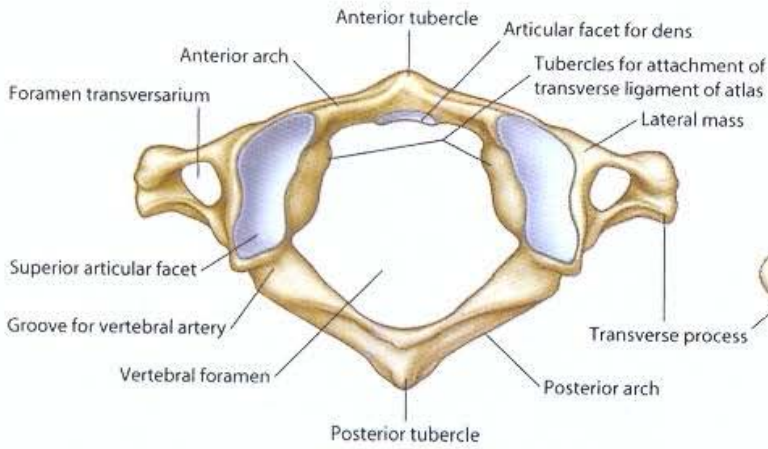
Cervical region of vertebral column. T1-weighted MR image in the sagittal plane

Cervical vertebrae lateral view

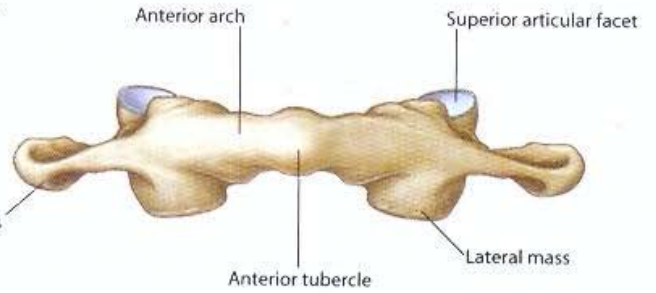


Cervical region of vertebral column. Radiograph, AP view

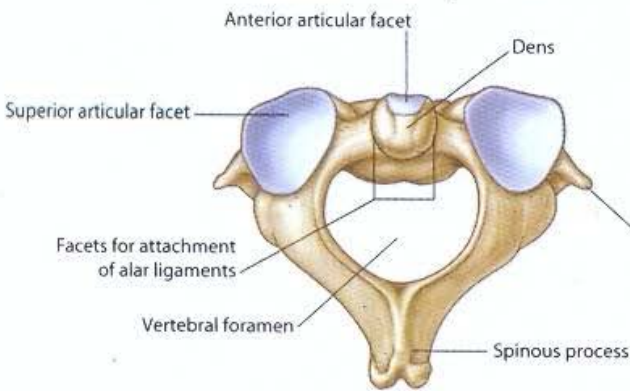
Cervical region of vertebral column. Radiograph, lateral view



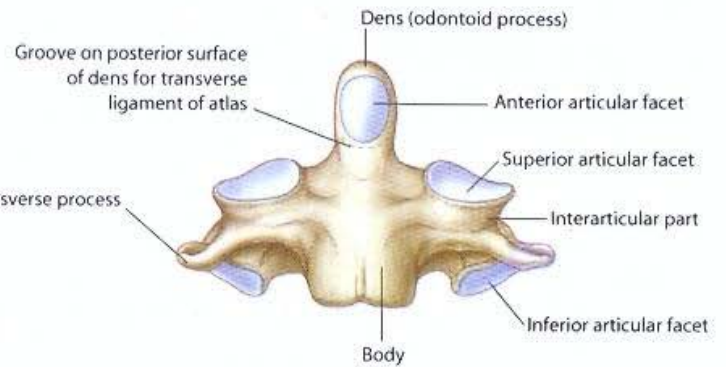
**C1 vertebra (atlas) superior view**



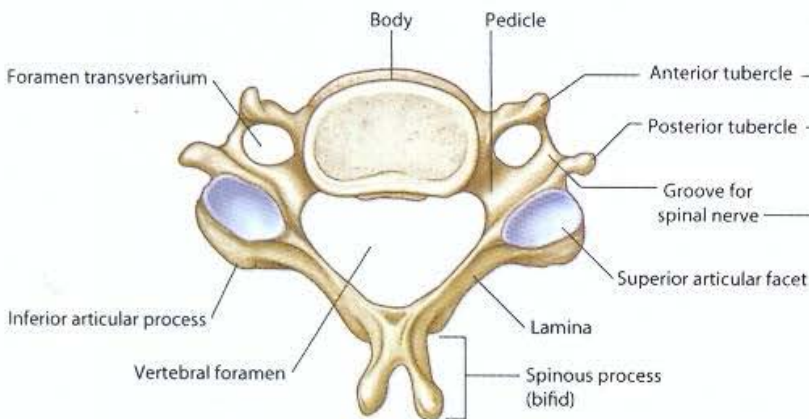
**C1 vertebra (atlas) anterior view**



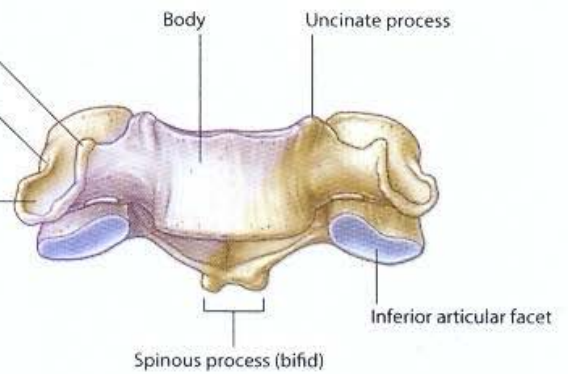
**C2 vertebra (axis) superior view**



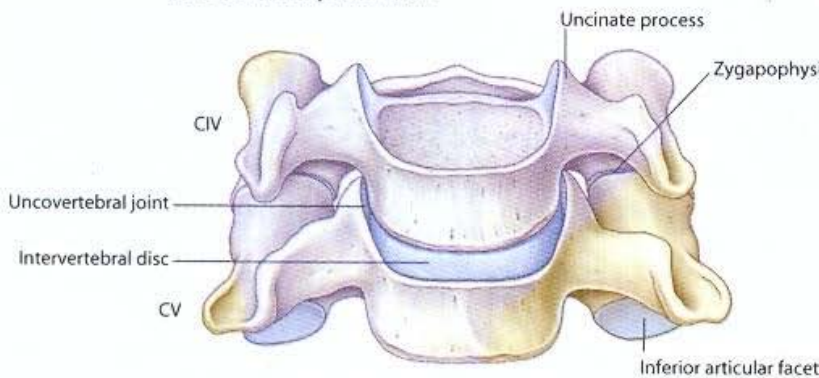
**C2 vertebra (axis) anterior view**



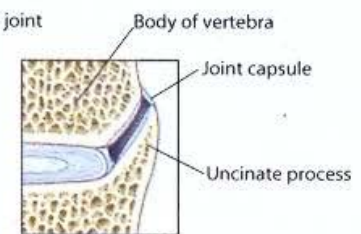
**C5 vertebra superior view**



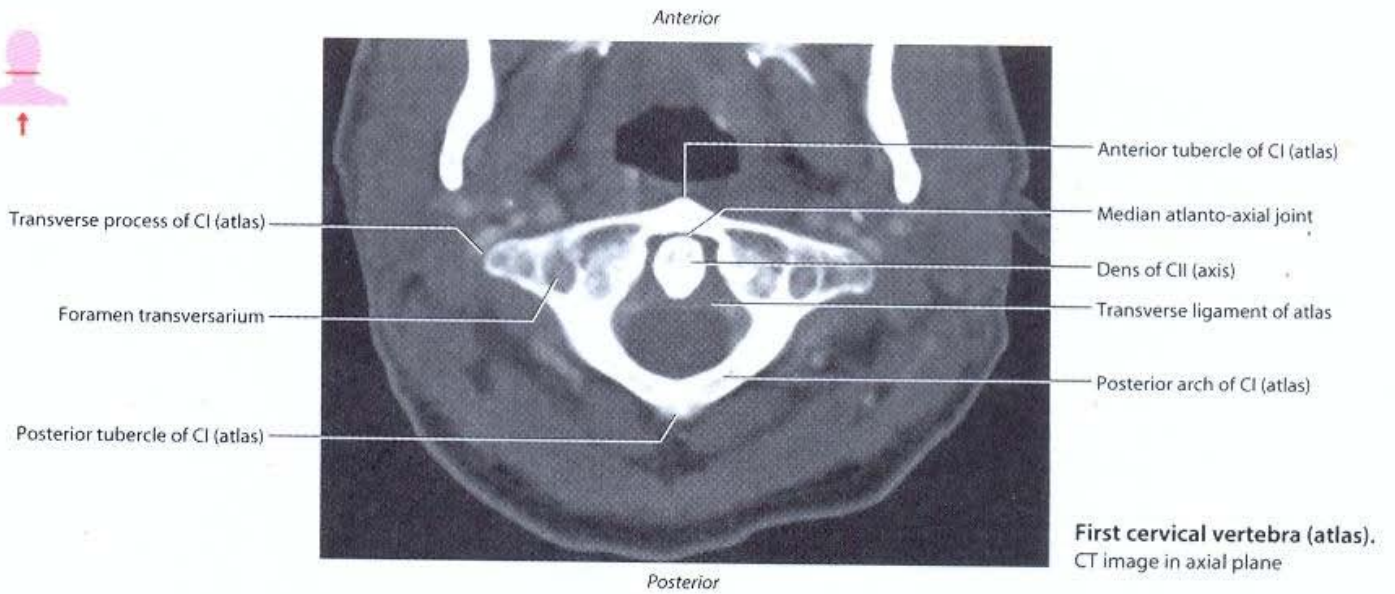
**C5 vertebra anterior view**



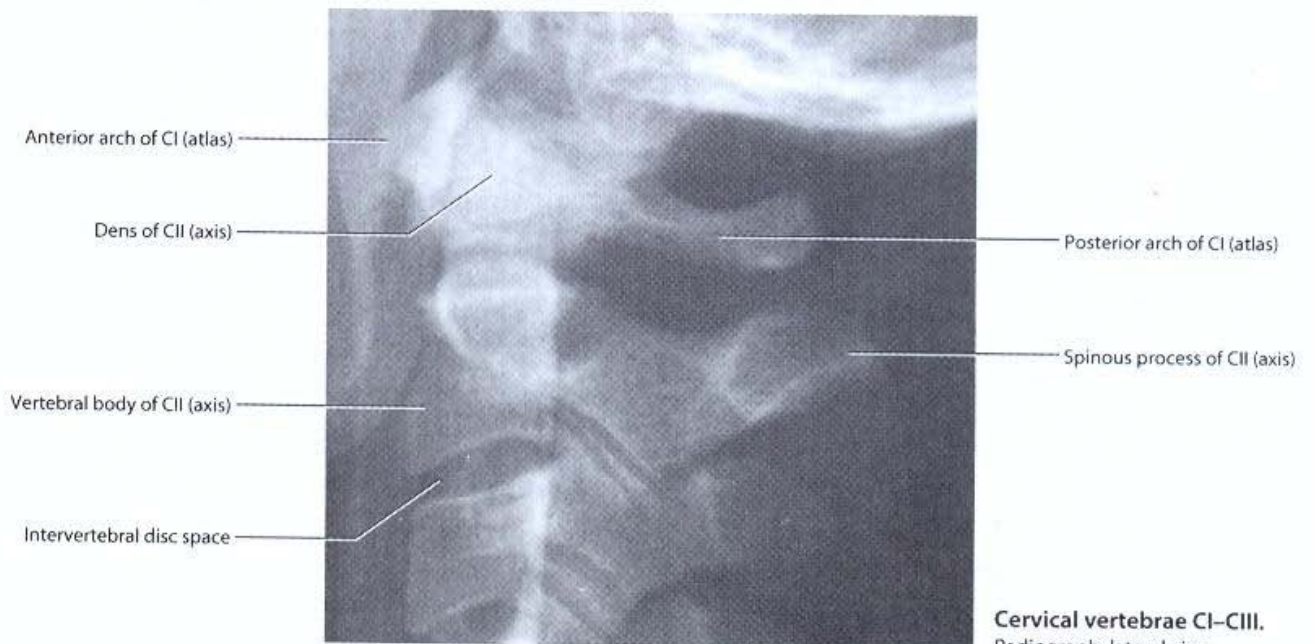
**C4/C5 vertebrae anterior view**



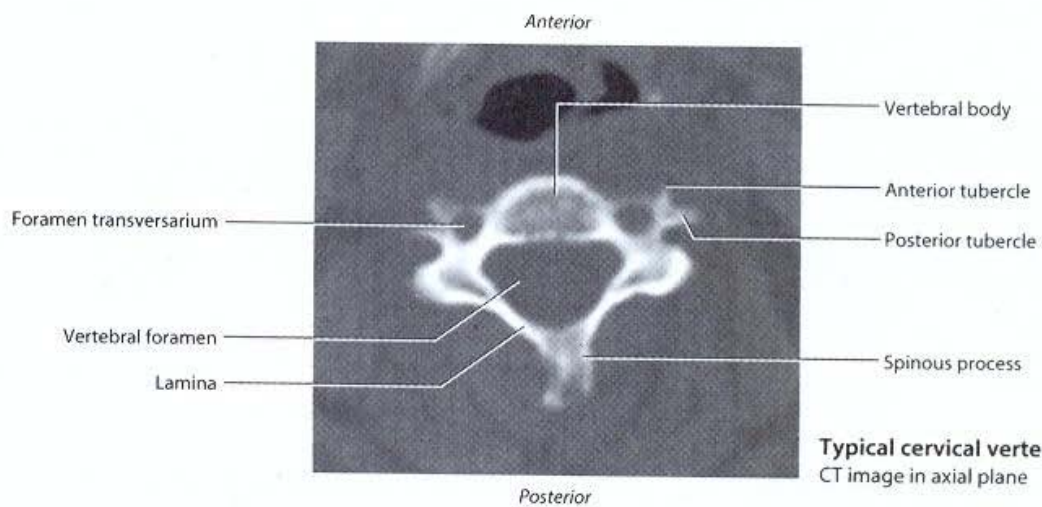
**Uncovertebral joint**



**First cervical vertebra (atlas).**  
CT image in axial plane

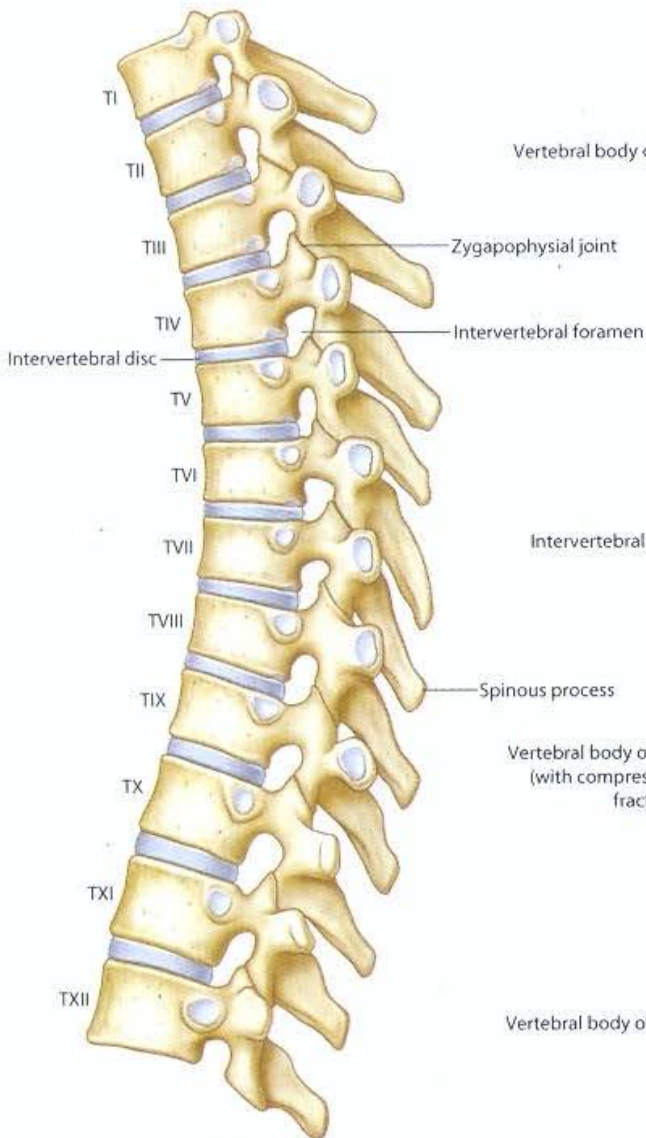


**Cervical vertebrae C1–C3.**  
Radiograph, lateral view

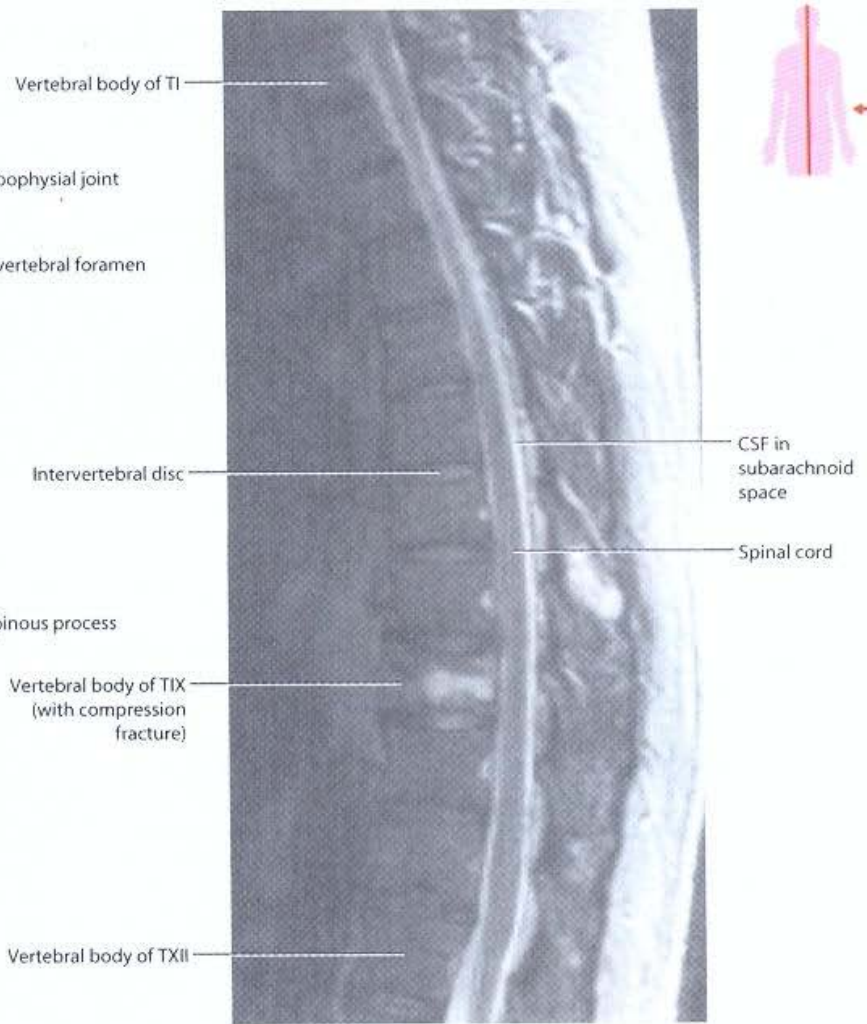


**Typical cervical vertebra.**  
CT image in axial plane



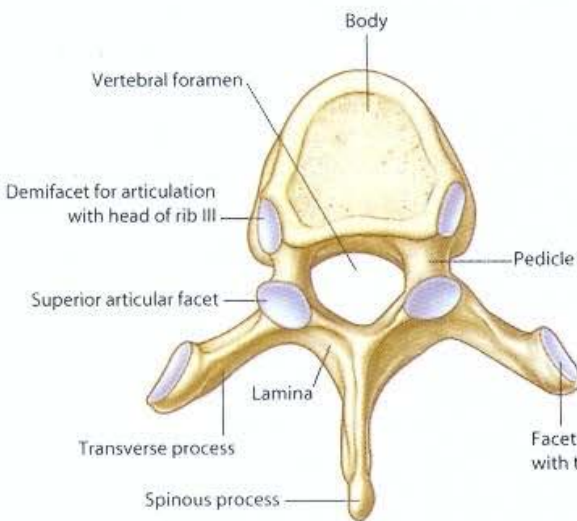


**Thoracic vertebrae lateral view**

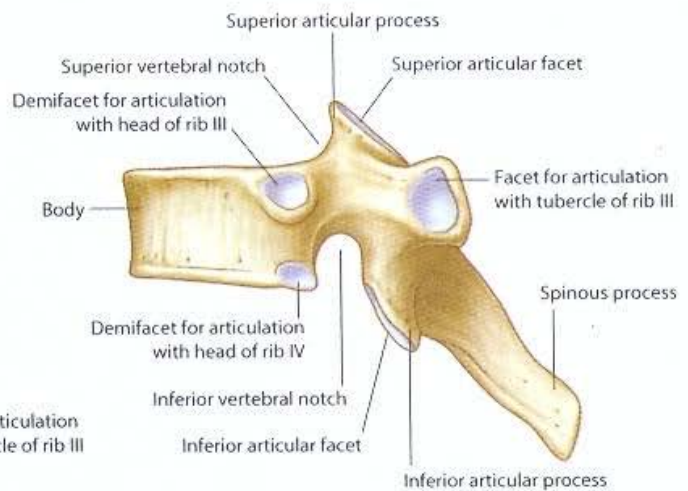


**Thoracic region of vertebral column.**

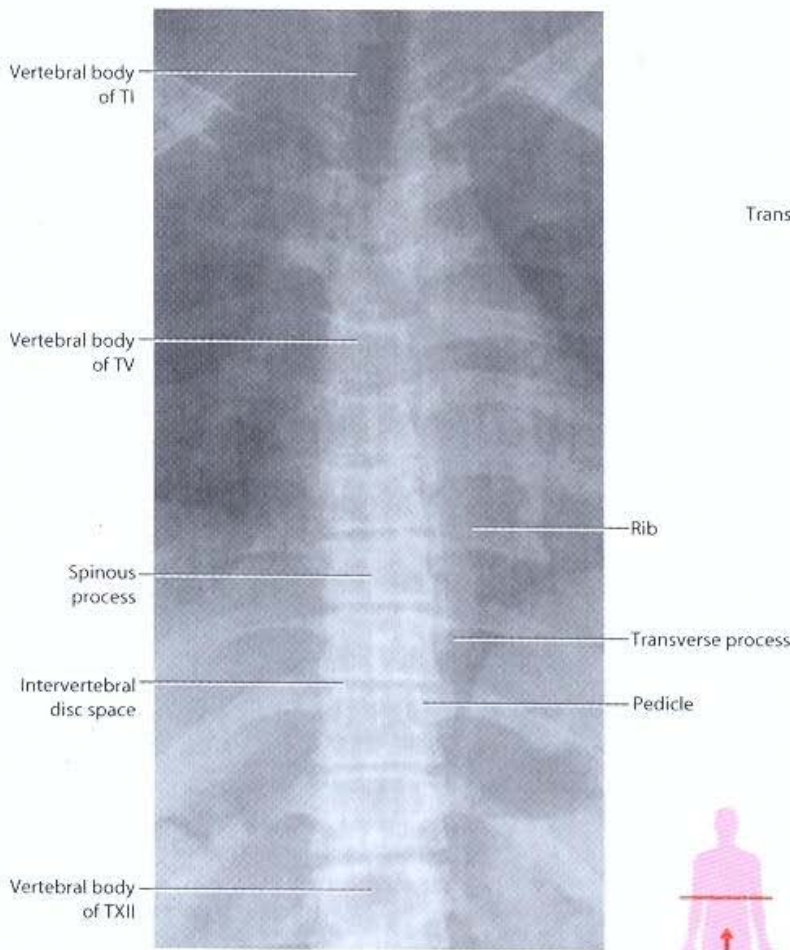
T2-weighted MR image in sagittal plane (compression fracture TIX)



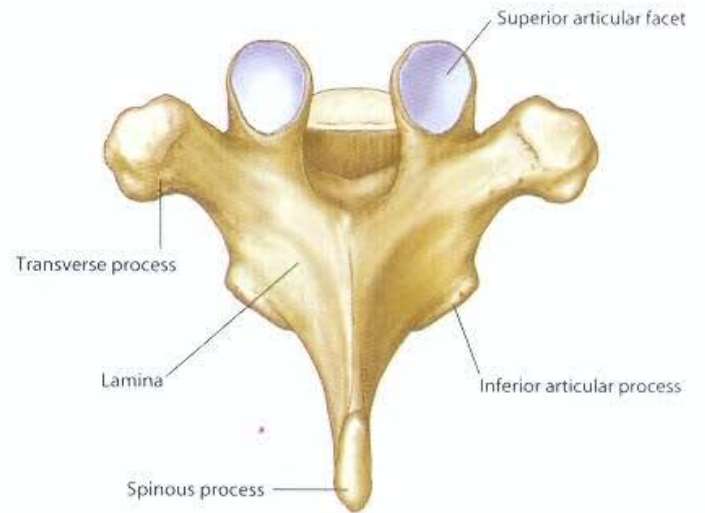
**TIII vertebra superior view**



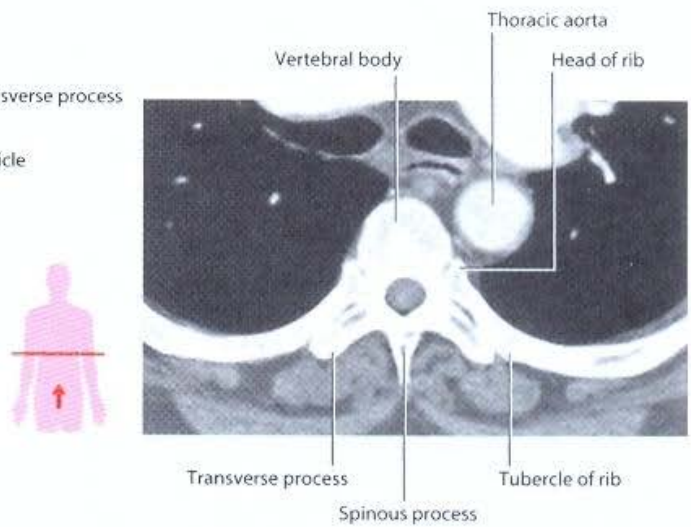
**TIII vertebra lateral view**



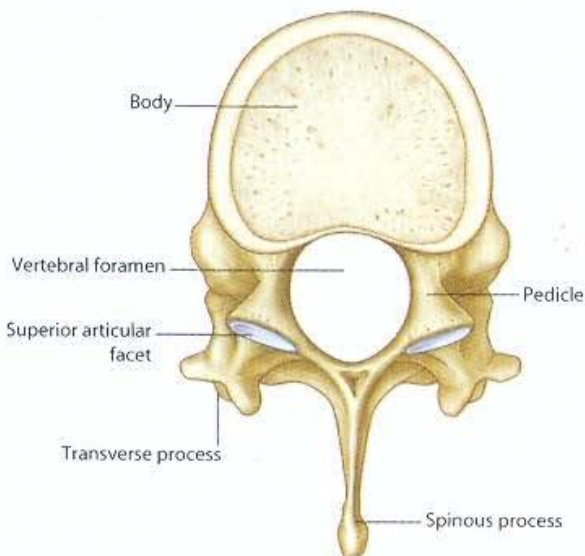
Thoracic region of vertebral column.  
Radiograph, AP view



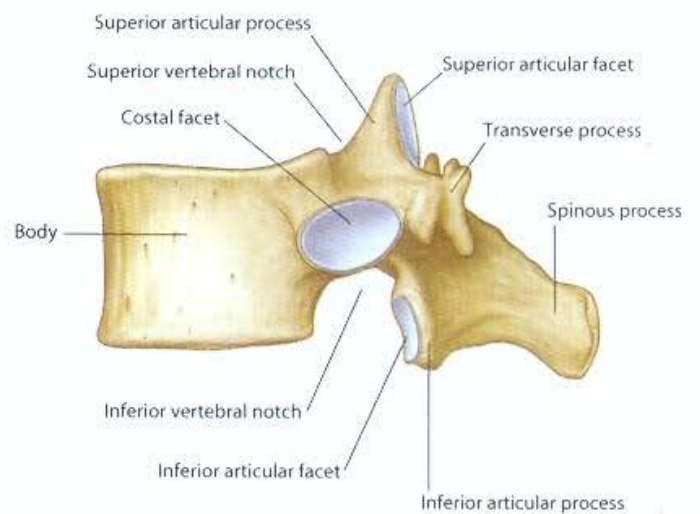
T11 vertebra posterior view



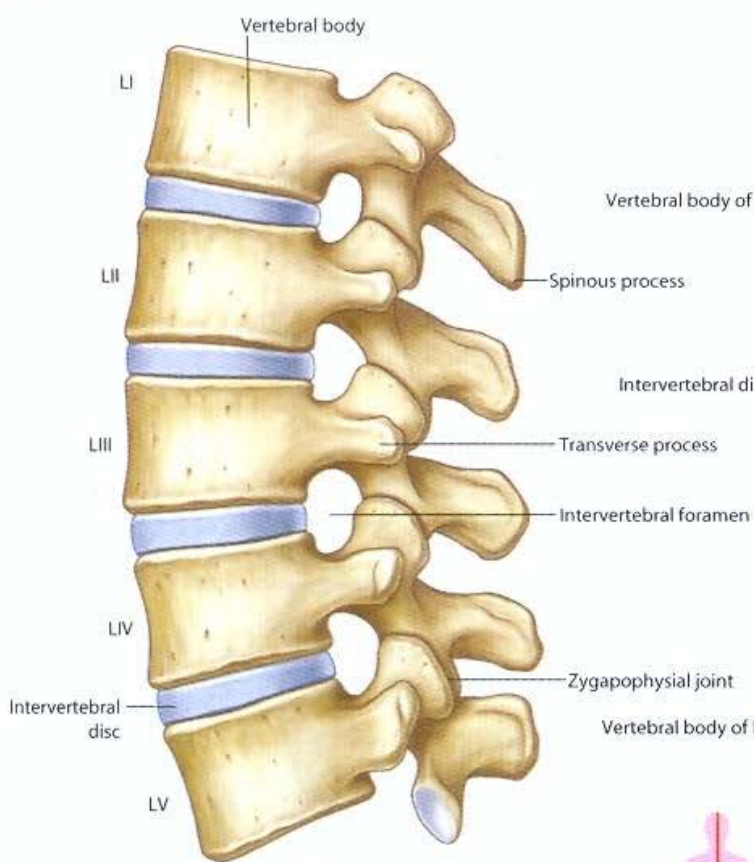
Thoracic vertebra with rib articulations.  
CT image in axial plane



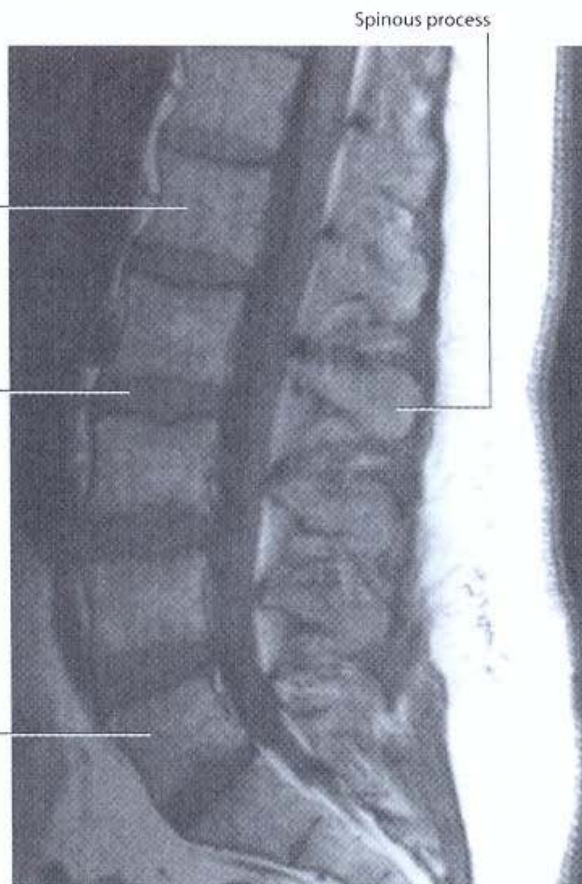
TXII vertebra superior view



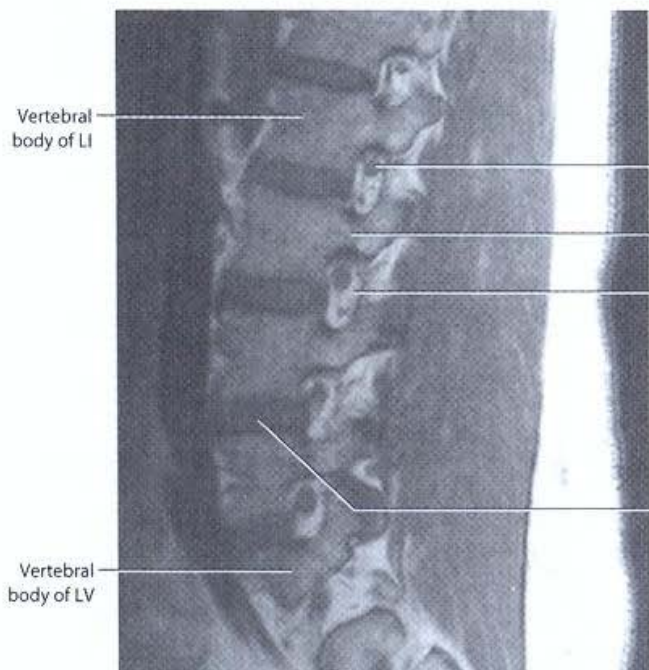
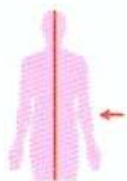
TXII vertebra lateral view



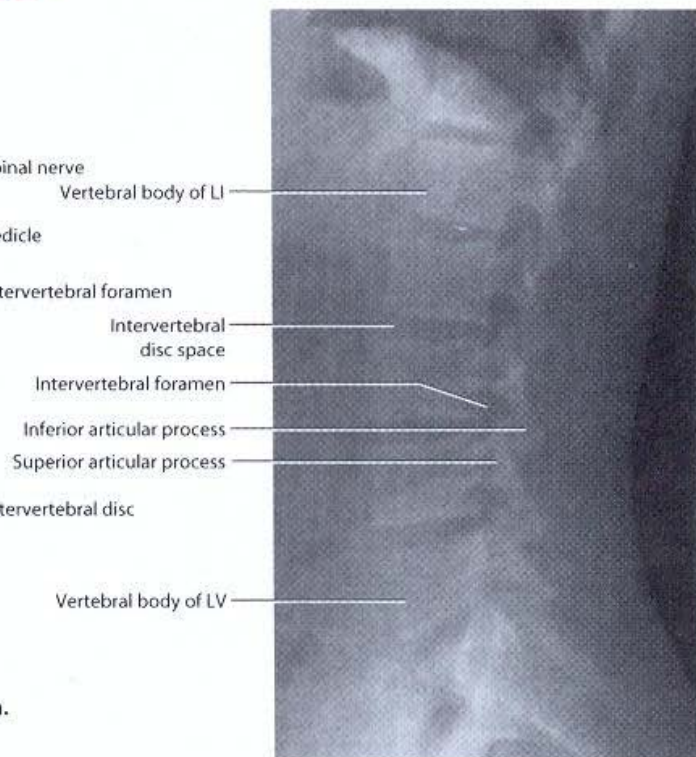
**Lumbar vertebrae lateral view**



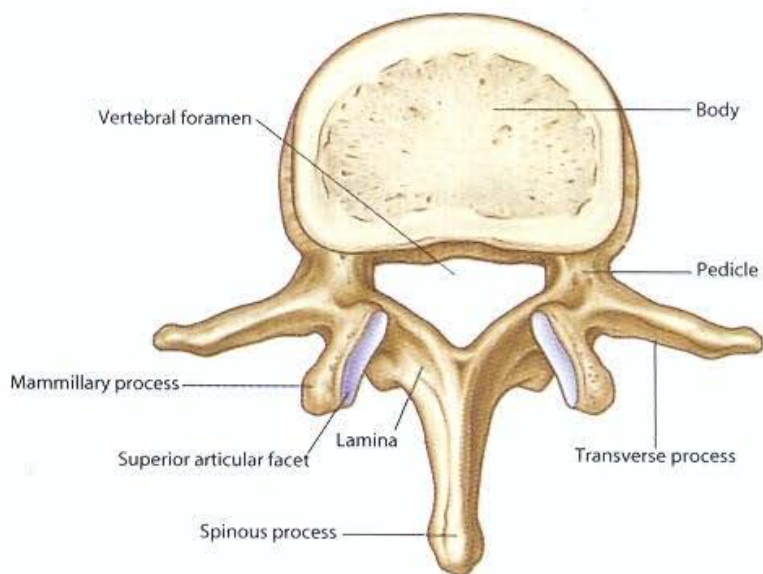
**Lumbar region of vertebral column.**  
T1-weighted MR image in sagittal plane



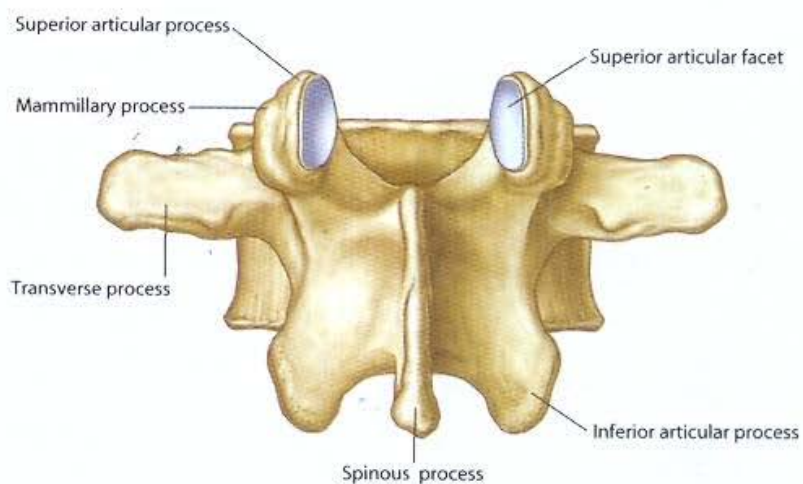
**Intervertebral foramina of lumbar region of vertebral column.**  
T1-weighted MR image in sagittal plane



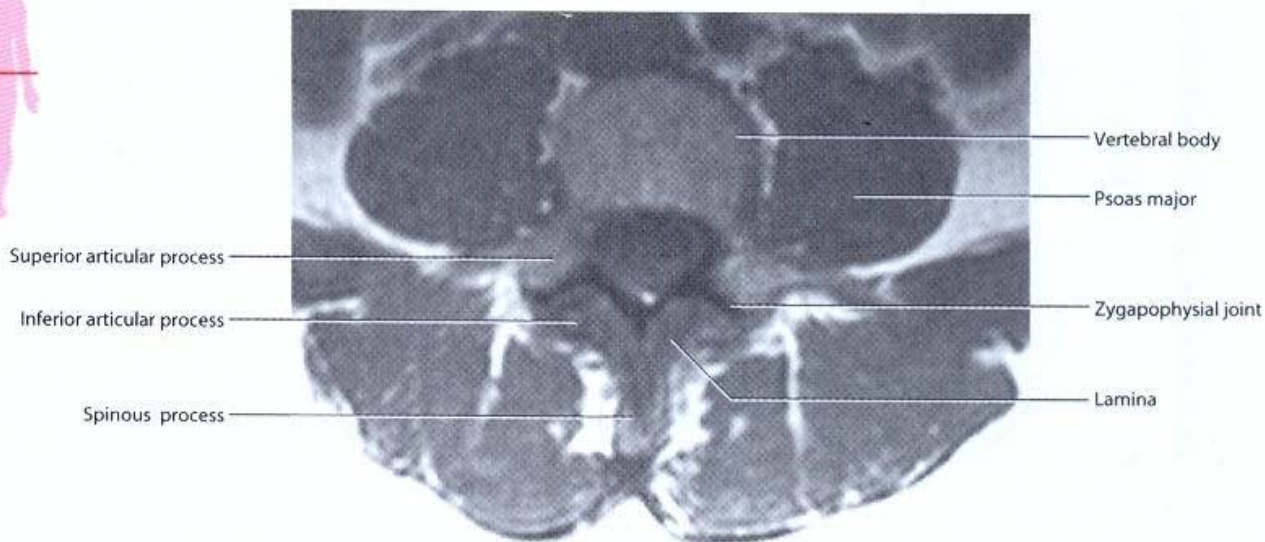**Lumbar region of vertebral column.**  
Radiograph, lateral view



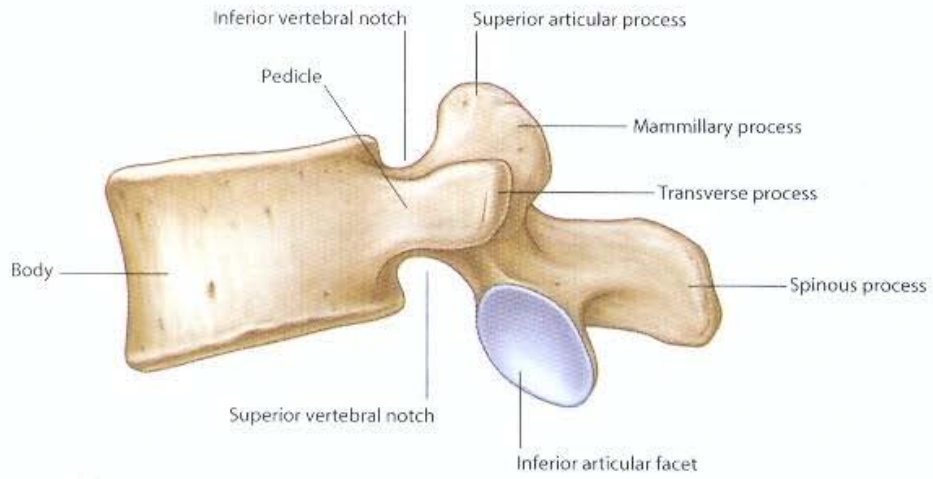
LIV vertebra superior view



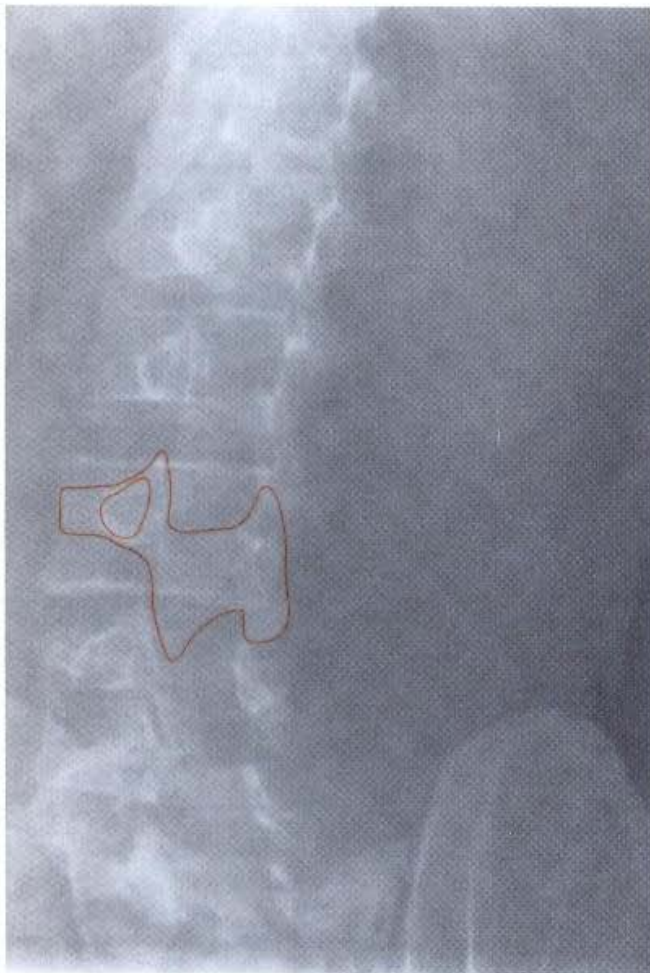LIV vertebra posterior view



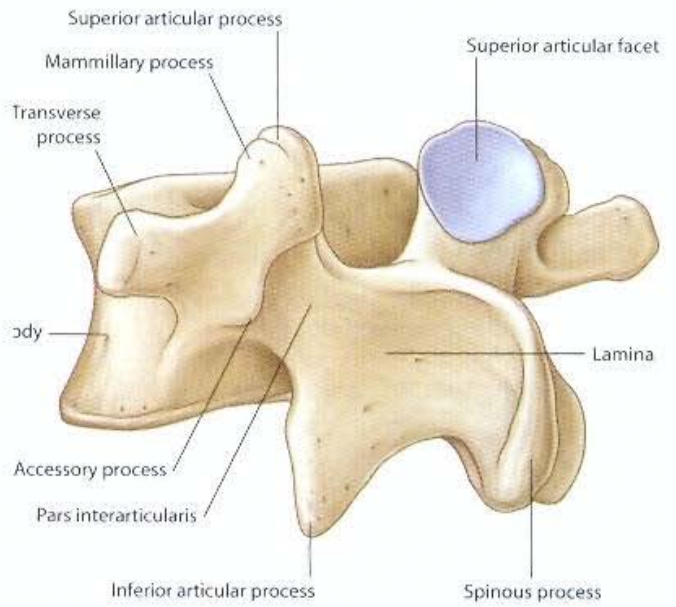
Articulation of lumbar vertebrae.  
T1-weighted MR image in axial plane



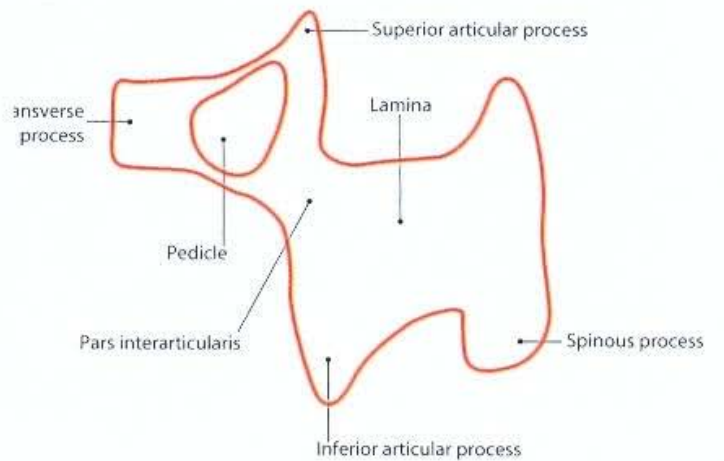
**LIV vertebra lateral view**

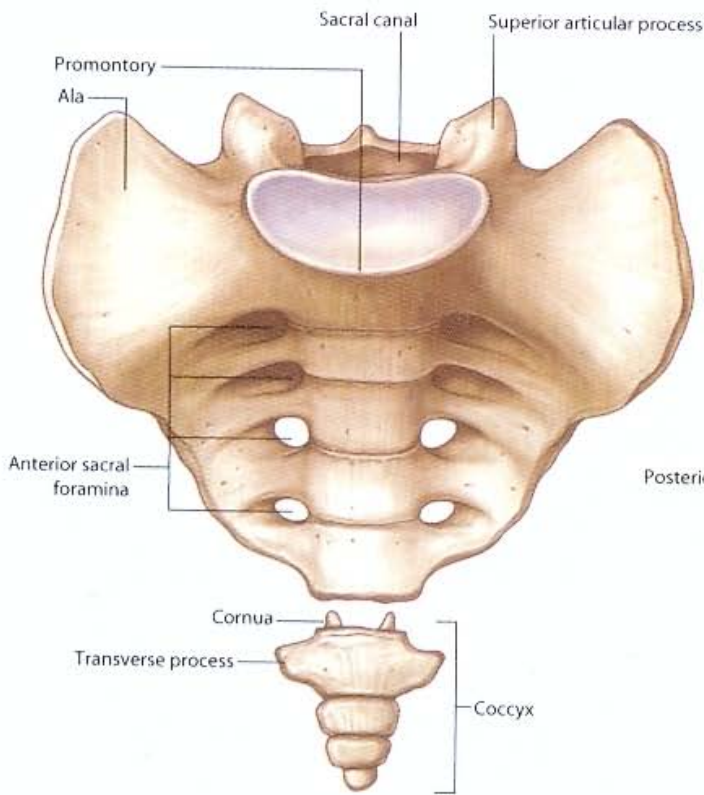


**Lumbar region of vertebral column ("Scottie dog").**  
Radiograph, oblique view

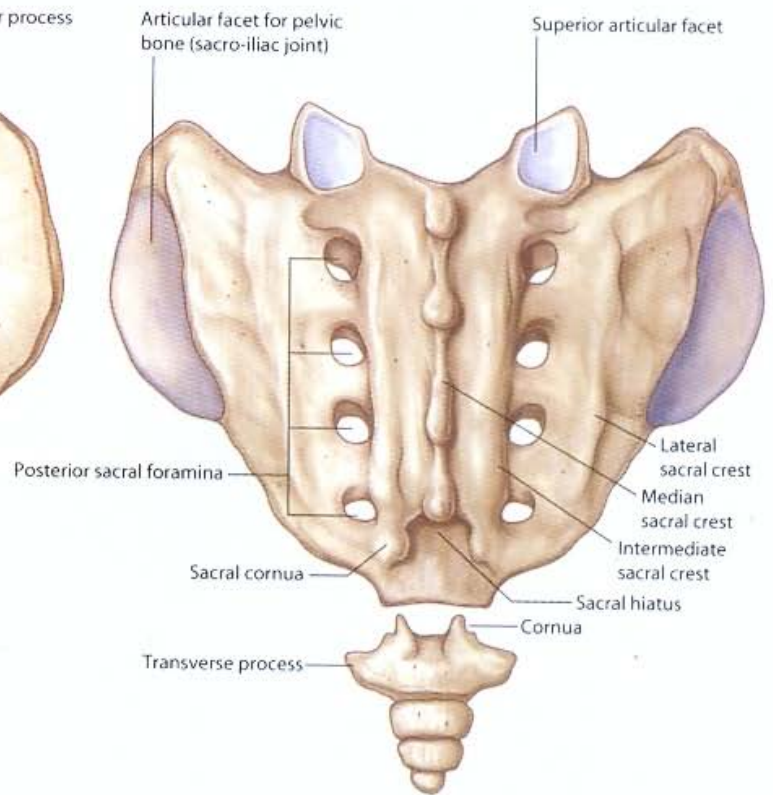


**LIV vertebra oblique view**

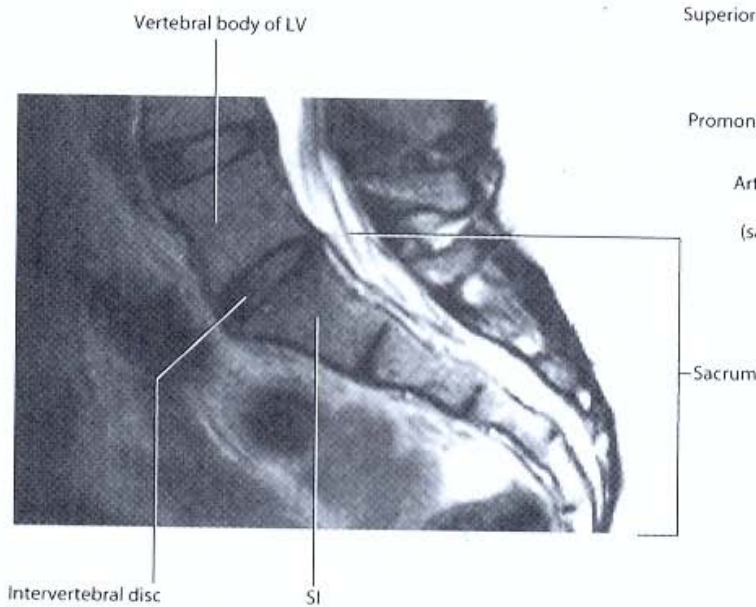




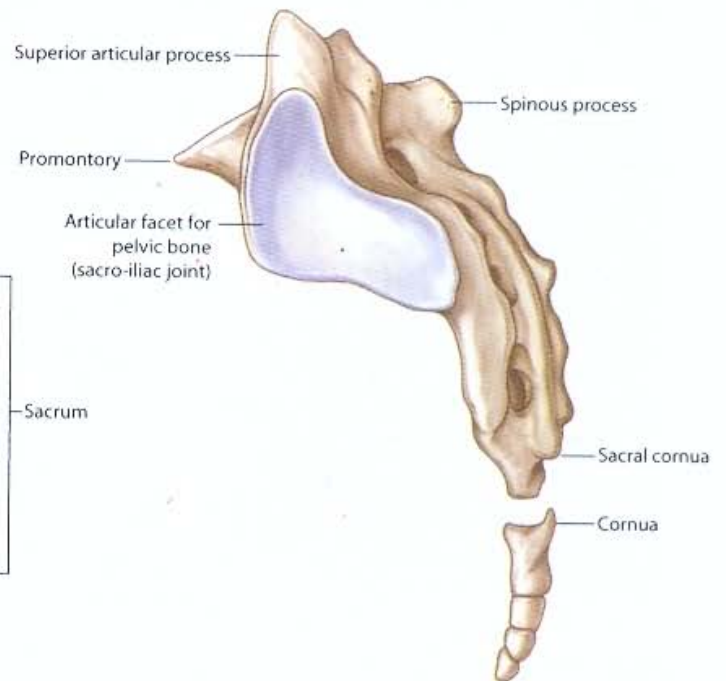
Sacrum and coccyx anterior view



Sacrum and coccyx posterior view

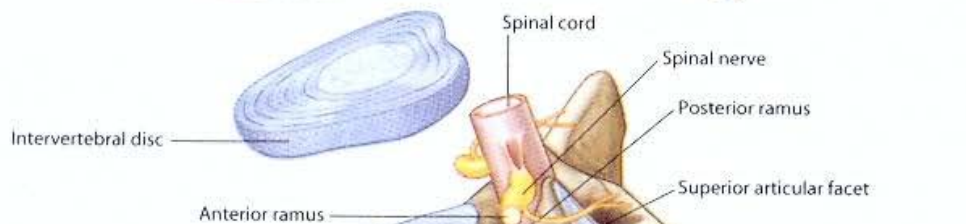
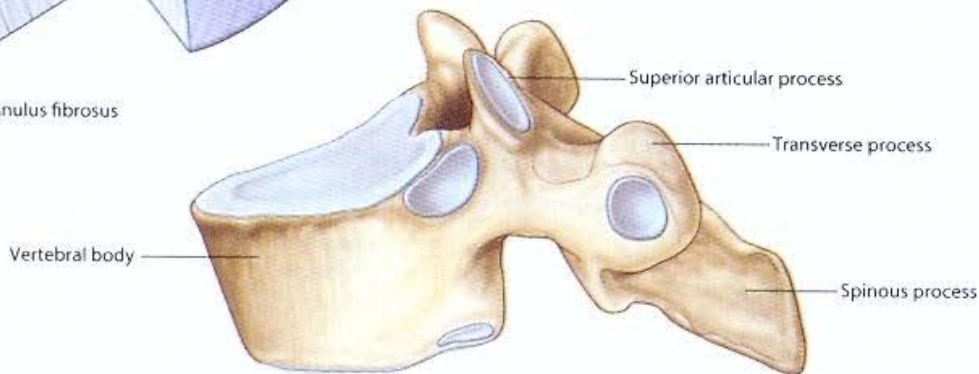
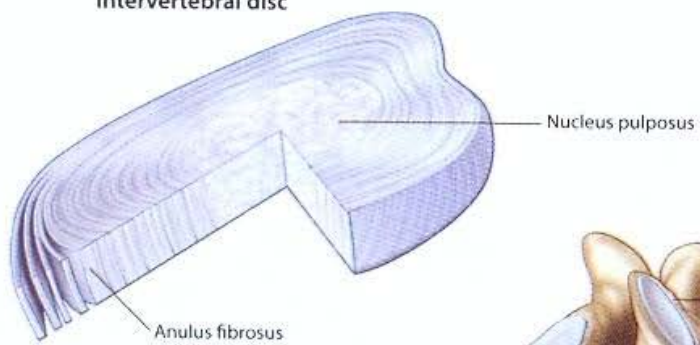


Sacral region of vertebral column.  
T2-weighted MR image in sagittal plane

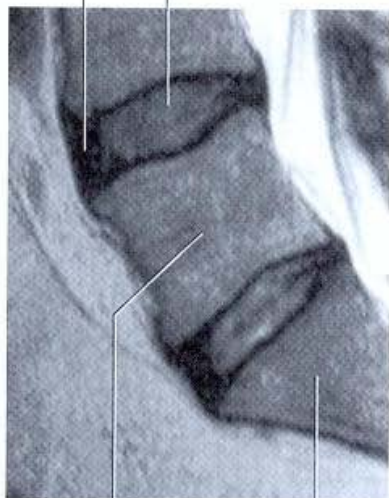


Sacrum and coccyx lateral view

**Intervertebral disc**

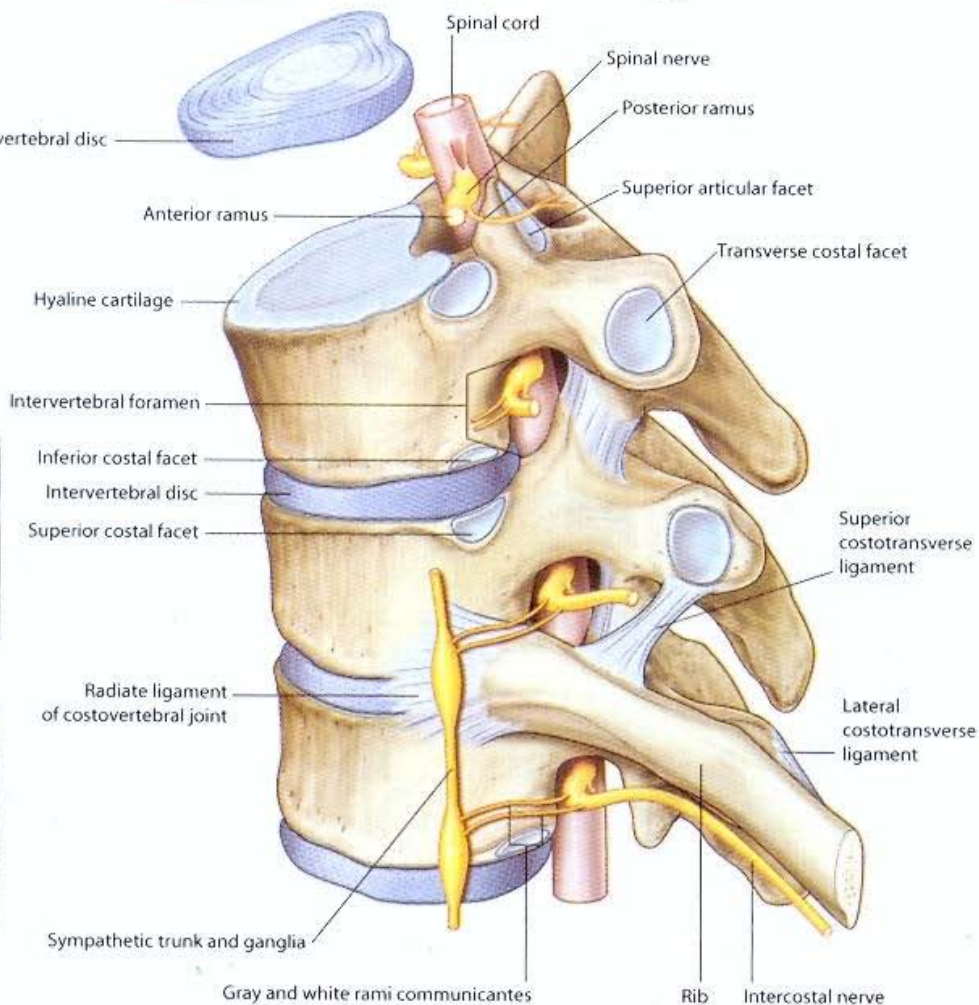


Intervertebral disc  
Anulus fibrosus  
Nucleus pulposus

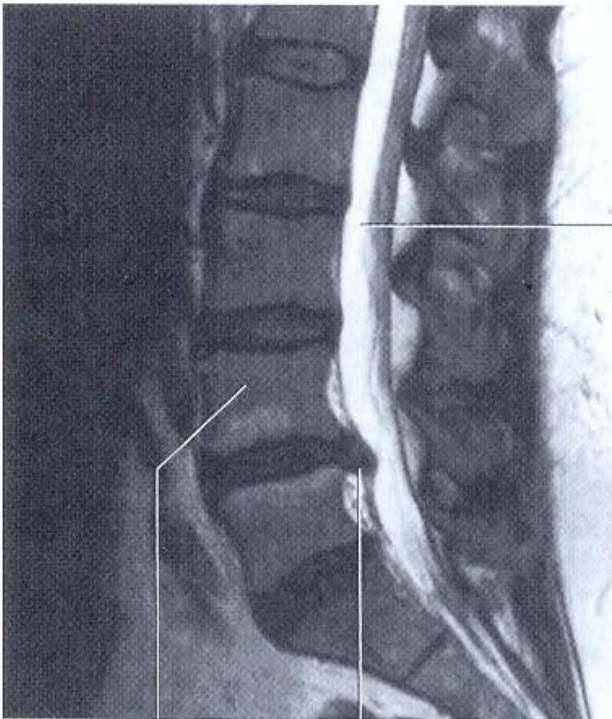


Vertebral body of LV  
Sacrum

**Intervertebral disc in lower lumbar region of vertebral column.**  
T2-weighted MR image in sagittal plane



**Intervertebral foramina and discs in the thoracic region**

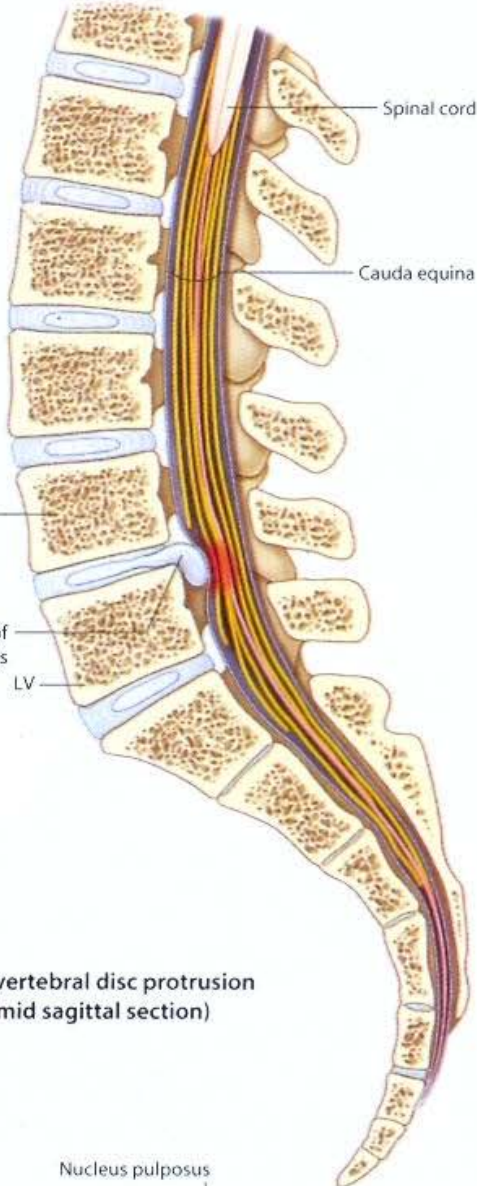


LIV vertebra      Disc protrusion

**Intervertebral disc protrusion in lower lumbar region of vertebral column.**

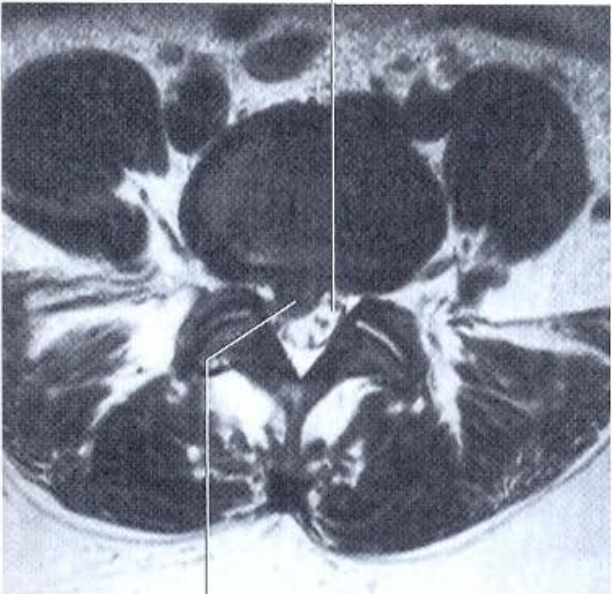
T2-weighted MR image in sagittal plane

Vertebral canal containing CSF and cauda equina



Herniation of nucleus pulposus  
LV

**Intervertebral disc protrusion (mid sagittal section)**

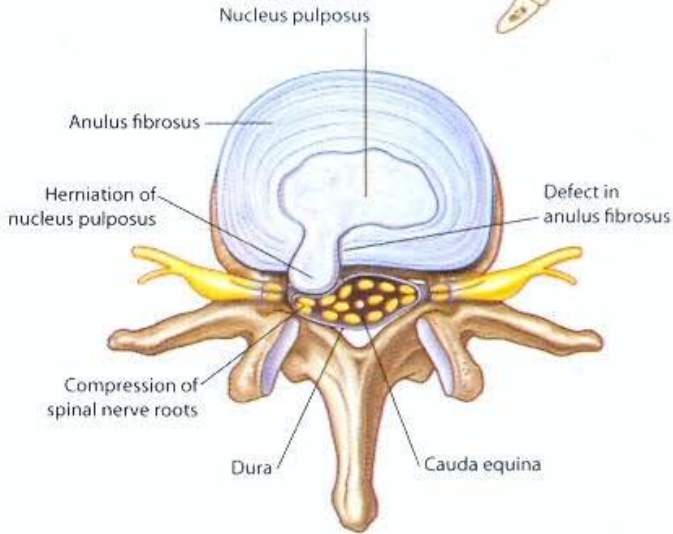


Disc protrusion

**Intervertebral disc protrusion in lower lumbar region of vertebral column.**

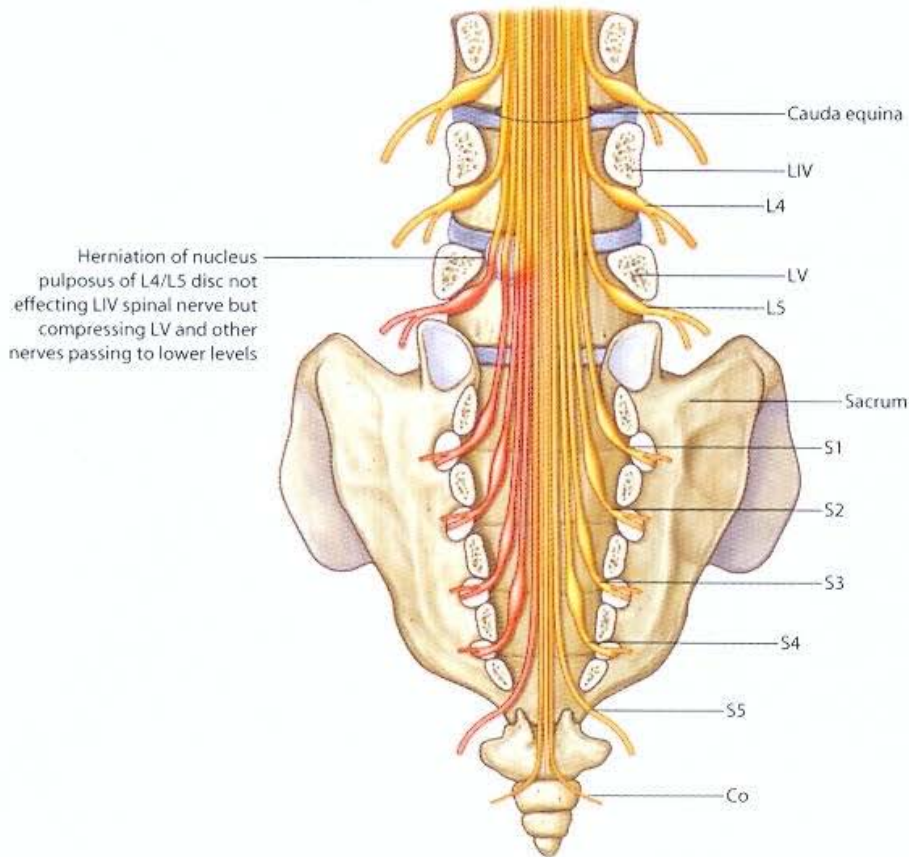
T2-weighted MR image in axial plane

Vertebral canal containing CSF and cauda equina



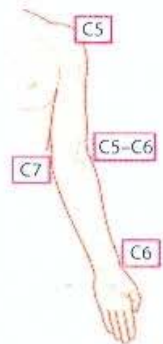
**Intervertebral disc protrusion (superior view)**





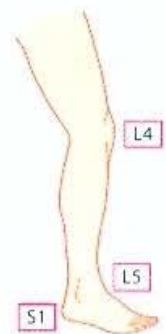
Intervertebral disc protrusion (posterior view)

Nerve root	Main weakness	Reflex decreased	Area of sensory decrease	Disc involved
C5	Deltoid (biceps)	(biceps, pectoralis)	Shoulder, upper lateral arm	C4–C5
C6	Wrist extension	(biceps, brachioradialis)	1st and 2nd digits (lateral forearm)	C5–C6
C7	Triceps	Triceps	Third finger	C6–C7
C8	Intrinsic hand muscles		4th and 5th digits (medial forearm)	C7–T1

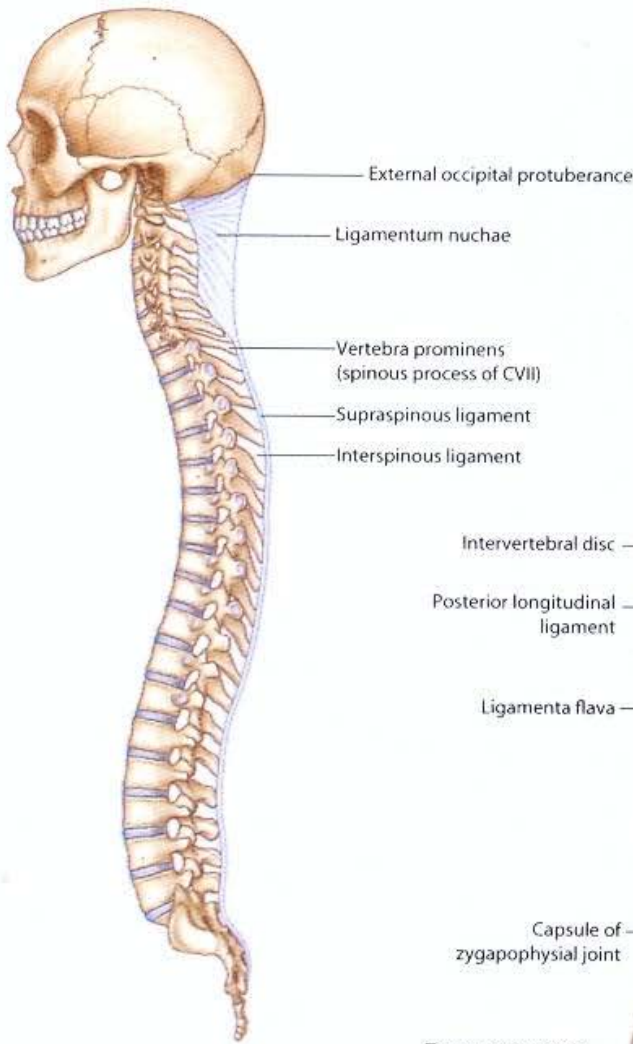


Clinically important nerve roots in the upper limb

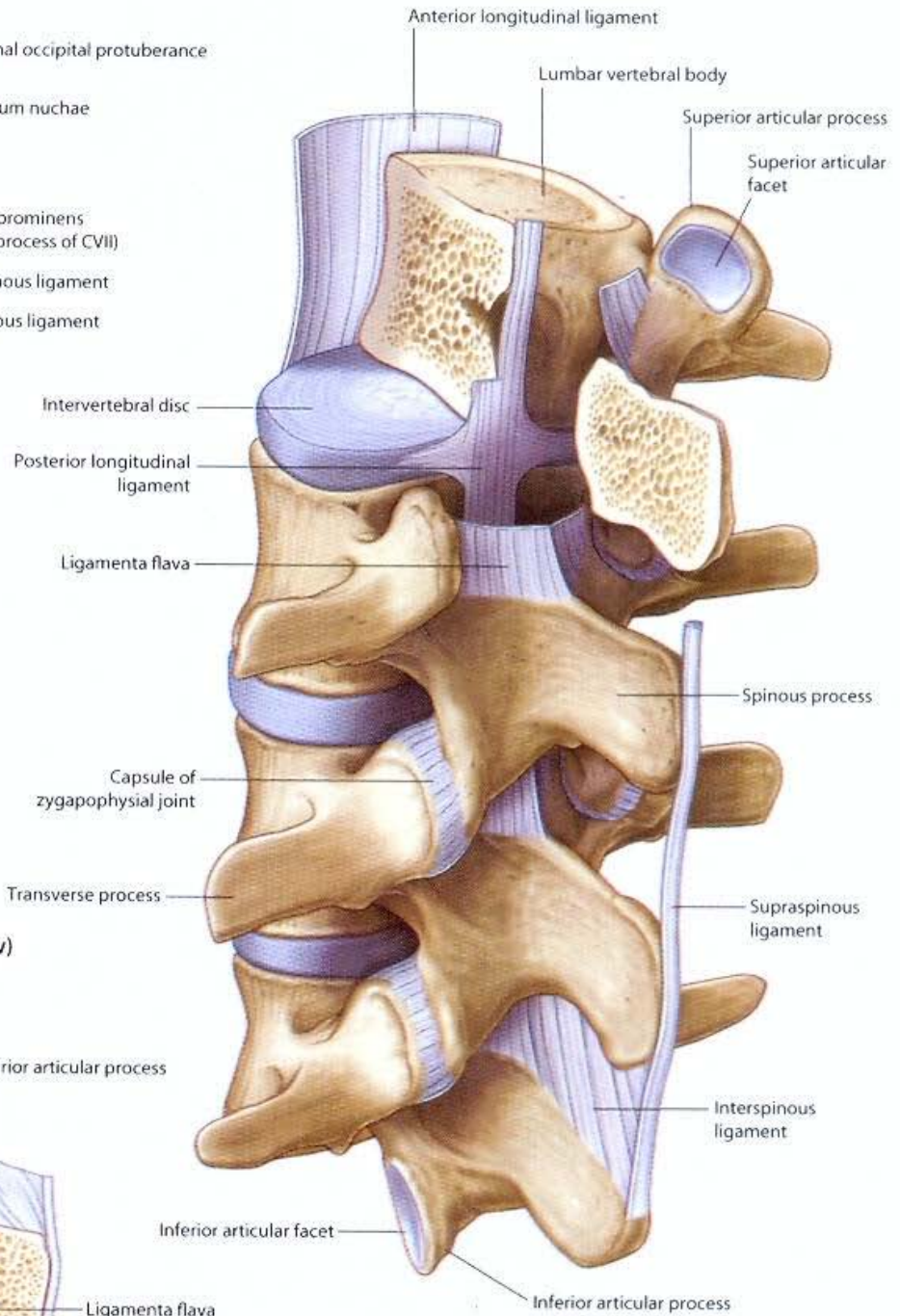
Nerve root	Main weakness	Reflex decreased	Area of sensory decrease	Disc involved
L4	Iliopsoas and quadriceps	Patellar tendon (knee jerk)	Knee, medial lower leg	L3–L4
L5	Dorsiflexion of foot at ankle (big toe extension, foot eversion and inversion)		Dorsum of foot, big toe	L4–L5
S1	Plantar flexion of foot at ankle	Achilles tendon (ankle jerk)	Lateral foot, small toe, sole	L5–S1



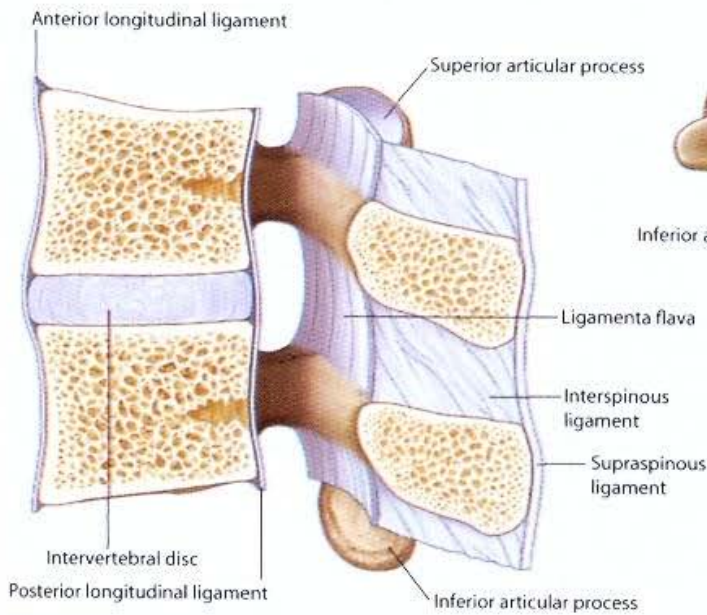
Clinically important nerve roots in the lower limb



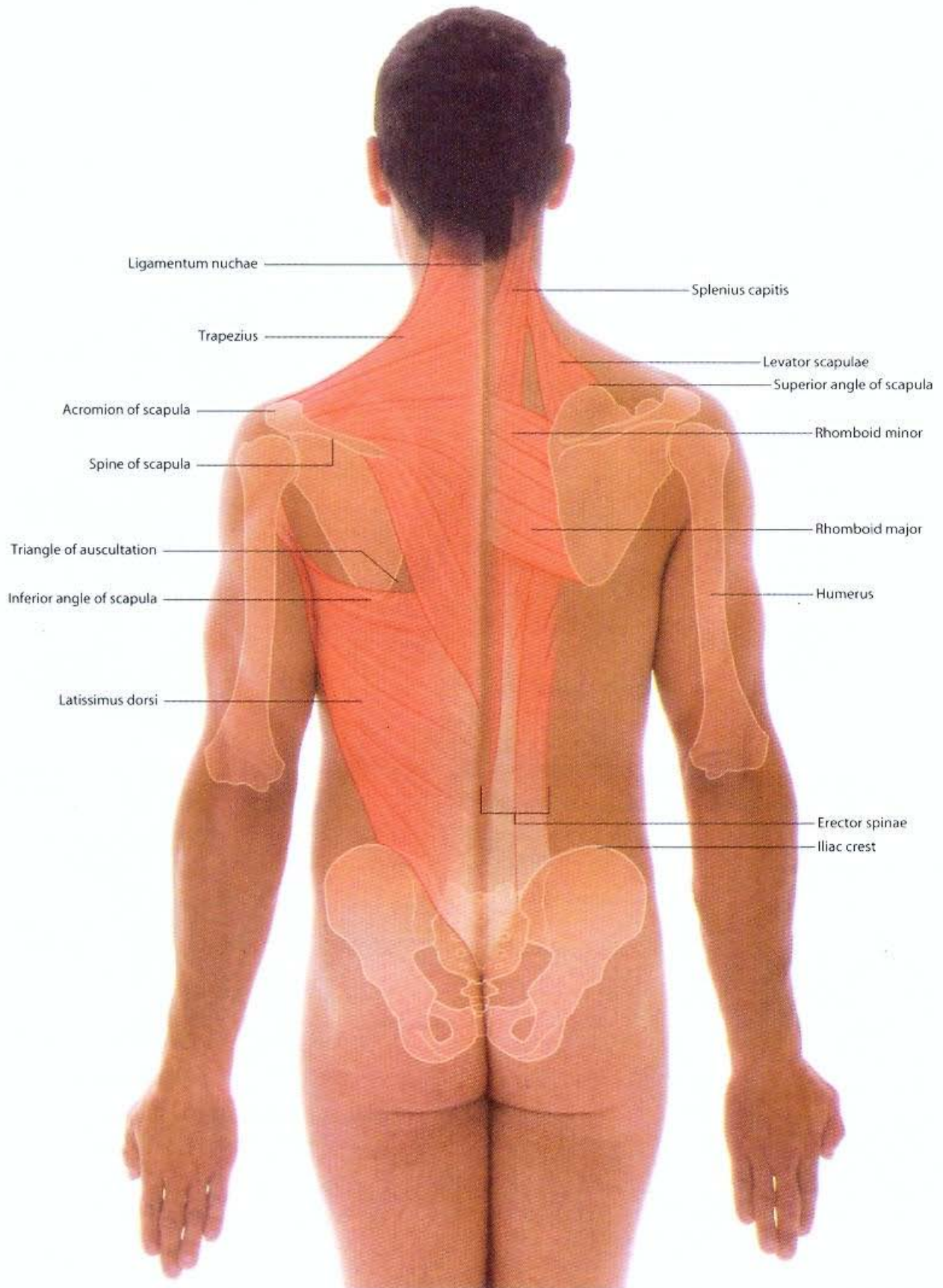
Ligamentum nuchae and supraspinous ligament (lateral view)



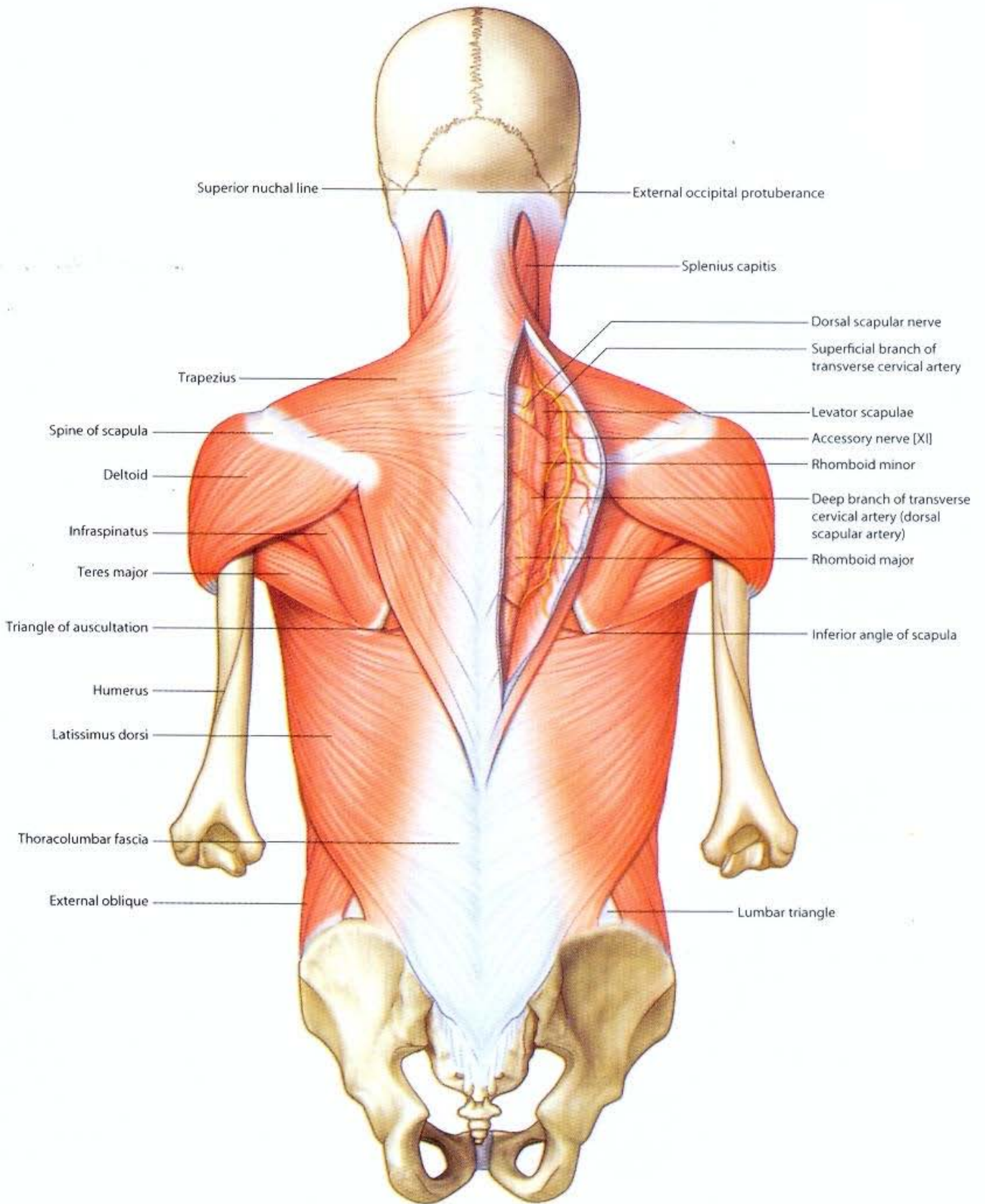
Vertebral ligaments of the lumbar region (posterior oblique view)



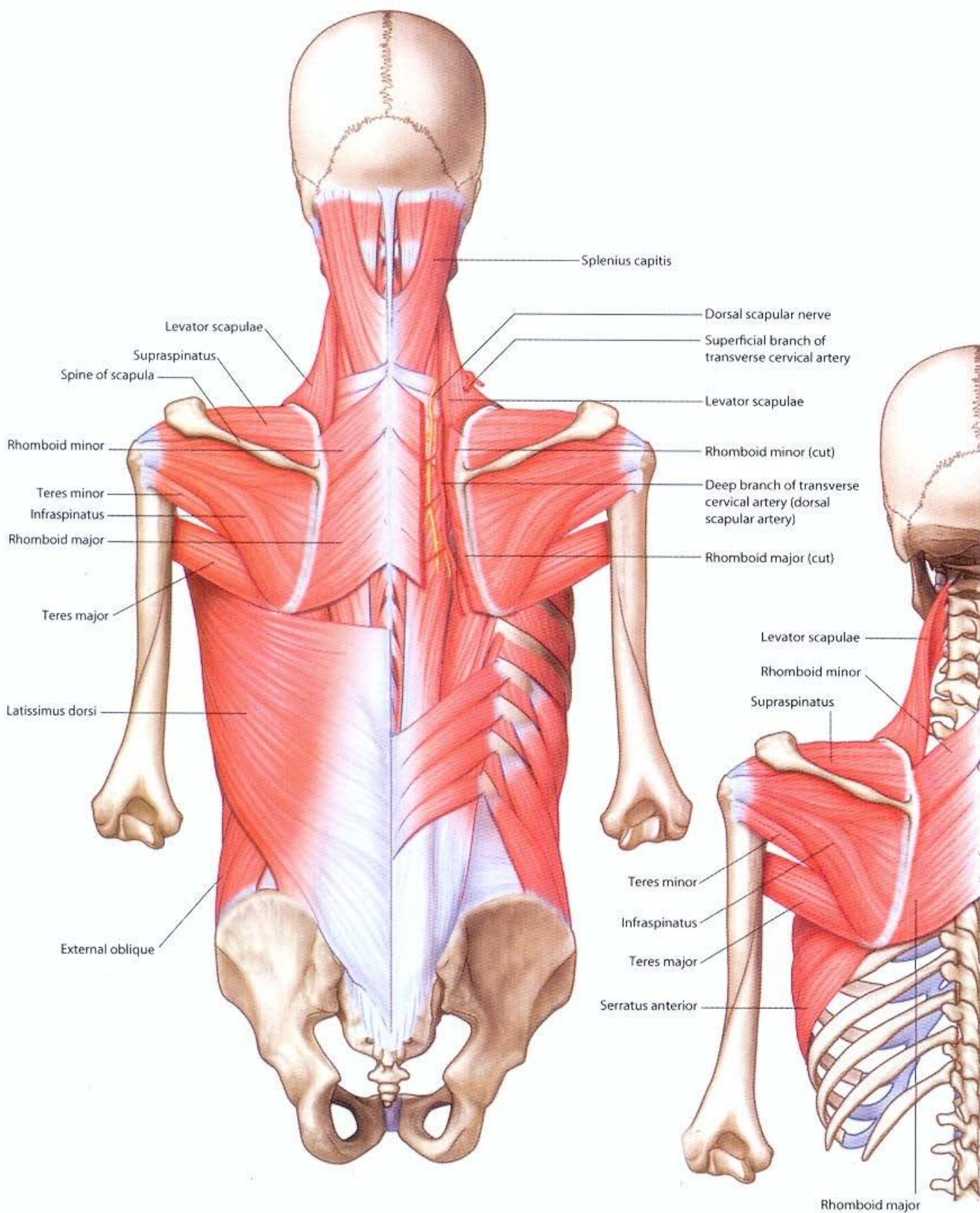
Ligamenta flava



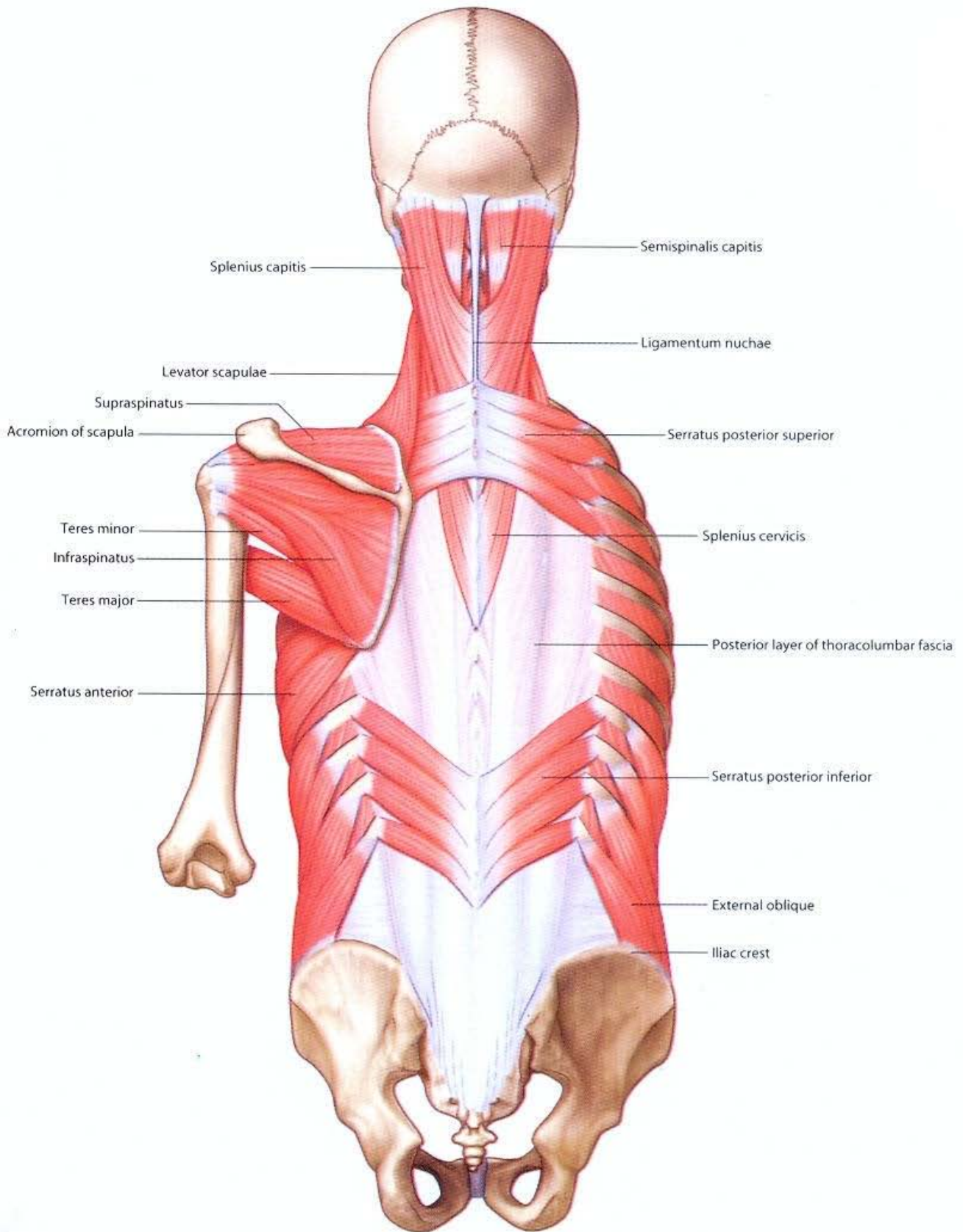
Posterior view of male showing surface projections of back muscles



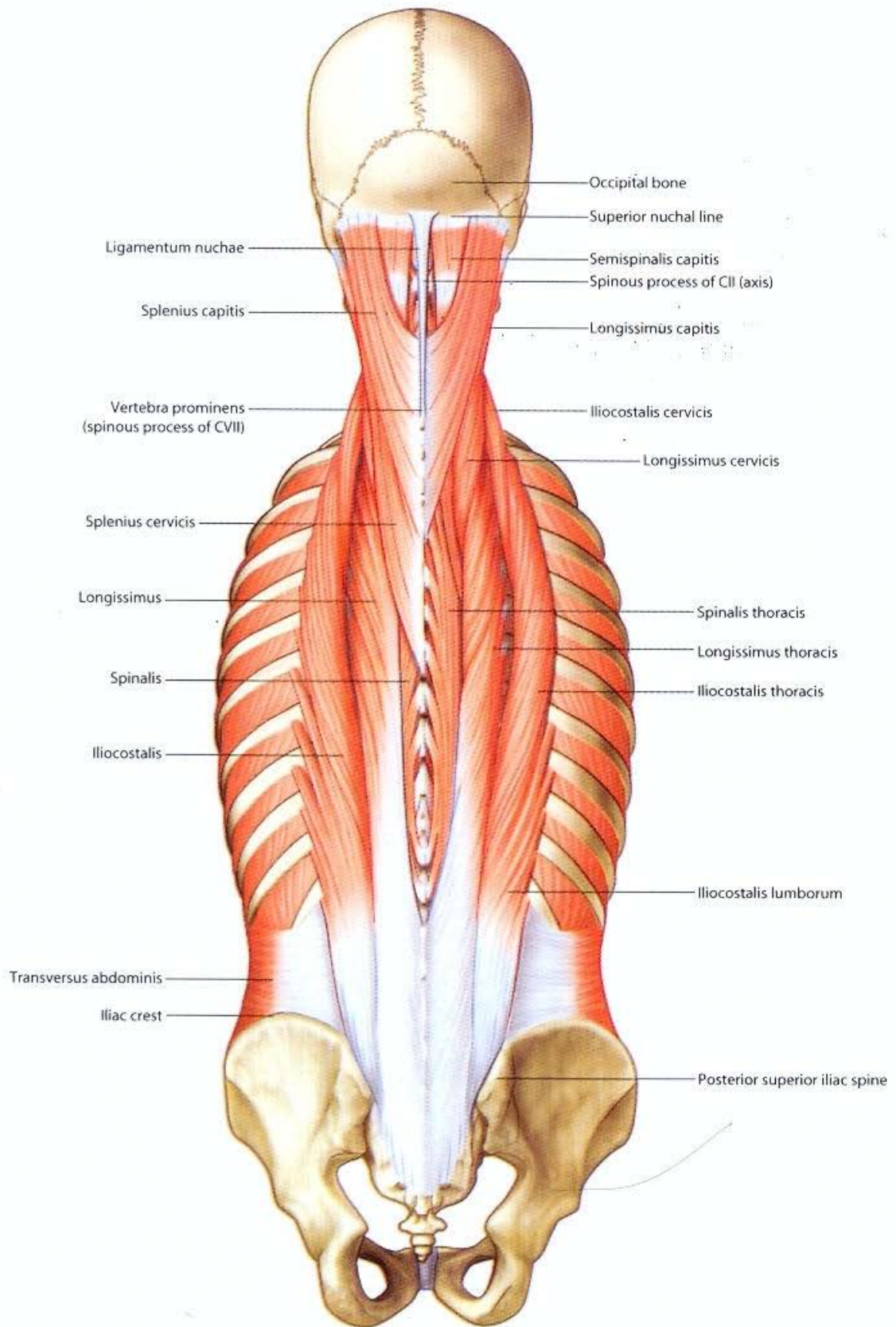
Superficial musculature – trapezius and latissimus dorsi



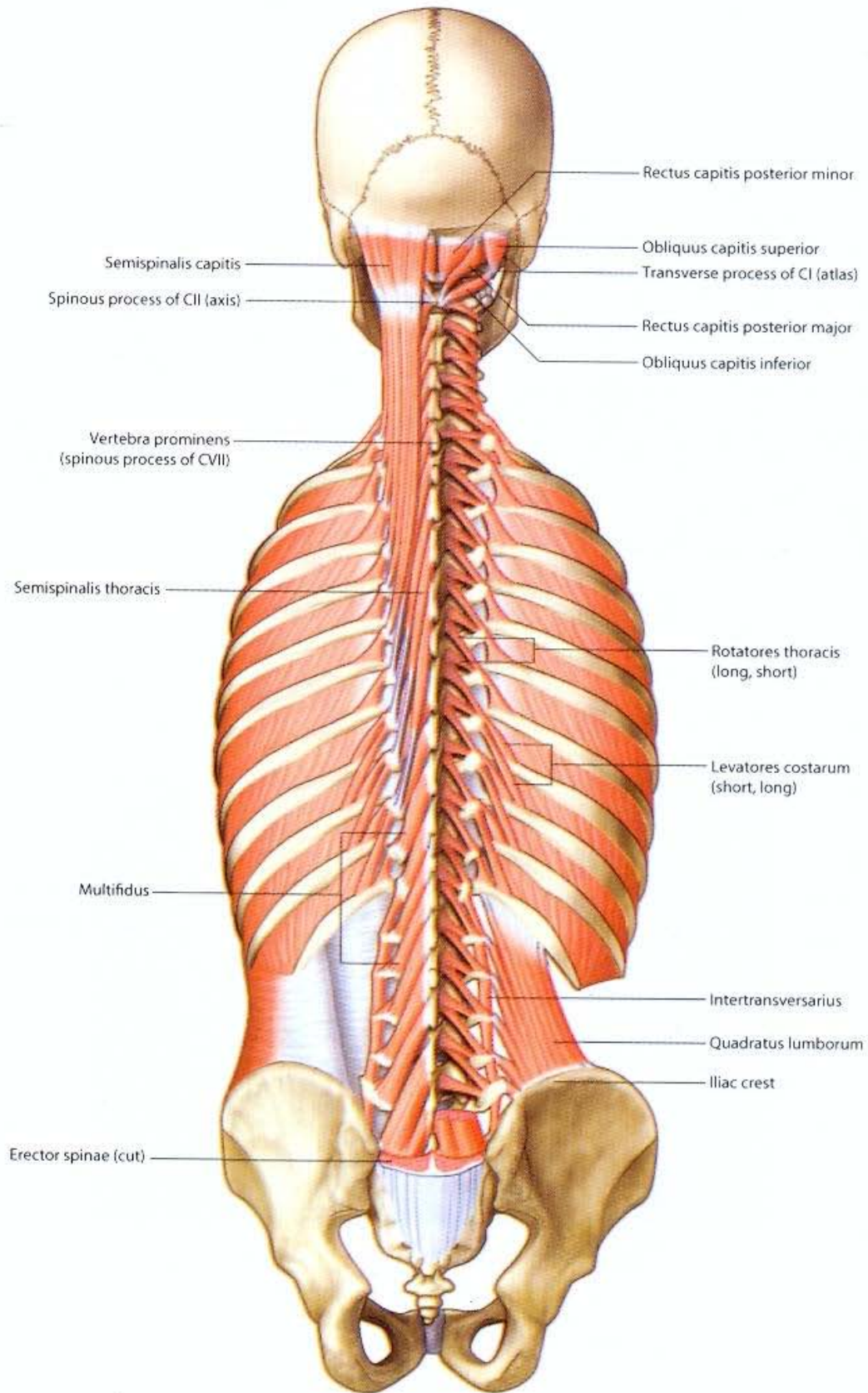
Superficial musculature – levator scapulae and rhomboid major and minor



Intermediate musculature

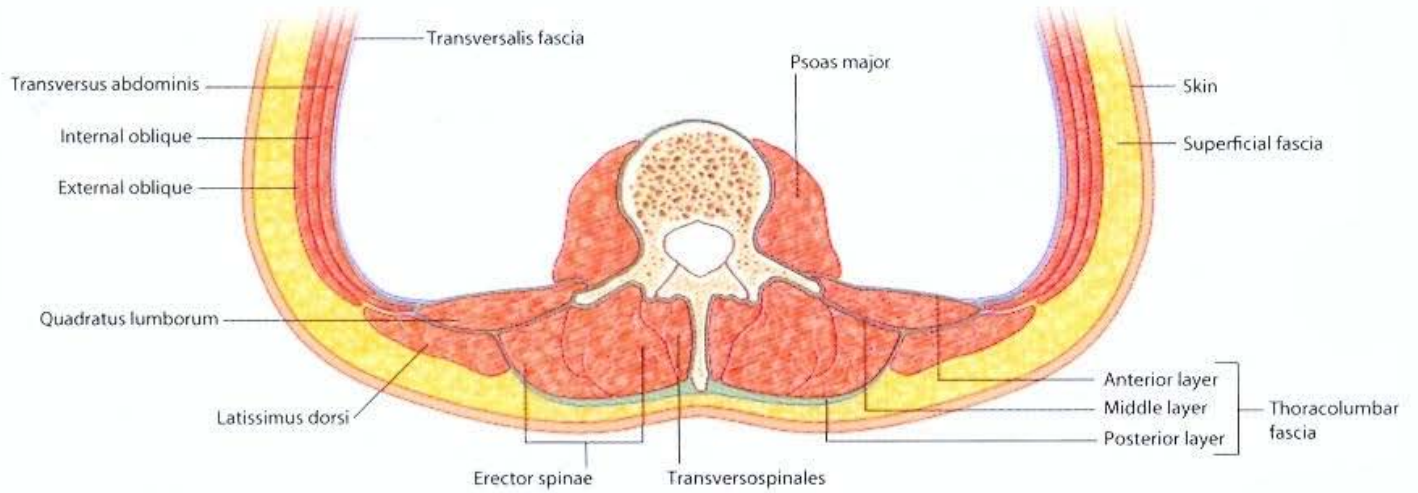


Deep group of back muscles – erector spinae muscles

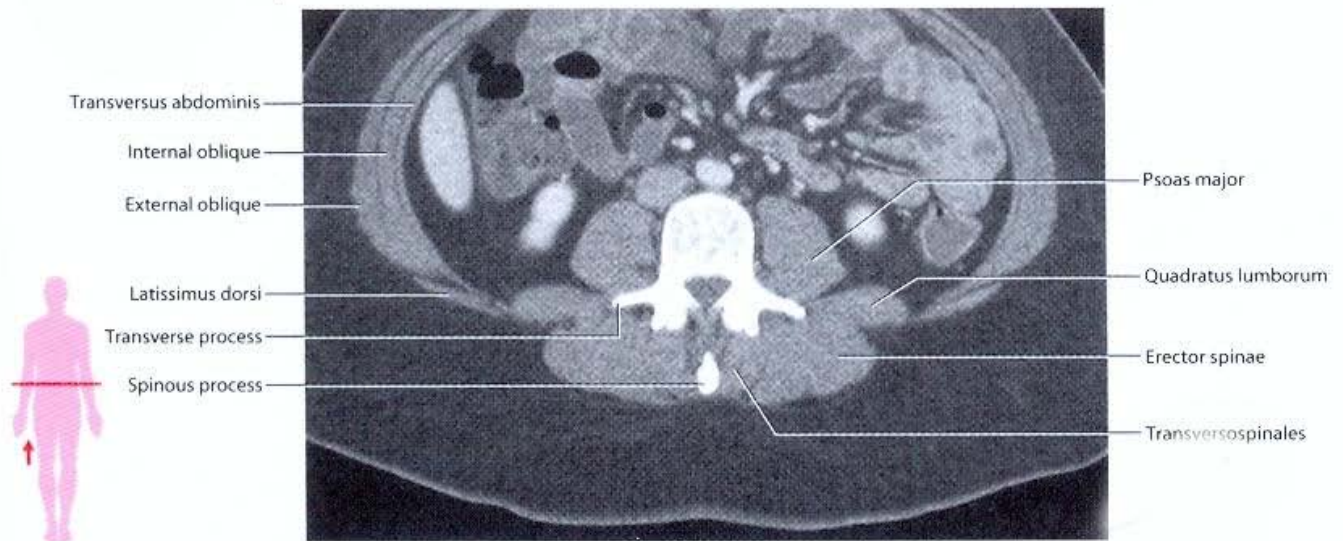


Deep group of back muscles – transversospinales and segmental muscles

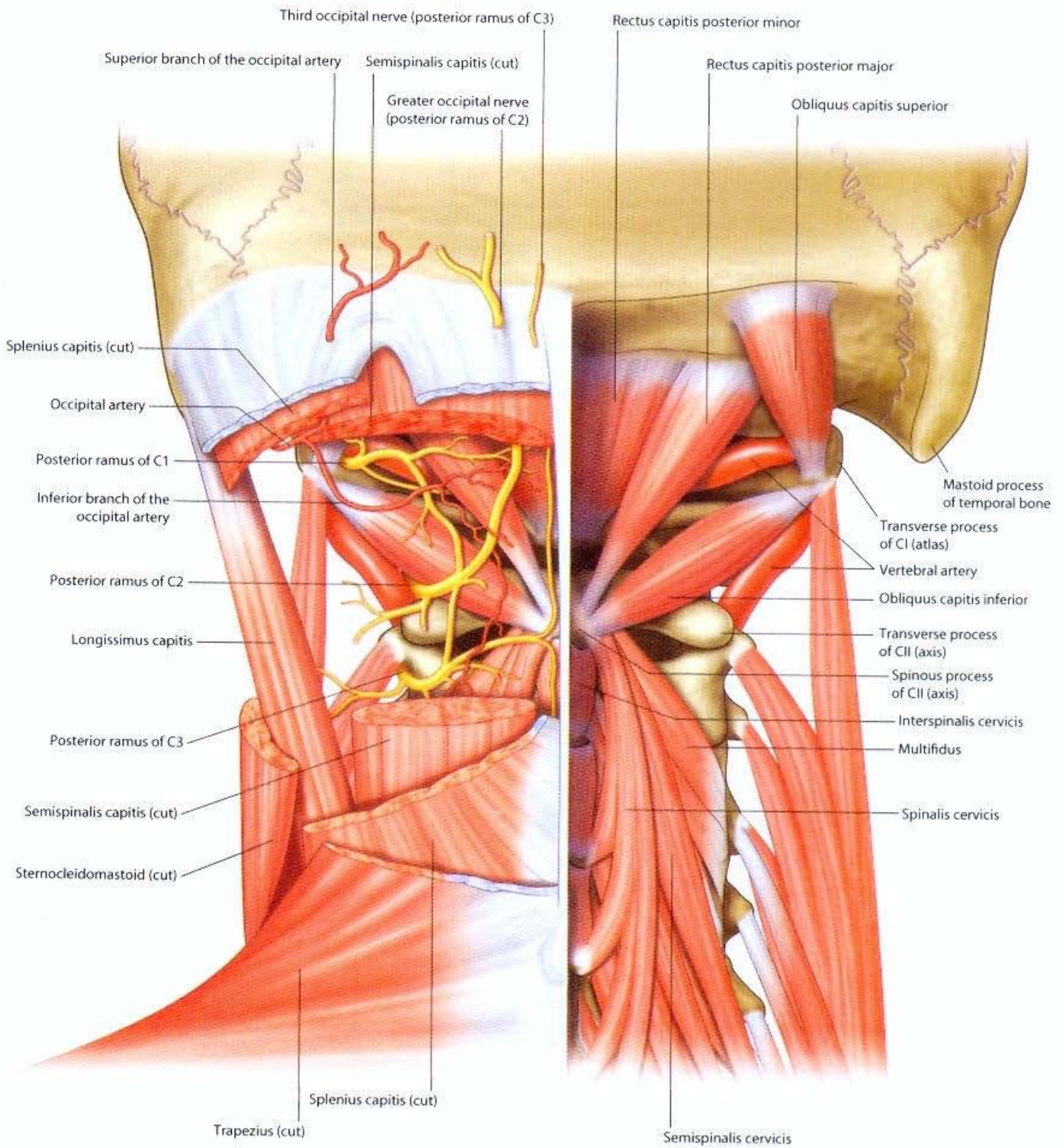




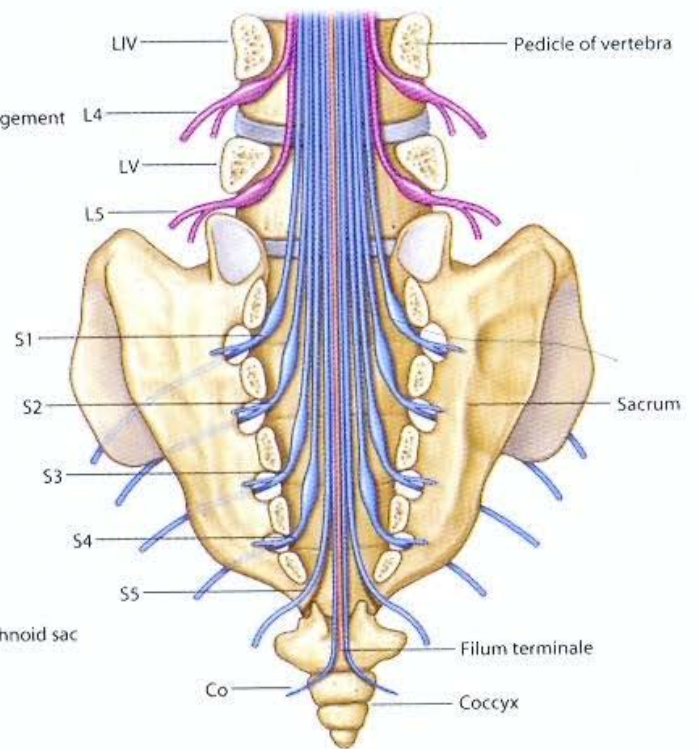
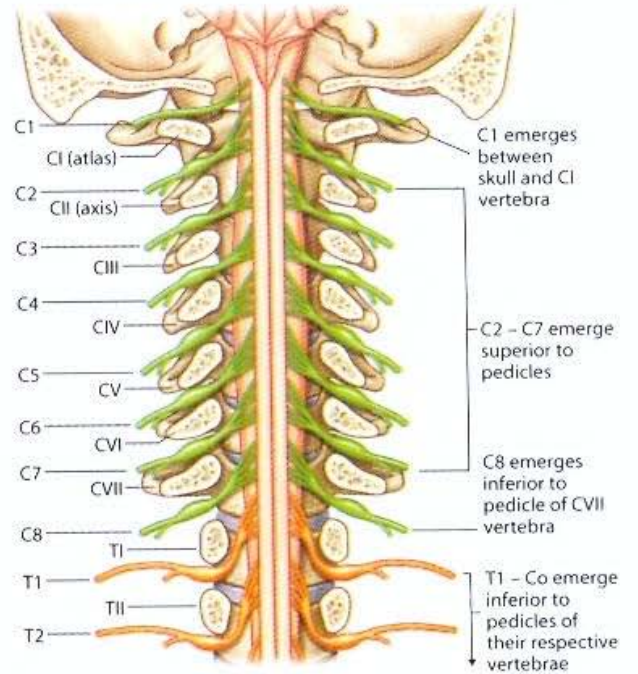
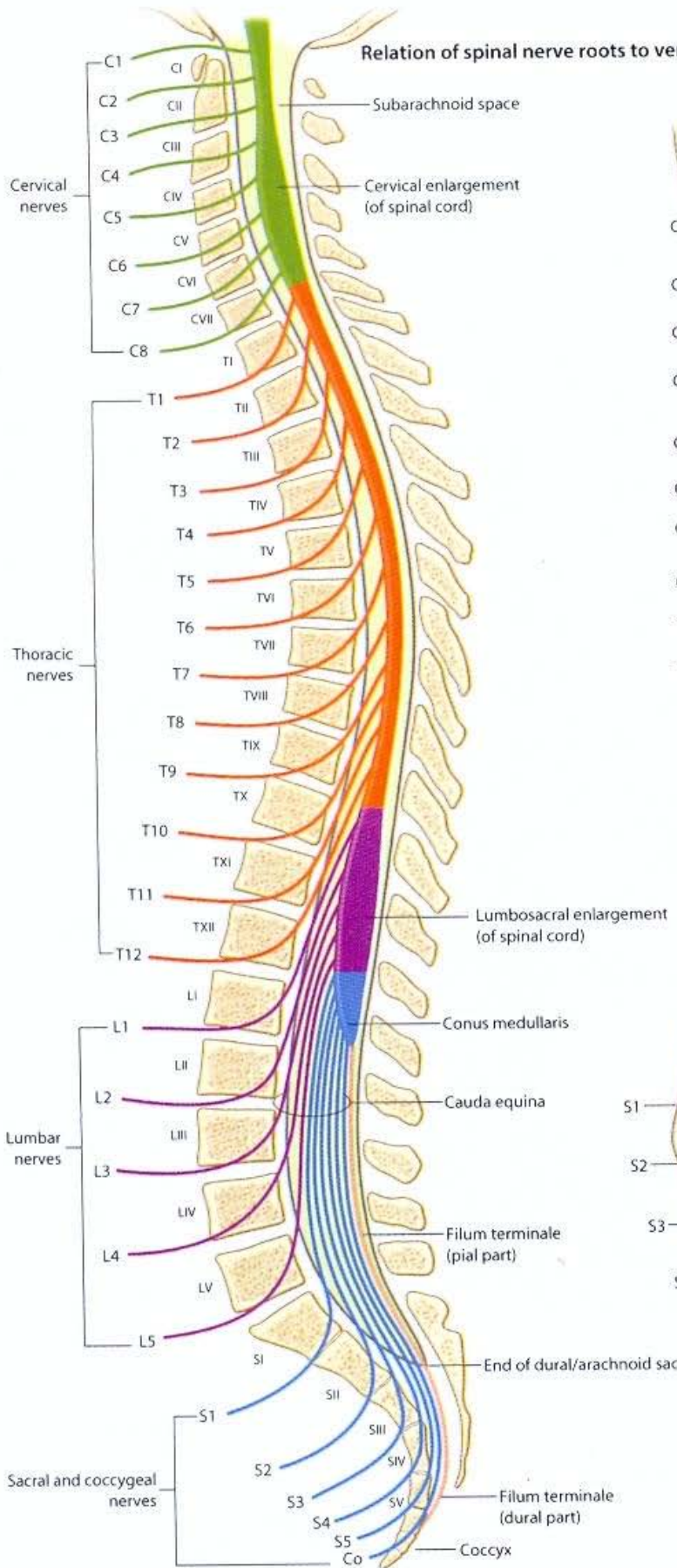
**Thoracolumbar fascia and the deep back muscles  
(transverse section – lumbar region)**



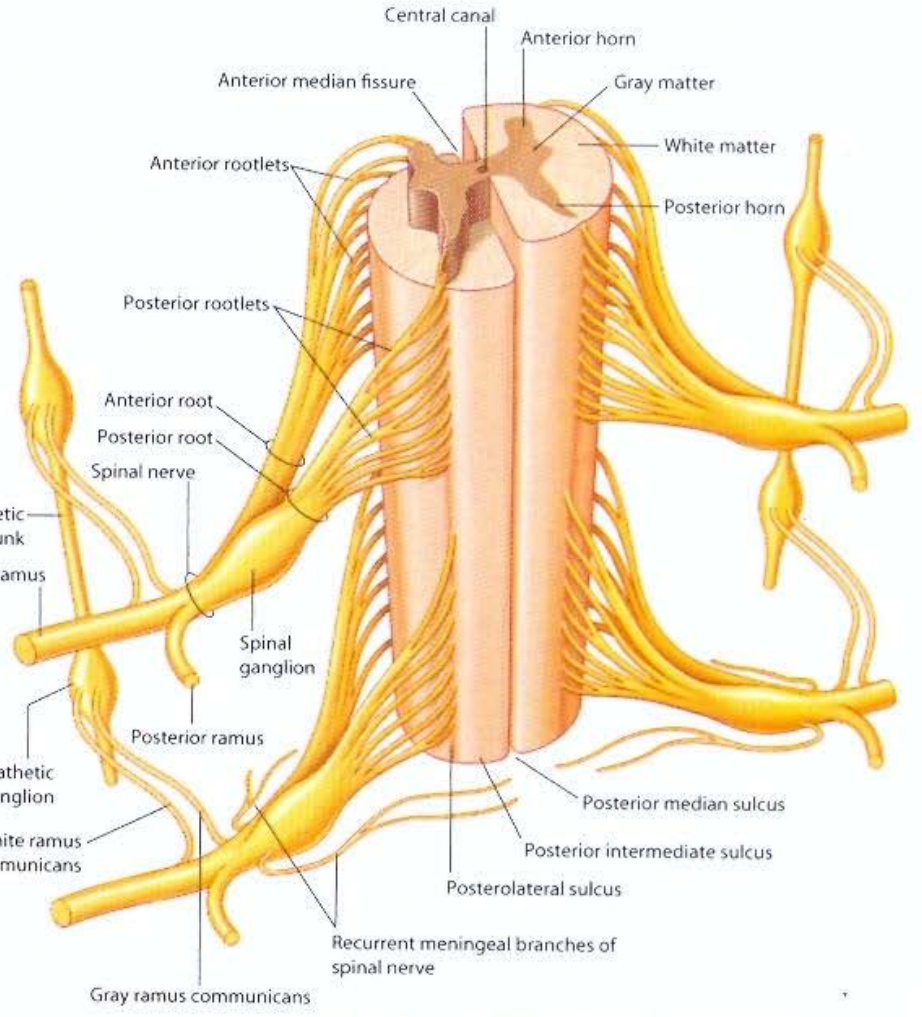
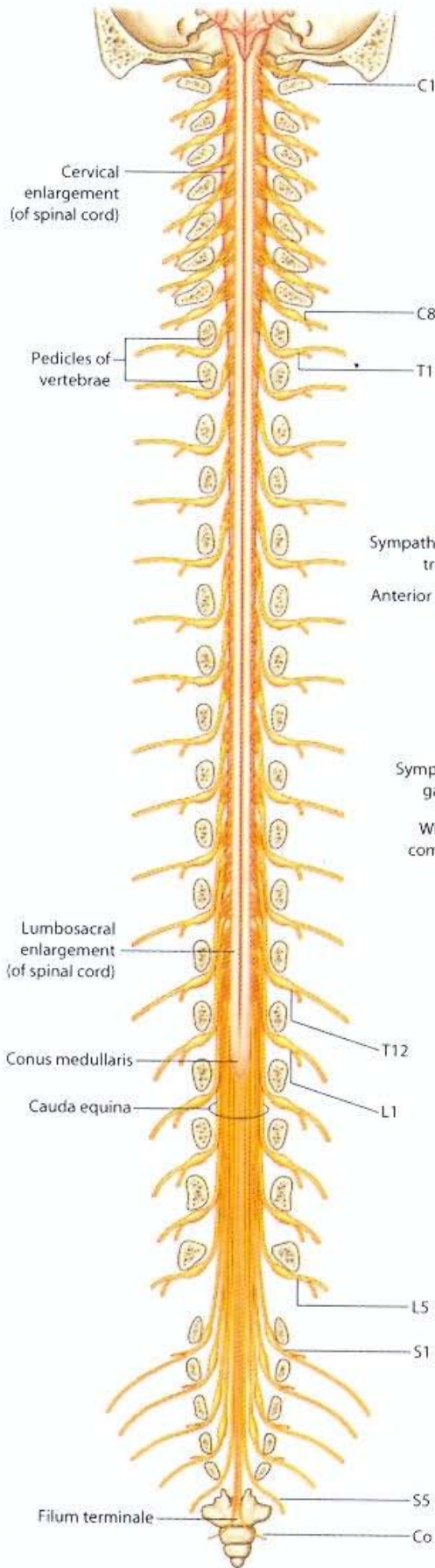
**Lumbar region (LIII) showing back musculature.  
CT image in axial plane**



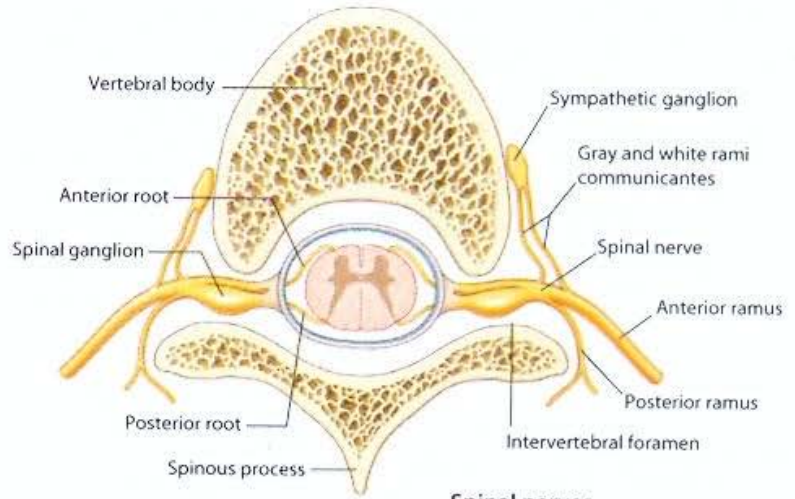
Suboccipital region



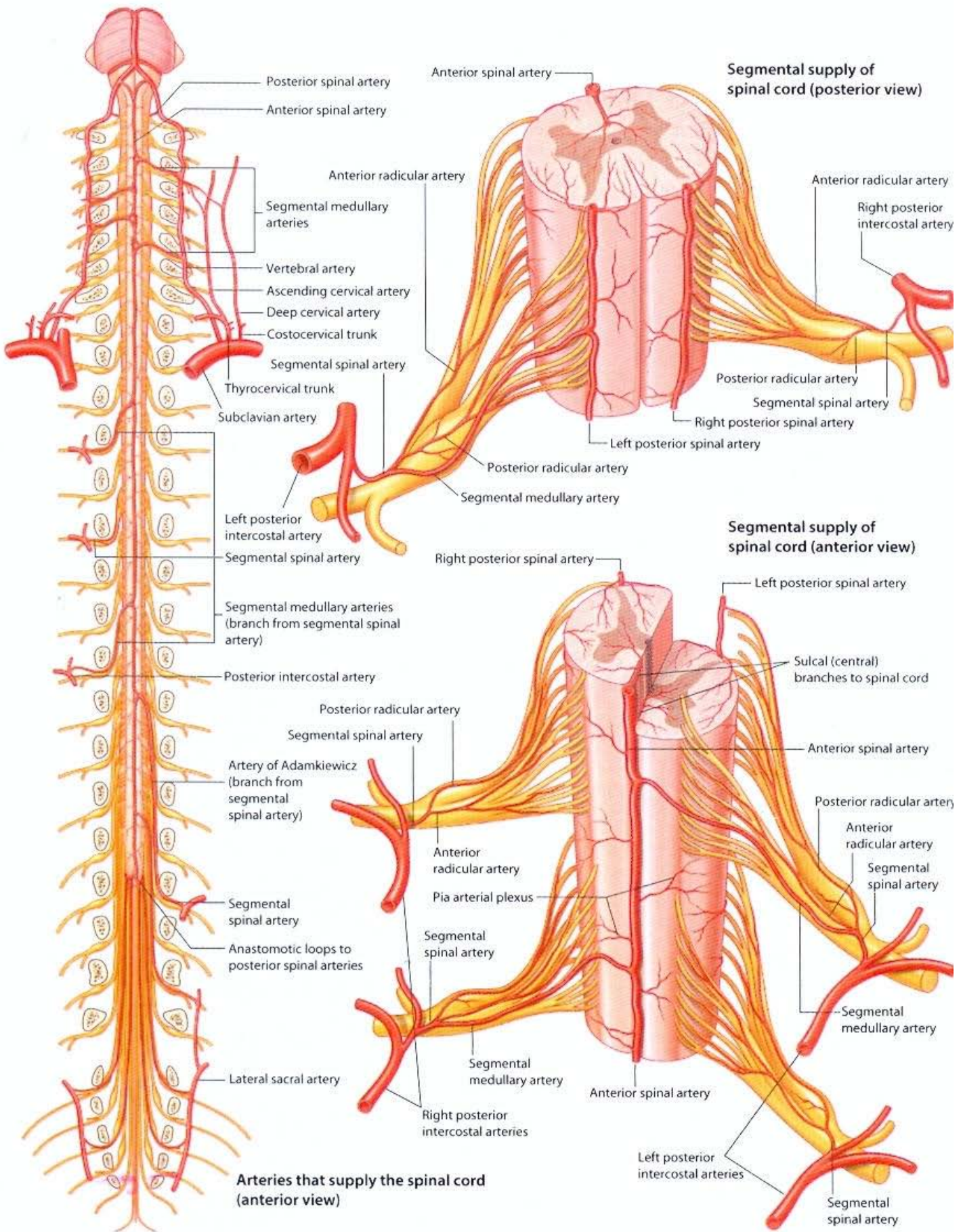
Spinal cord and spinal nerves in vertebral canal

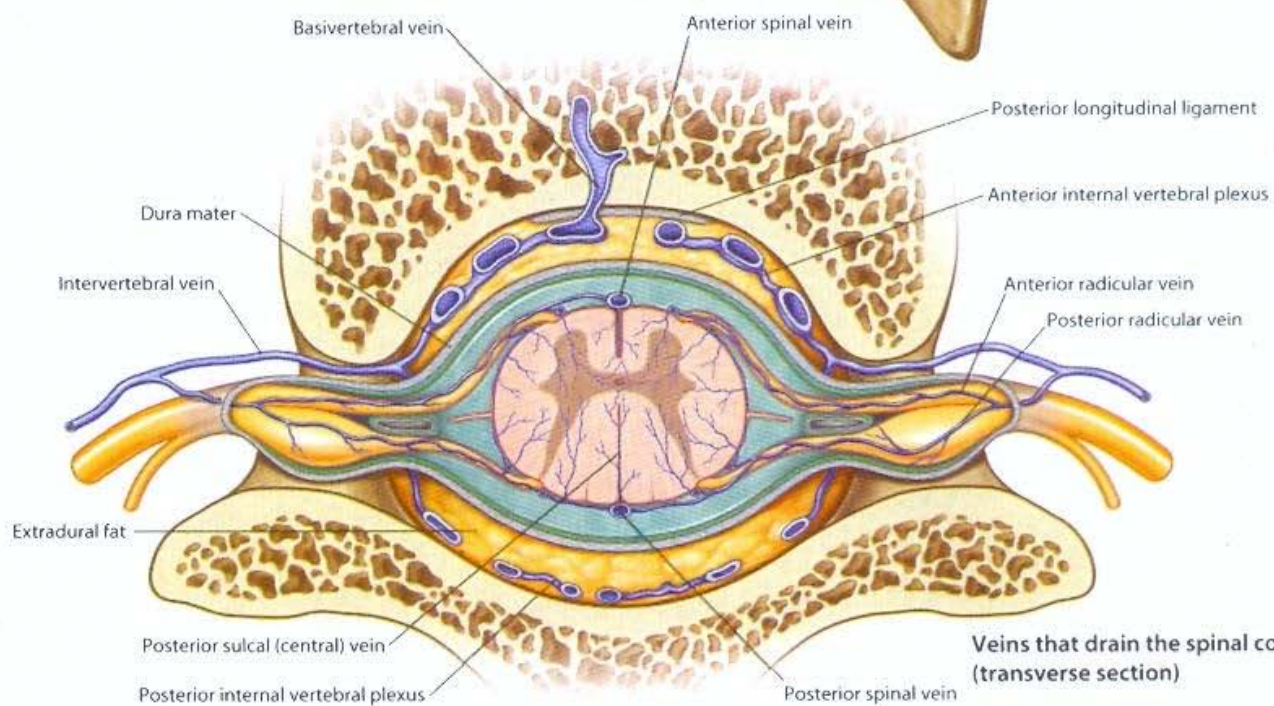
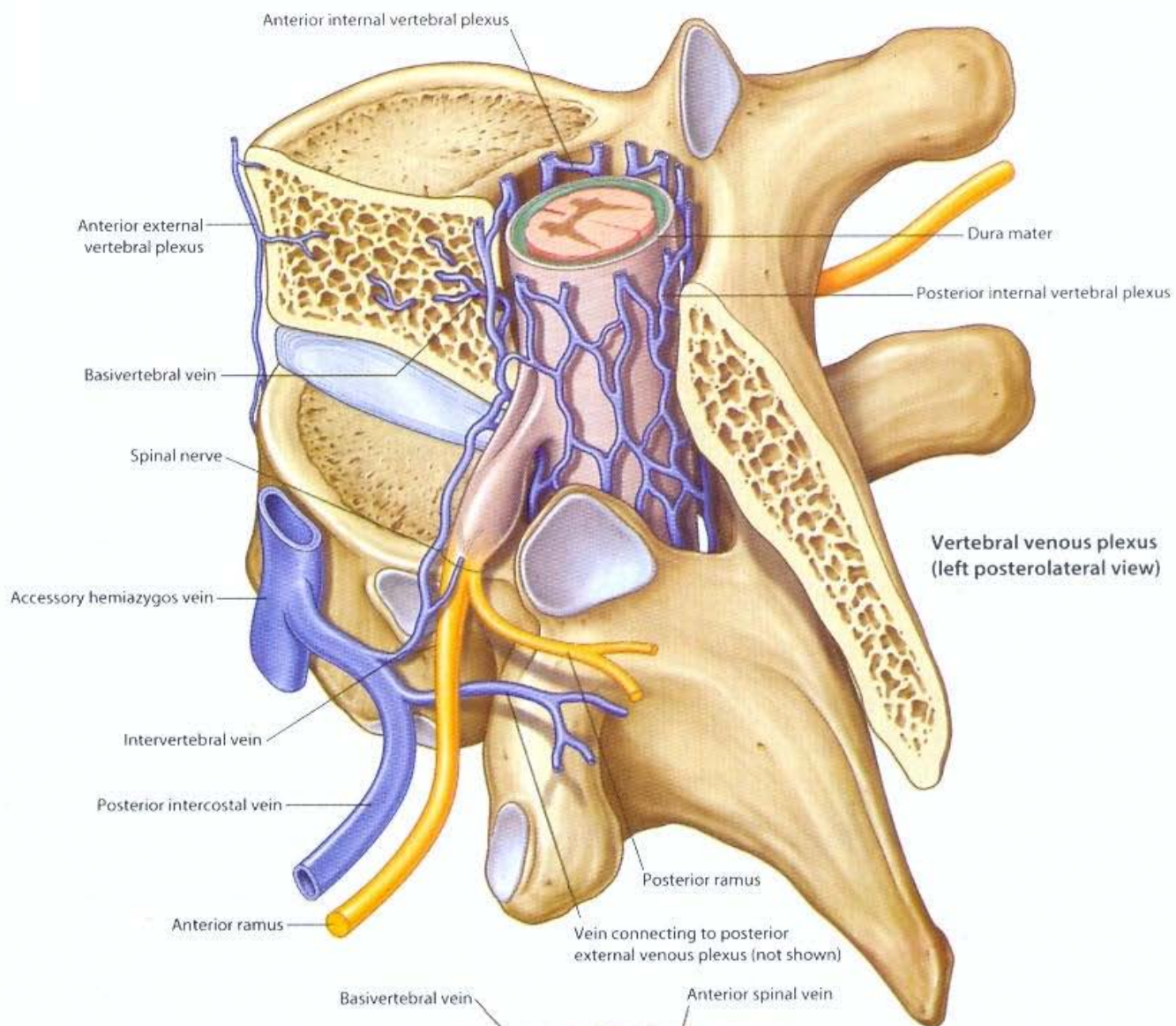


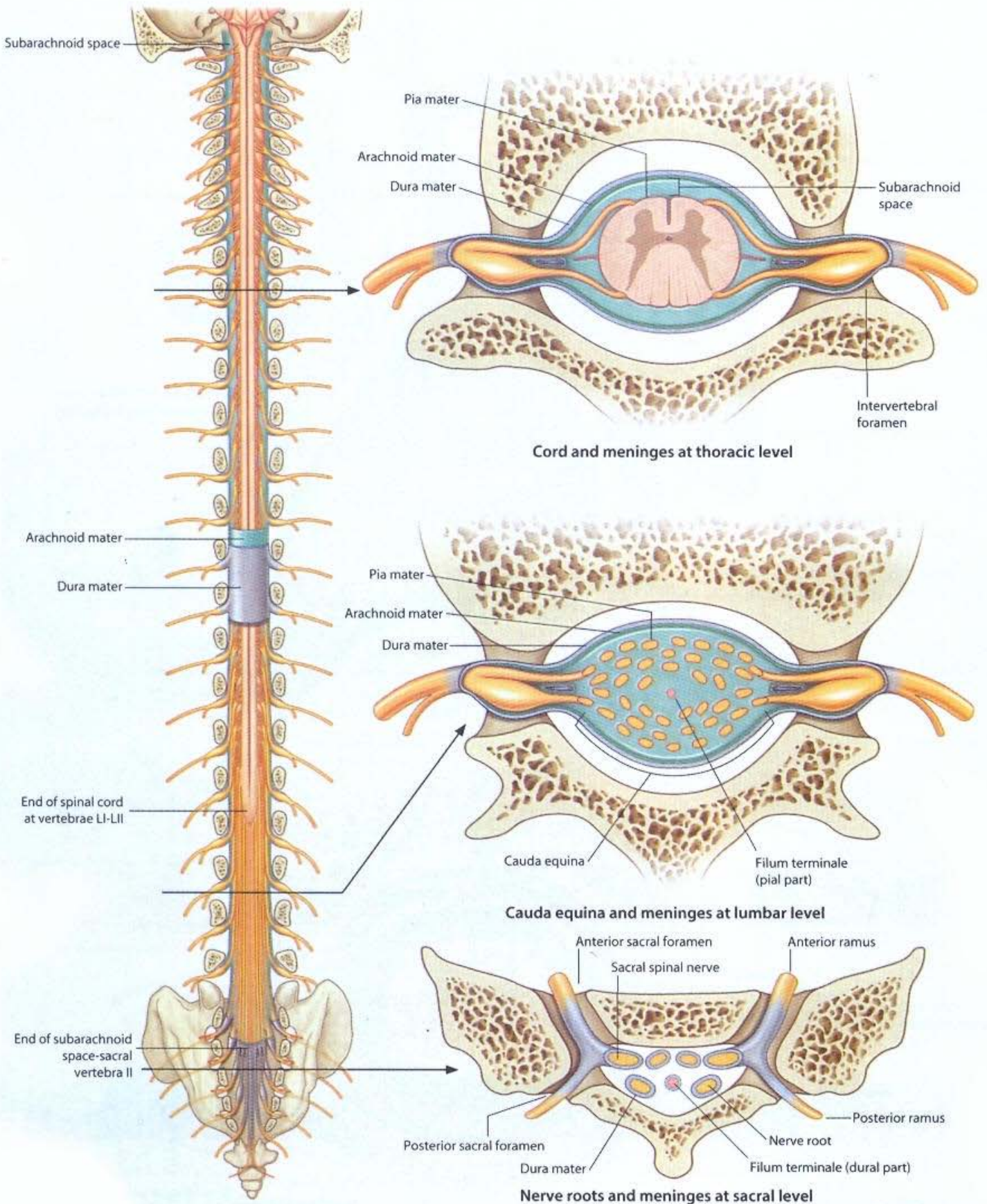
Features of the spinal cord (thoracic region) and basic organization of a spinal nerve (posterior view)

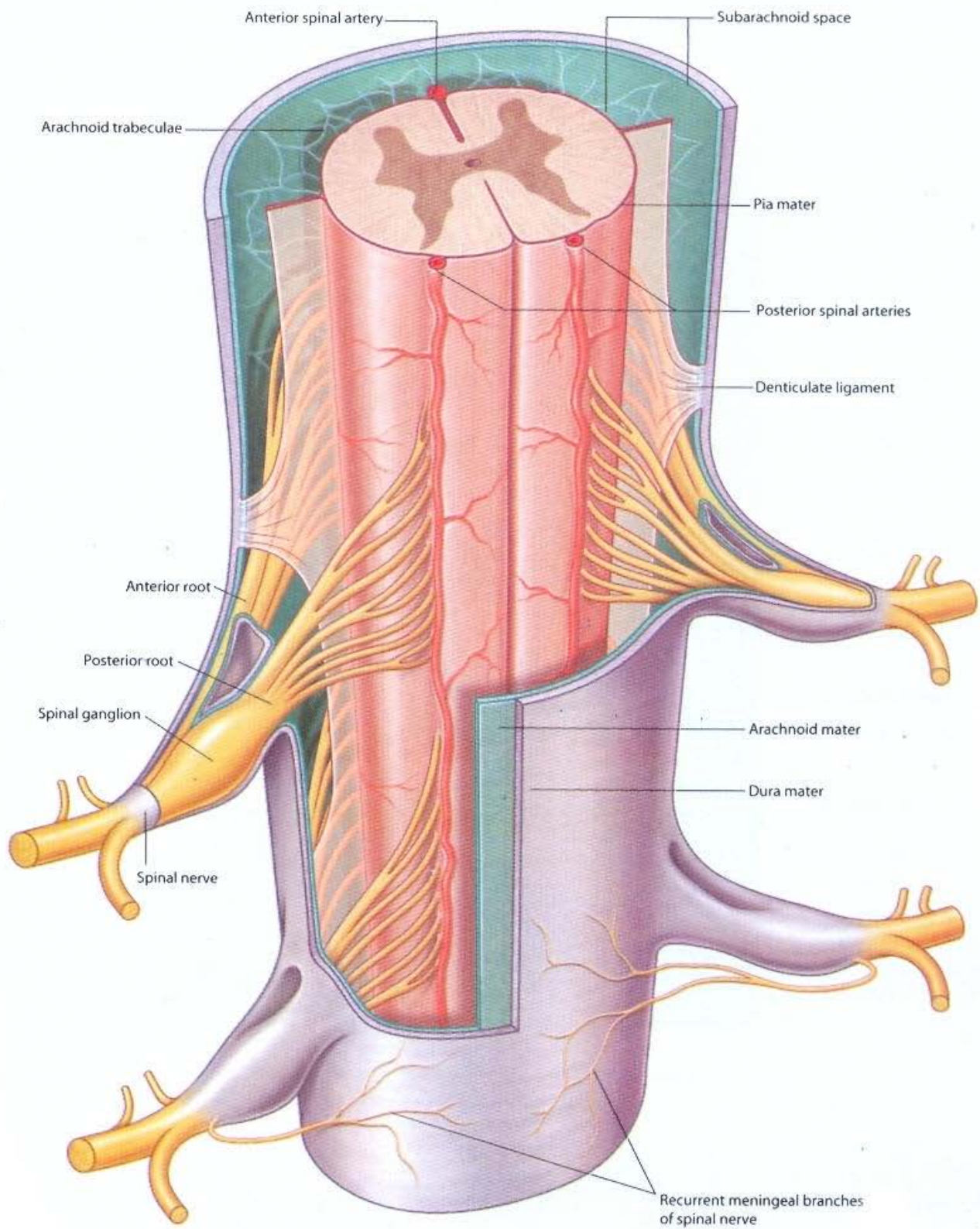


Spinal nerves (transverse section)



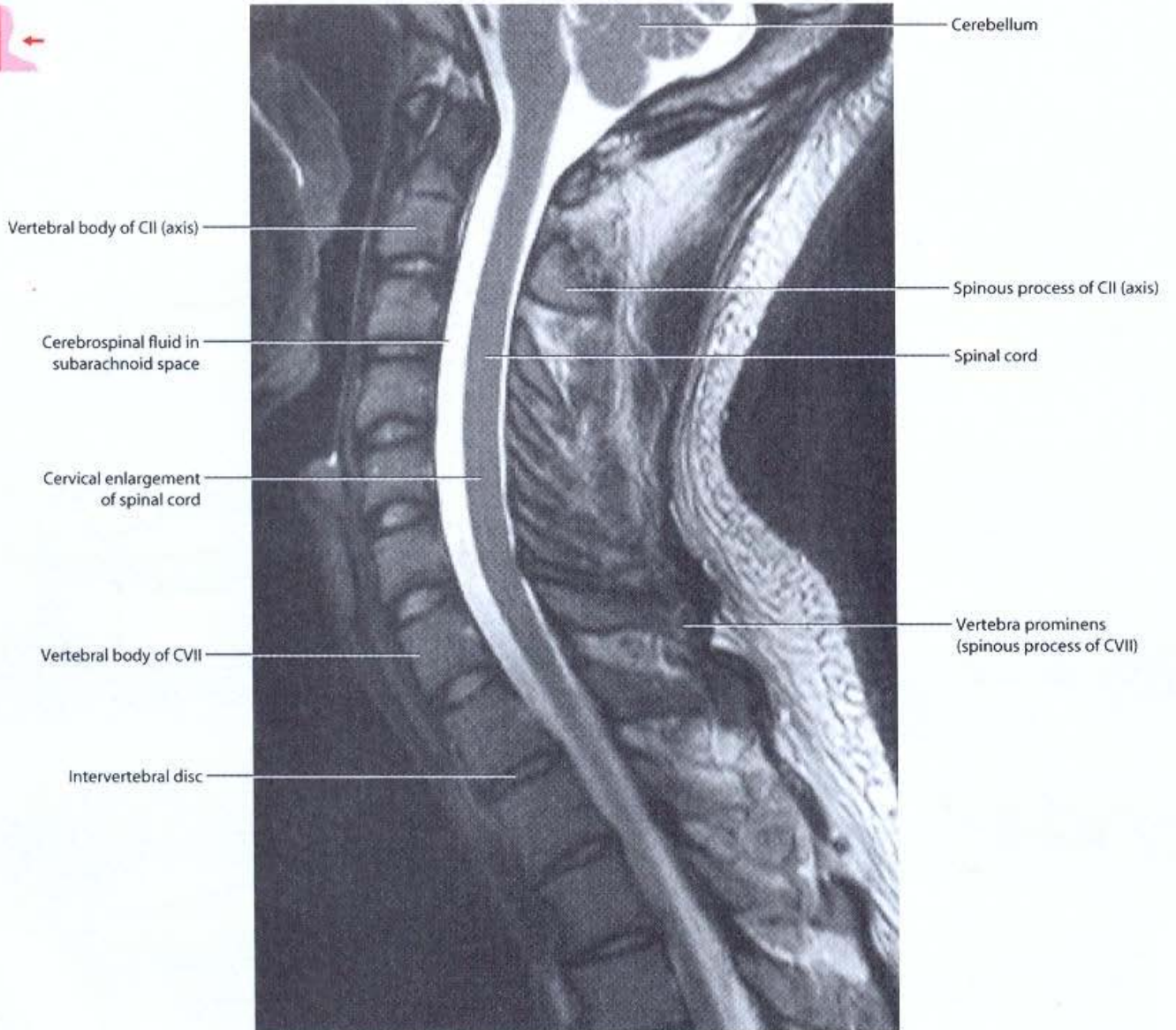
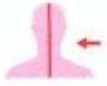




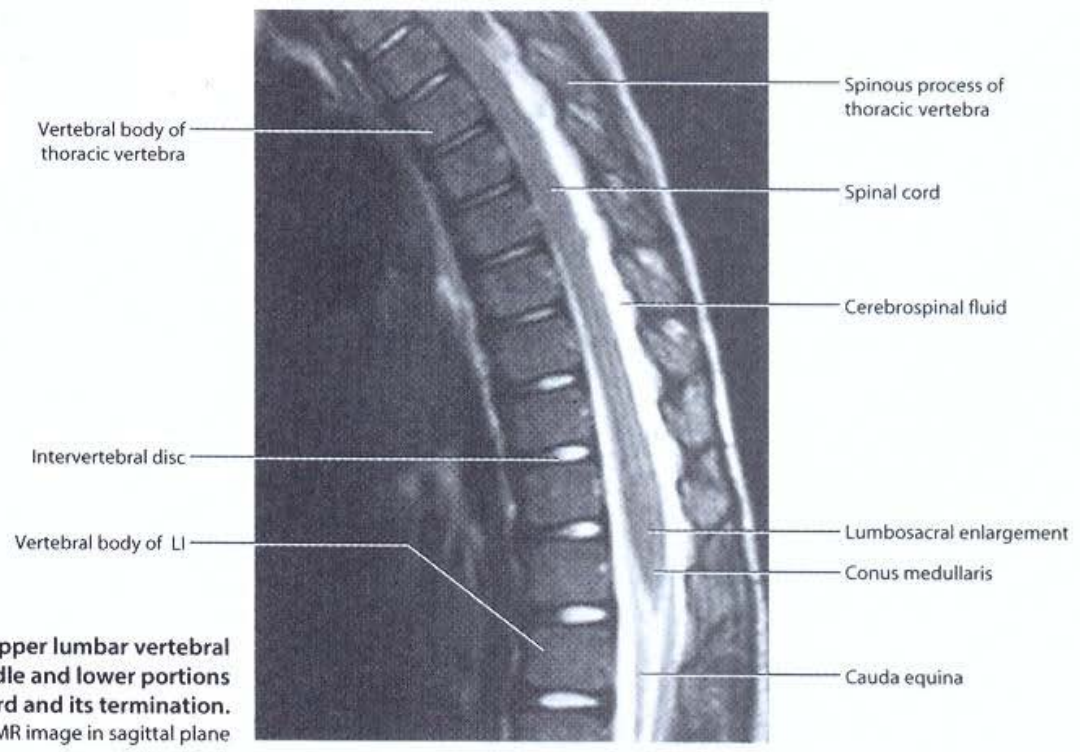
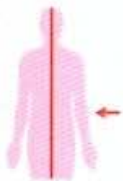


Meninges covering parts of the thoracic region of the spinal cord (posterior view)

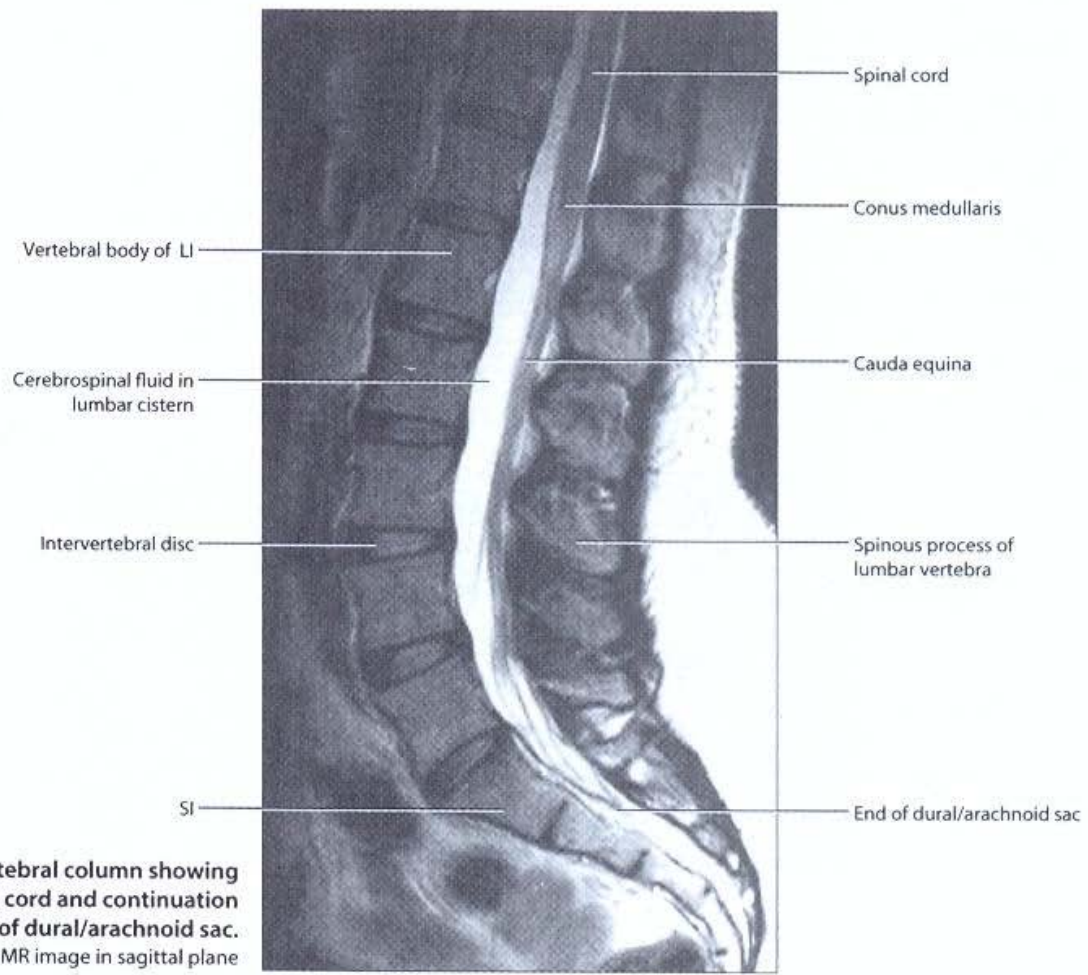




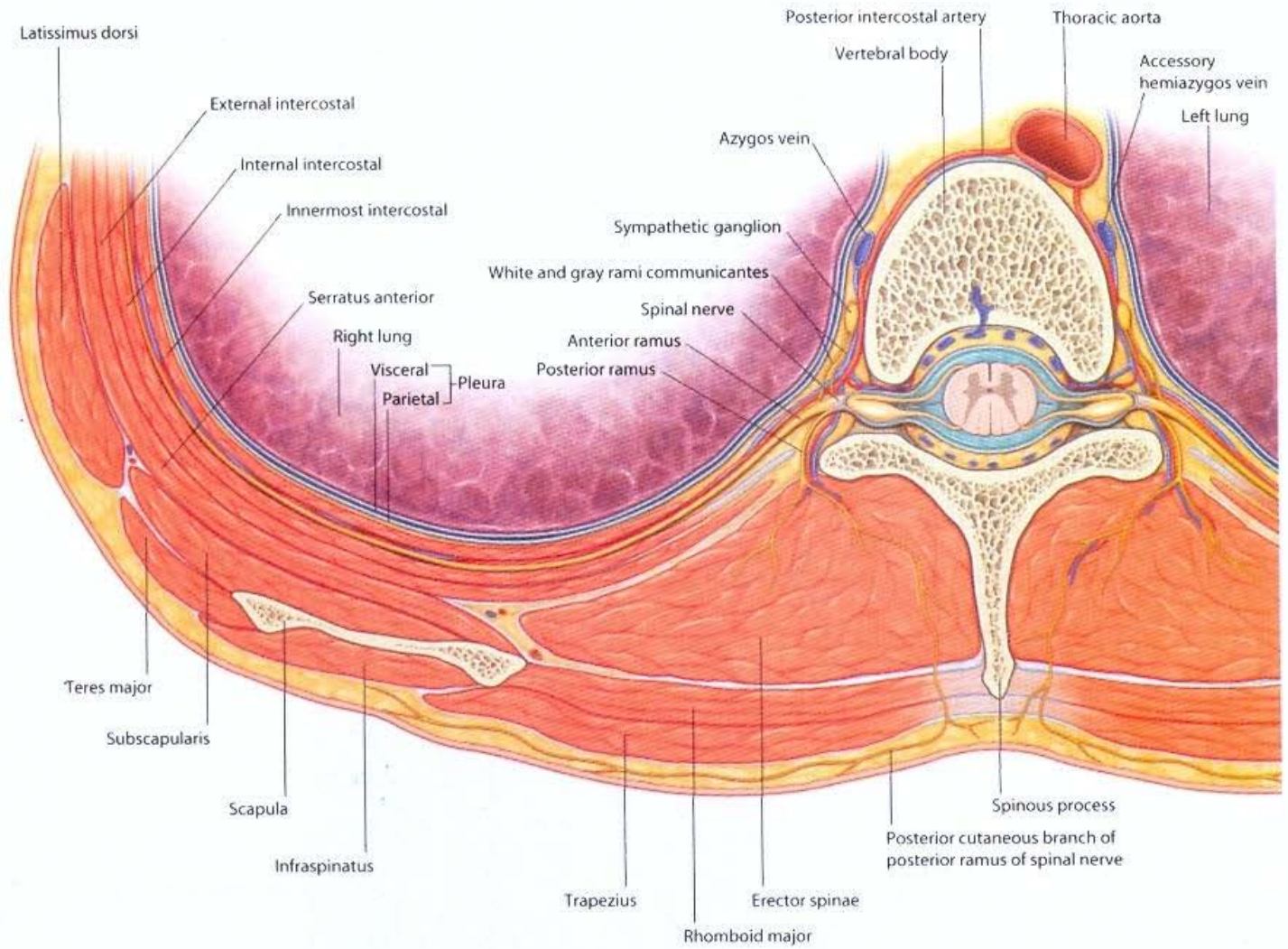
**Cervical and upper thoracic vertebral column showing upper and middle portions of spinal cord.**  
T2-weighted MR image in sagittal plane



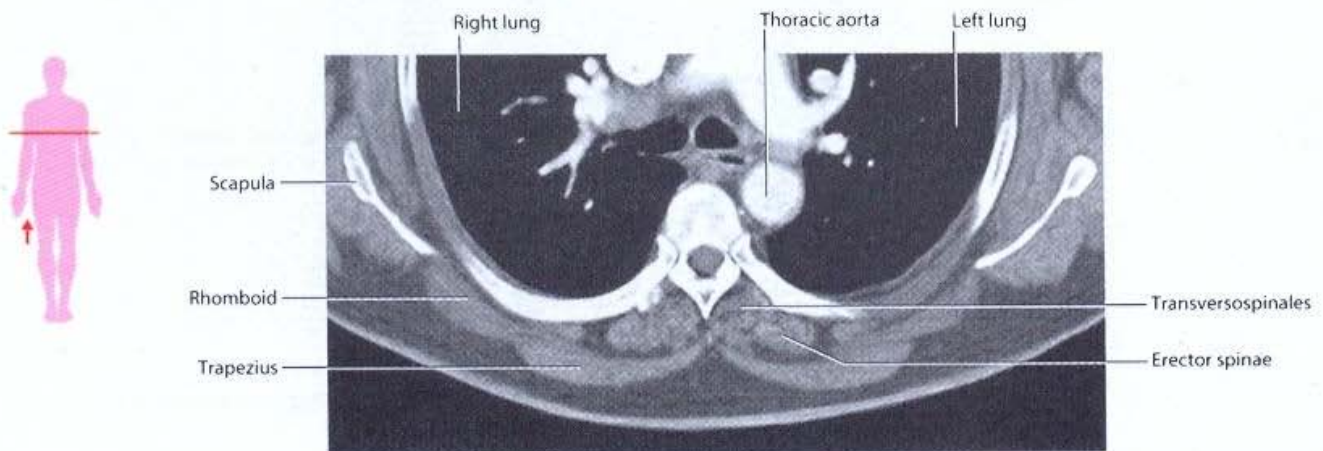
Thoracic and upper lumbar vertebral column showing middle and lower portions of spinal cord and its termination. T2-weighted MR image in sagittal plane



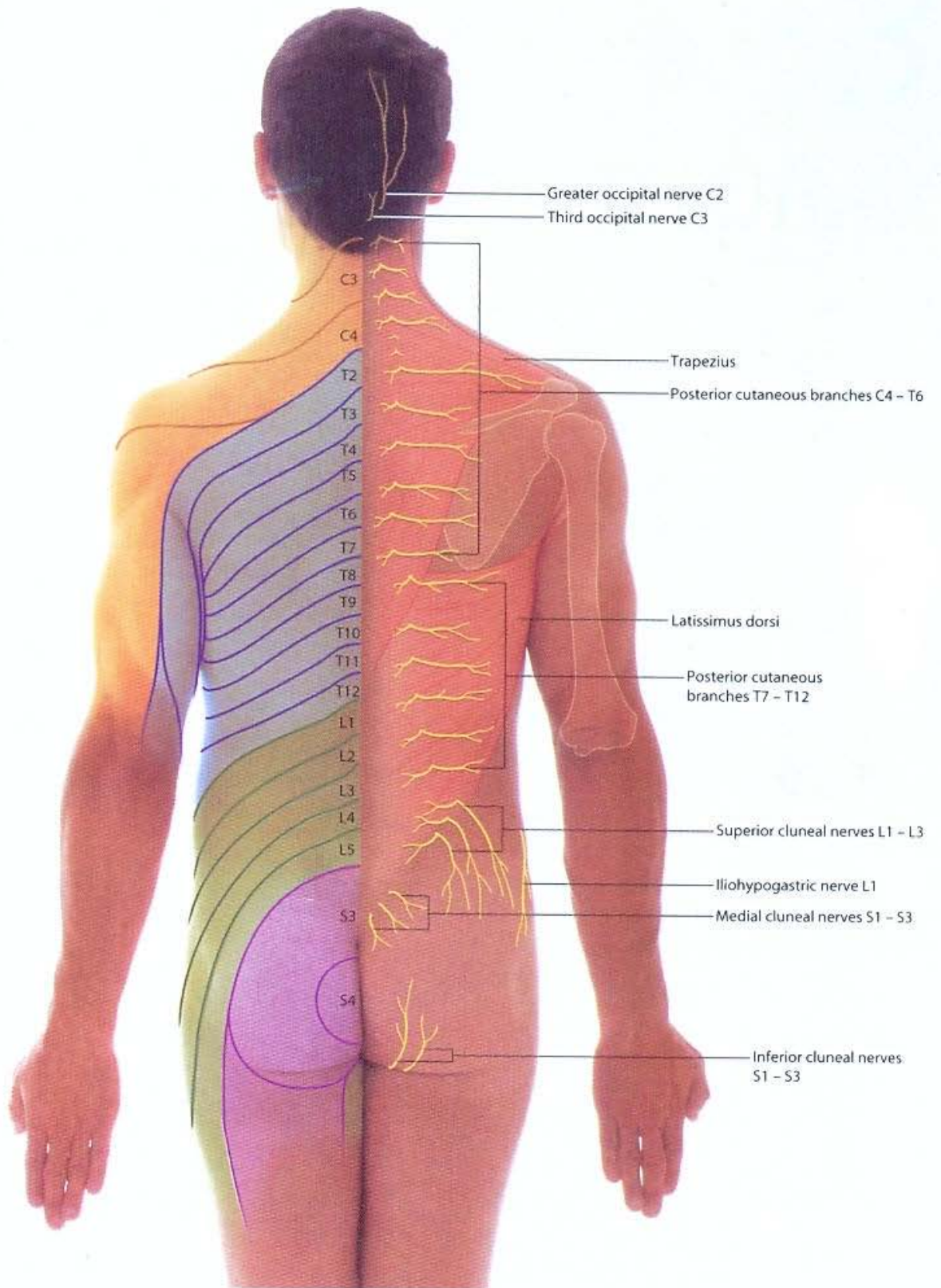
Lumbar and sacral vertebral column showing termination of spinal cord and continuation and termination of dural/arachnoid sac. T2-weighted MR image in sagittal plane



**Transverse section through thoracic region of vertebral column**



**Thoracic region of back.**  
CT image in axial plane



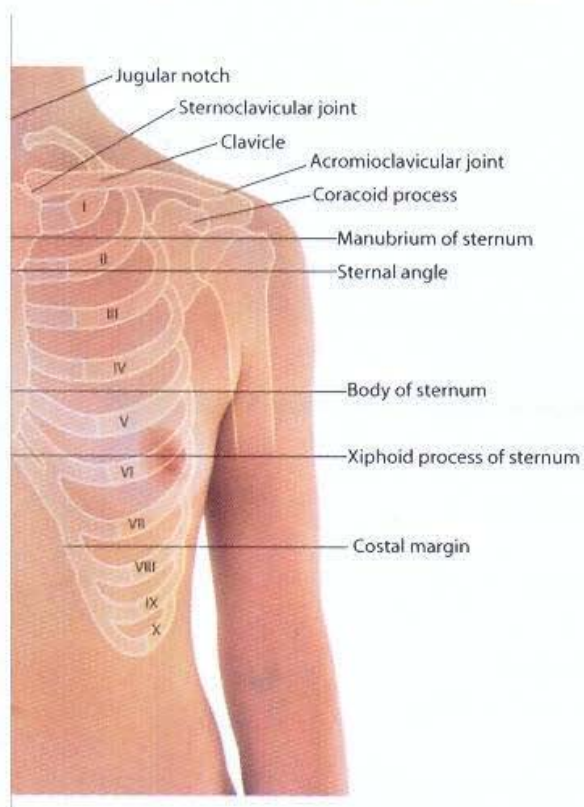
Dermatomes and cutaneous nerves of the back

## 3

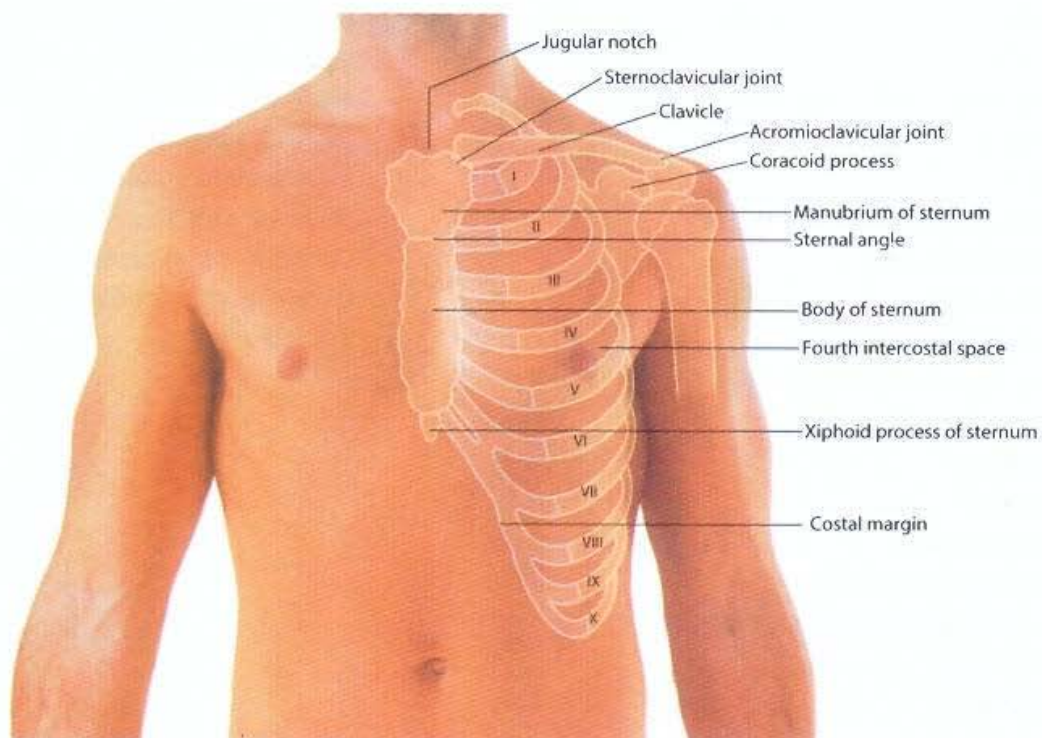
## THORAX

## CONTENTS

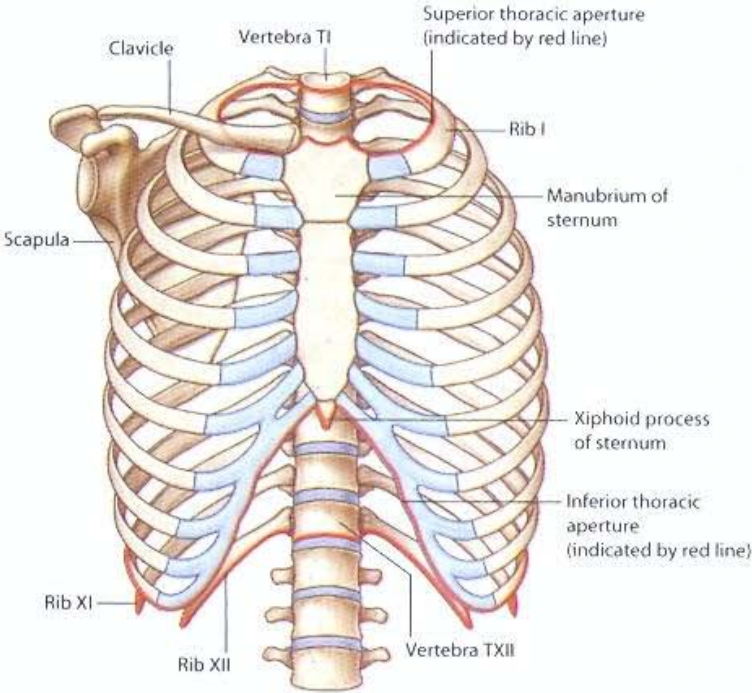
<i>Surface anatomy with bones</i>	56	<i>Cardiac chambers and heart valves</i>	95
<i>Bony framework</i>	57	<i>Coronary vessels</i>	96
<i>Ribs</i>	59	<i>Coronary arteries and variations</i>	97
<i>Articulations</i>	60	<i>Cardiac conduction system</i>	99
<i>Breast</i>	62	<i>Auscultation points and heart sounds</i>	100
<i>Pectoral region</i>	64	<i>Cardiac innervation</i>	101
<i>Thoracic wall muscles</i>	66	<i>Superior mediastinum: thymus</i>	102
<i>Diaphragm</i>	67	<i>Superior mediastinum: veins and arteries</i>	103
<i>Arteries of the thoracic wall</i>	68	<i>Superior mediastinum: arteries and nerves</i>	104
<i>Veins of the thoracic wall</i>	69	<i>Superior mediastinum: imaging</i>	105
<i>Nerves of the thoracic wall</i>	70	<i>Superior mediastinum: veins and trachea</i>	106
<i>Lymphatics of the thoracic wall</i>	71	<i>Mediastinum: imaging</i>	107
<i>Intercostal nerves and arteries</i>	72	<i>Mediastinum: view from right</i>	108
<i>Pleural cavities and mediastinum</i>	73	<i>Mediastinum: imaging – view from right</i>	109
<i>Parietal pleura</i>	74	<i>Mediastinum: view from left</i>	110
<i>Surface projections of pleural recesses</i>	75	<i>Mediastinum: imaging – view from left</i>	111
<i>Right lung</i>	76	<i>Posterior mediastinum</i>	112
<i>Left lung</i>	77	<i>Mediastinum: imaging</i>	114
<i>Lung lobes: surface relationship</i>	78	<i>Transverse section: TVIII level</i>	118
<i>Lung lobes: imaging</i>	79	<i>Dermatomes and cutaneous nerves</i>	119
<i>Bronchial tree</i>	80	<i>Visceral efferent (motor) innervation of the heart</i>	120
<i>Bronchopulmonary segments</i>	81	<i>Visceral afferents</i>	121
<i>Pulmonary vessels and plexus</i>	82		
<i>Pulmonary vessels: imaging</i>	83		
<i>Mediastinum</i>	85		
<i>Pericardium</i>	86		
<i>Pericardial layers</i>	87		
<i>Anterior surface of heart</i>	88		
<i>Base and diaphragmatic surface of heart</i>	89		
<i>Right atrium</i>	90		
<i>Right ventricle</i>	91		
<i>Left atrium</i>	92		
<i>Left ventricle</i>	93		
<i>Aortic valve and cardiac skeleton</i>	94		



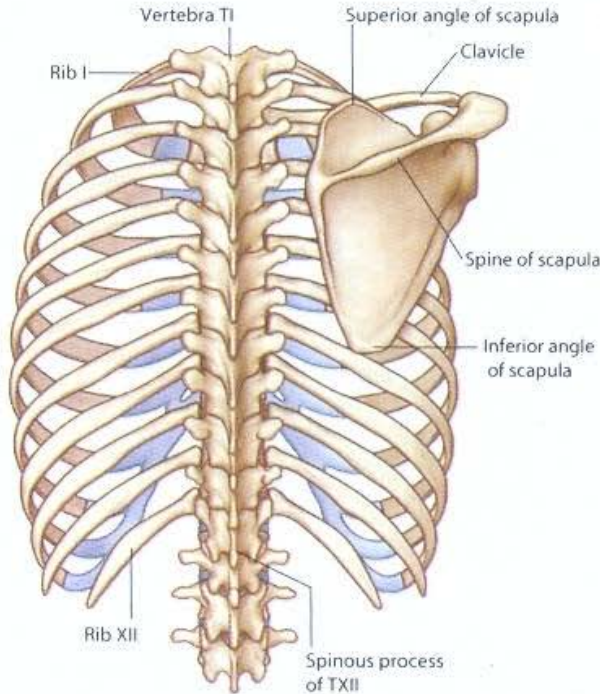
Anterior chest wall in a woman



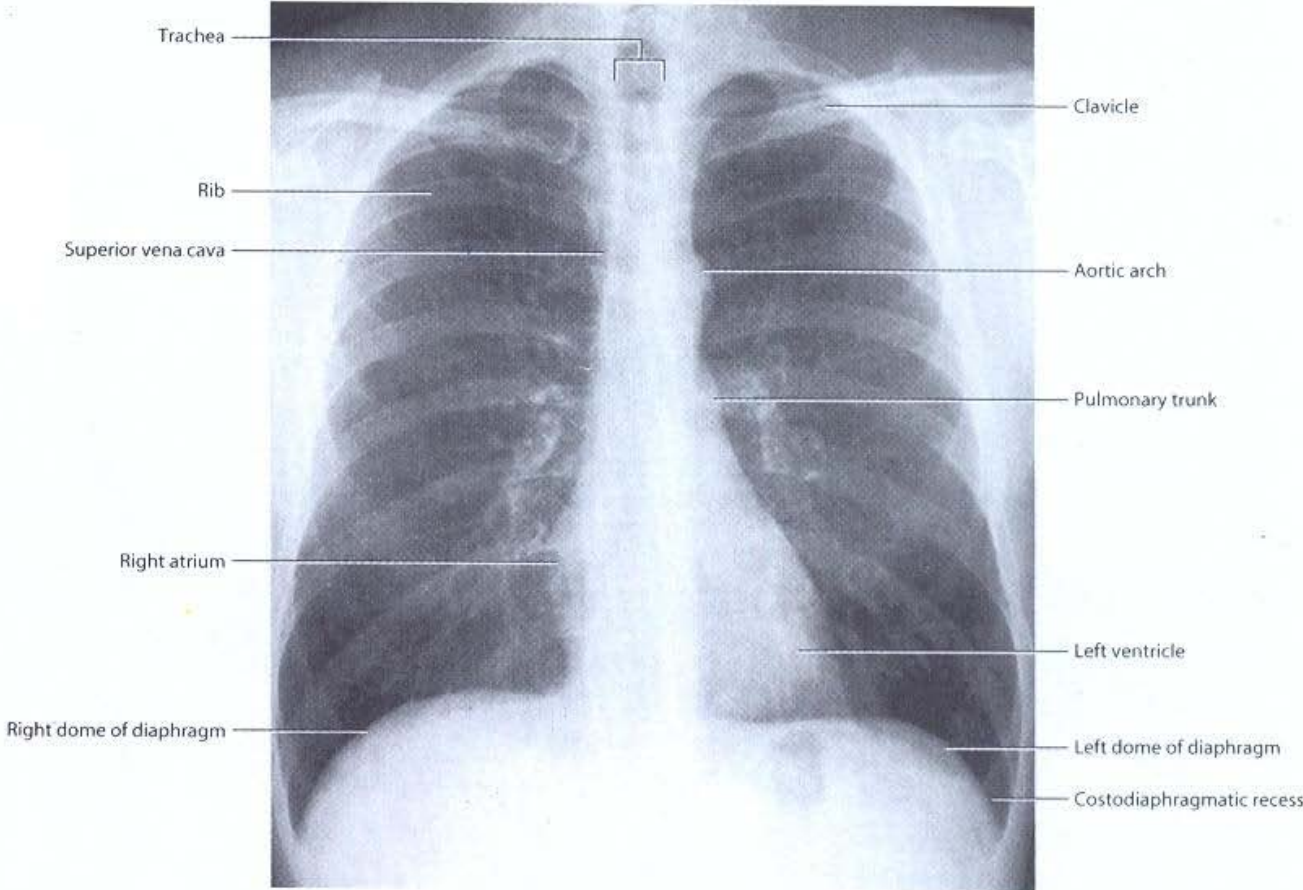
Anterior chest wall in a man



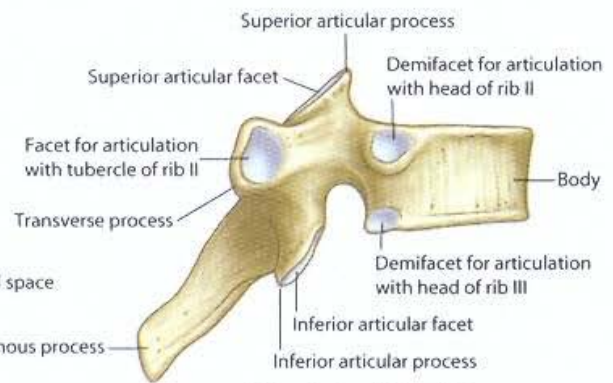
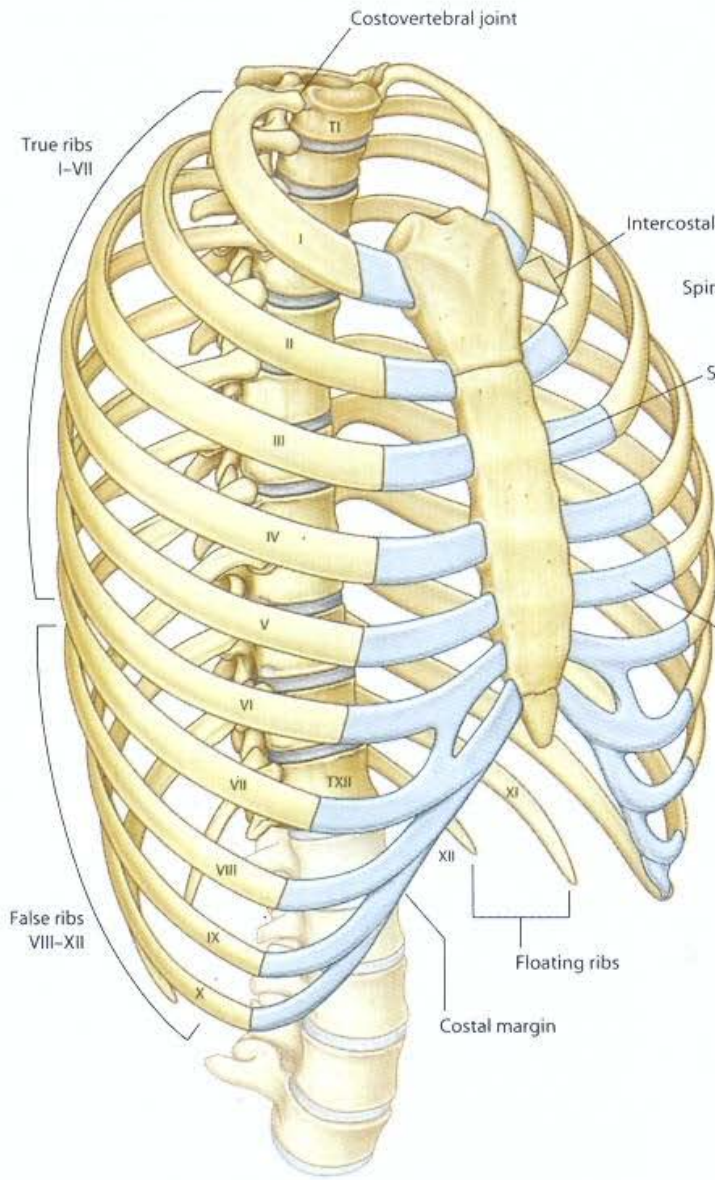
Bony framework of thorax (anterior view)



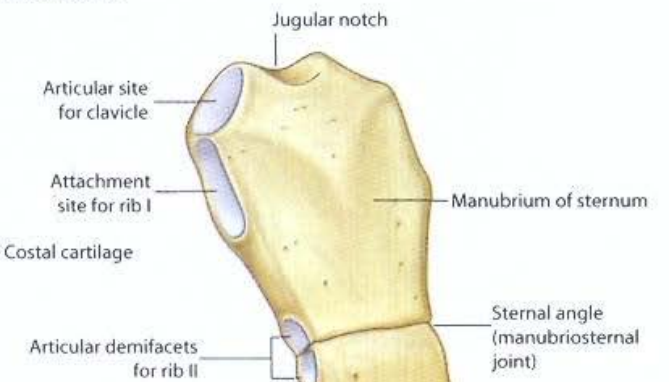
Bony framework of thorax (posterior view)



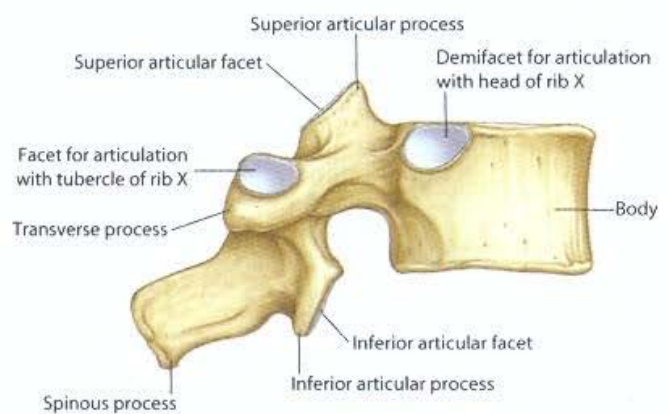
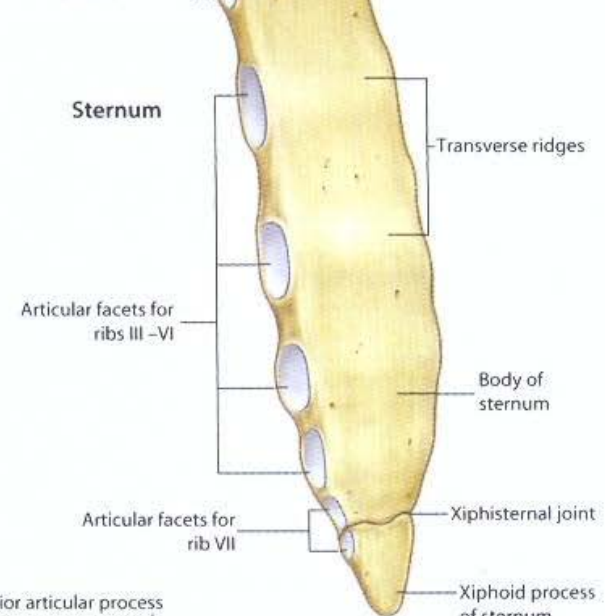
Positioning of structures in chest. Radiograph, AP view



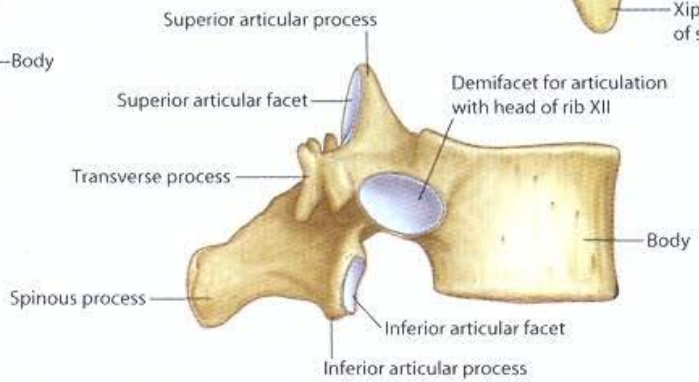
**TII vertebra lateral view**



**Sternum**

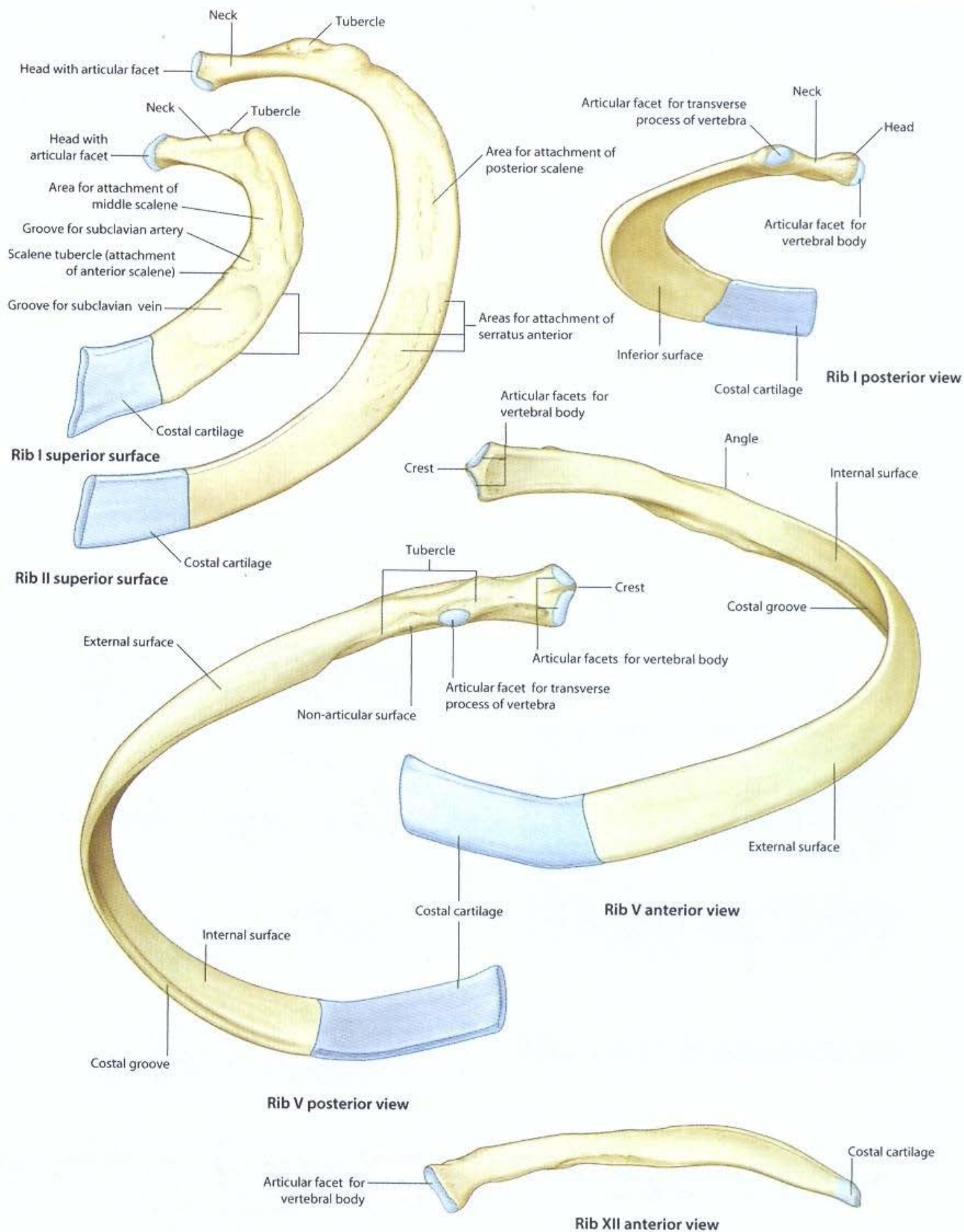


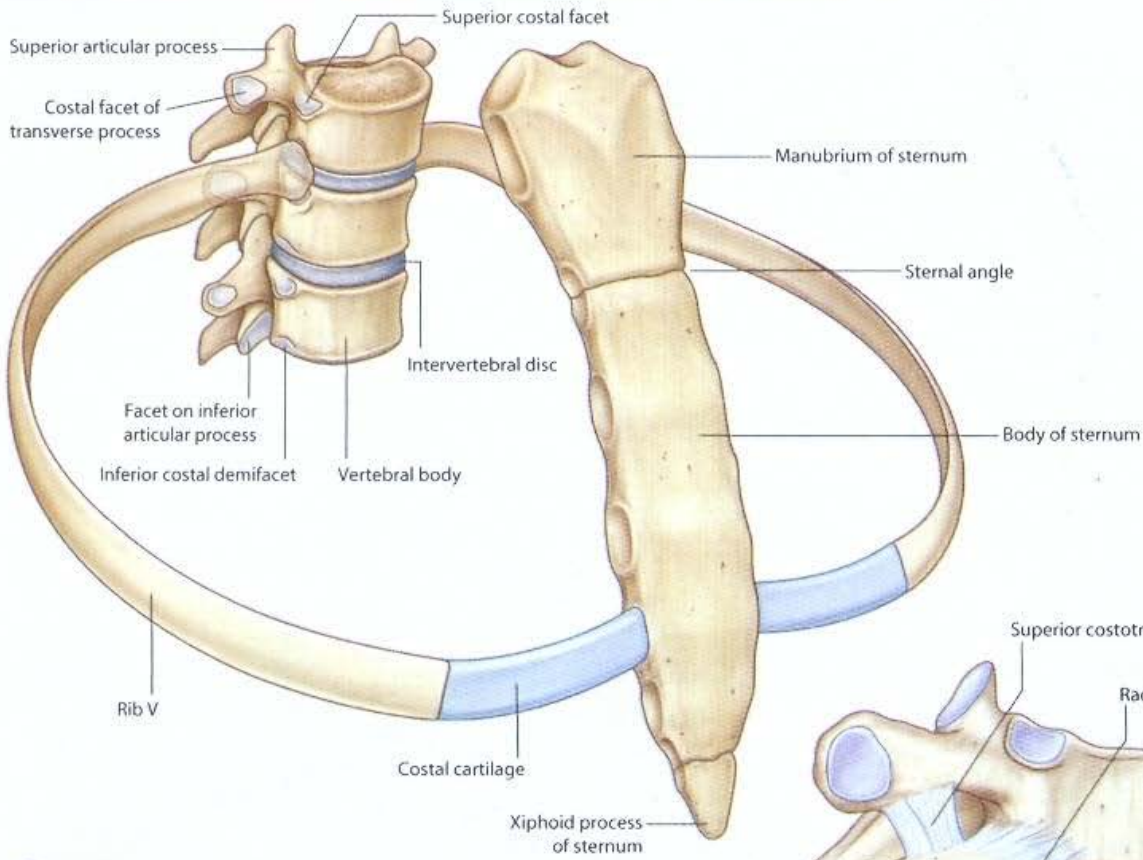
**TX vertebra lateral view**



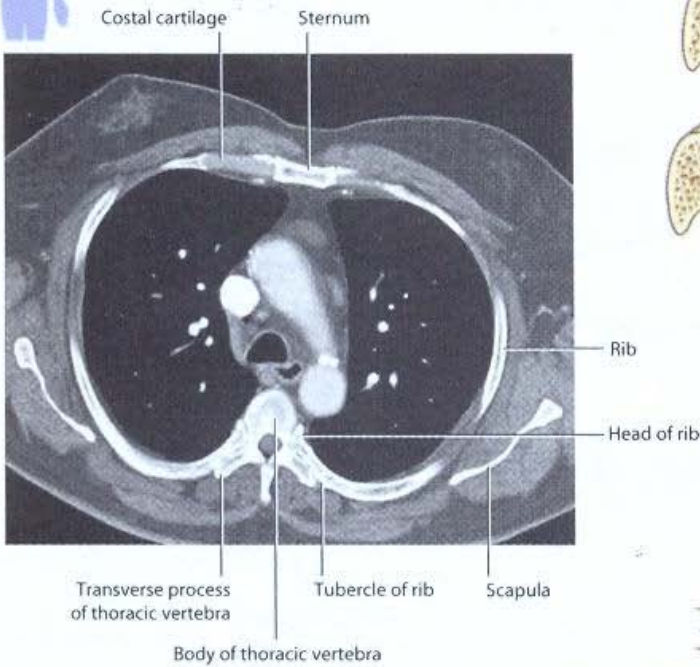
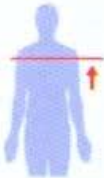
**TXII vertebra lateral view**



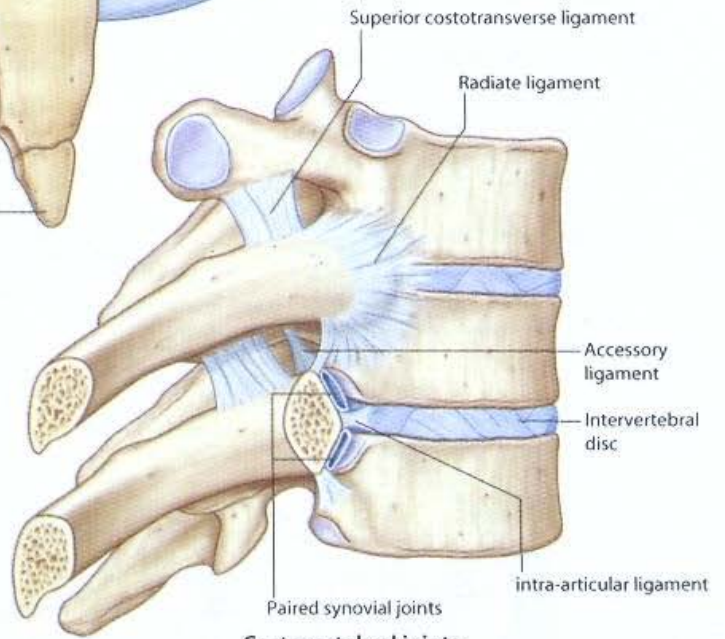




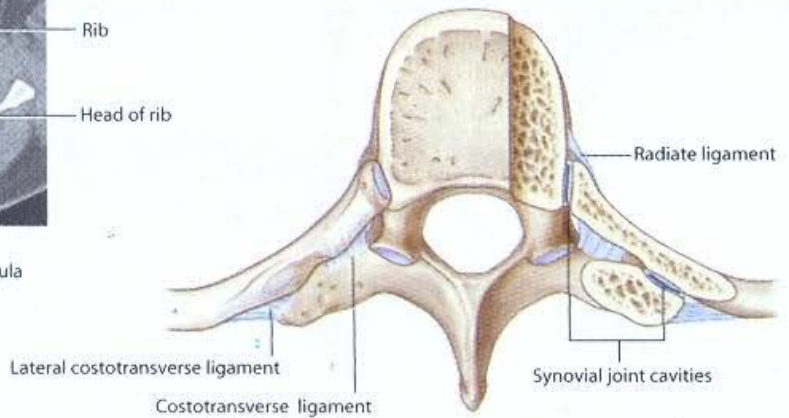
**Costovertebral and sternocostal joints**



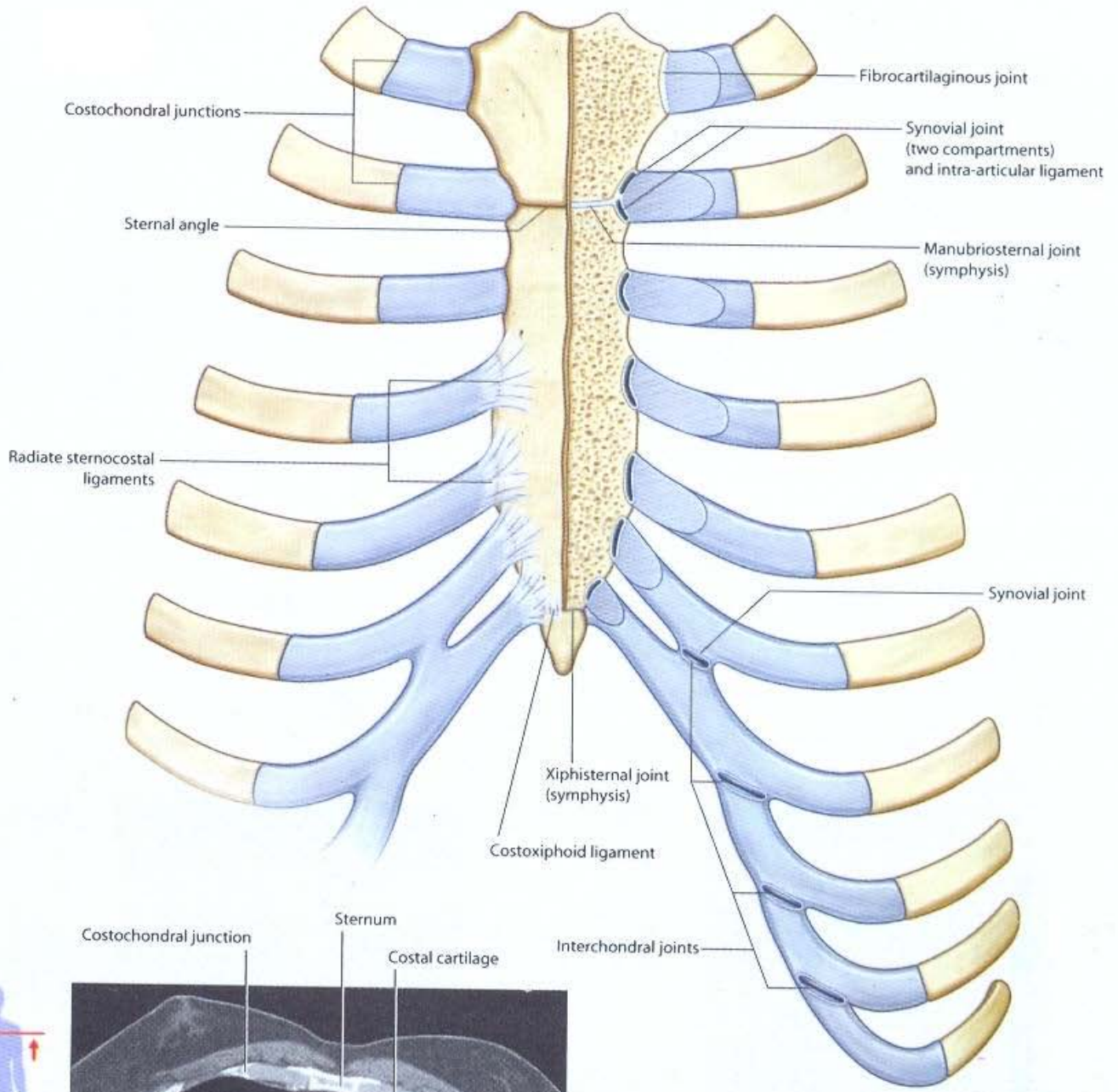
**Articulation of rib with thoracic vertebra (TIV).**  
CT image, with contrast, in axial plane



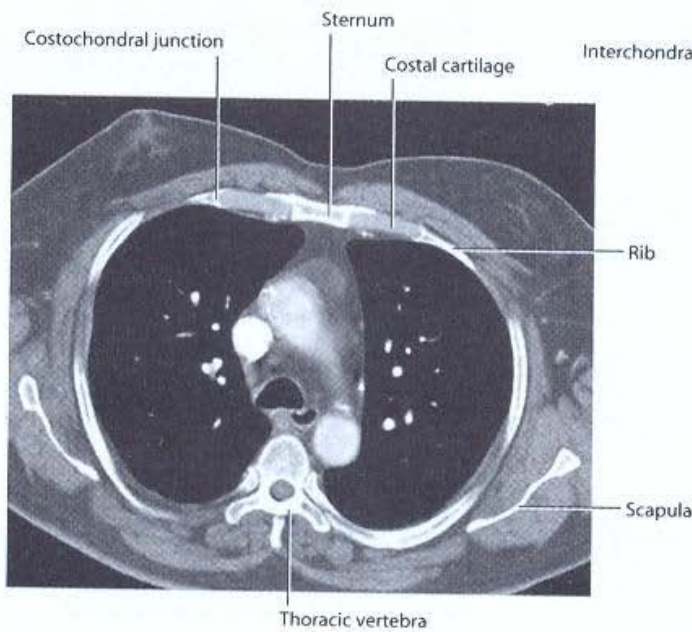
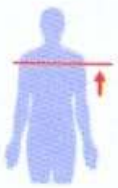
**Costovertebral joints (lateral view)**



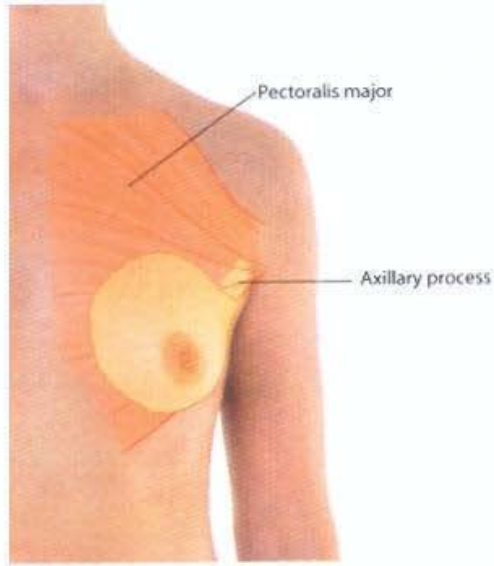
**Costovertebral joints (superior view)**



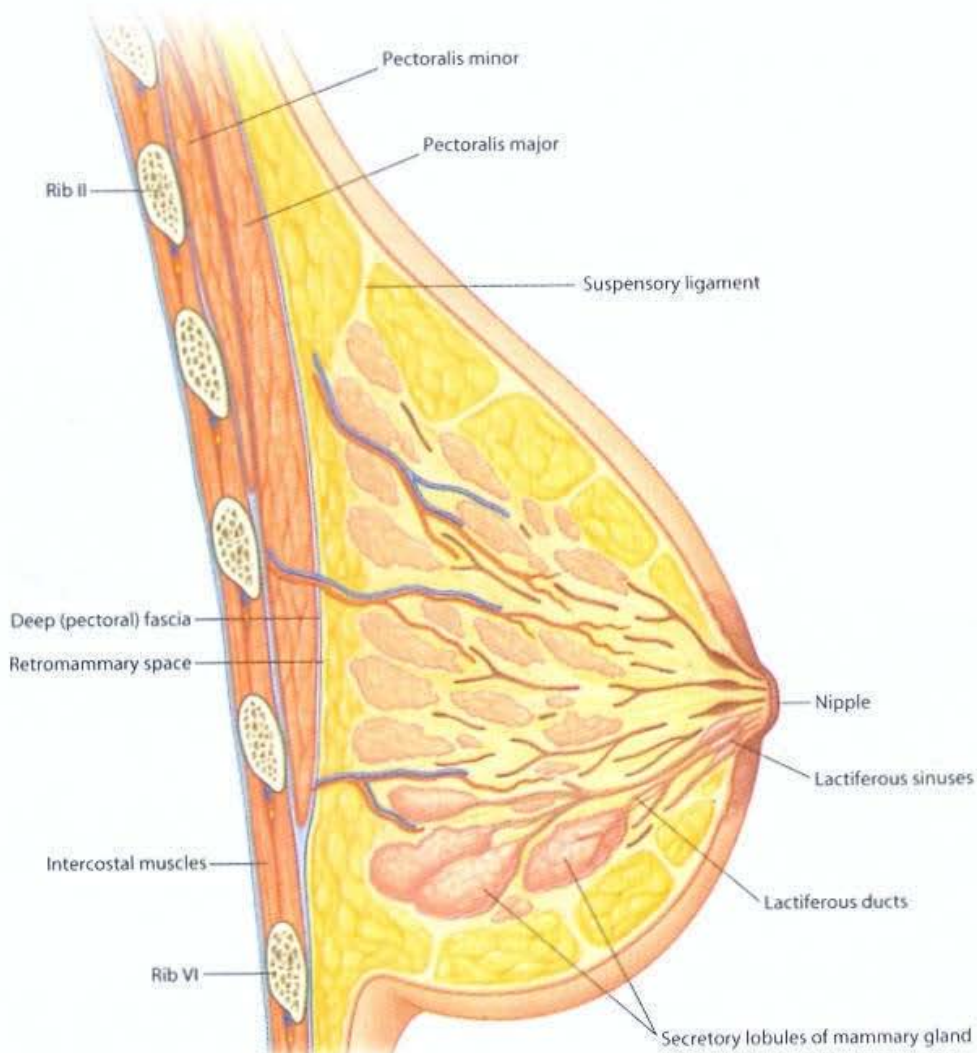
Sternocostal and interchondral joints



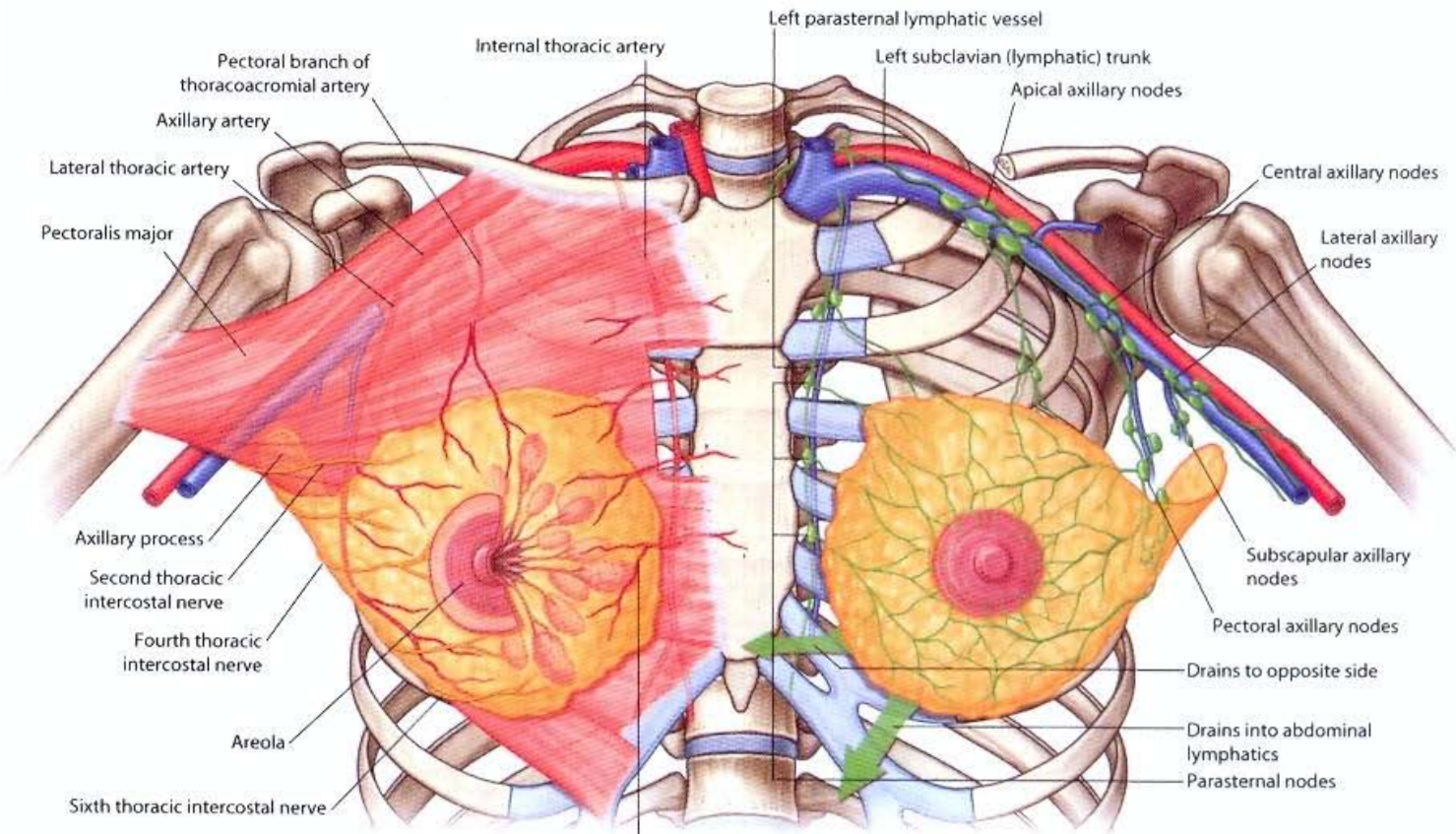
Articulation of costal cartilage with sternum.  
CT image, with contrast, in axial plane



**Anterior view**



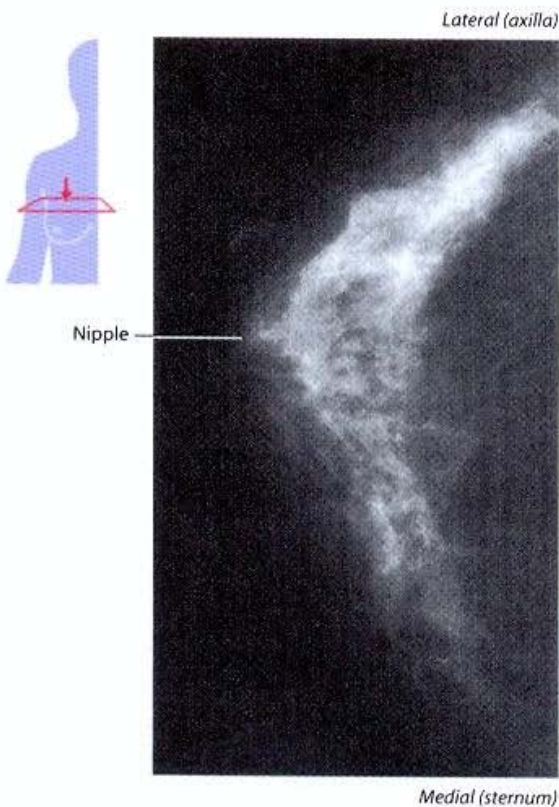
**Sagittal section**



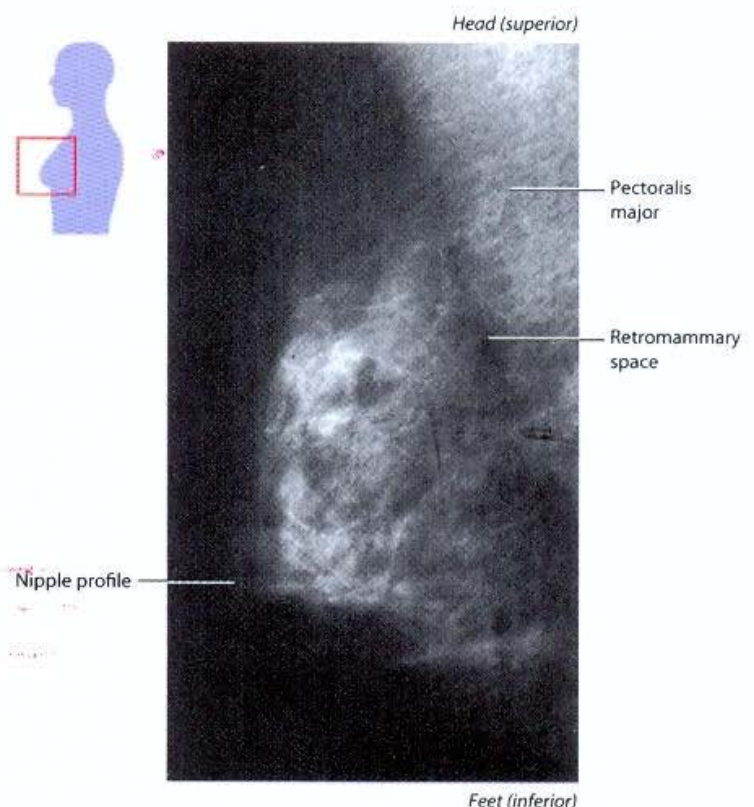
**Arteries and innervation of breast**

Mammary branches of internal thoracic artery

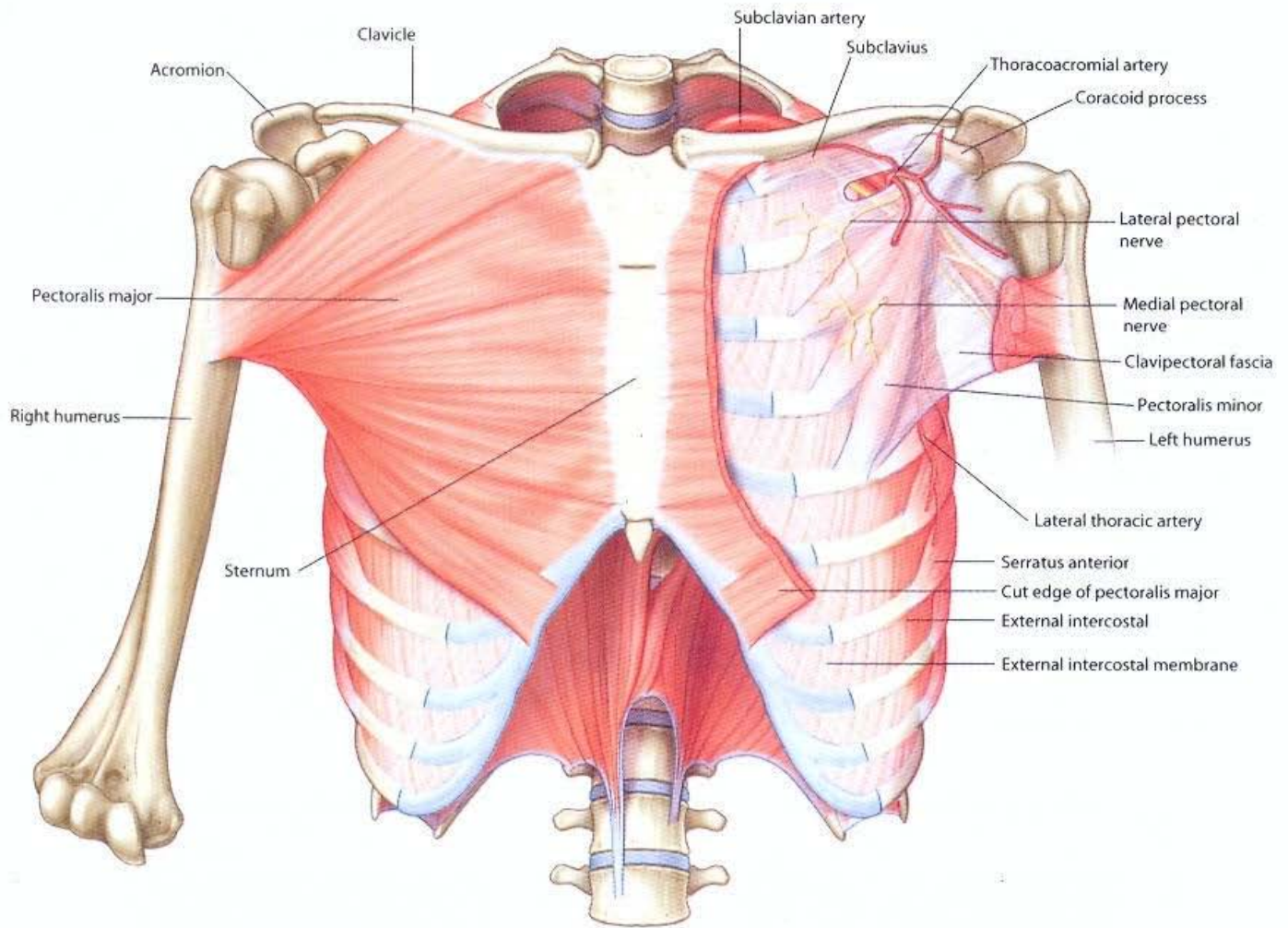
**Lymphatic drainage of breast**



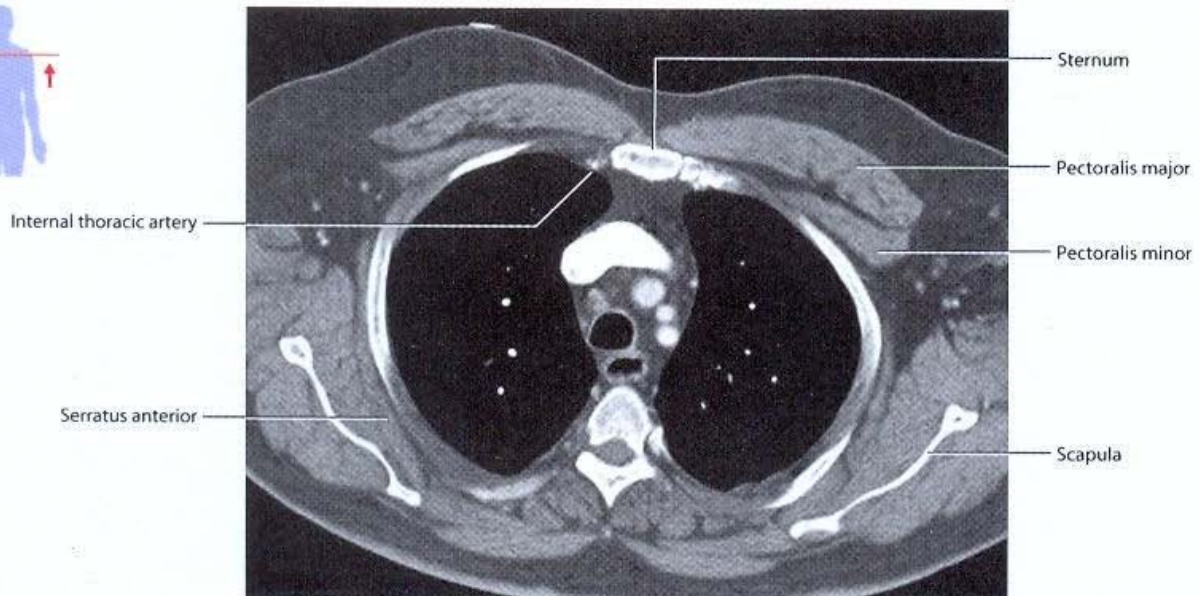
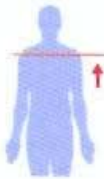
**Mammography. Craniocaudal (cc) view of a normal right breast showing a heterogeneously dense appearance**



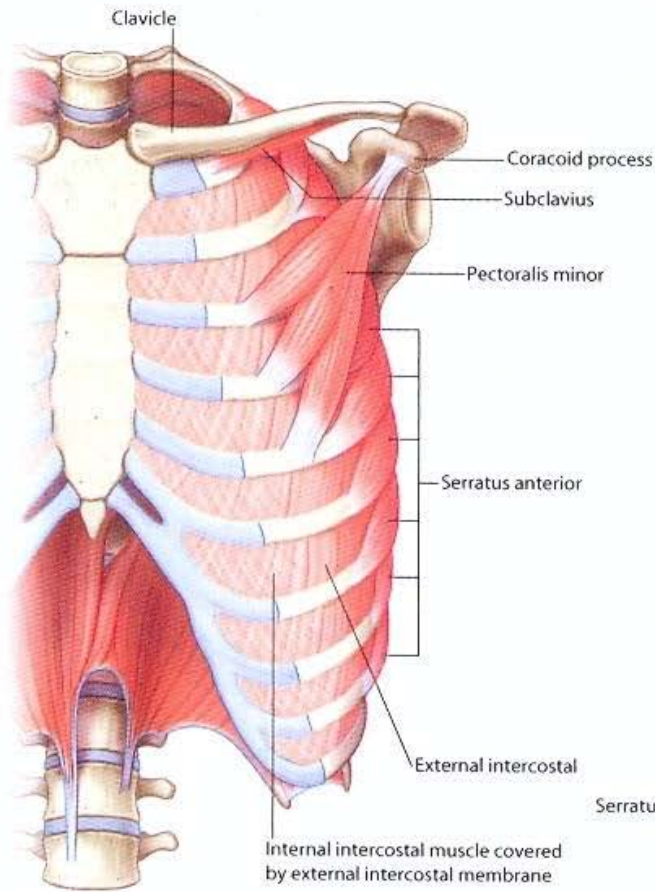
**Mammography. Mediolateral oblique (mlo) view of a normal right breast showing a heterogeneously dense appearance**



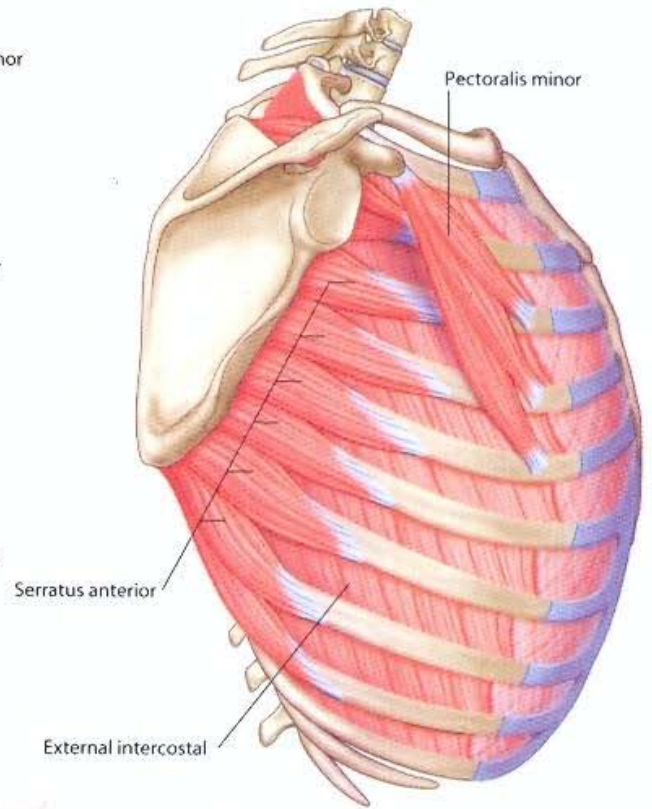
**Pectoralis major muscle and related deep structures**



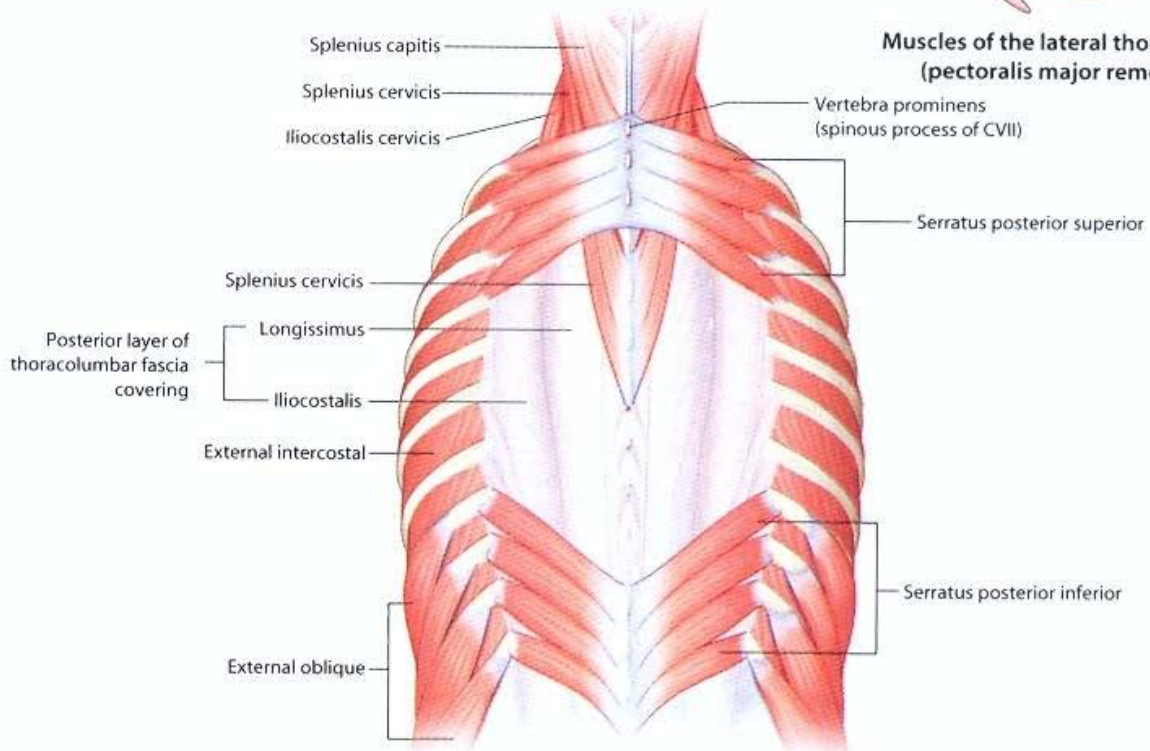
**Pectoralis major and minor muscles on anterior thoracic wall.**  
CT image, with contrast, in axial plane



**Pectoralis minor and the anterior thoracic wall  
(pectoralis major removed)**

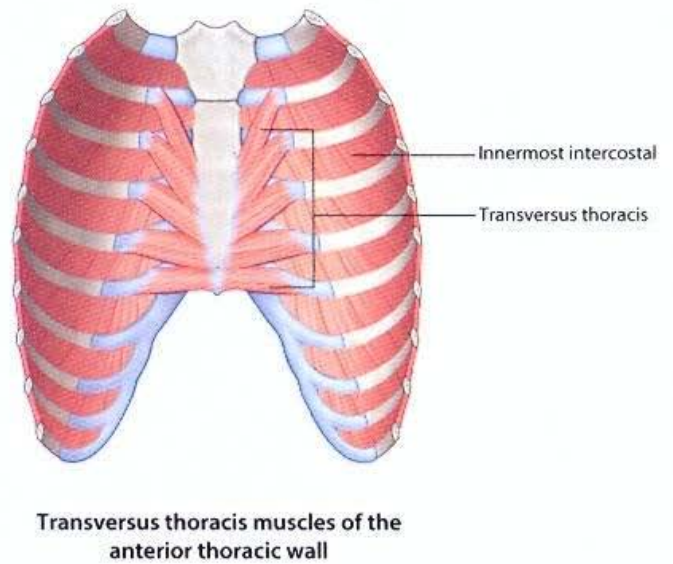
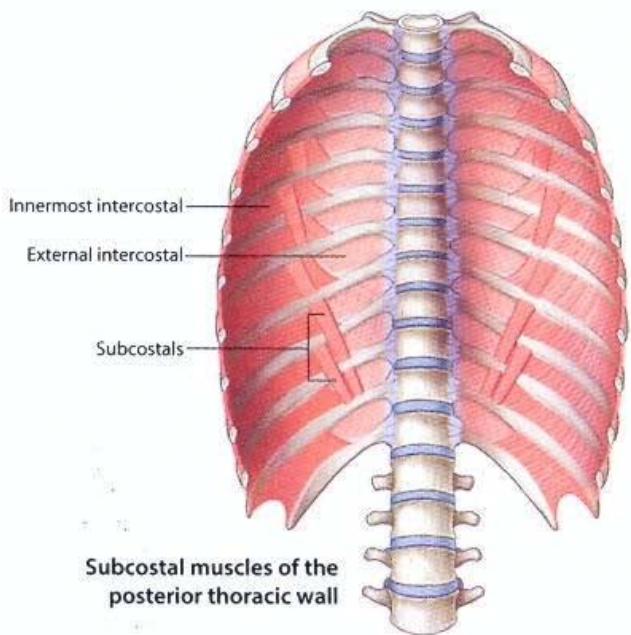
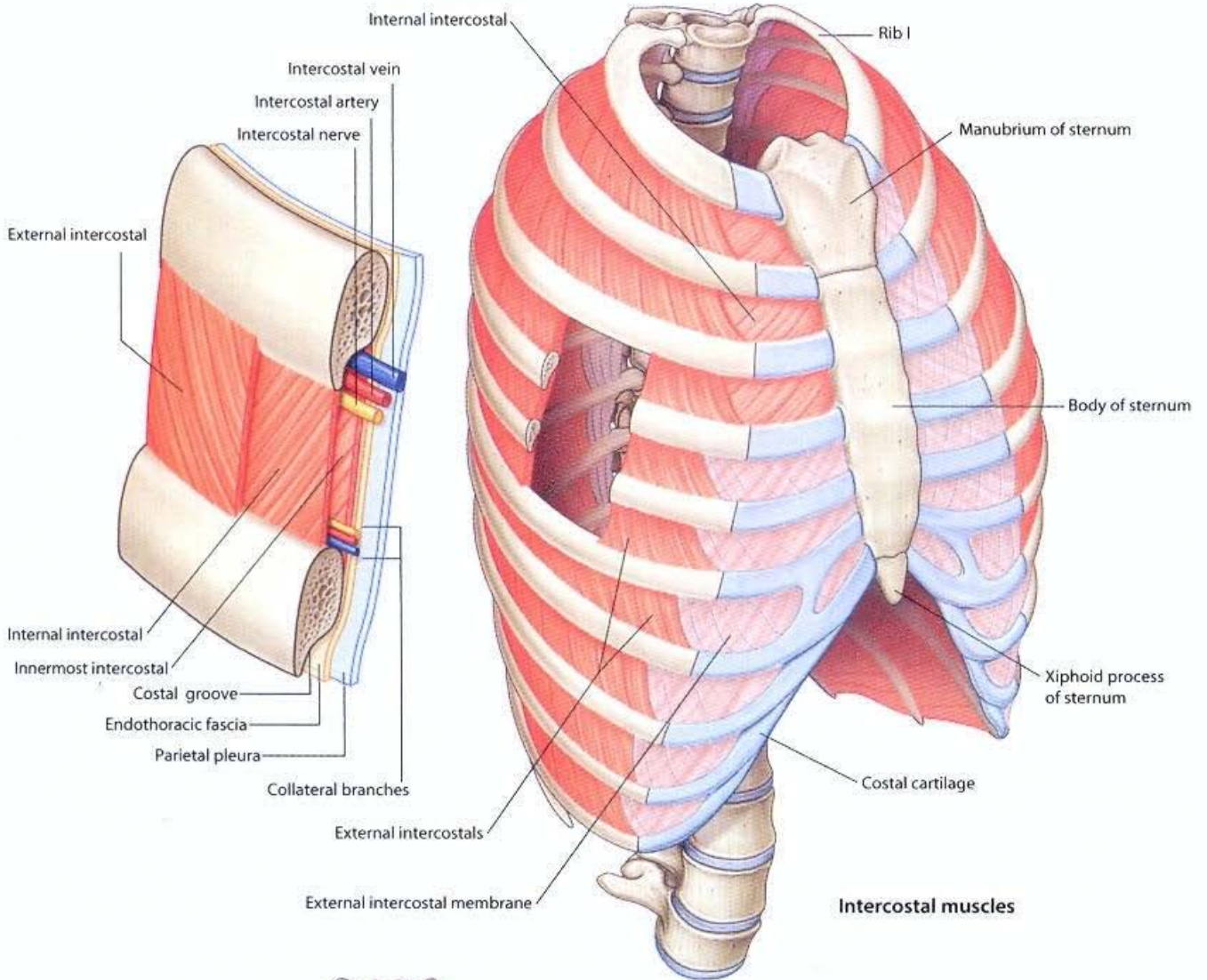


**Muscles of the lateral thoracic wall  
(pectoralis major removed)**

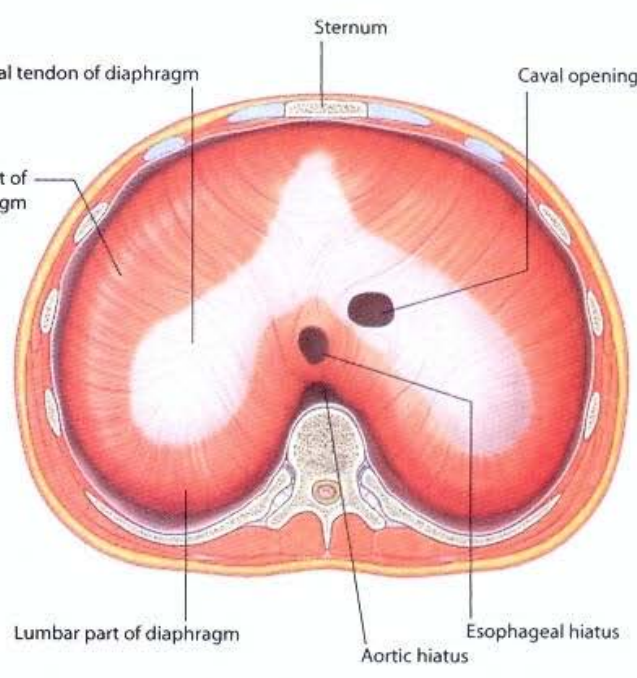
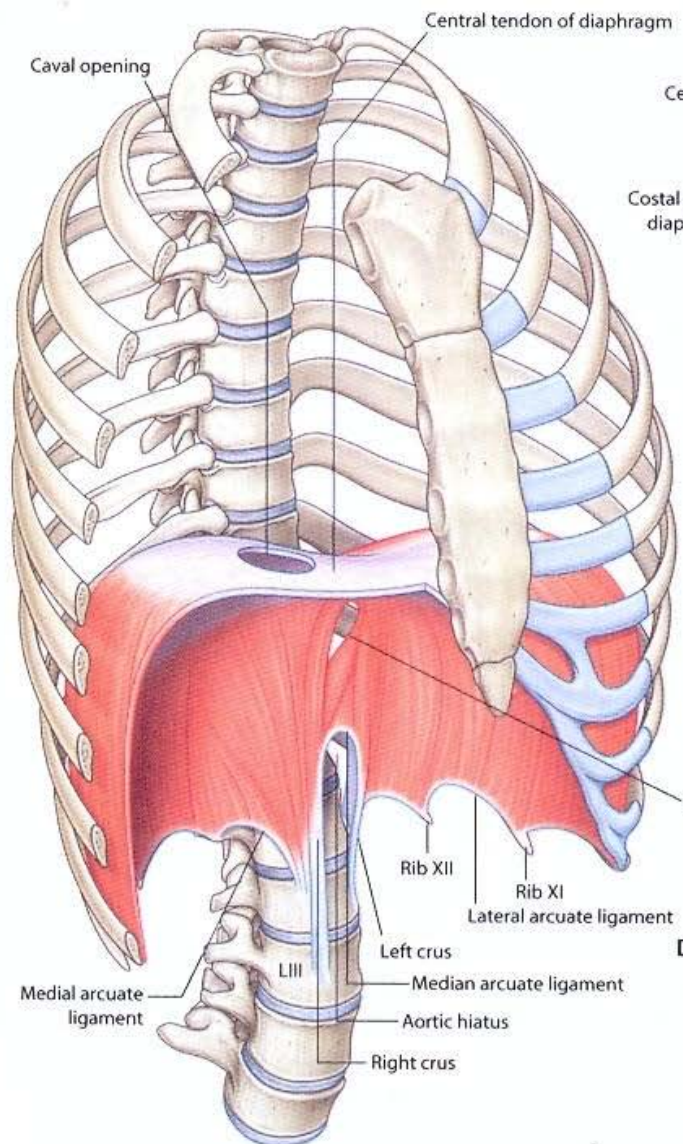


**Muscles of the posterior thoracic wall**

# THORAX • Thoracic wall muscles

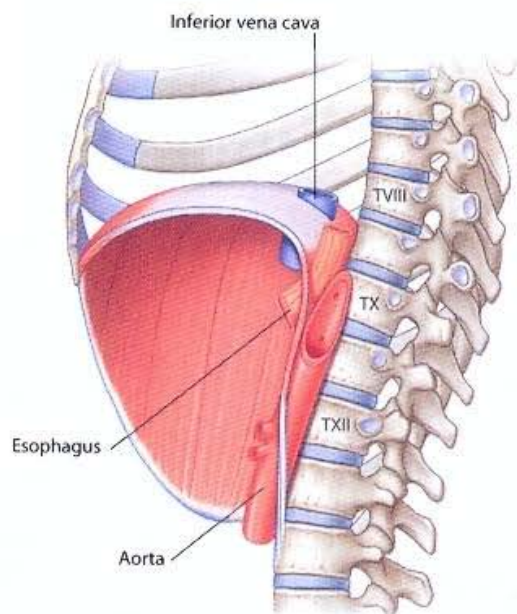




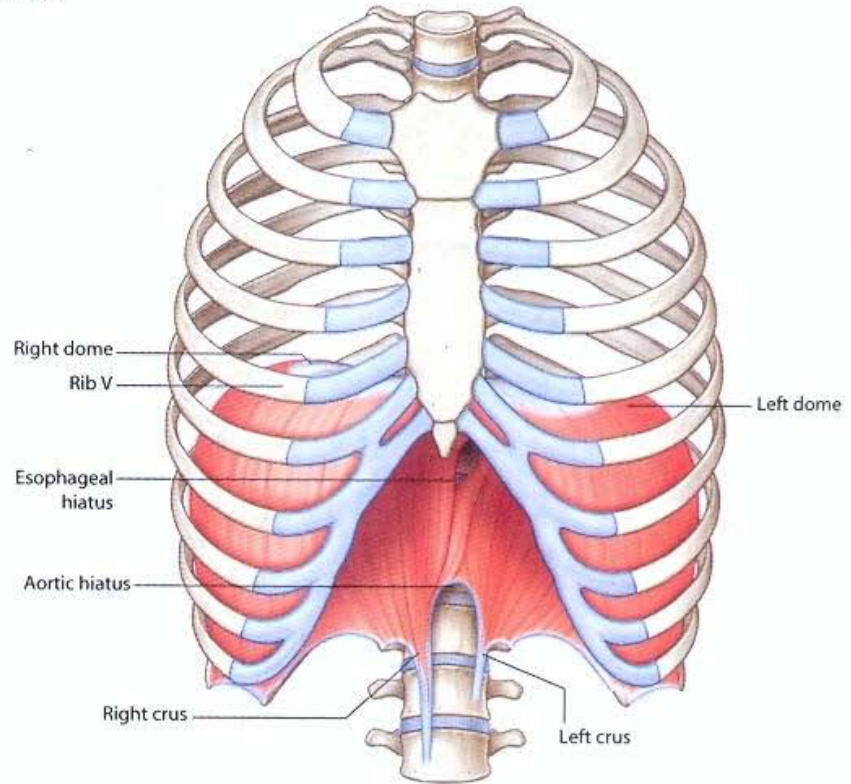


Diaphragm superior view

Diaphragm within the rib cage

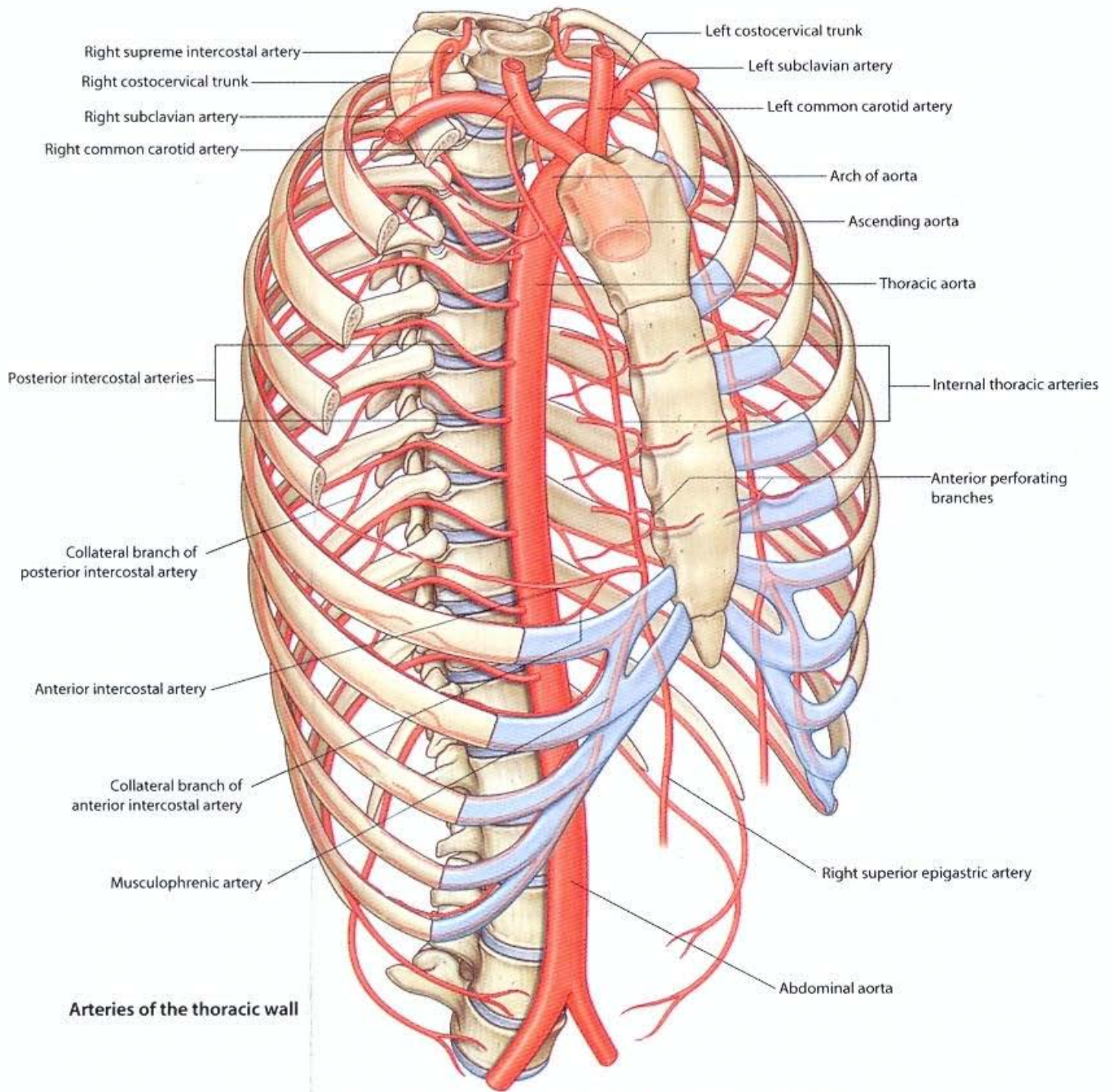


Major structures that pass through the diaphragm

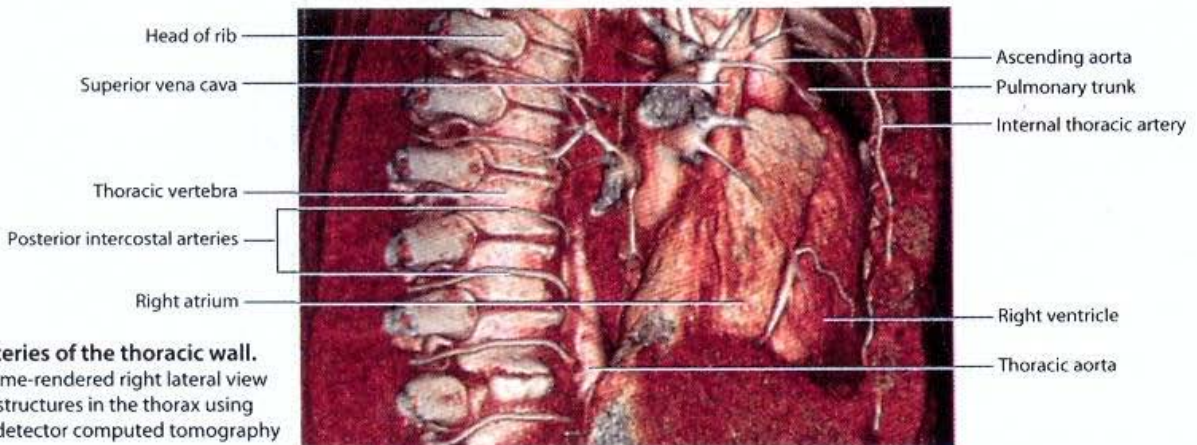


Features of diaphragm

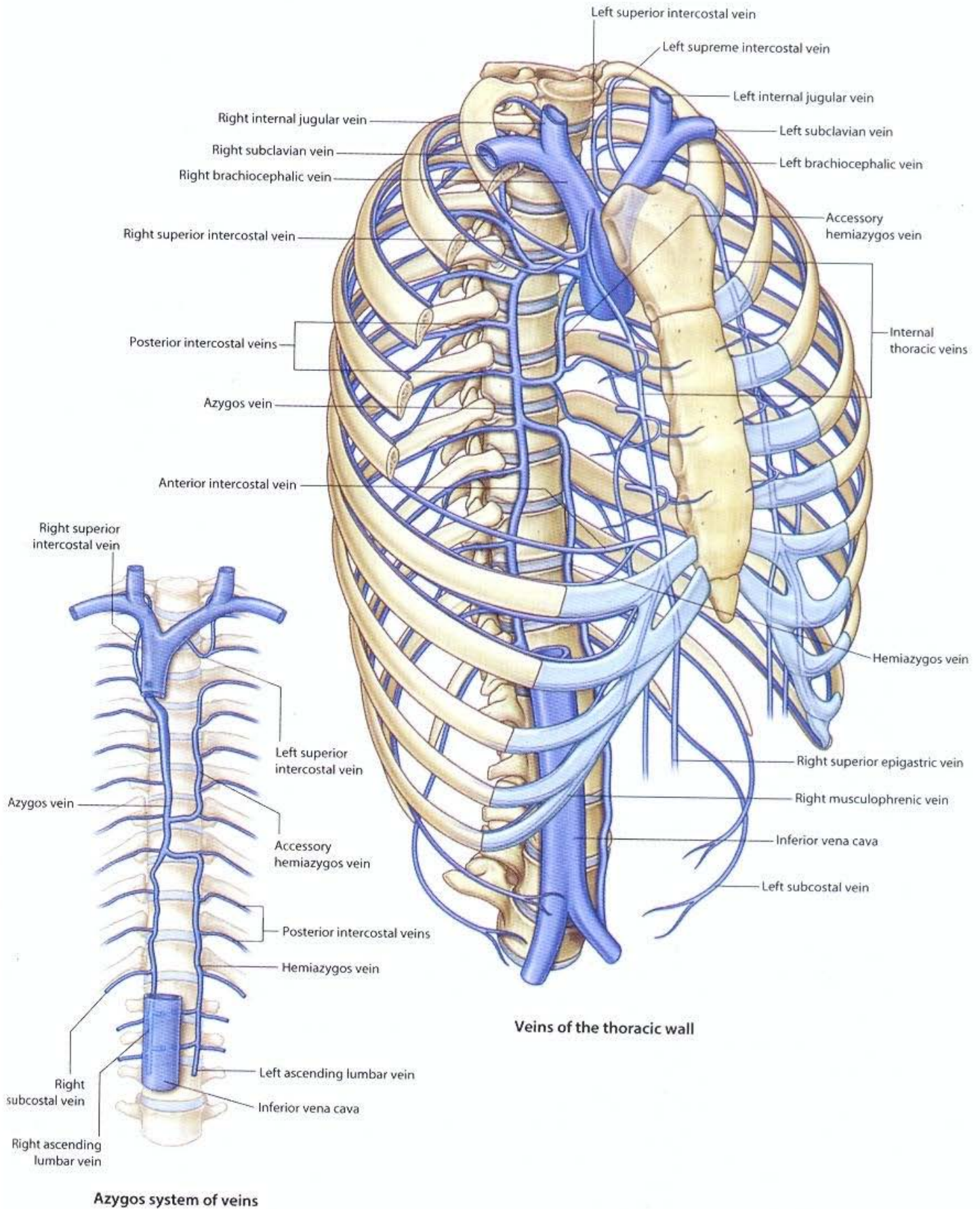
# THORAX • Arteries of the thoracic wall

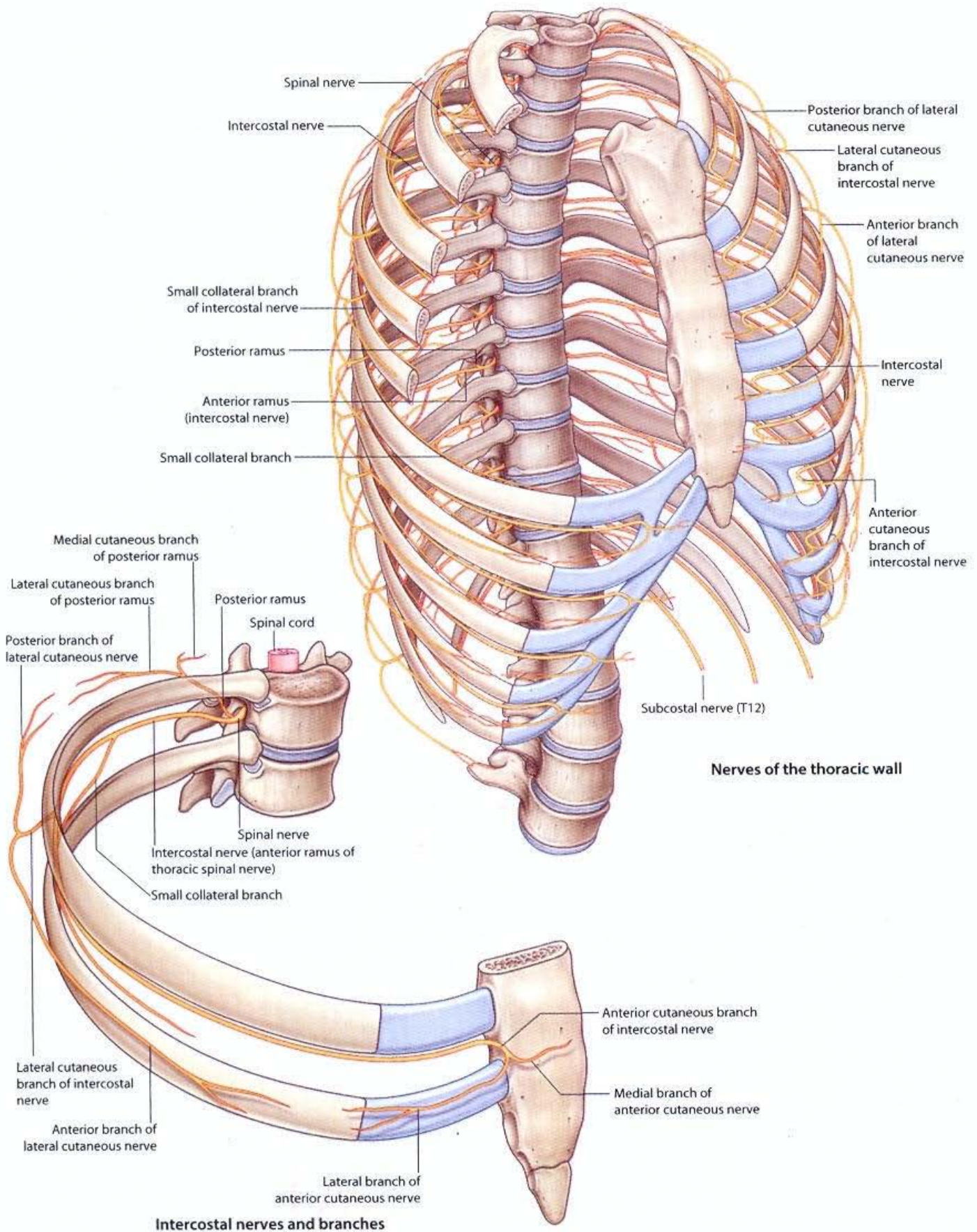


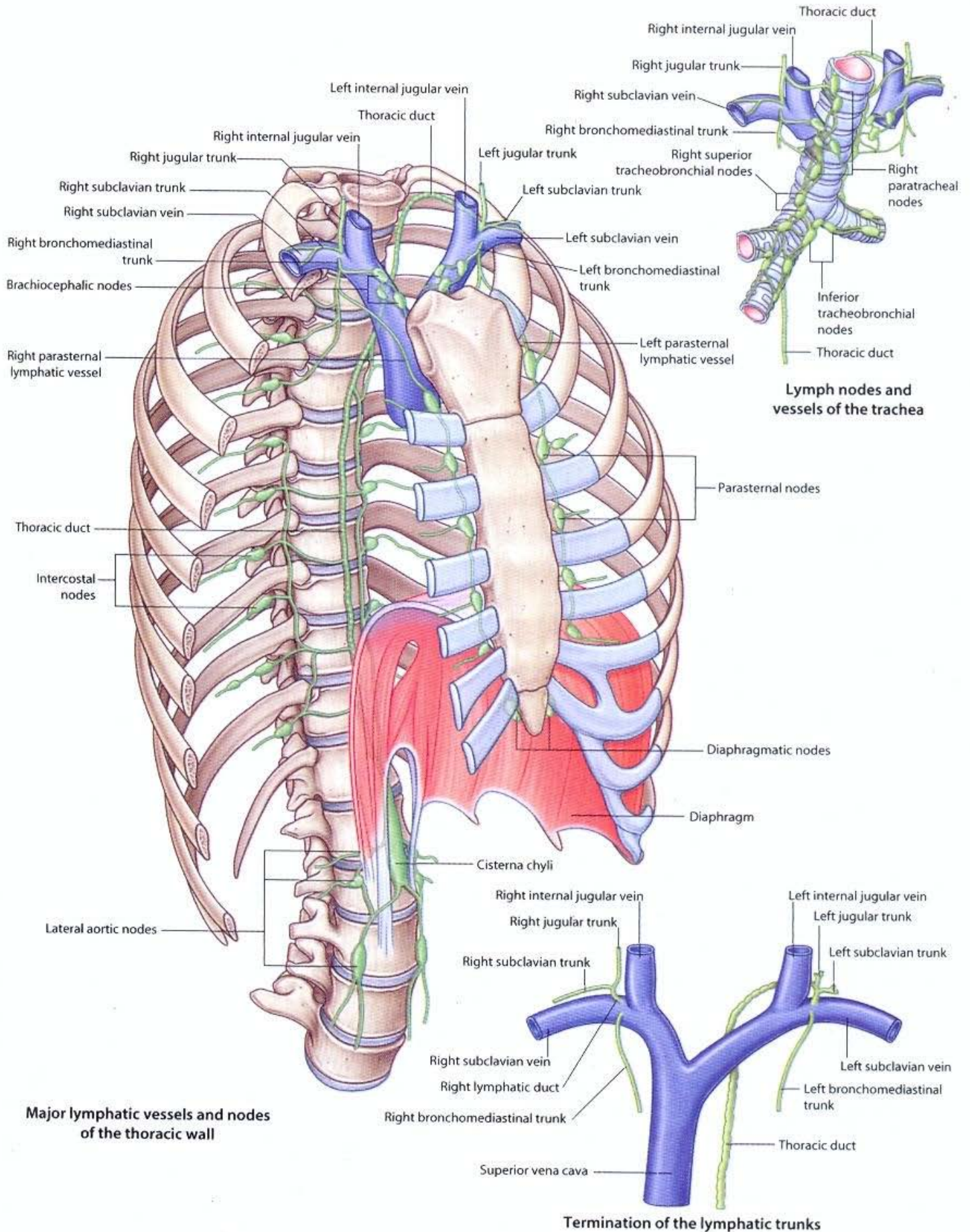
**Arteries of the thoracic wall**

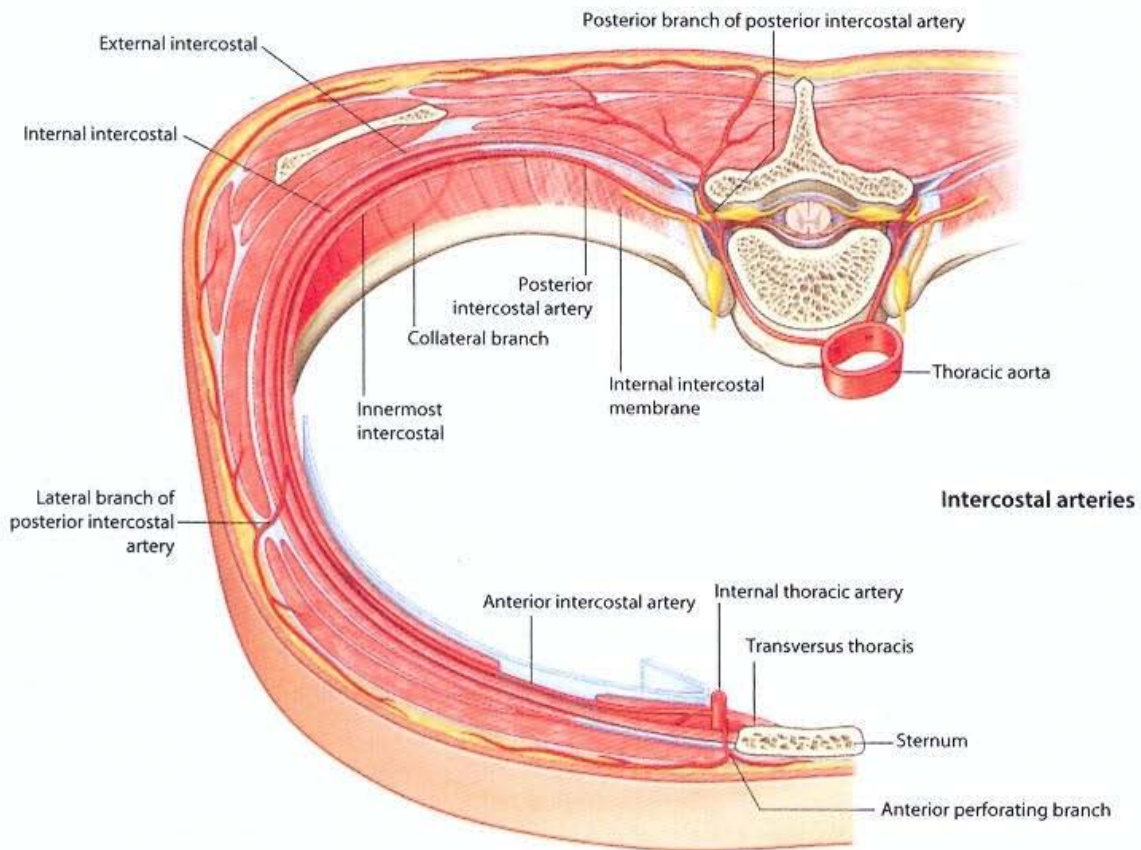
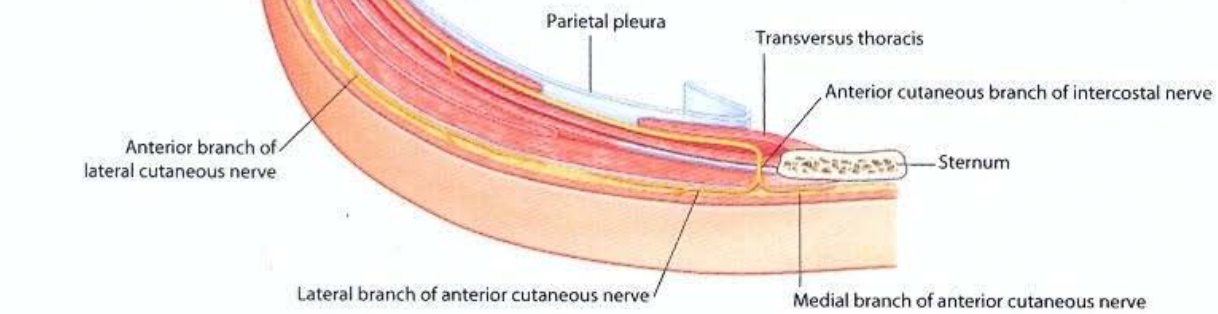
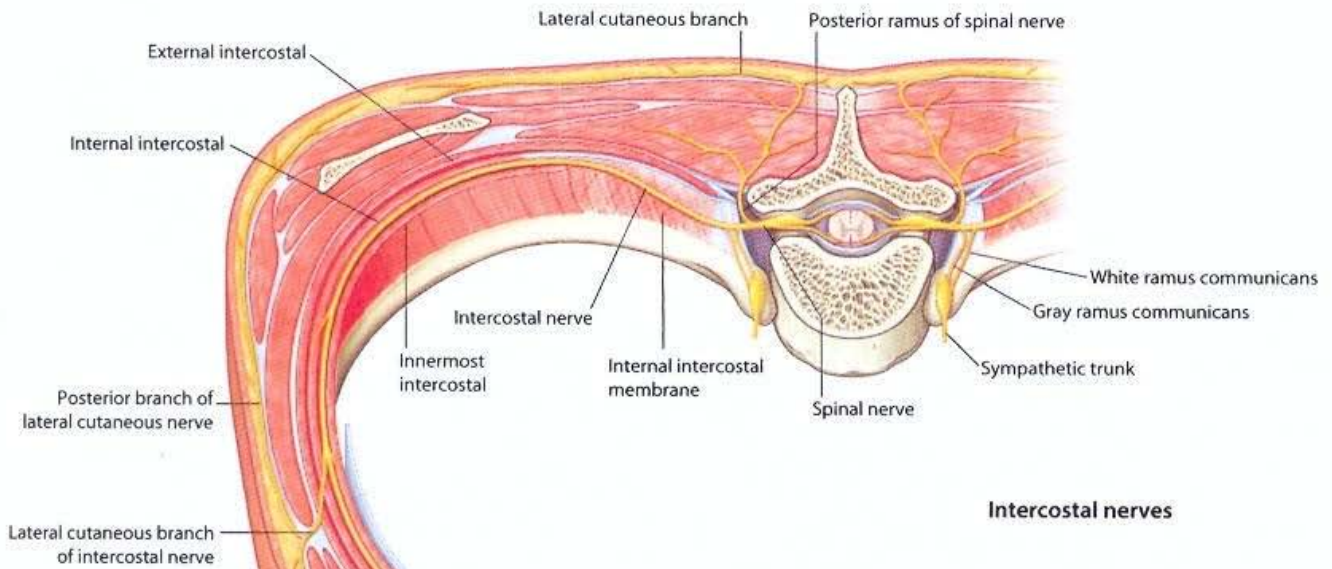


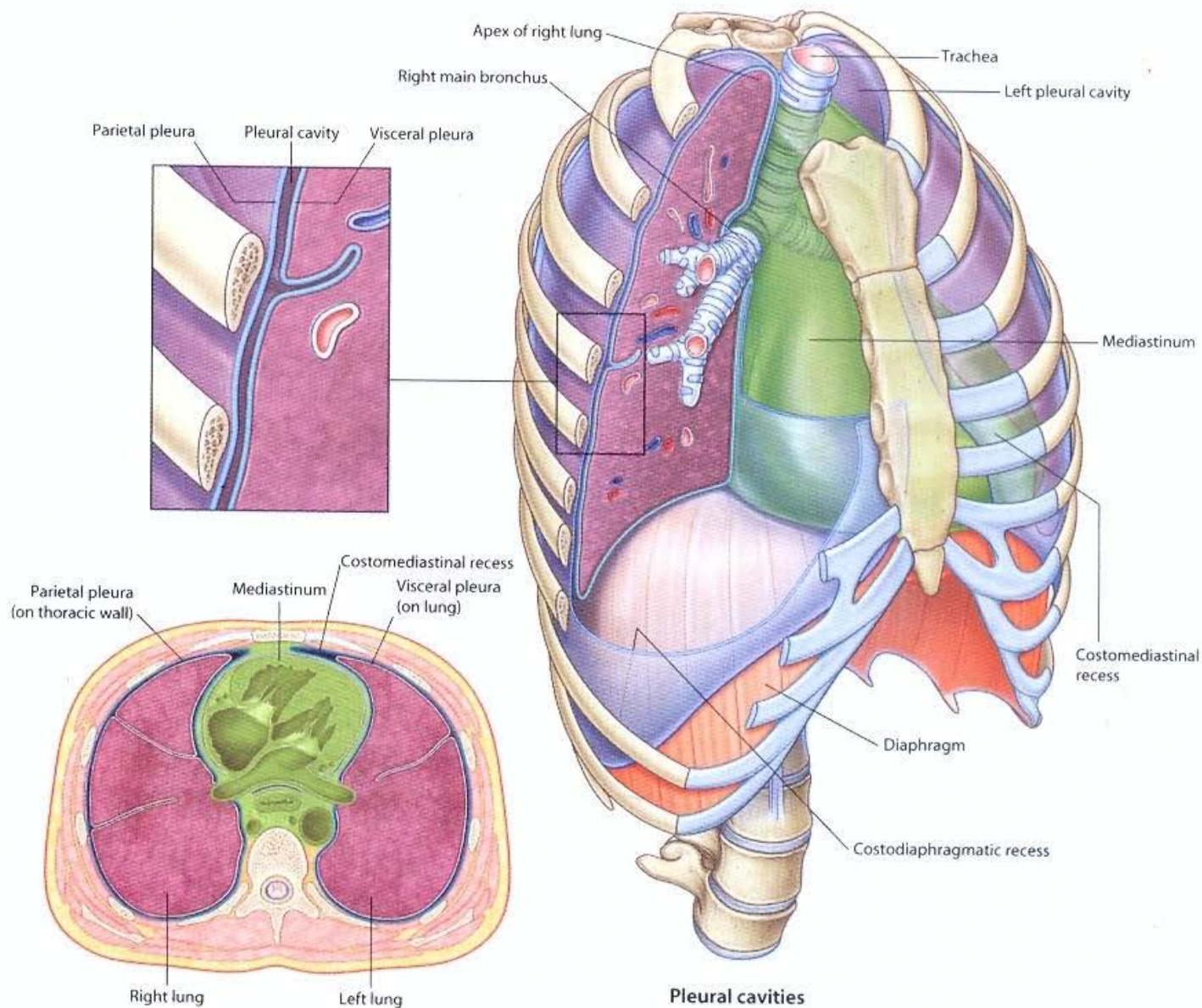
**Arteries of the thoracic wall.**  
Volume-rendered right lateral view of structures in the thorax using multidetector computed tomography



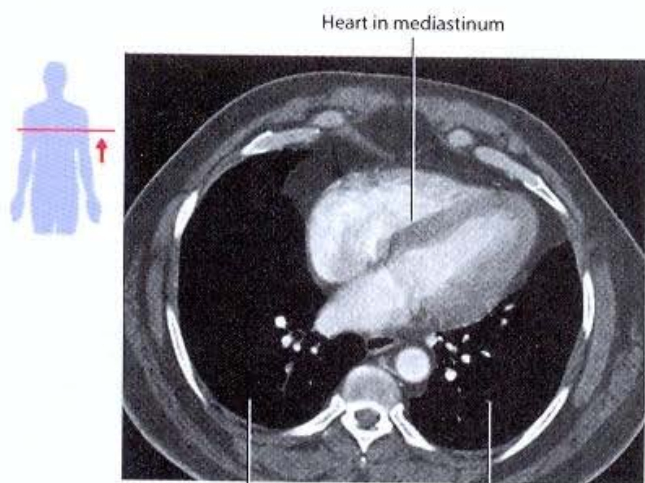




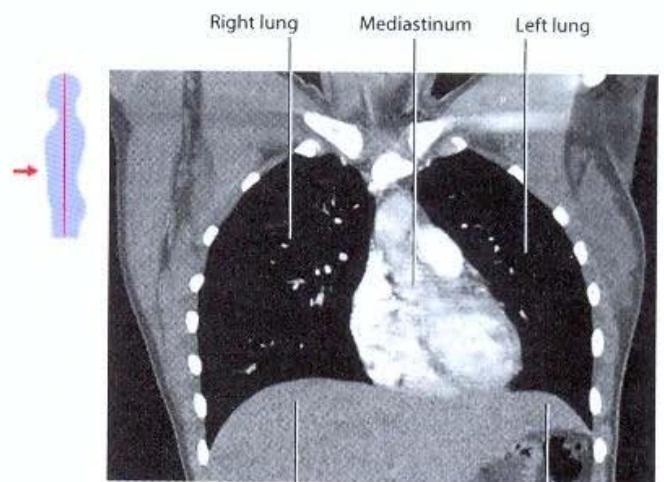




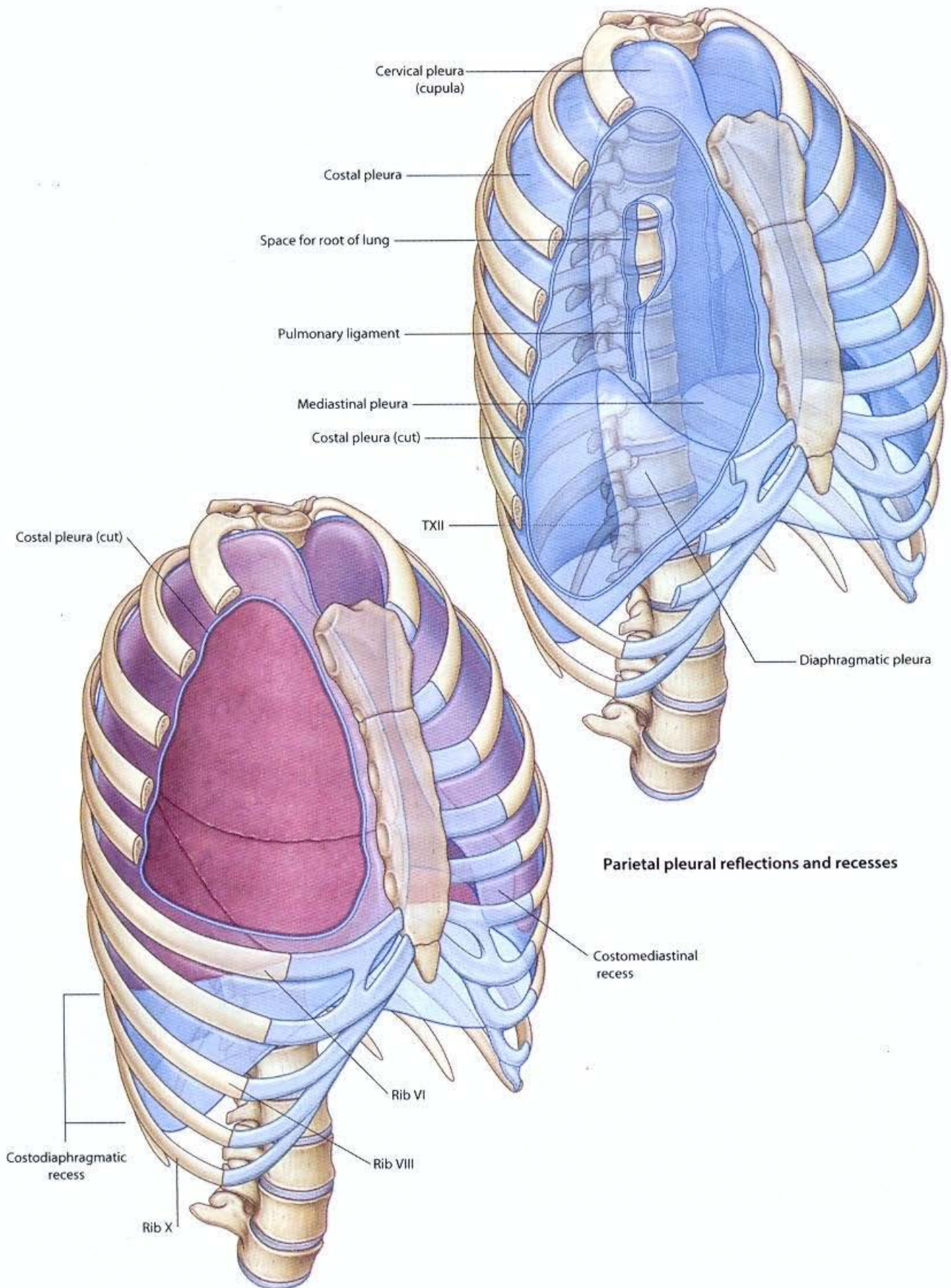
Pleural cavities



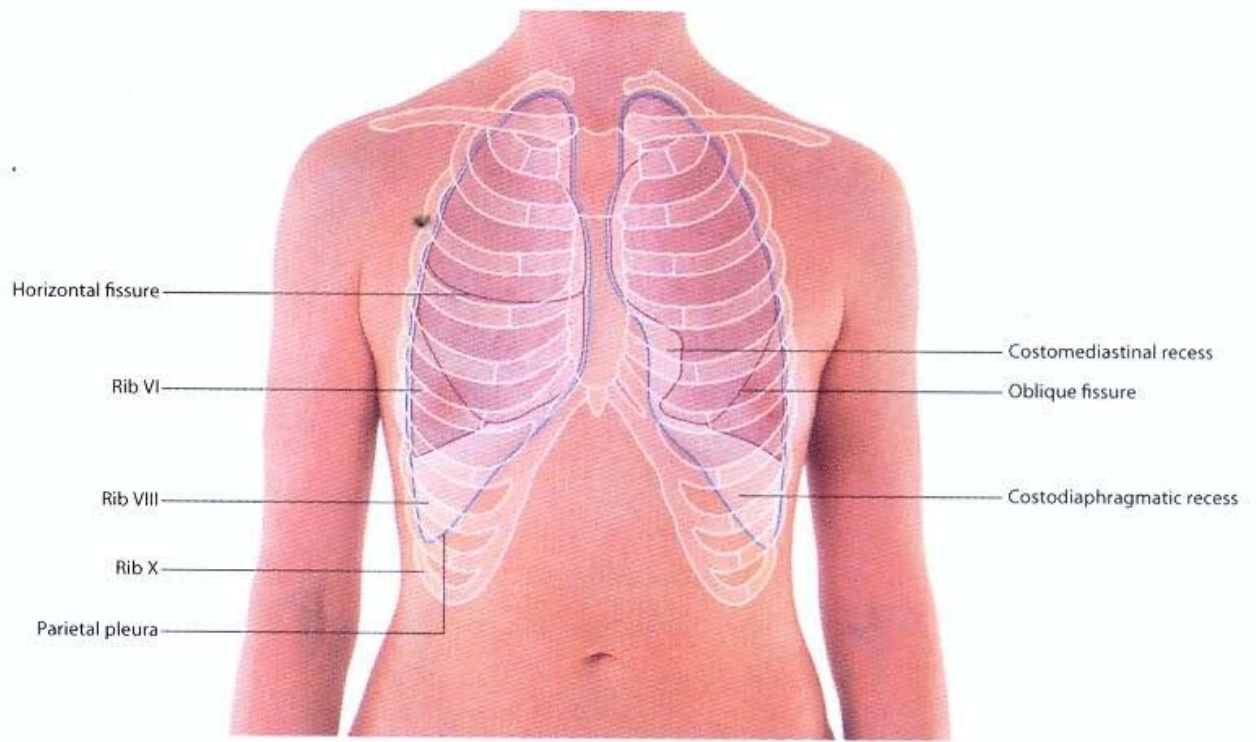
Organization of the thoracic cavity. CT image, with contrast, in axial plane



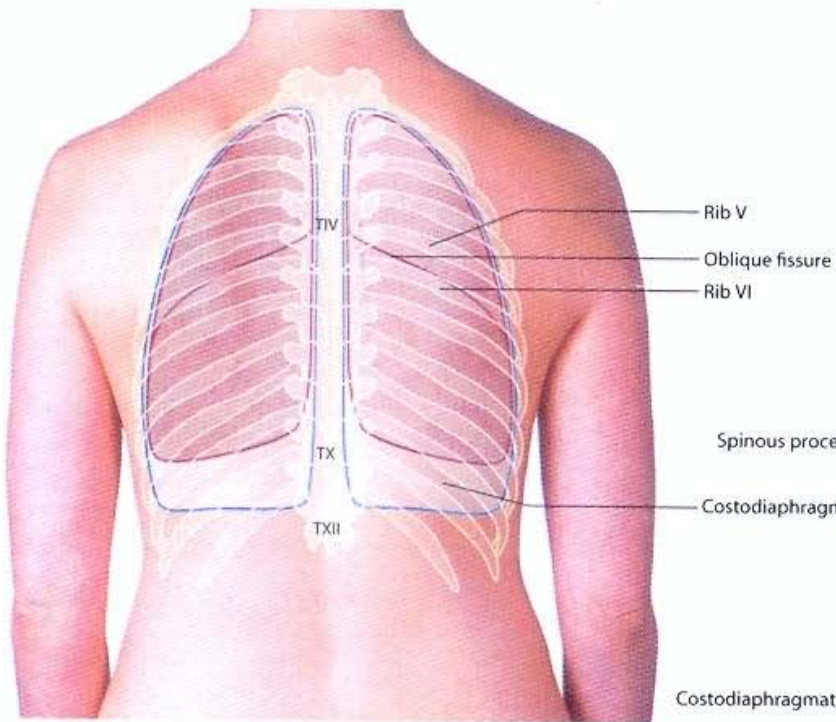
Organization of the thoracic cavity. CT image, with contrast, in coronal plane



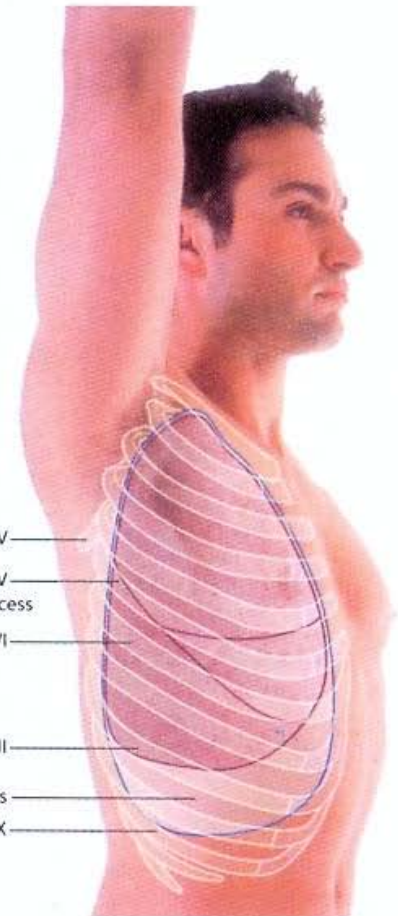




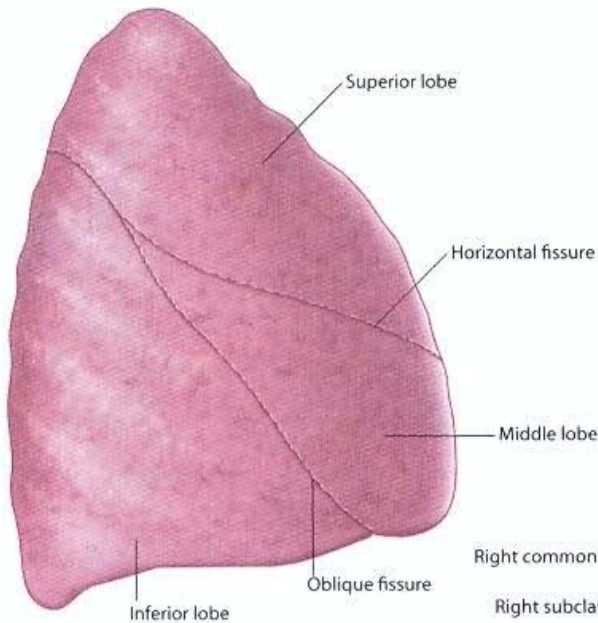
Surface projections of the pleura and lungs (anterior view)



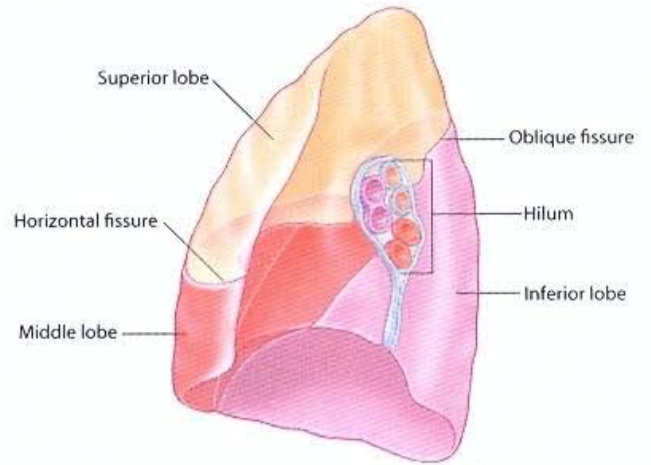
Surface projections of the pleura and lungs (posterior view)



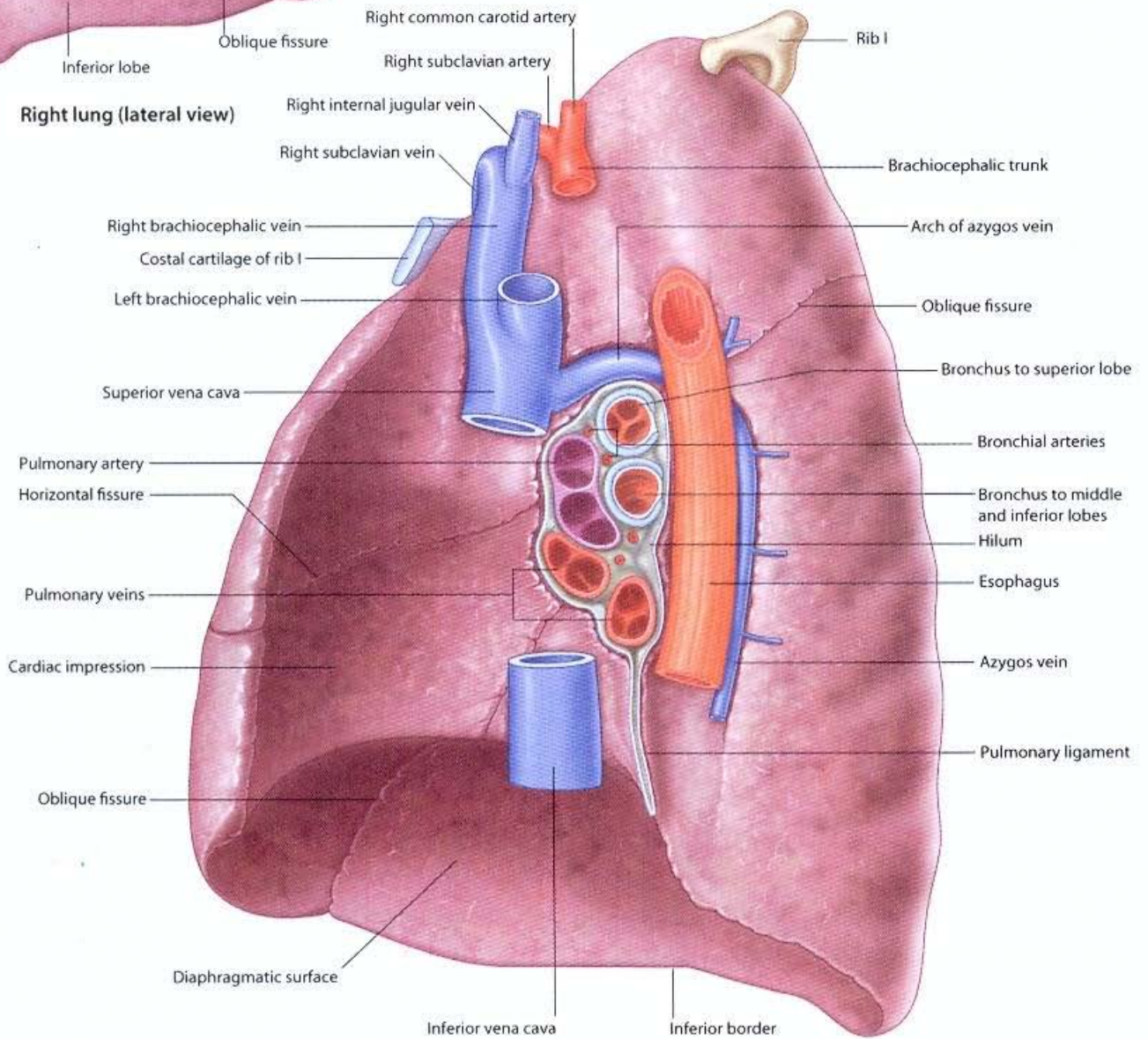
Surface projections of the pleura and right lung (lateral view)



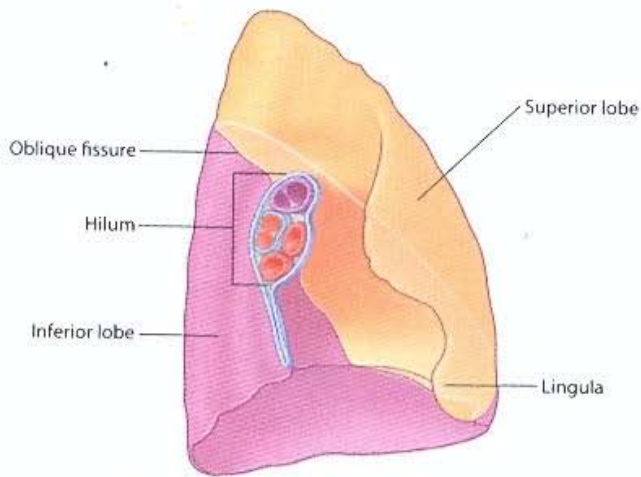
**Right lung (lateral view)**



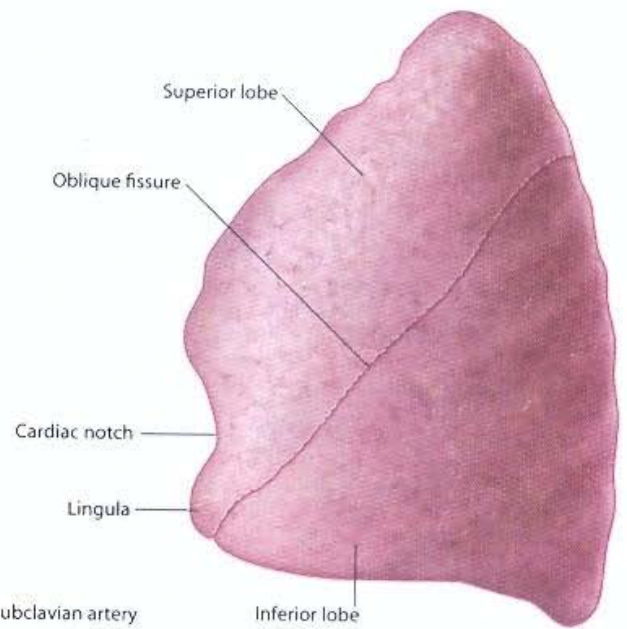
**Lobes of the right lung (anteromedial view)**



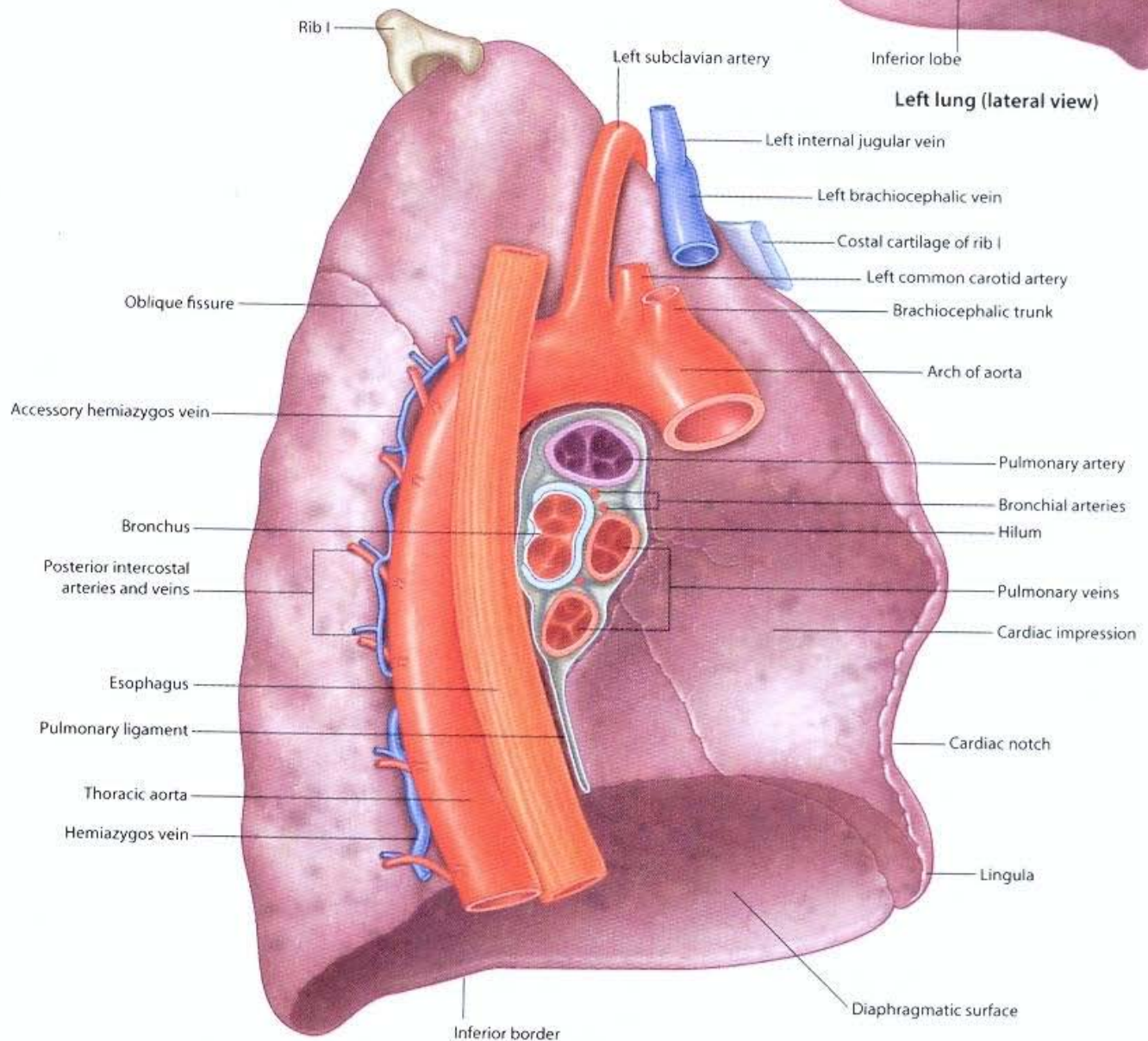
**Right lung and related structures (medial view)**



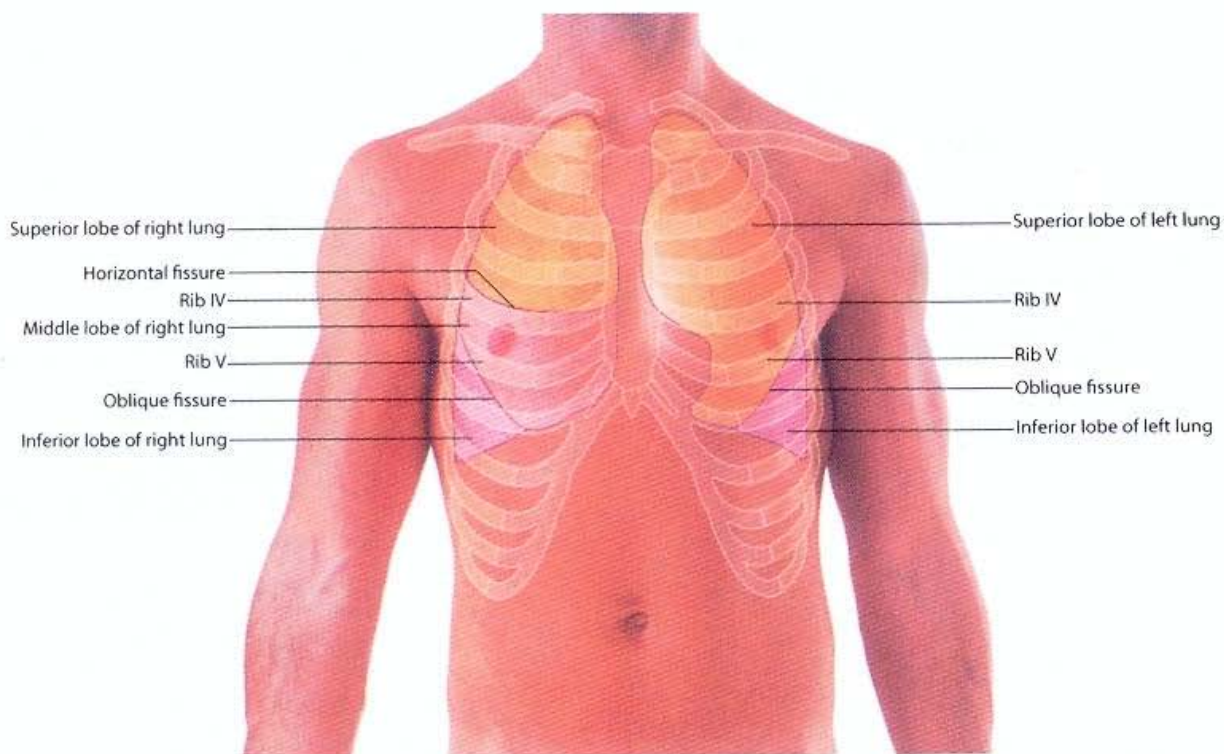
Lobes of the left lung (anteromedial view)



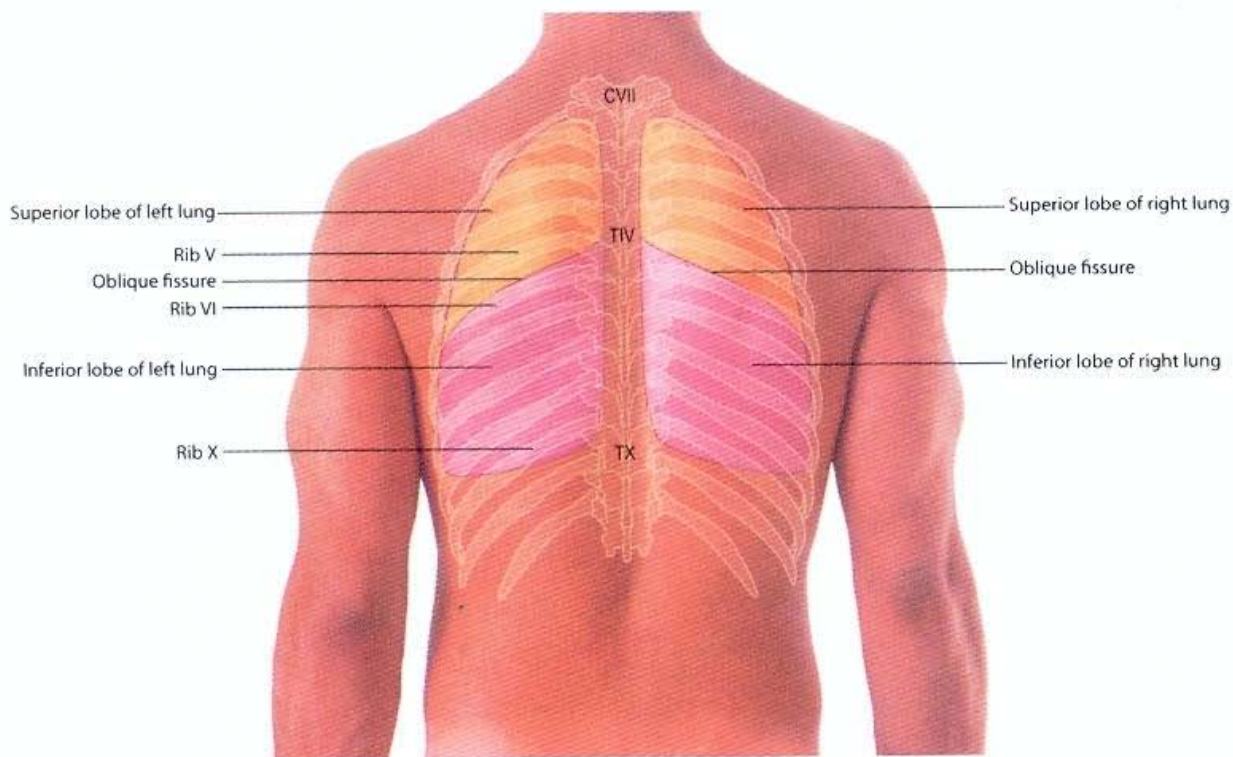
Left lung (lateral view)



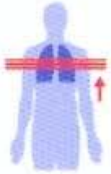
Left lung and related structures (medial view)



Surface projections of the lobes and fissures of the lungs (anterior view)



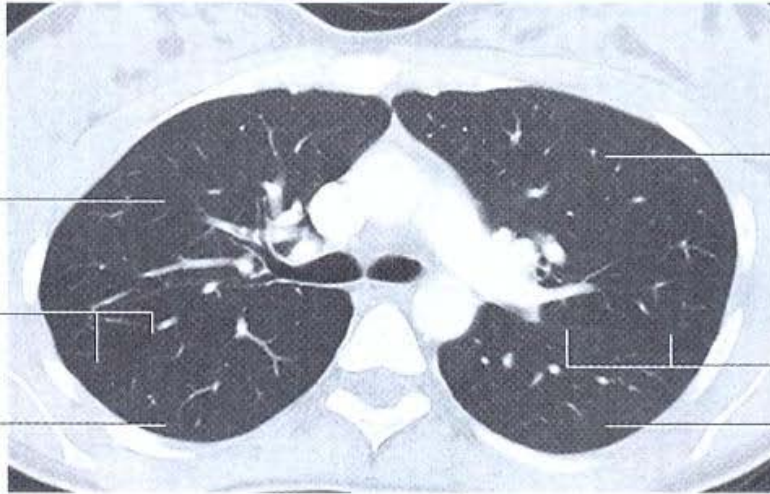
Surface projections of the lobes and fissures of the lungs (posterior view)



Superior lobe of right lung

Oblique fissure

Inferior lobe of right lung



Superior lobe of left lung

Oblique fissure

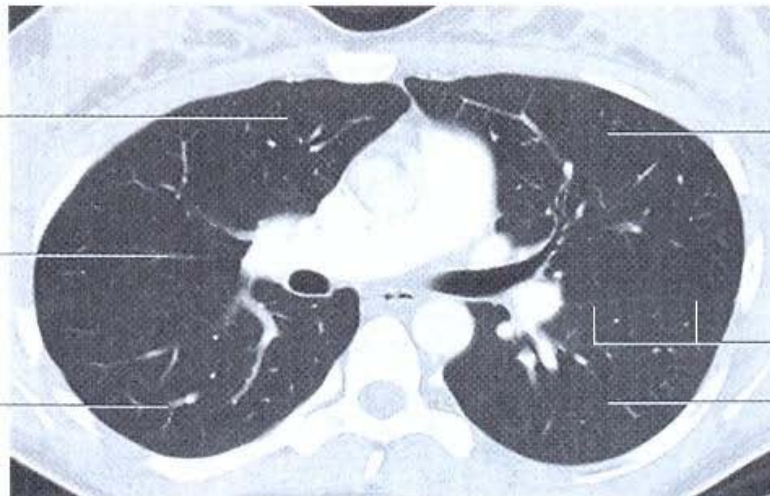Inferior lobe of left lung

**Right lung and left lung demonstrating superior and inferior lobes. The oblique fissures are visible.**  
CT image, with contrast, in axial plane

Superior lobe of right lung

Middle lobe of right lung

Inferior lobe of right lung



Superior lobe of left lung

Oblique fissure

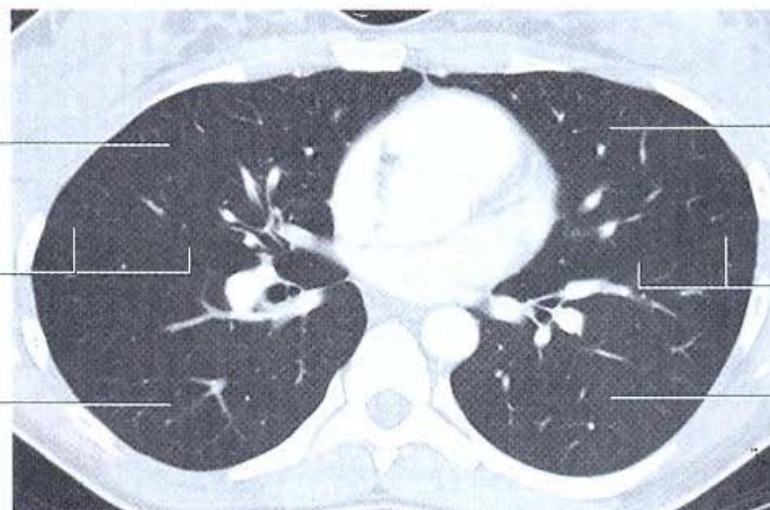Inferior lobe of left lung

**Right lung demonstrating superior, middle, and inferior lobes and the left lung demonstrating superior and inferior lobes. The oblique fissure associated with the left lung is visible.**  
CT image, with contrast, in axial plane

Middle lobe of right lung

Oblique fissure

Inferior lobe of right lung

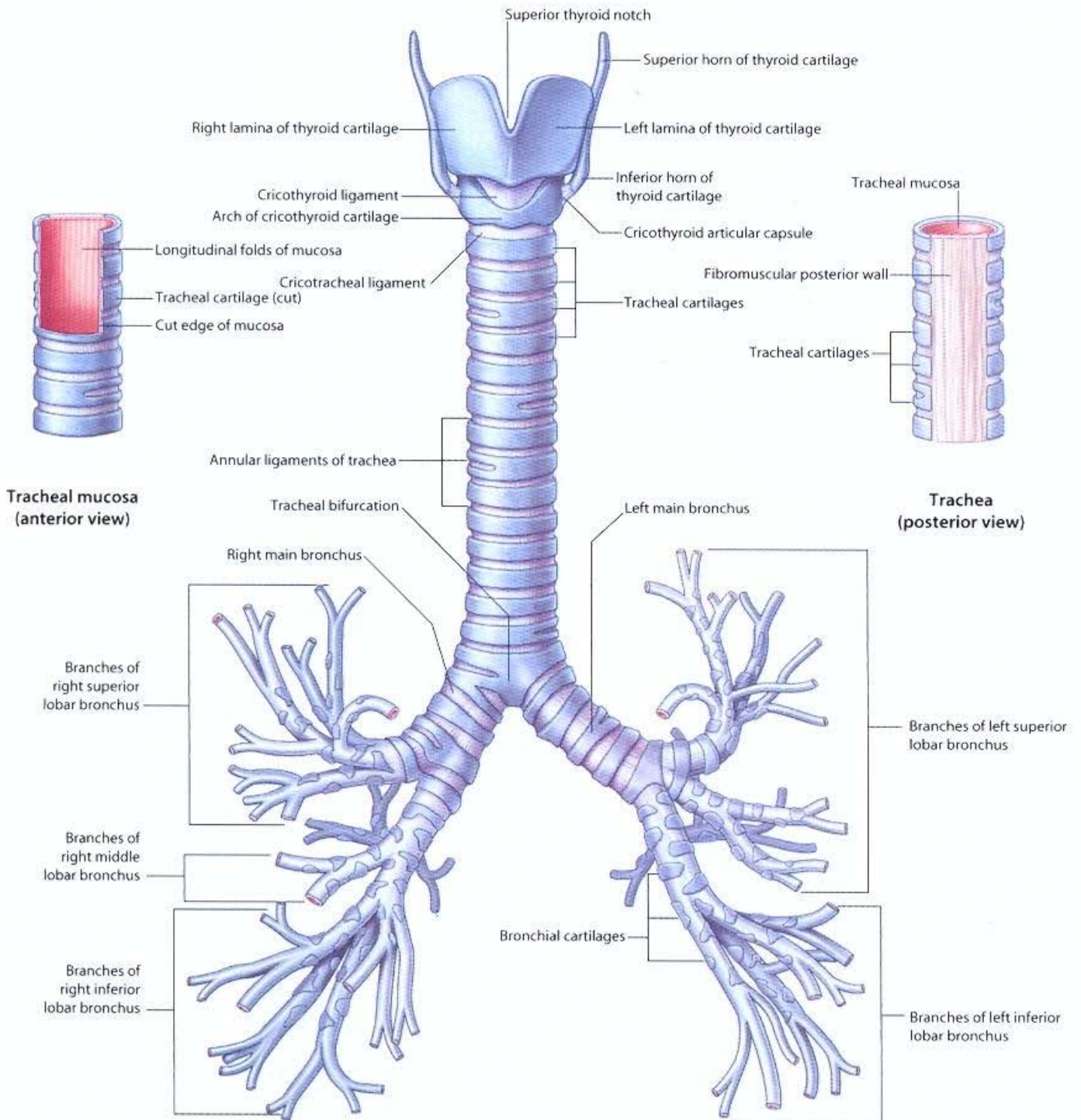


Superior lobe of left lung

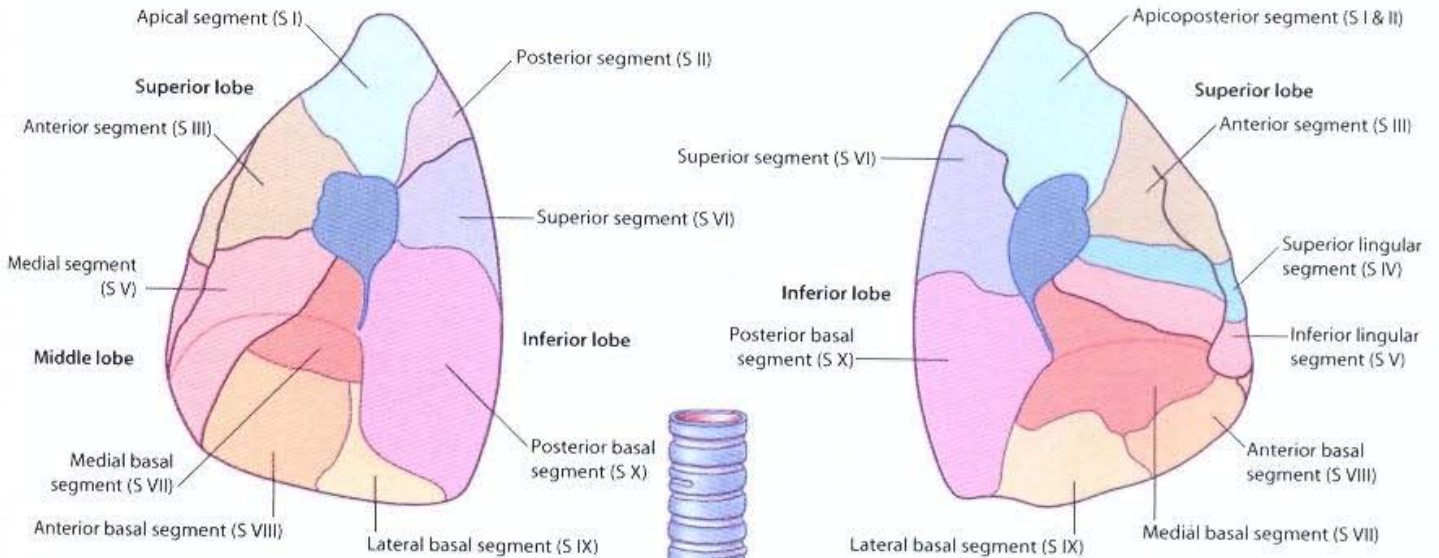
Oblique fissure

Inferior lobe of left lung

**Right lung demonstrating middle and inferior lobes and the left lung demonstrating superior and inferior lobes. The oblique fissures are visible.**  
CT image, with contrast, in axial plane

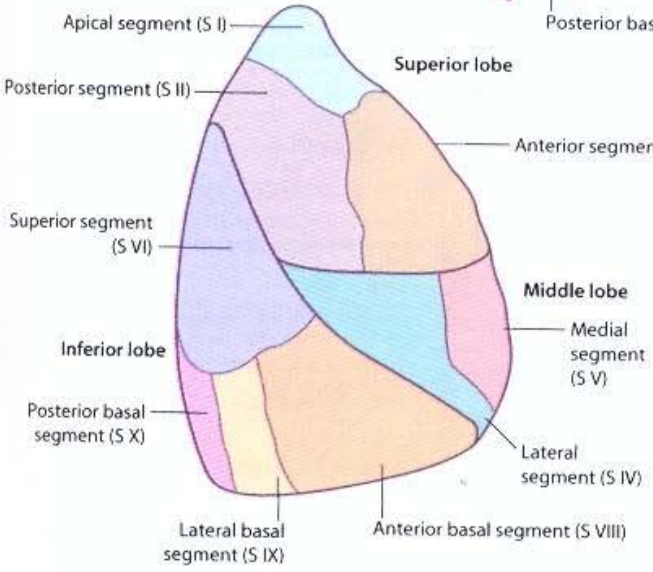
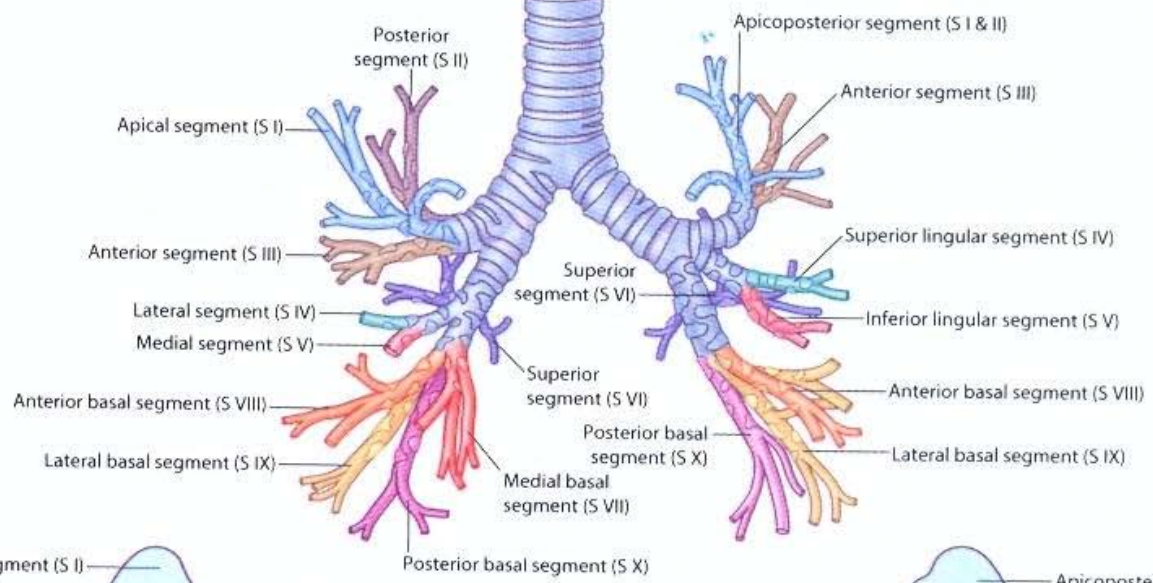


**Trachea and bronchial tree**

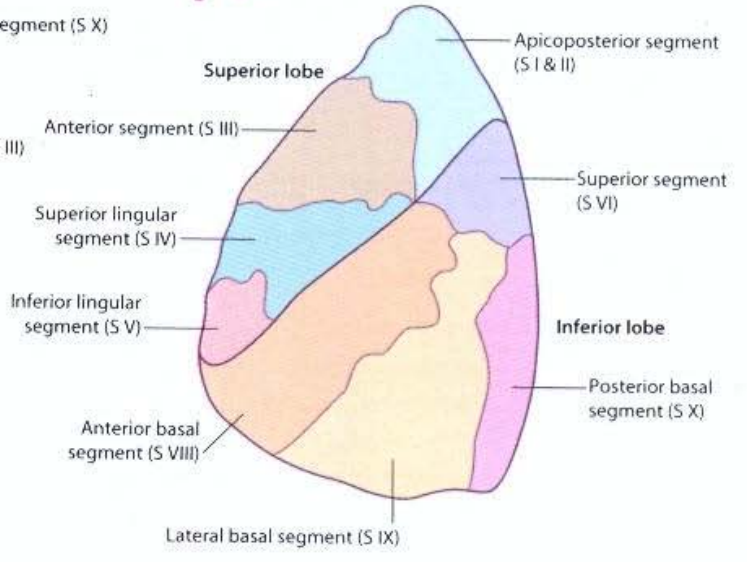


Right lung (medial view)

Left lung (medial view)

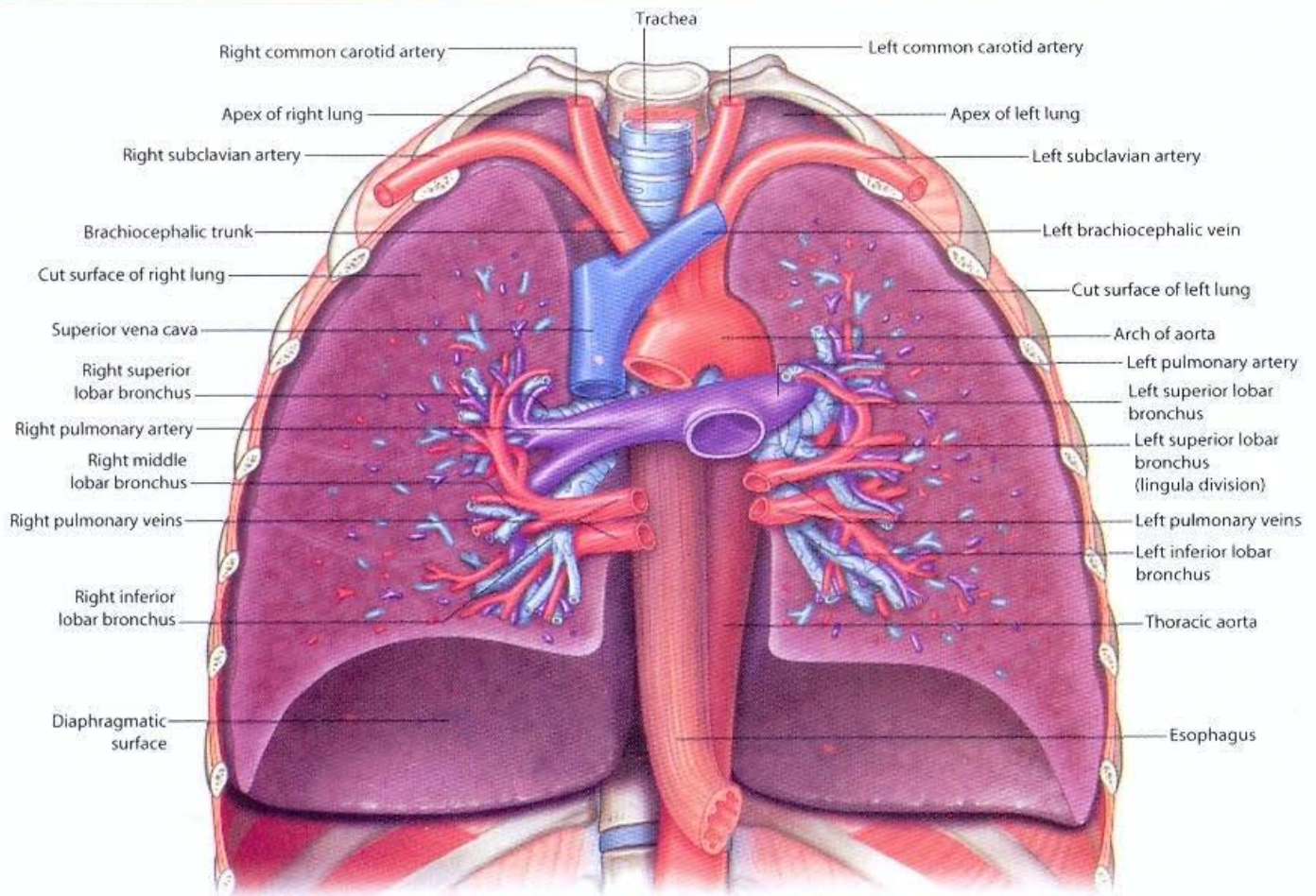


Right lung (lateral view)

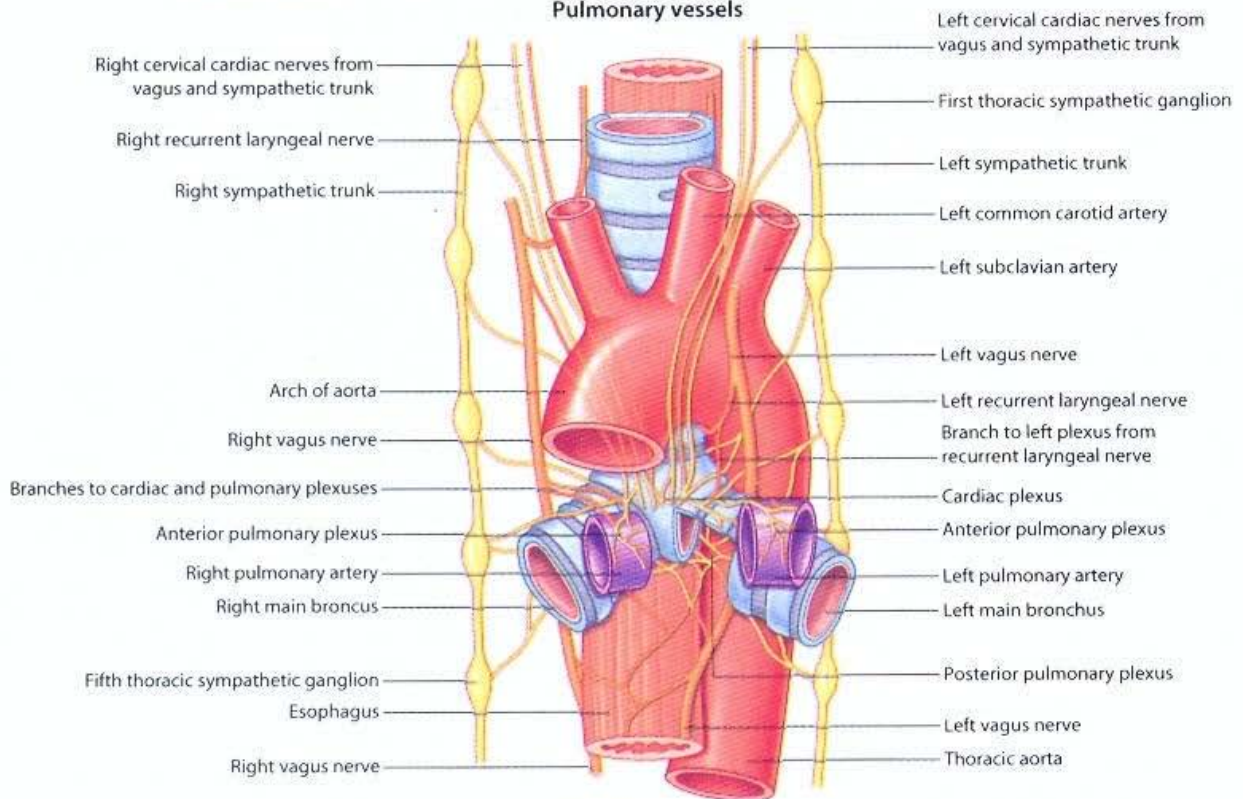


Left lung (lateral view)

Bronchopulmonary segments

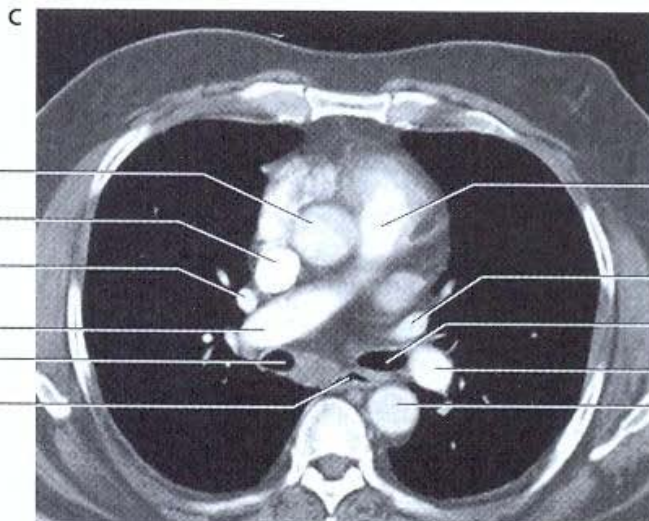

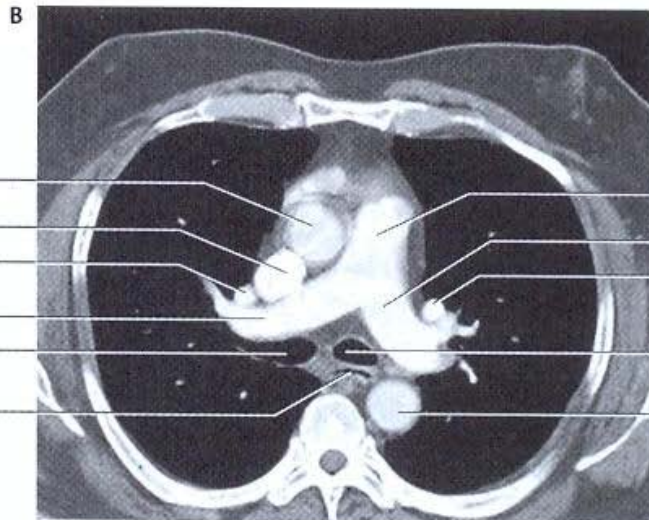
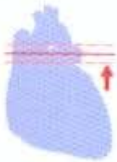
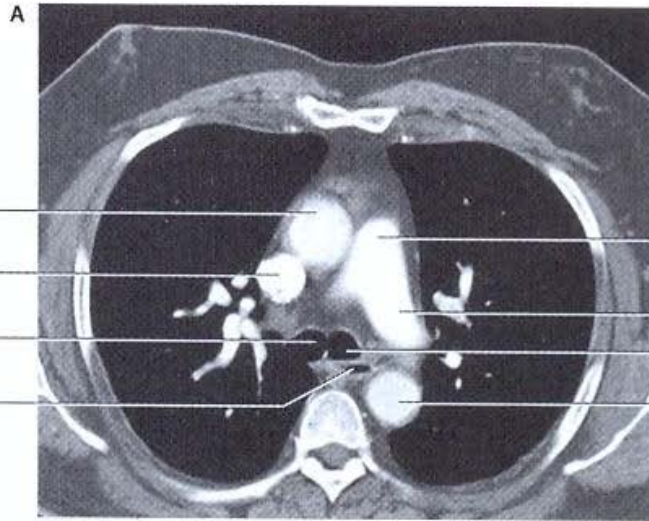


**Pulmonary vessels**

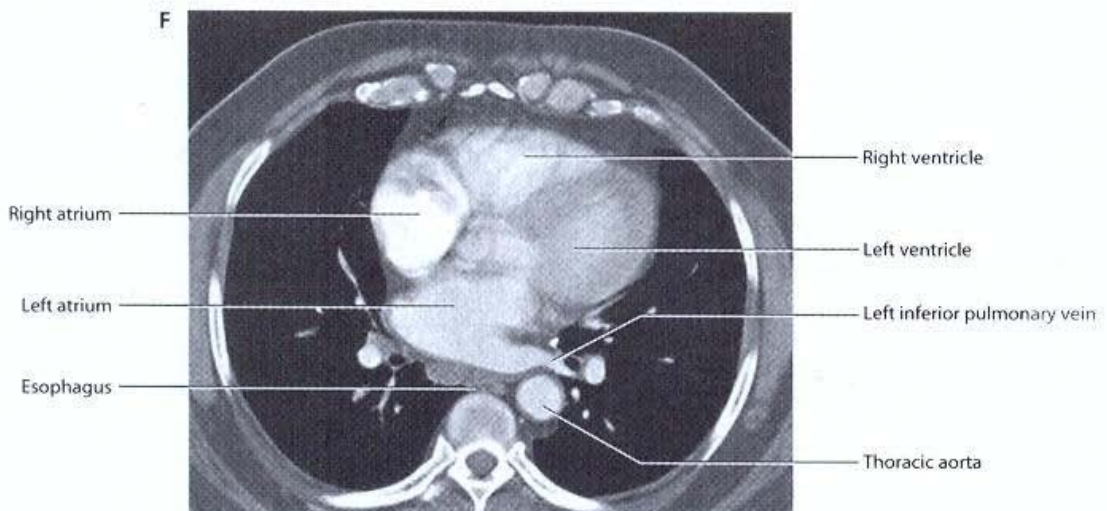
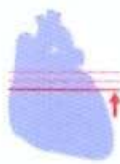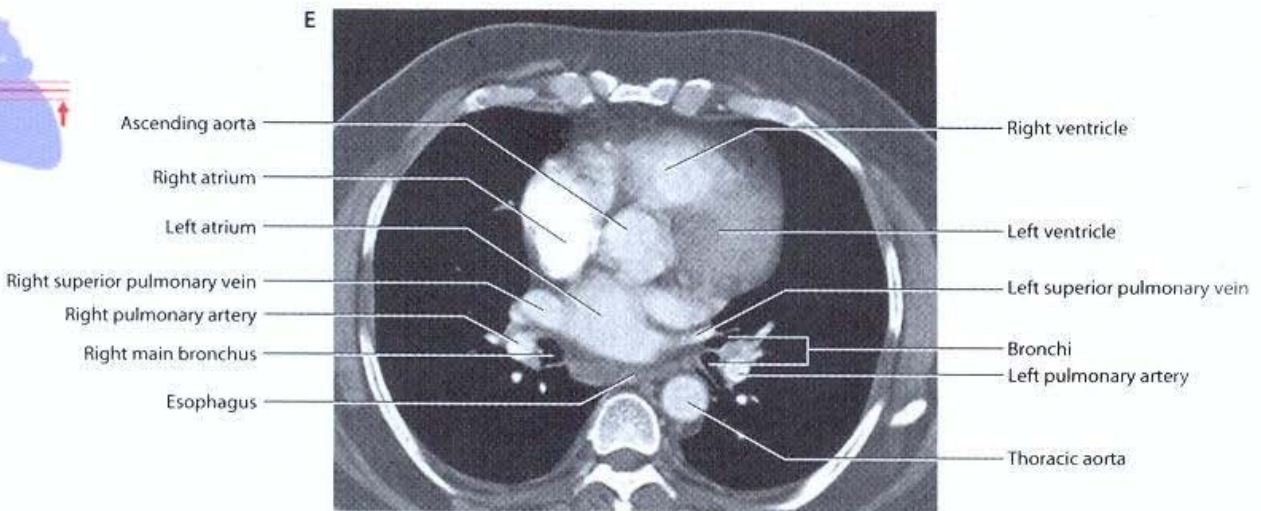
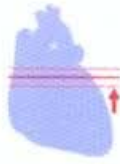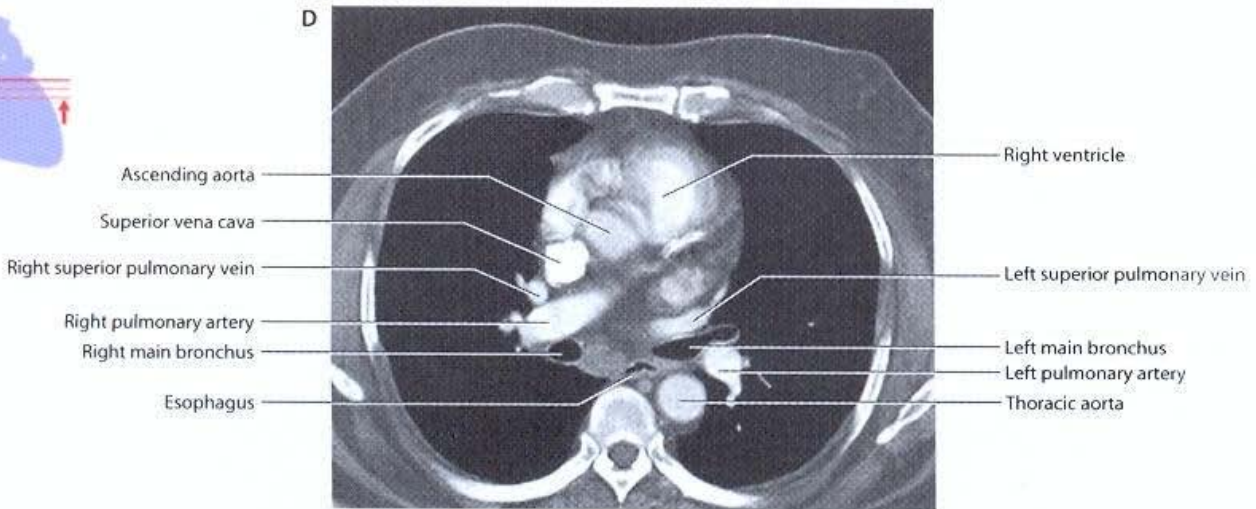


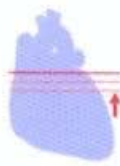**Pulmonary plexus**

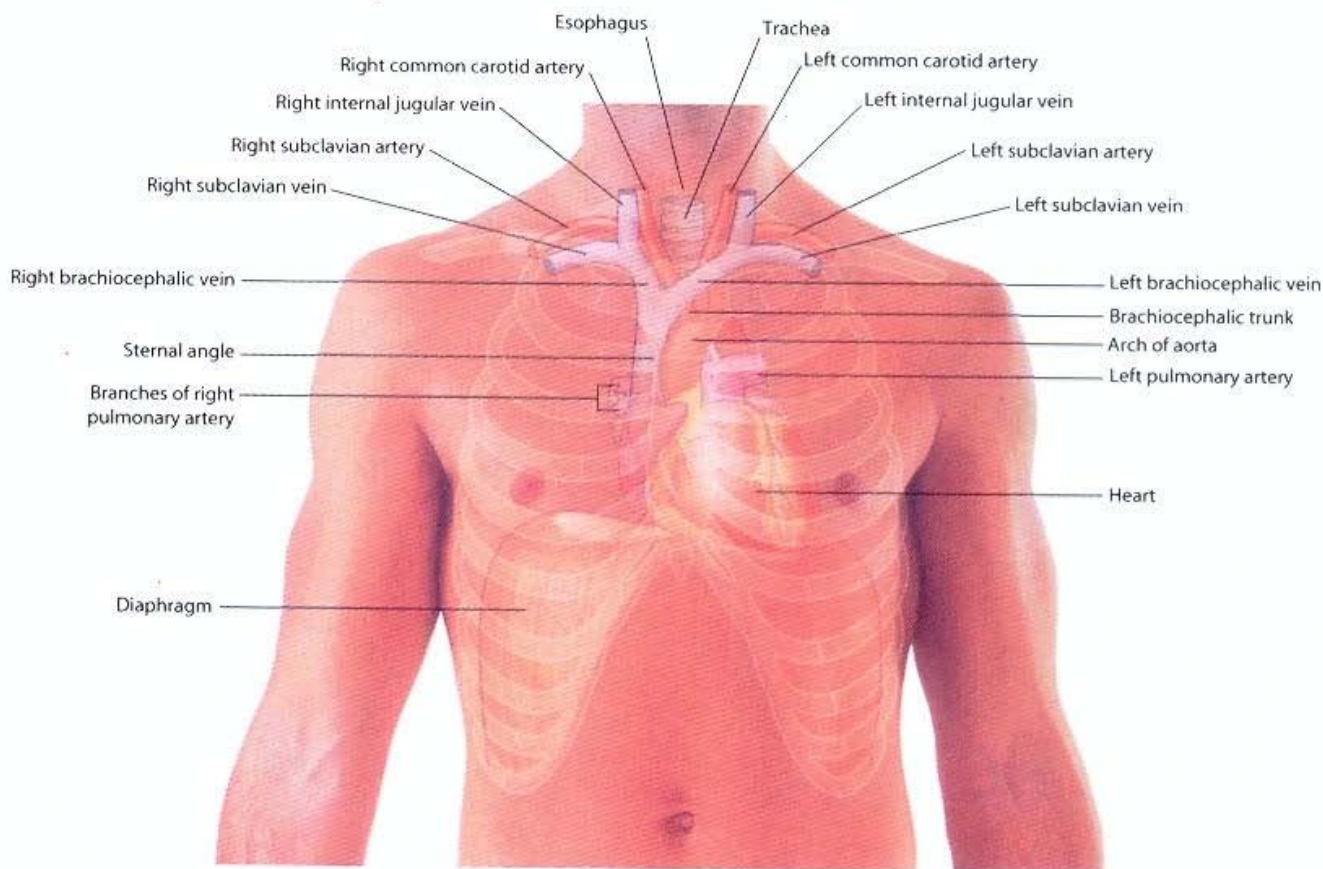




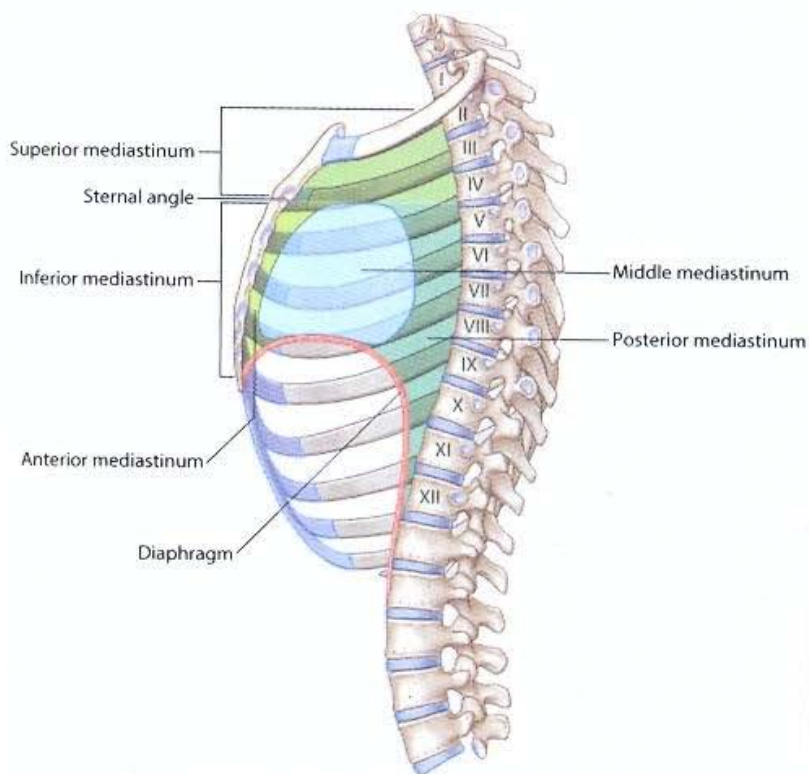
**A through C – Relationships of the pulmonary arteries, pulmonary veins, and bronchi in the mediastinum.**  
 CT images, with contrast, in axial plane



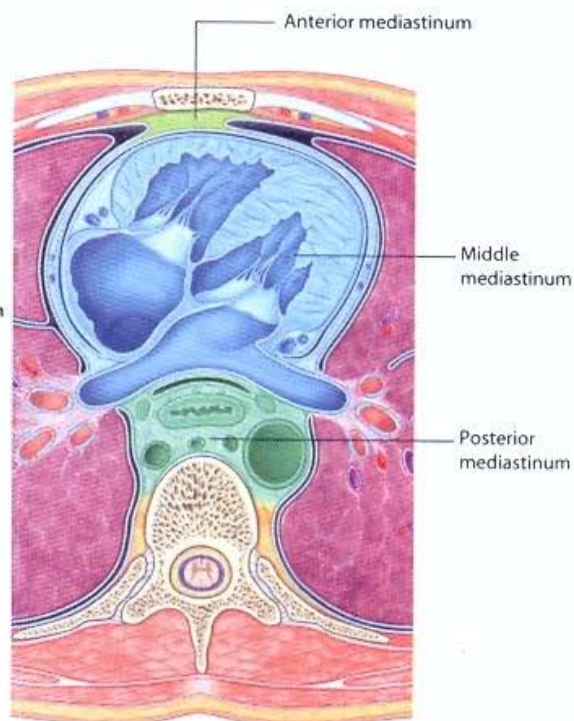
**D through F – Relationships of the pulmonary arteries, pulmonary veins, and bronchi in the mediastinum.**  
CT images, with contrast, in axial plane



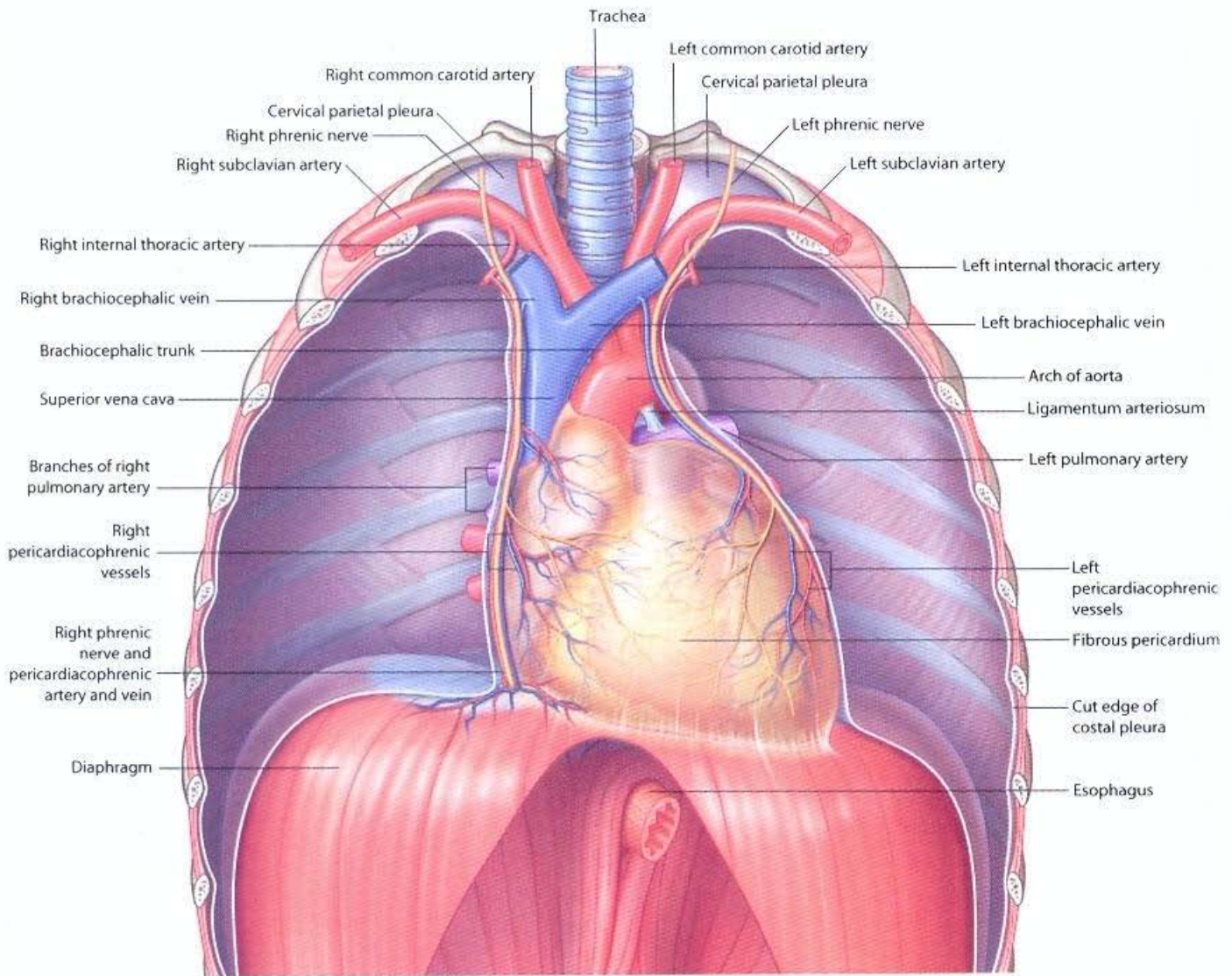
Structures of the mediastinum as they relate to the surface



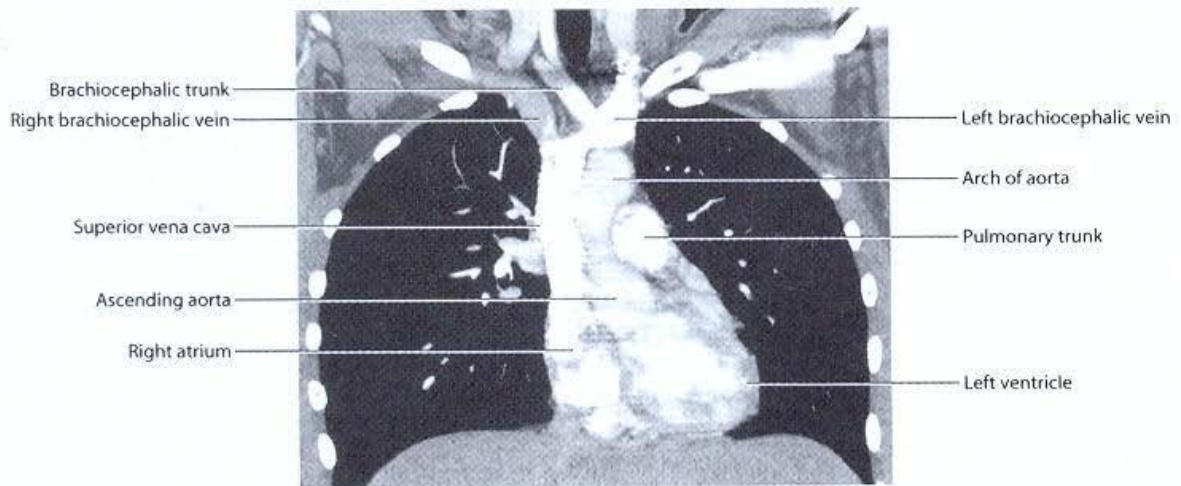
Subdivisions of the mediastinum (sagittal section)



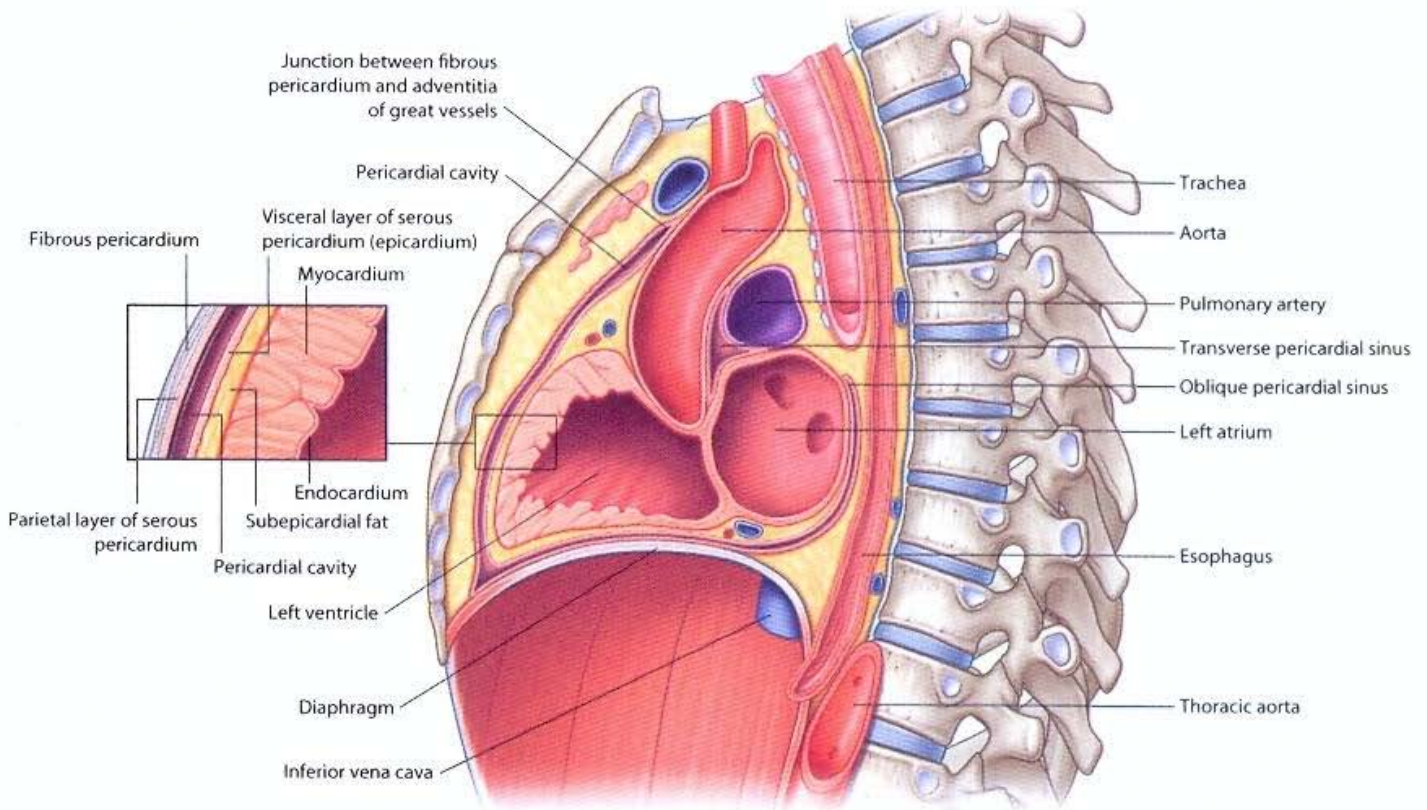
Subdivisions of the mediastinum (transverse section)



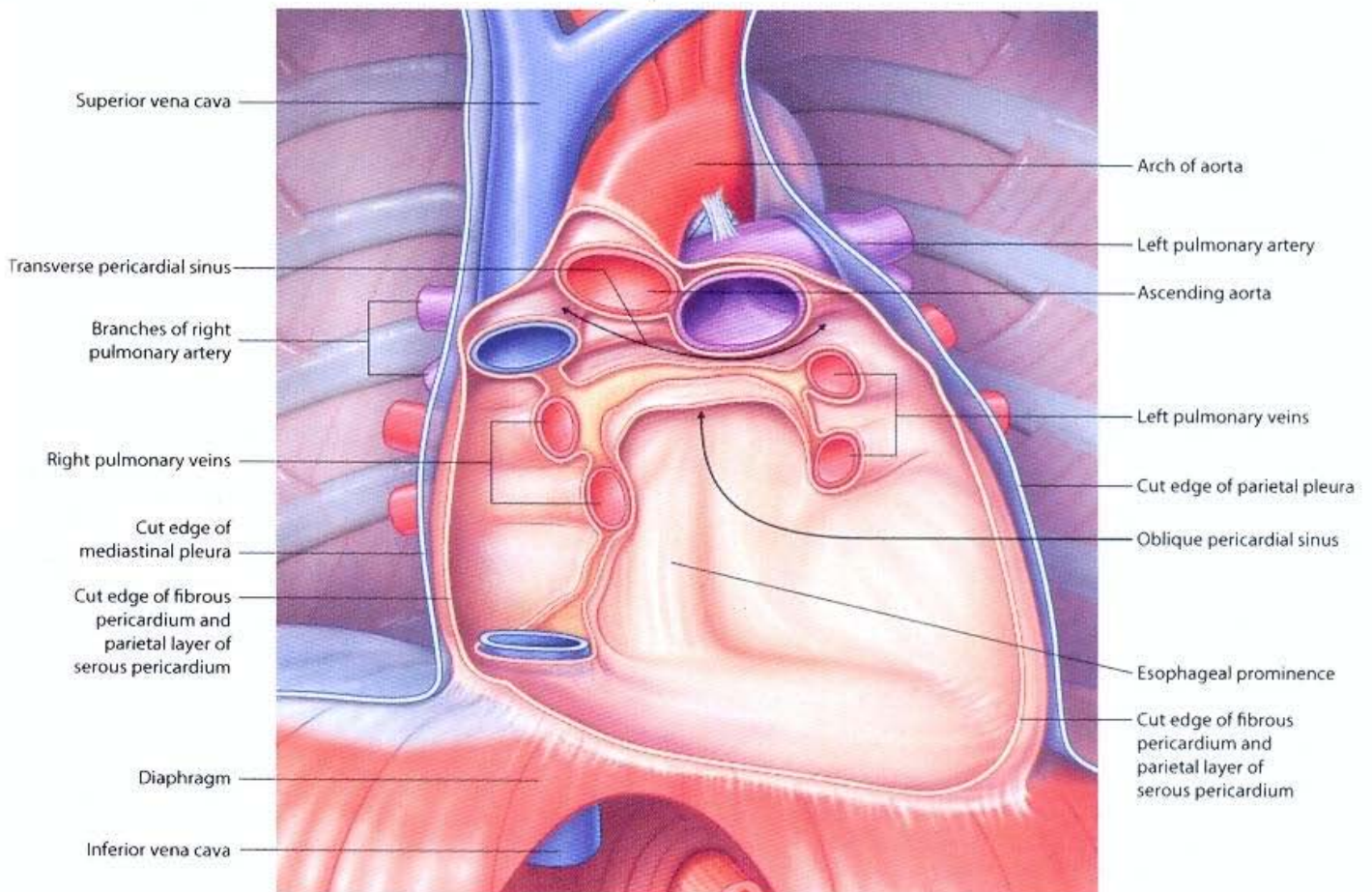
**Pericardium with nerves and vessels**



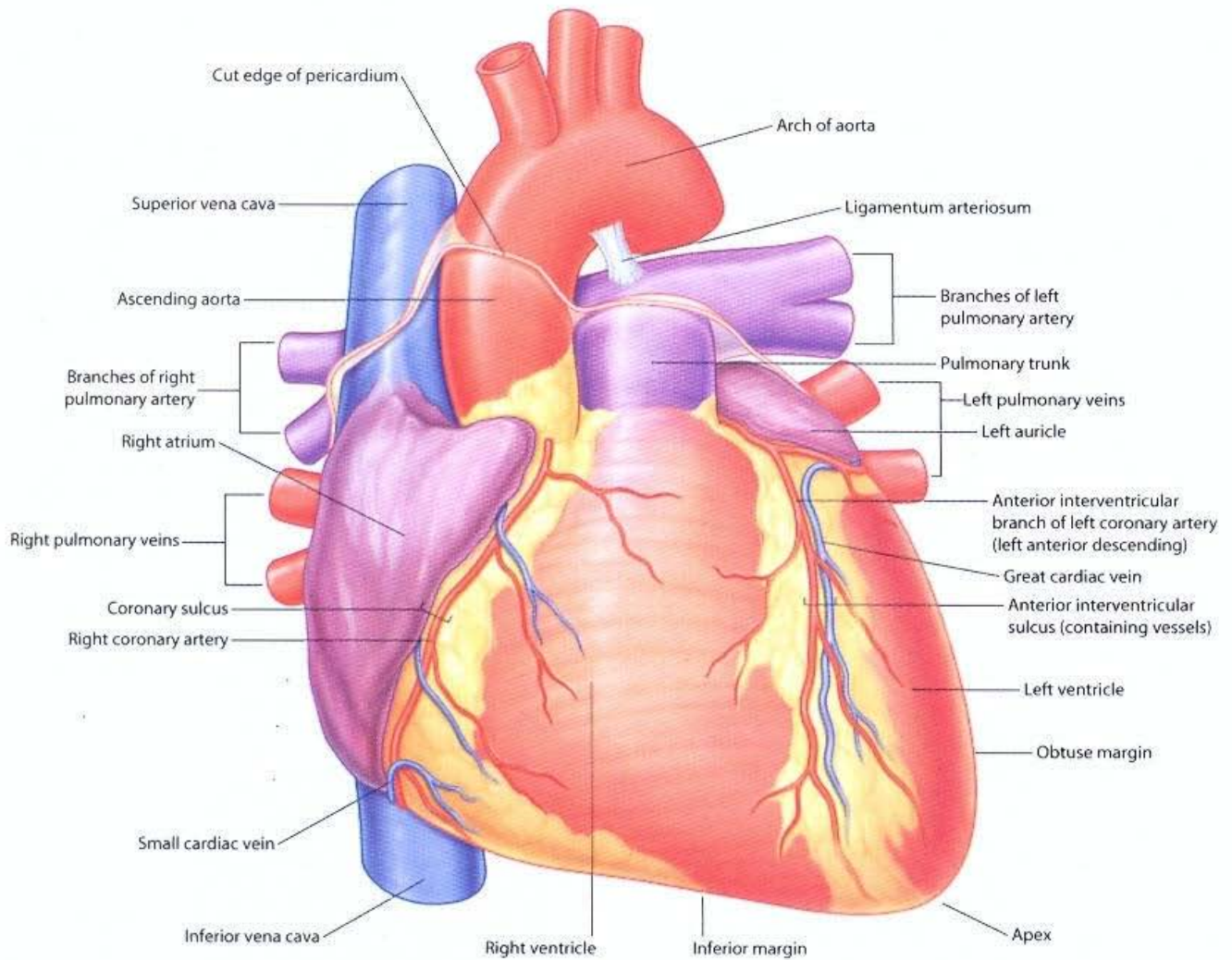
**Mediastinal structures and lungs.**  
CT image, with contrast, in coronal plane



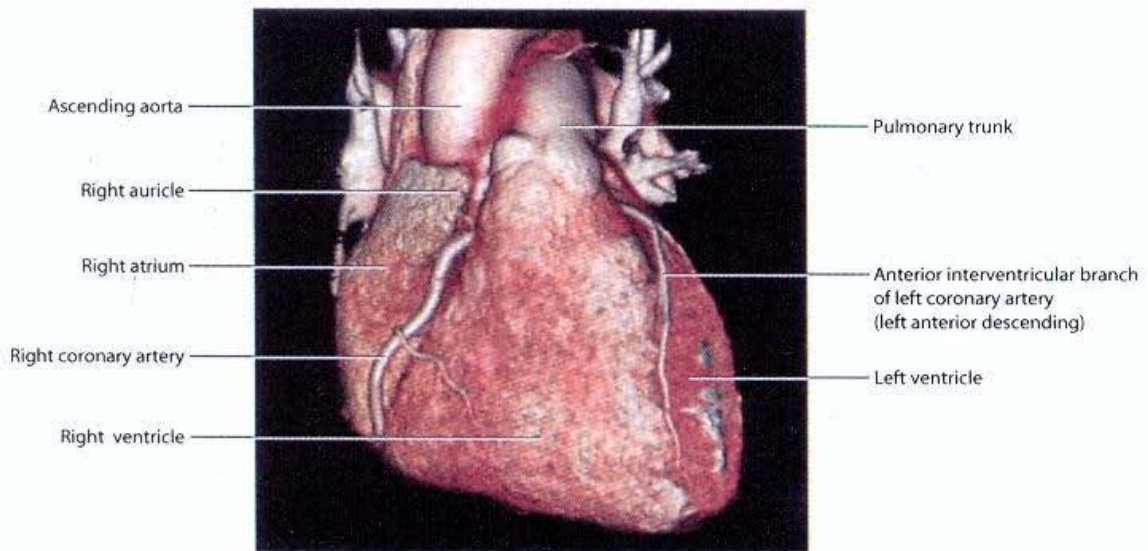
Sagittal section of the pericardium and heart



Pericardial sac with heart removed

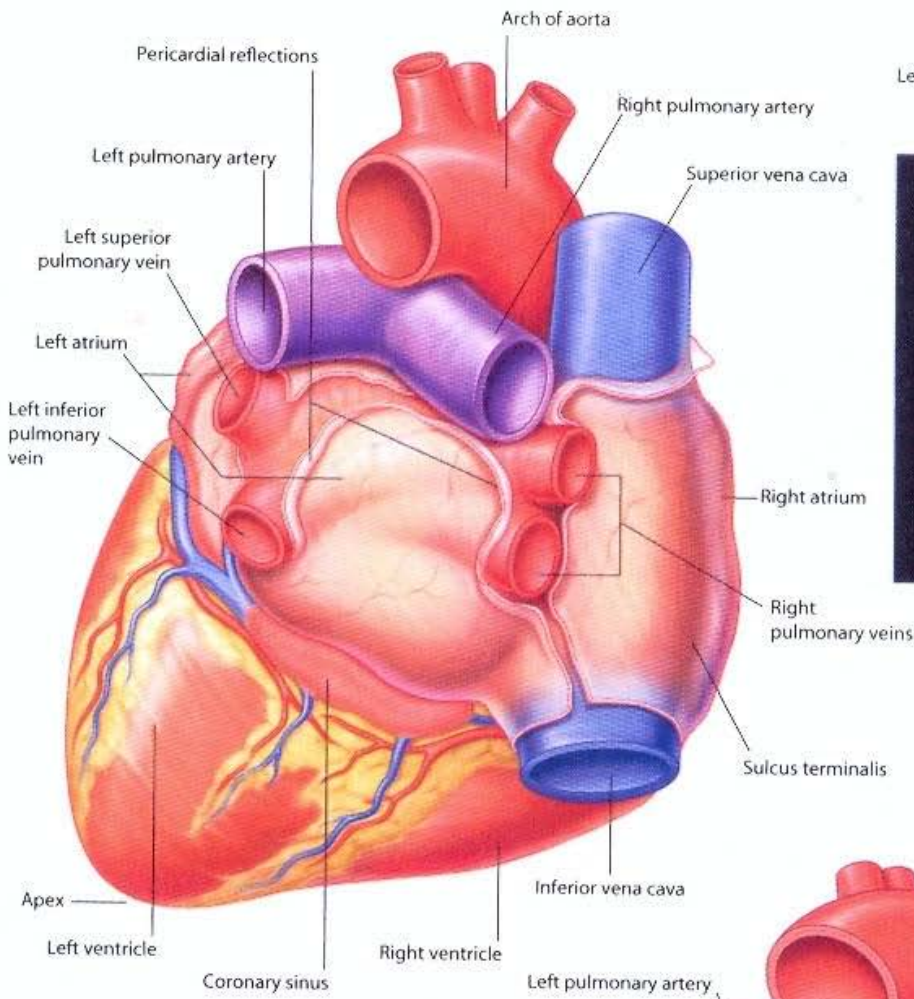


**Anterior surface of the heart**

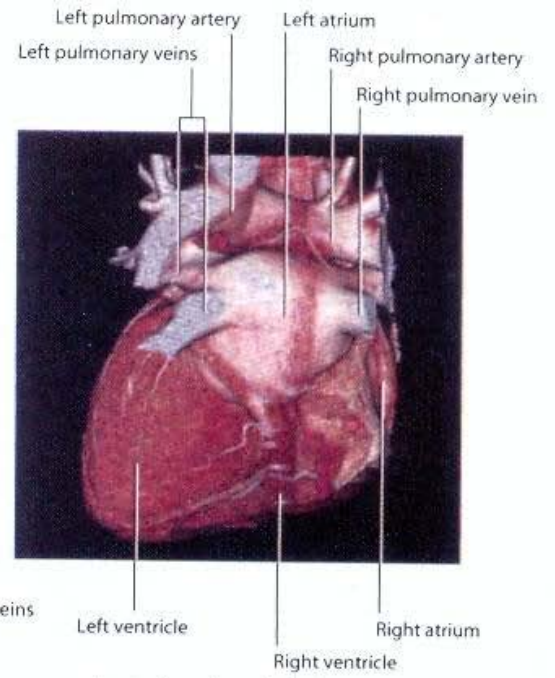


**Anterior view of the heart.**

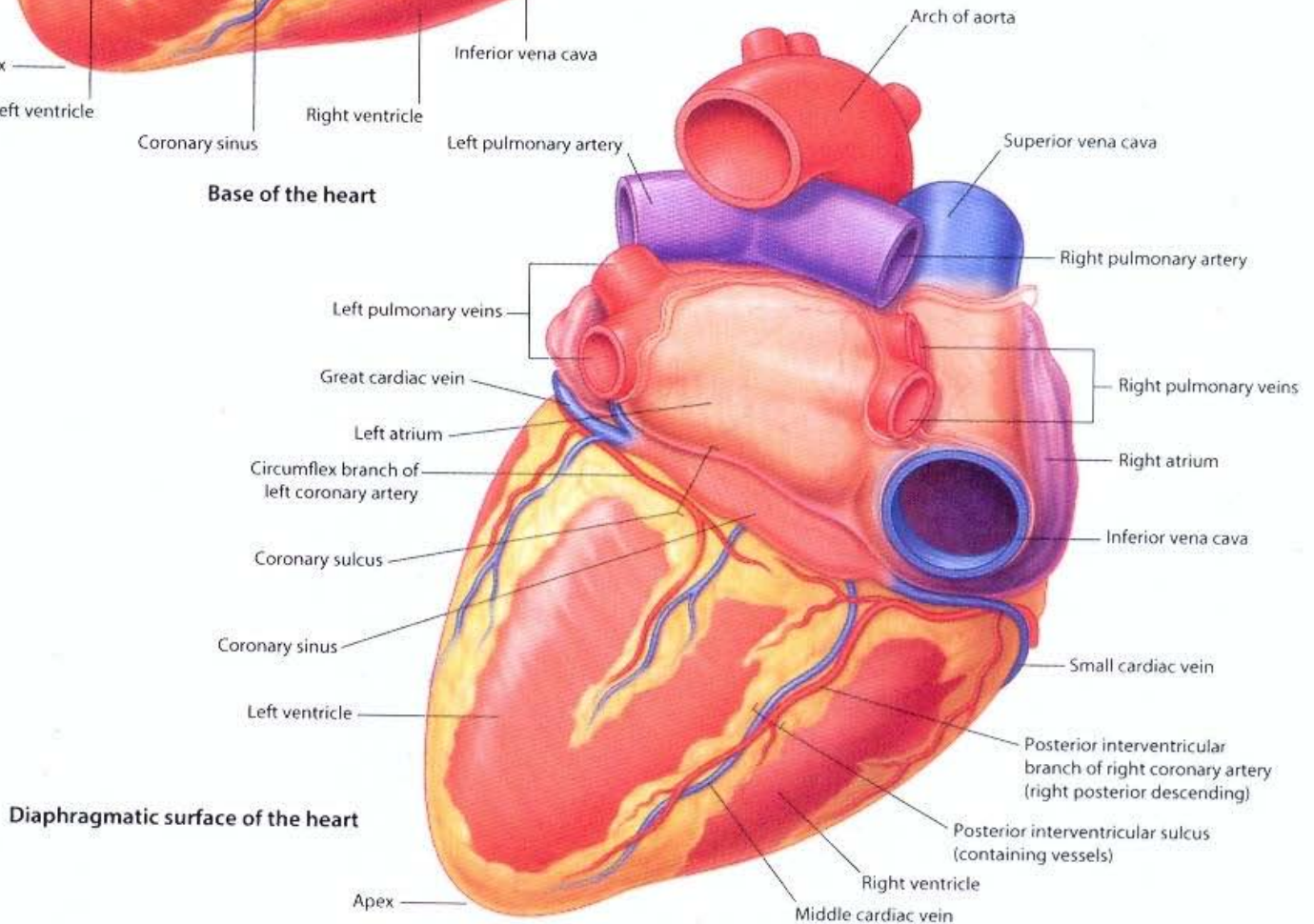
Volume-rendered anterior view using multidetector computed tomography



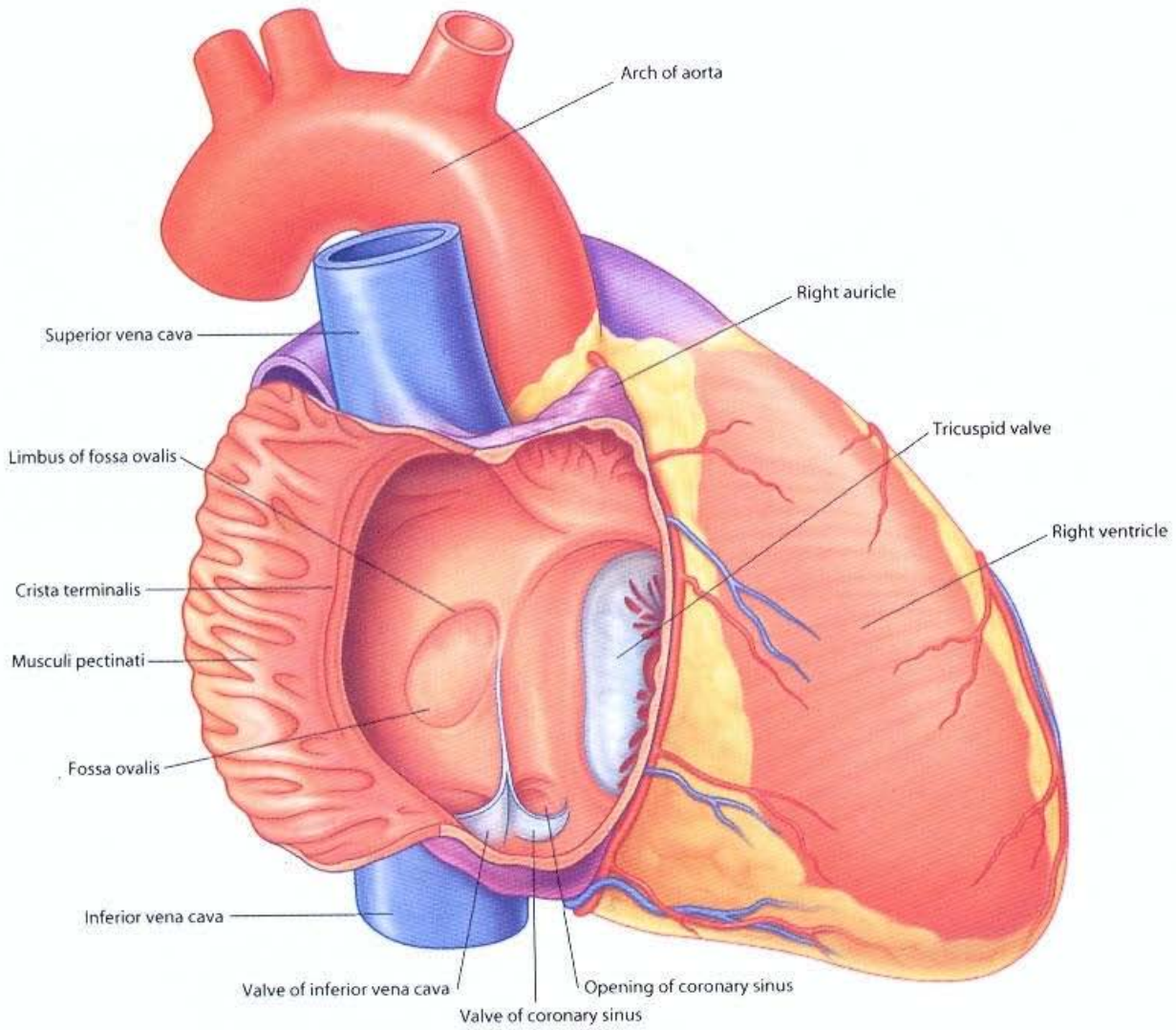
**Base of the heart**



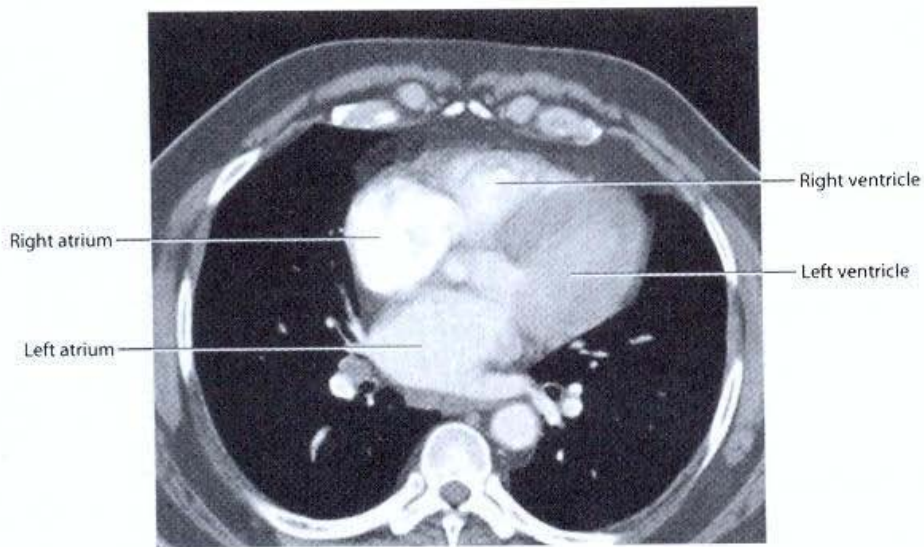
**Posterior view of the heart.**  
Volume-rendered posterior view using multidetector computed tomography



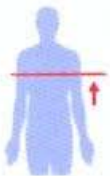
**Diaphragmatic surface of the heart**



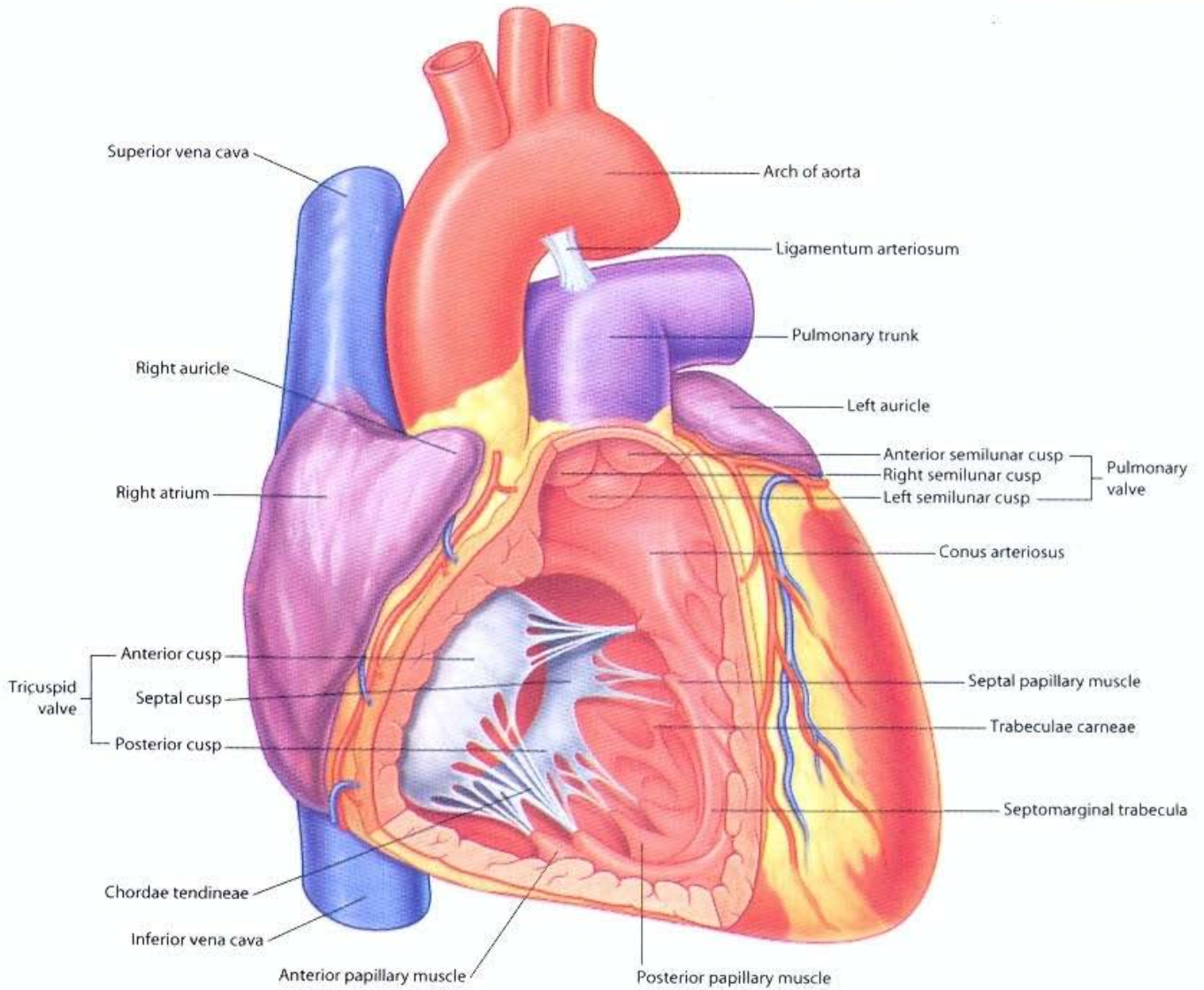
**Internal view of right atrium**



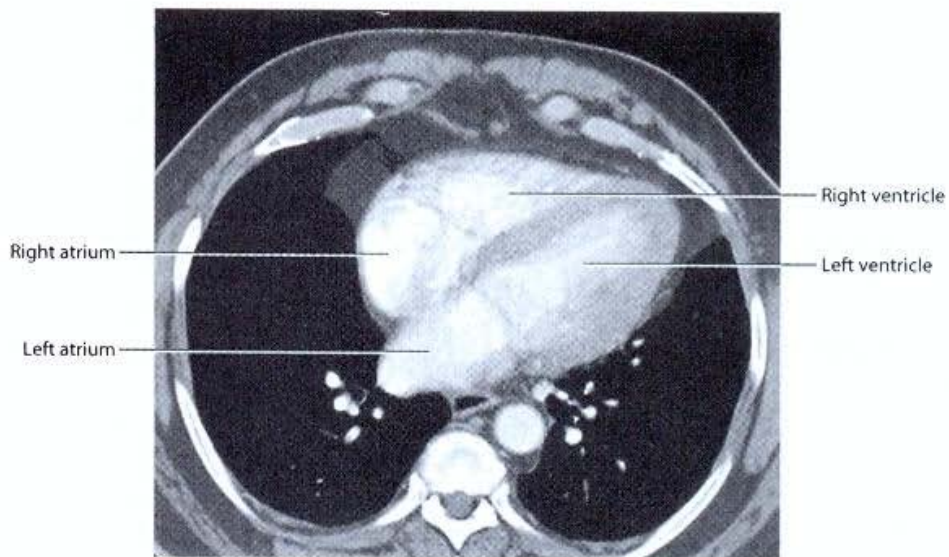
**Positioning of right atrium in relation to other cardiac chambers.**  
CT image, with contrast, in axial plane



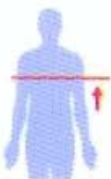


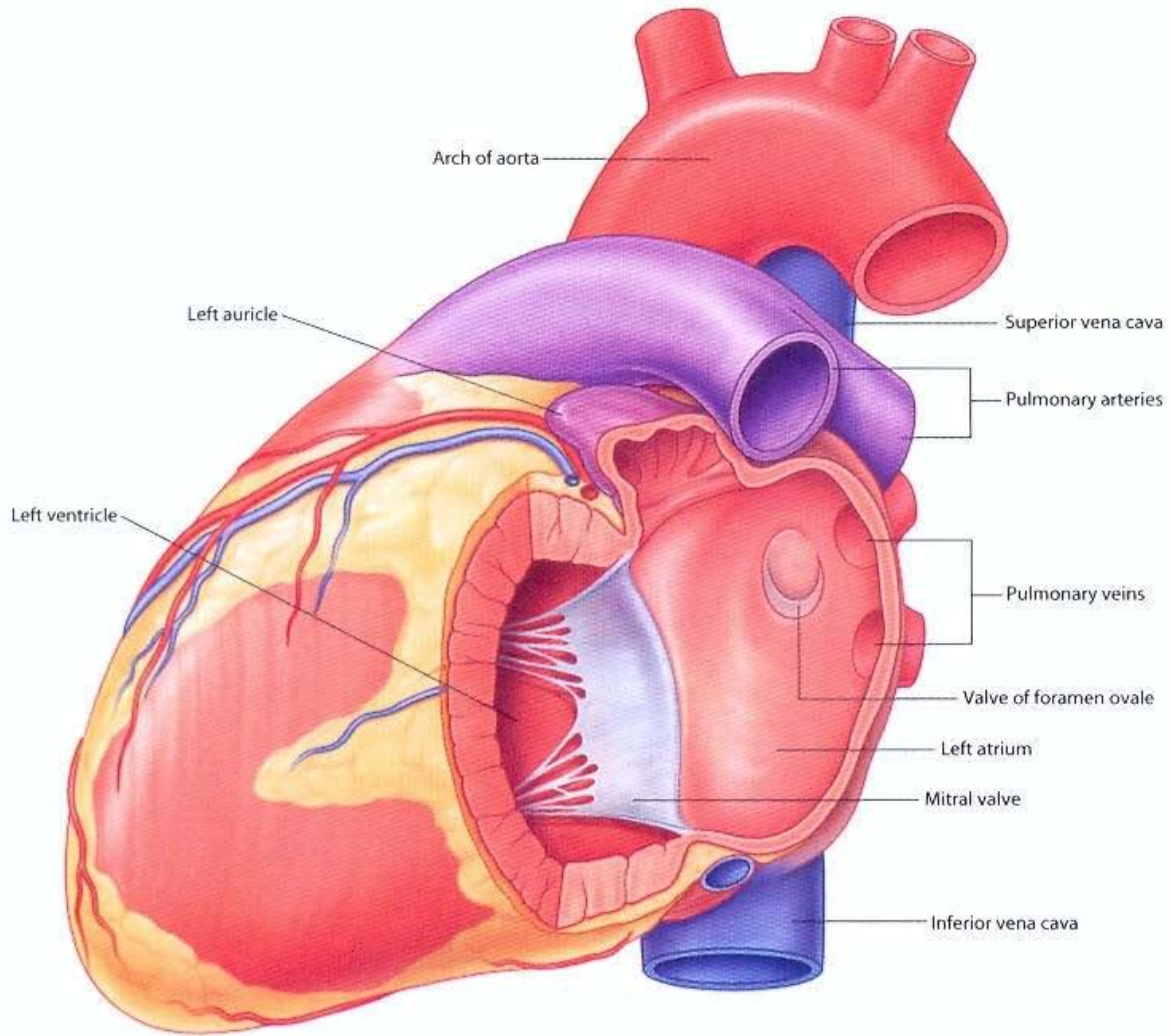


Internal view of right ventricle

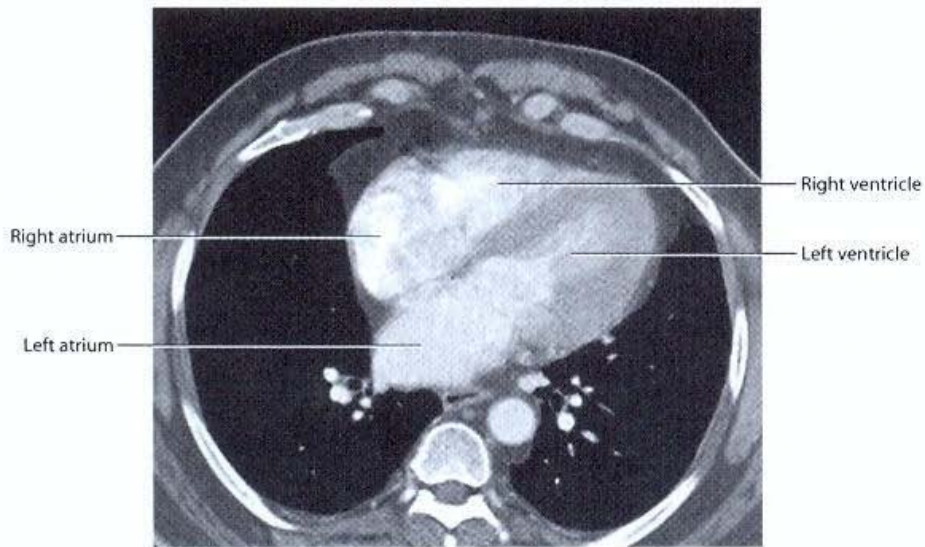


Positioning of right ventricle in relation to other cardiac chambers.  
CT image, with contrast, in axial plane

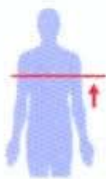


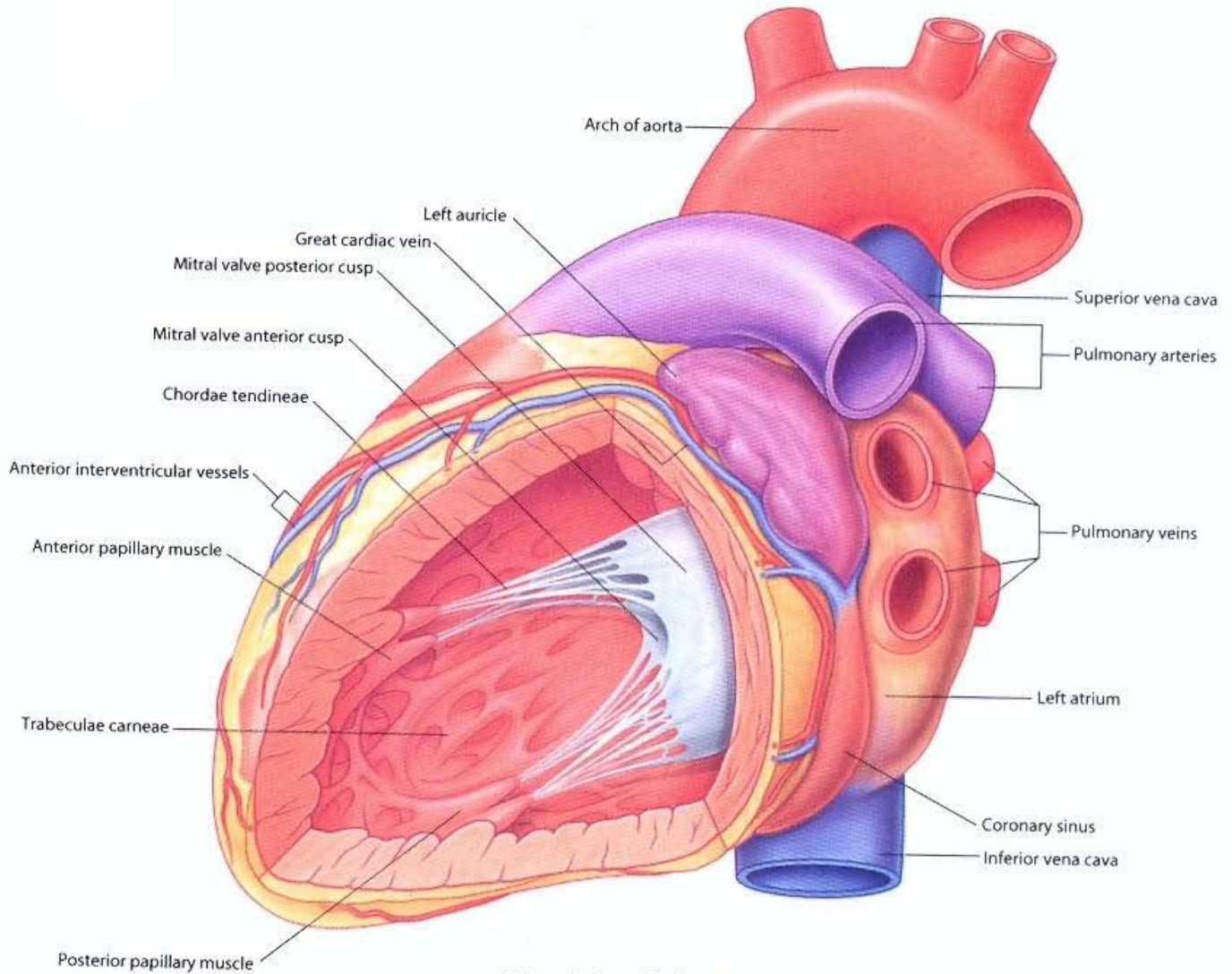


Internal view of left atrium

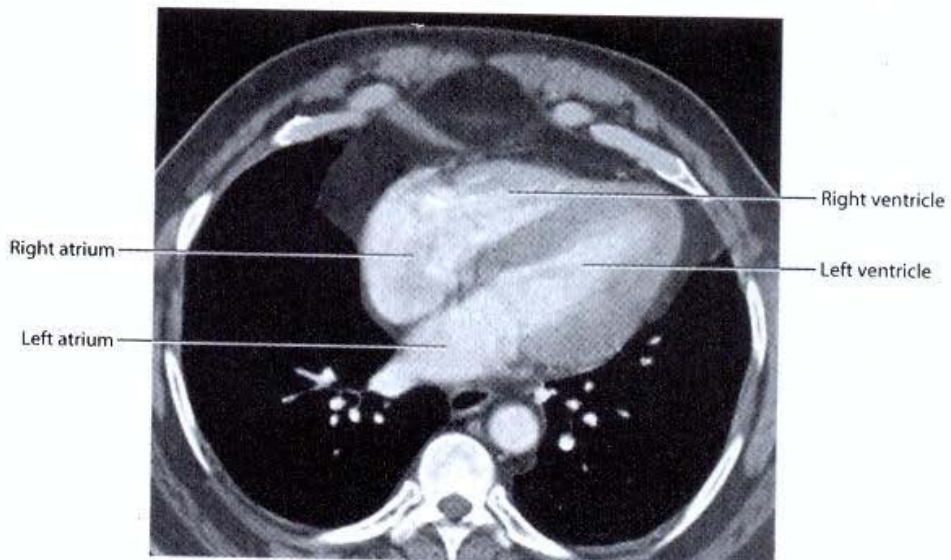


Positioning of left atrium in relation to other cardiac chambers.  
CT image, with contrast, in axial plane

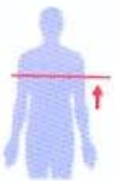


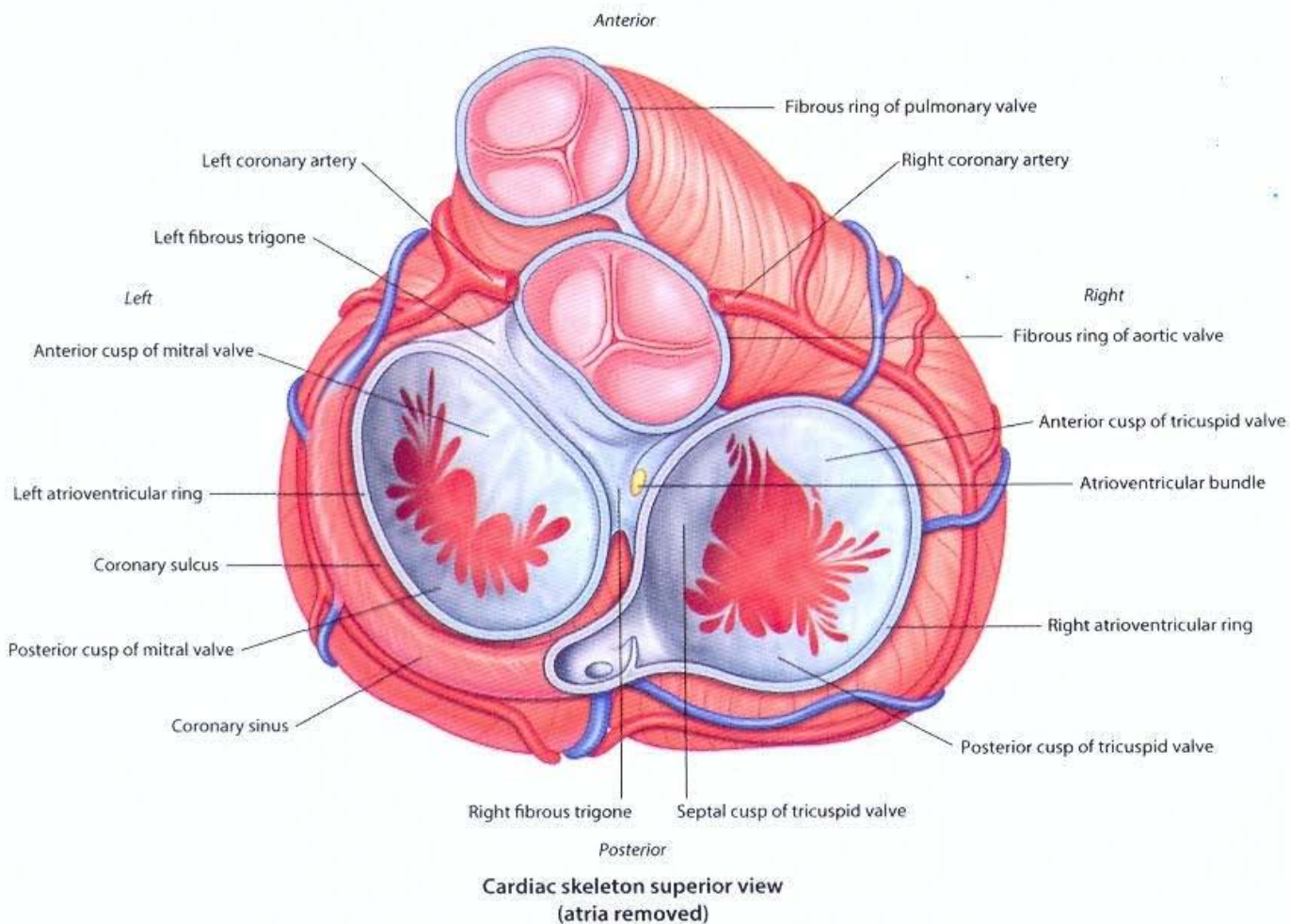
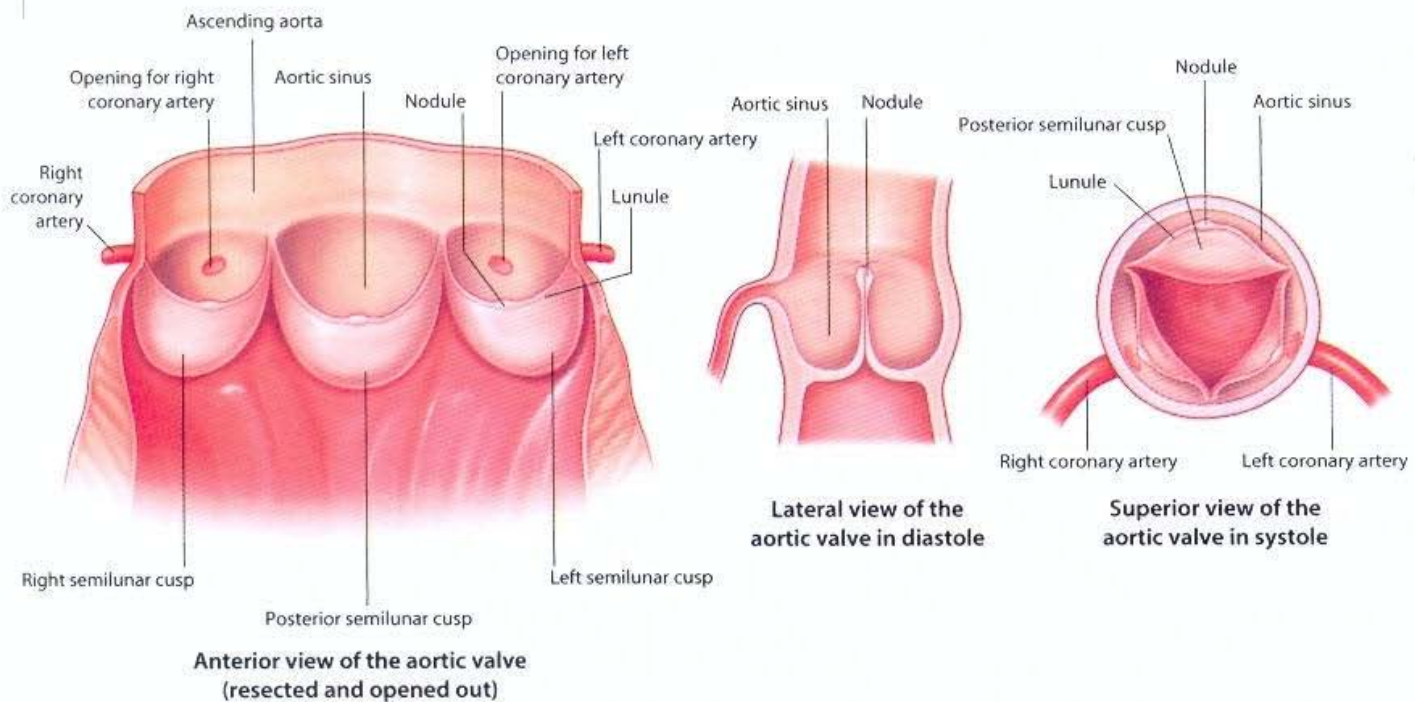


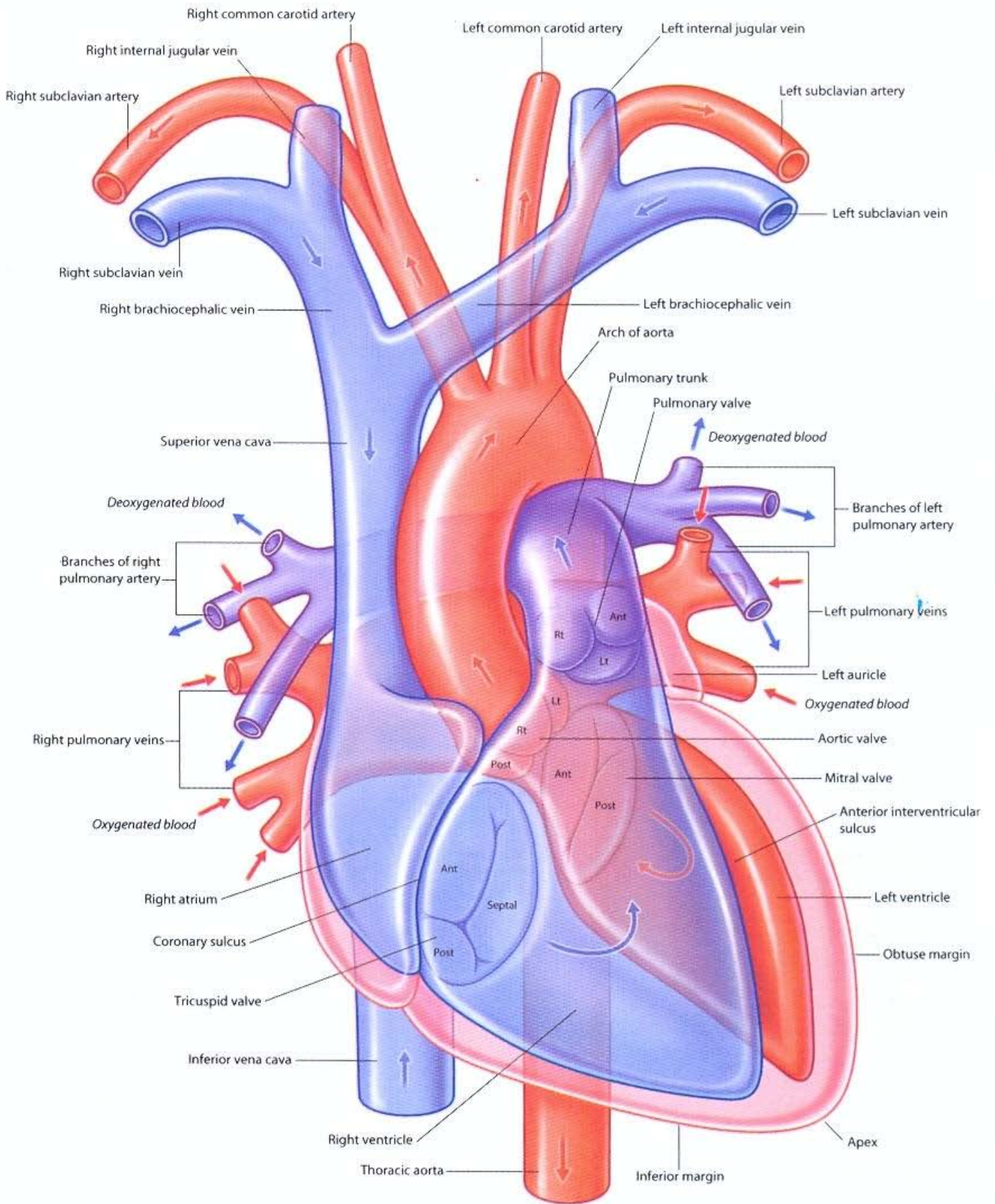
Internal view of left ventricle



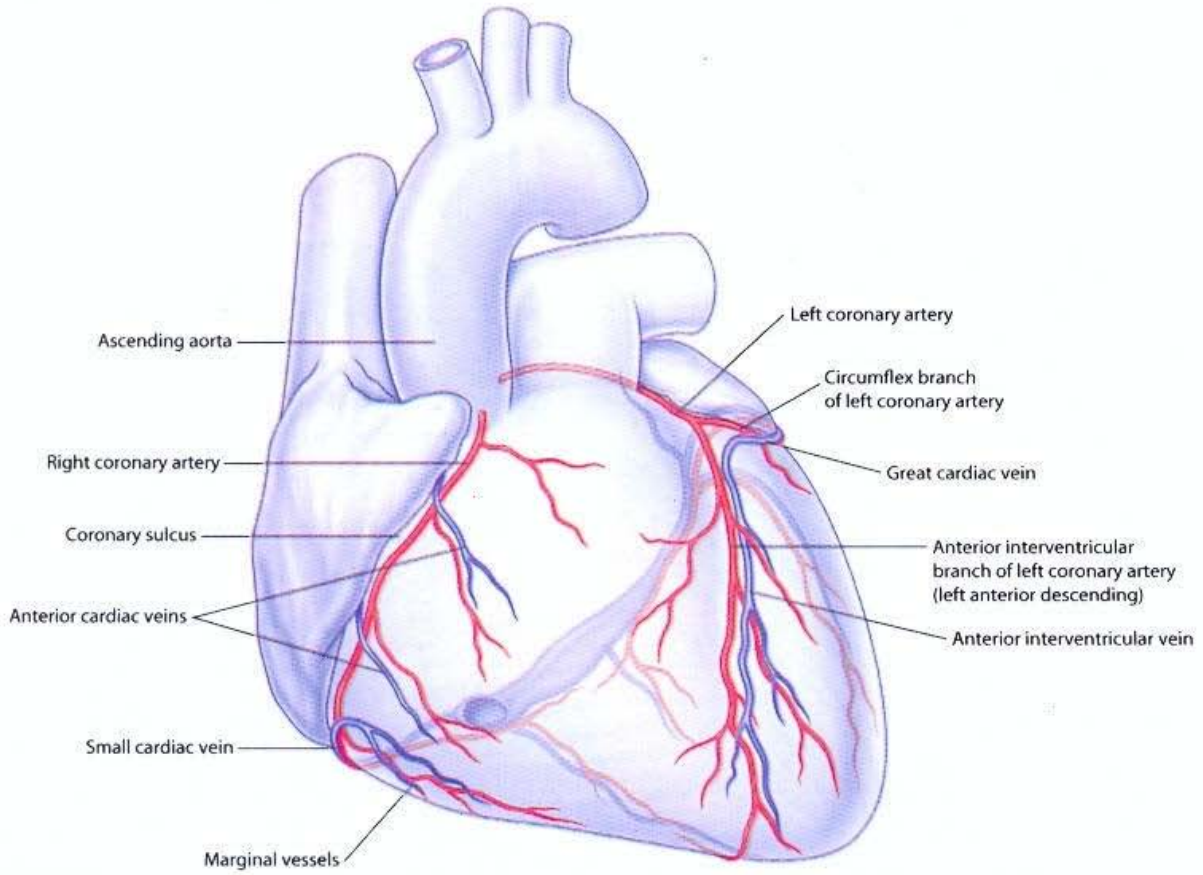
Positioning of left ventricle in relation to other cardiac chambers.  
CT image, with contrast, in axial plane



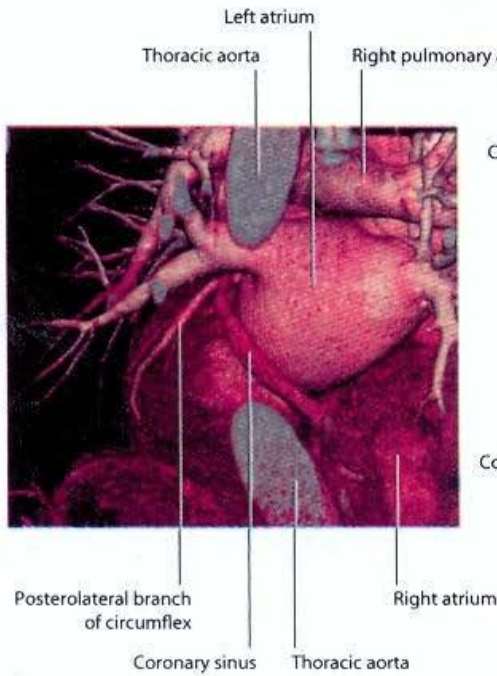




Cardiac chambers and direction of blood flow

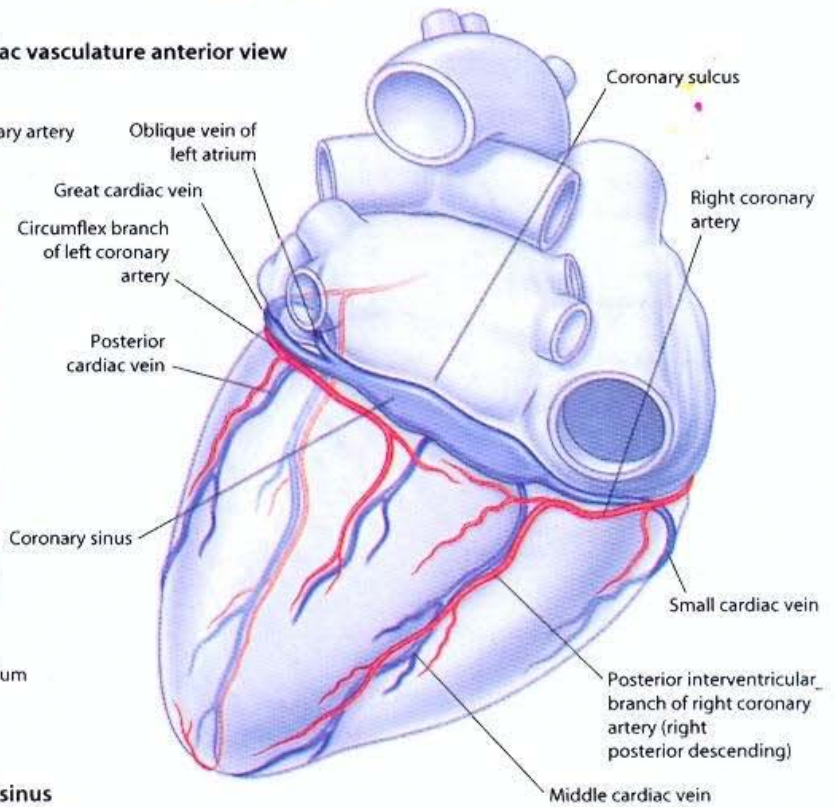


**Cardiac vasculature anterior view**

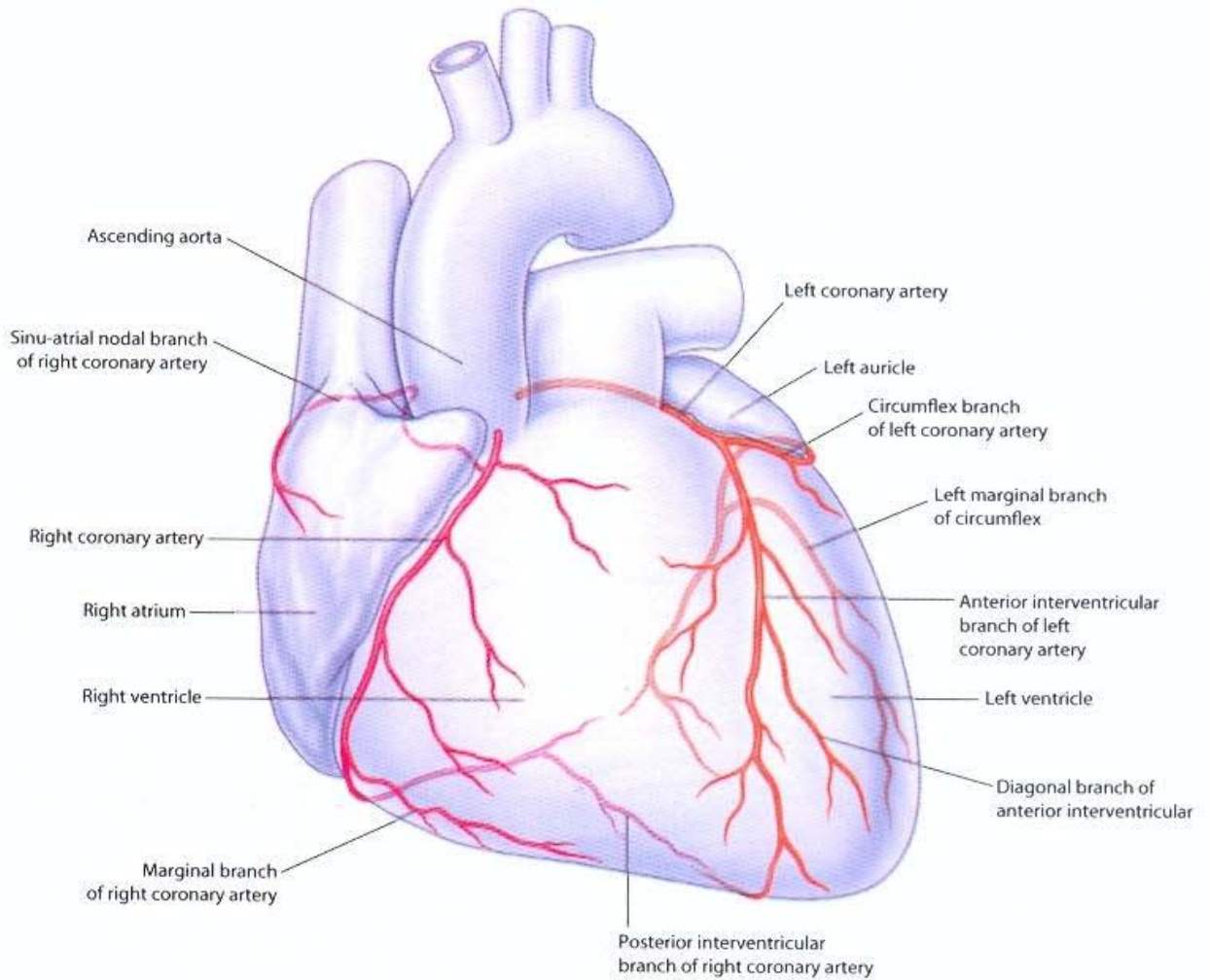


**Posterior view of the heart showing the coronary sinus**

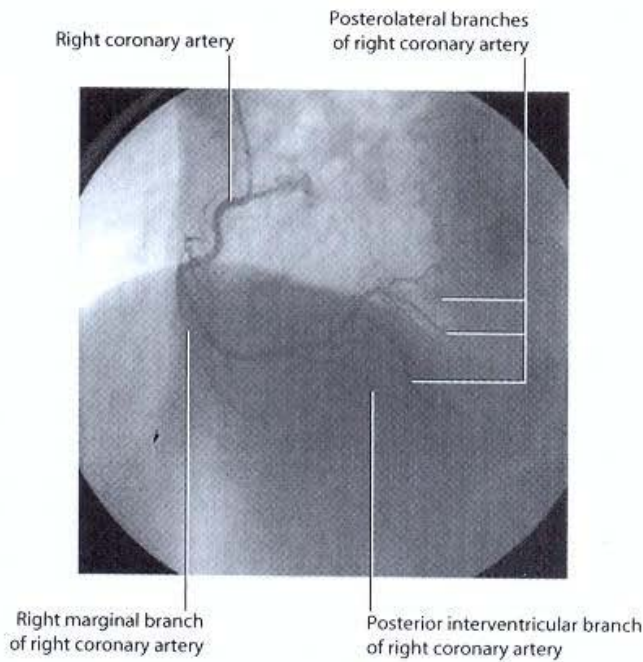
Volume-rendered posterior view using multidetector computed tomography



**Posteroinferior view**

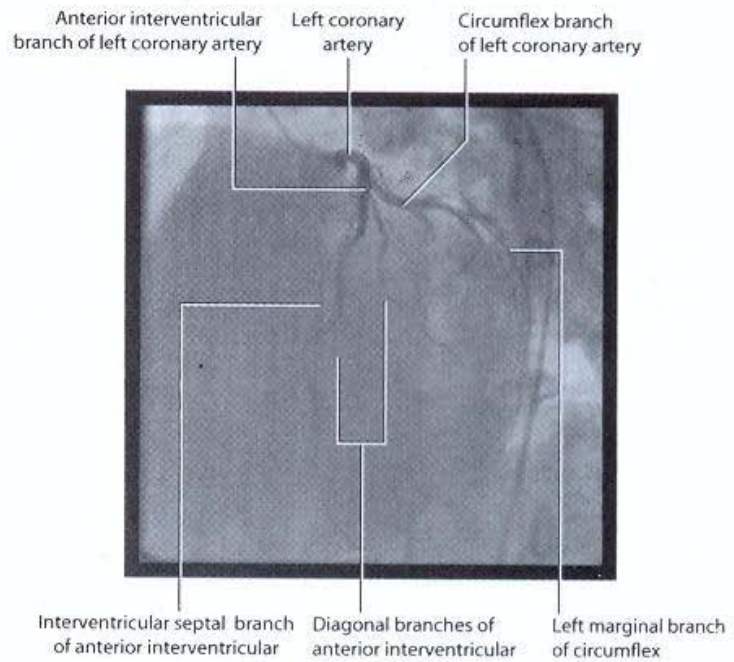


**Coronary arteries (right dominant system)**



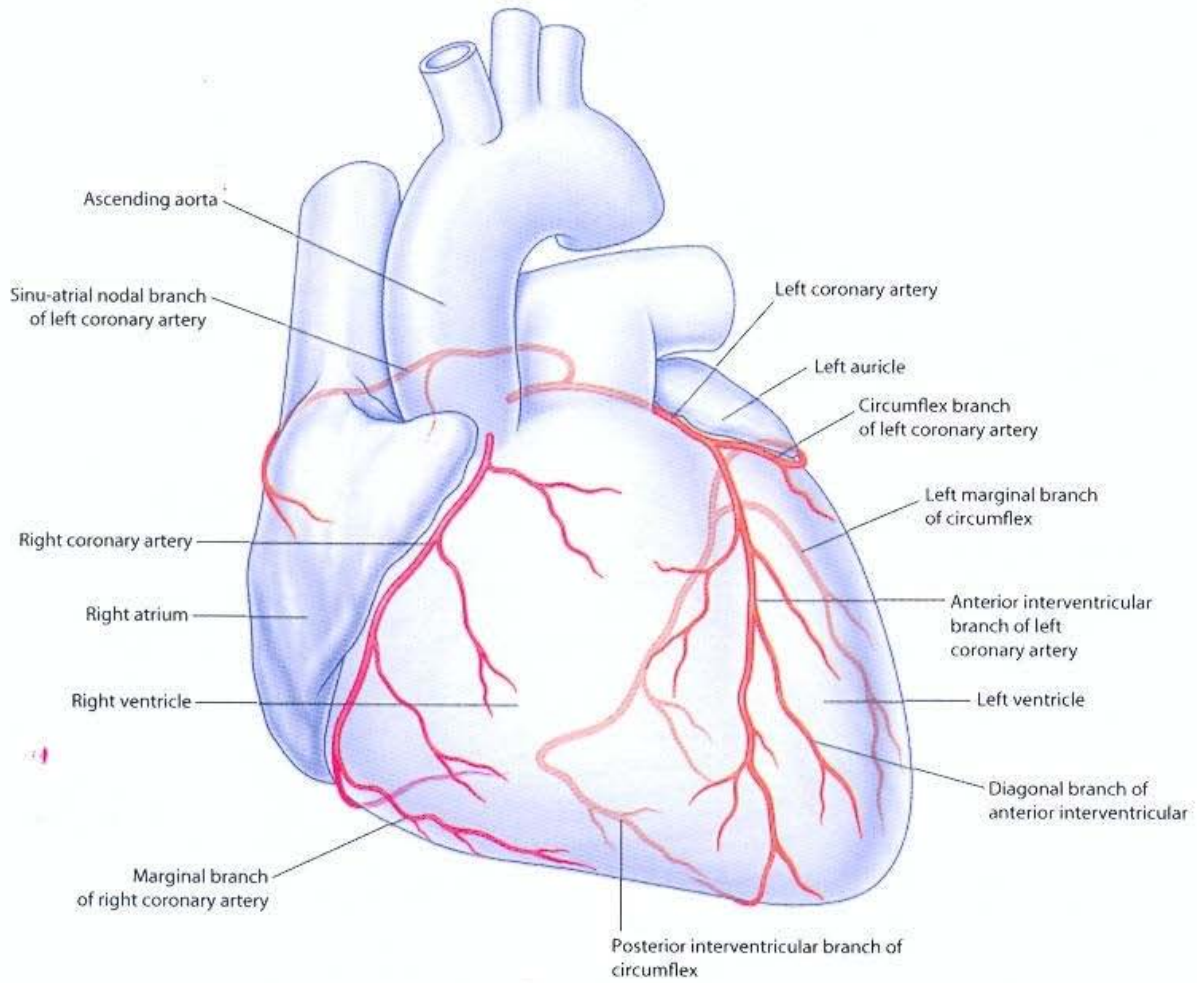
**Coronary angiography (right dominant system).**

Left anterior oblique projection, cranial angulation, of right coronary artery

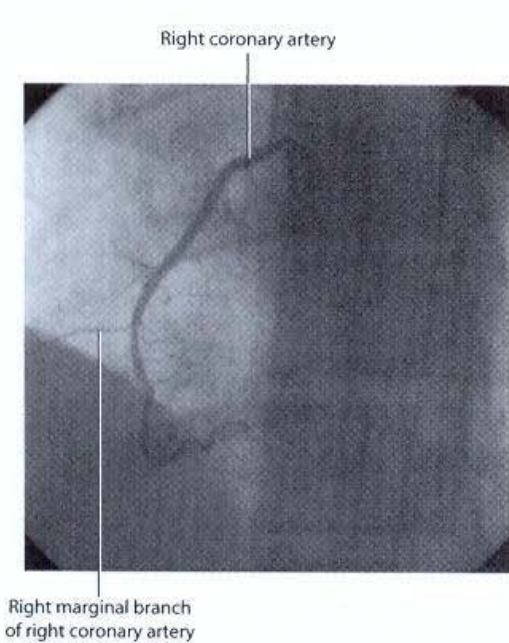


**Coronary angiography (right dominant system).**

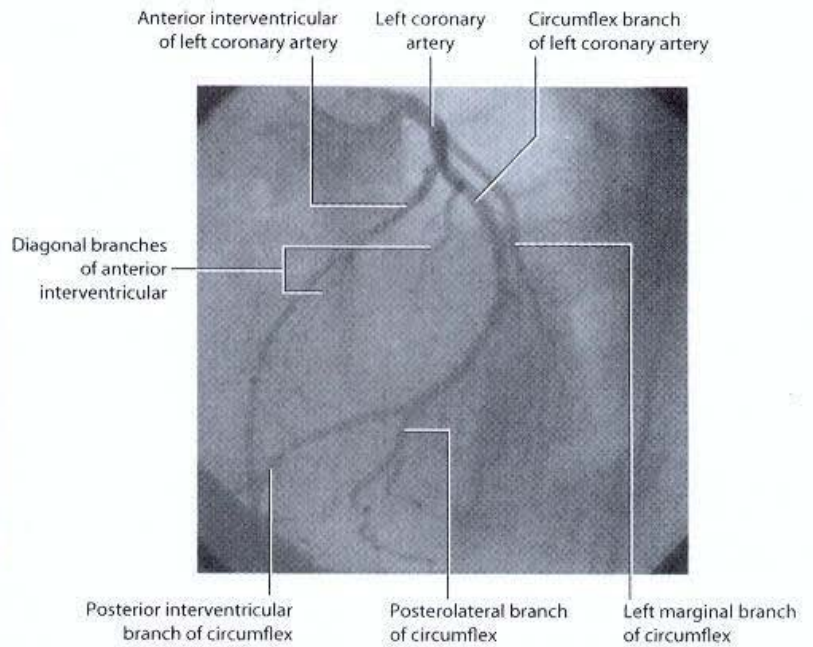
Left anterior oblique projection, cranial angulation, of left coronary artery



**Coronary arteries (left dominant system)**

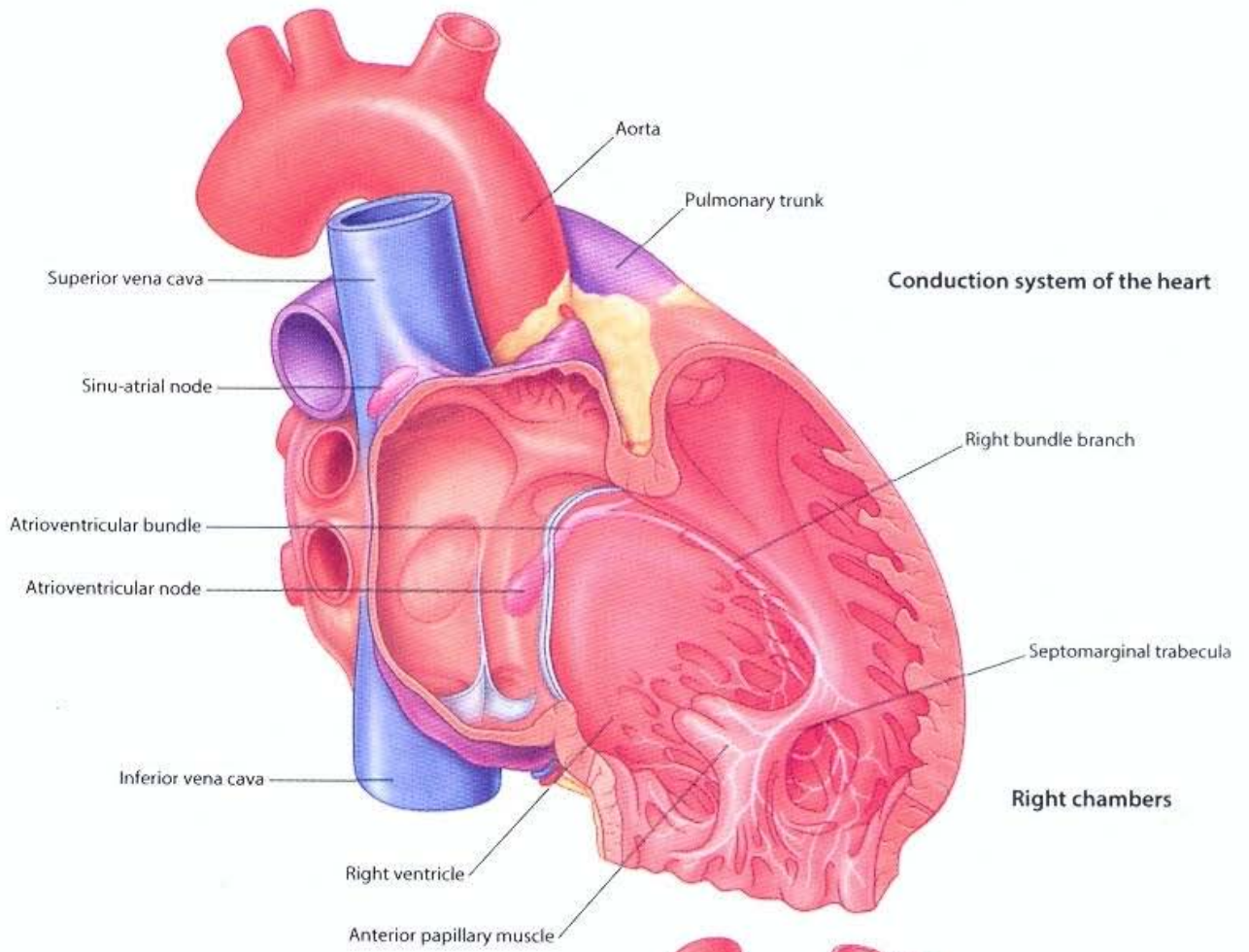


**Coronary angiography (left dominant system).**  
Left anterior oblique projection, cranial angulation, of right coronary artery

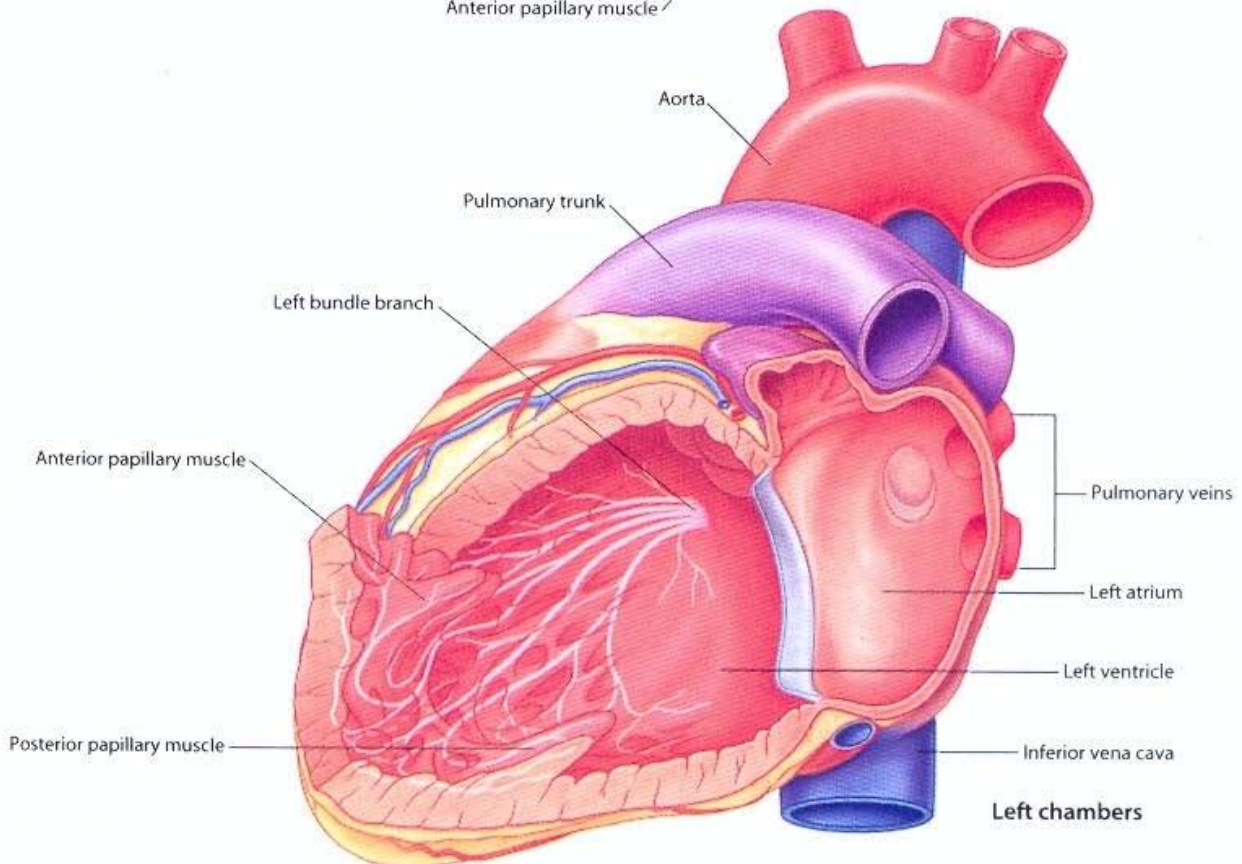


**Coronary angiography (left dominant system).**  
Left anterior oblique projection, cranial angulation, of left coronary artery



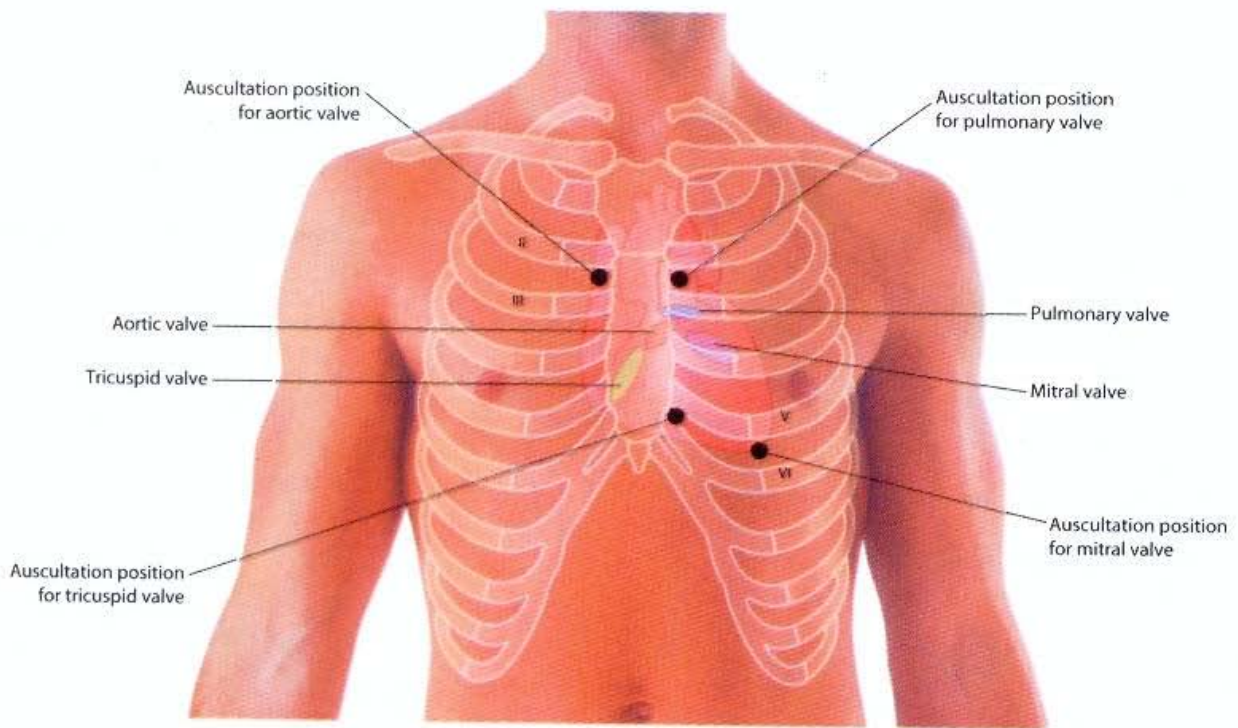


**Right chambers**

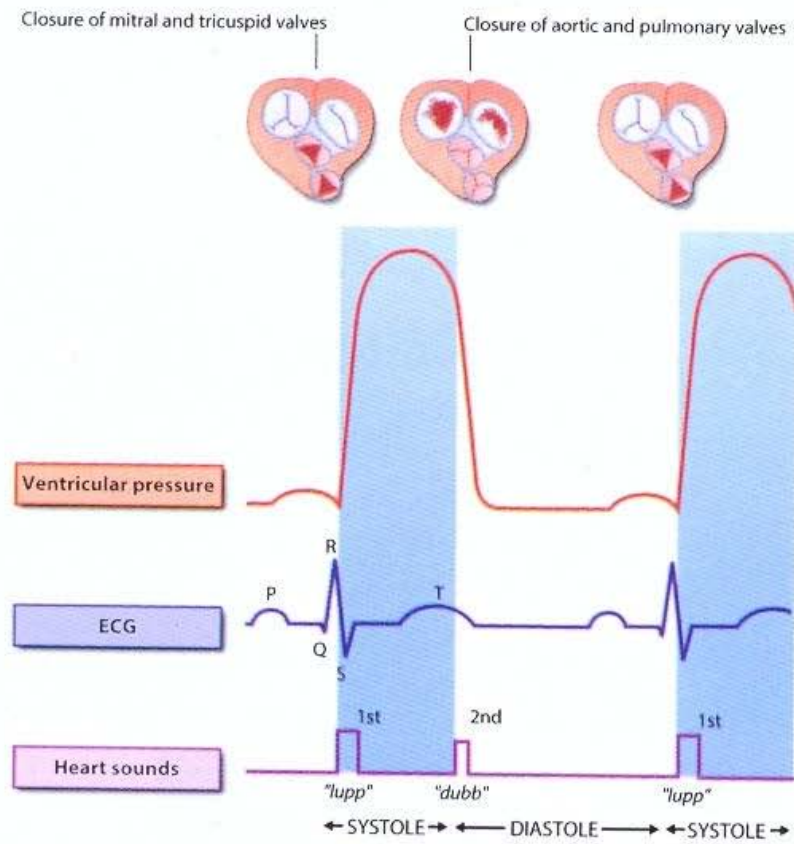


**Left chambers**

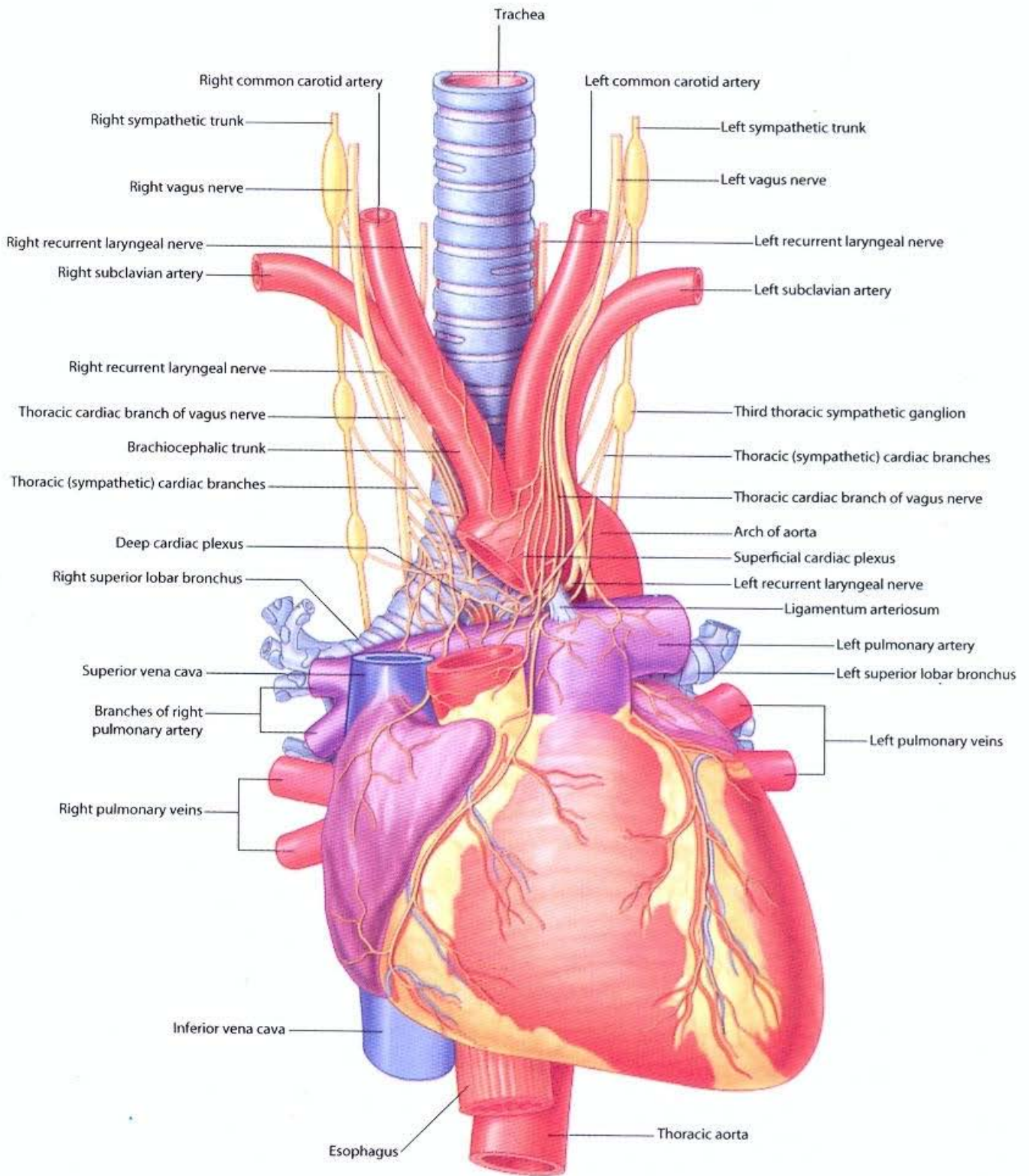
# THORAX • Auscultation points and heart sounds



**Auscultation points**

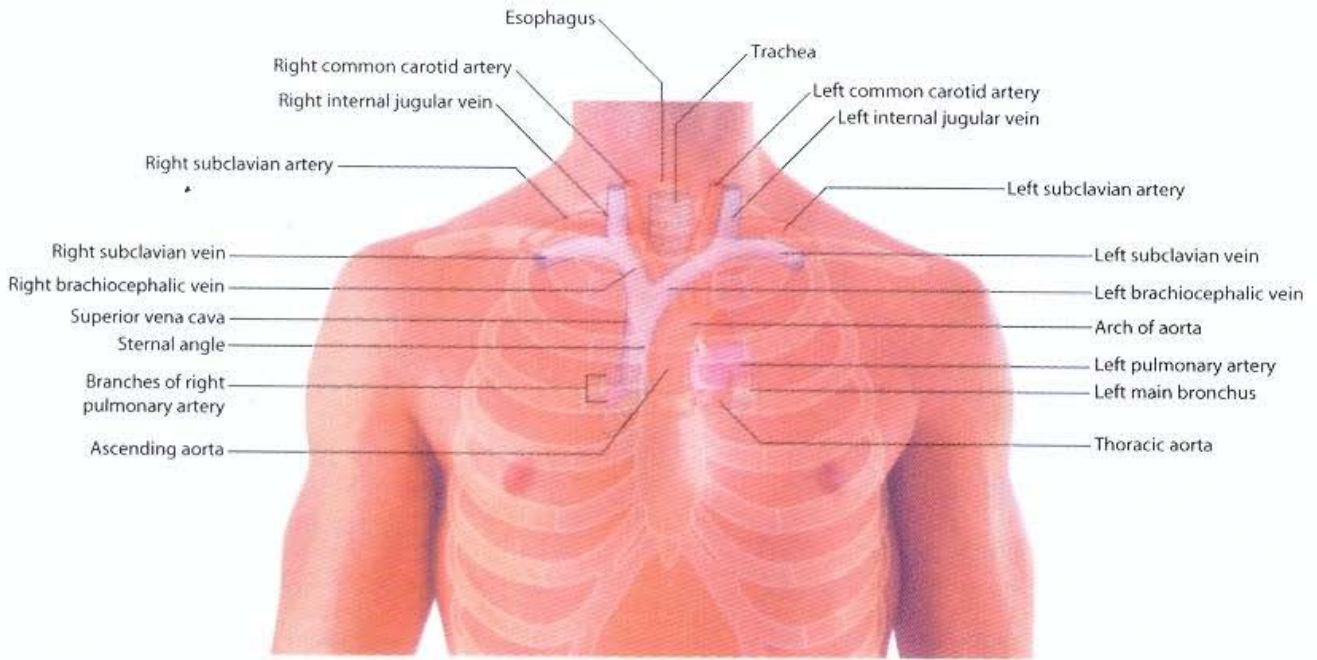


**Cardiac auscultation**

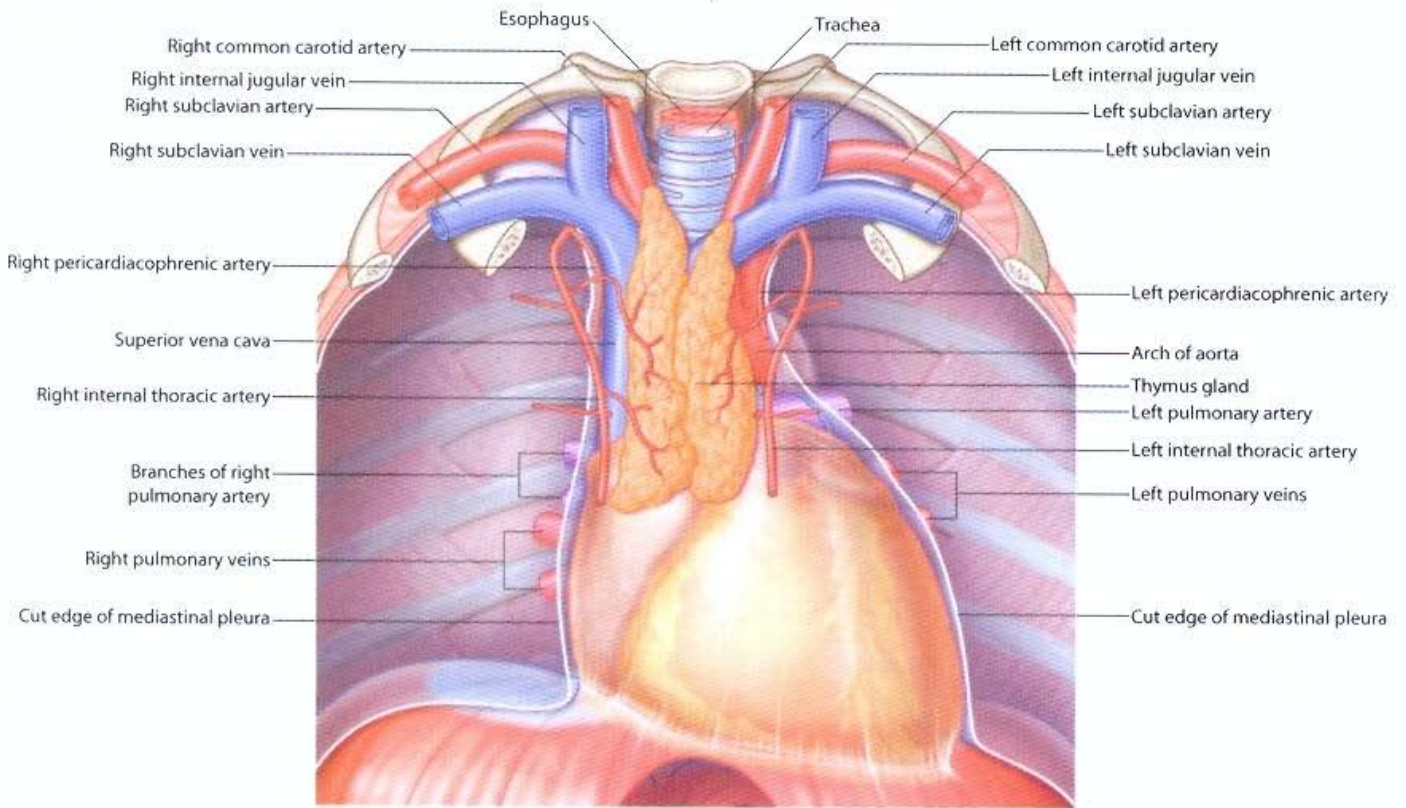


Cardiac plexus and nerves of the heart

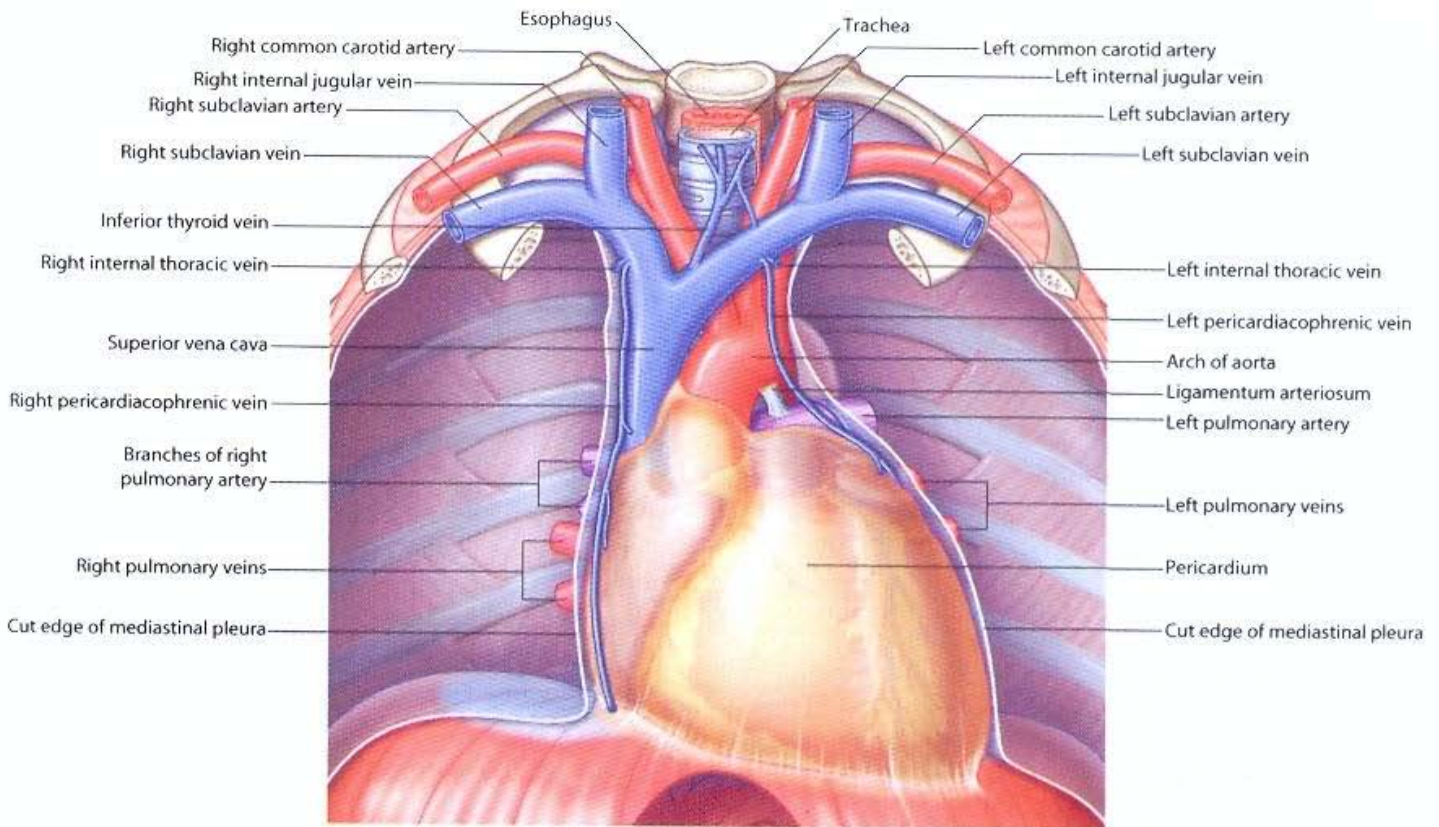
# THORAX • Superior mediastinum: thymus



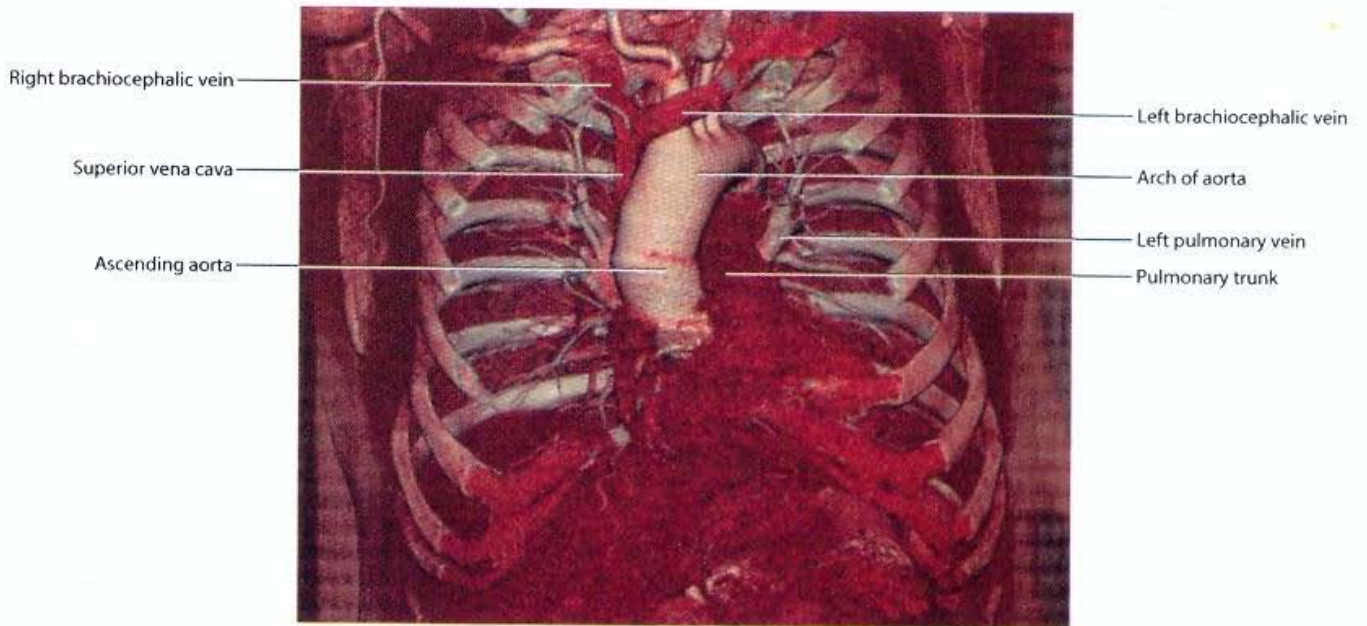
Surface projections of structures in the superior mediastinum



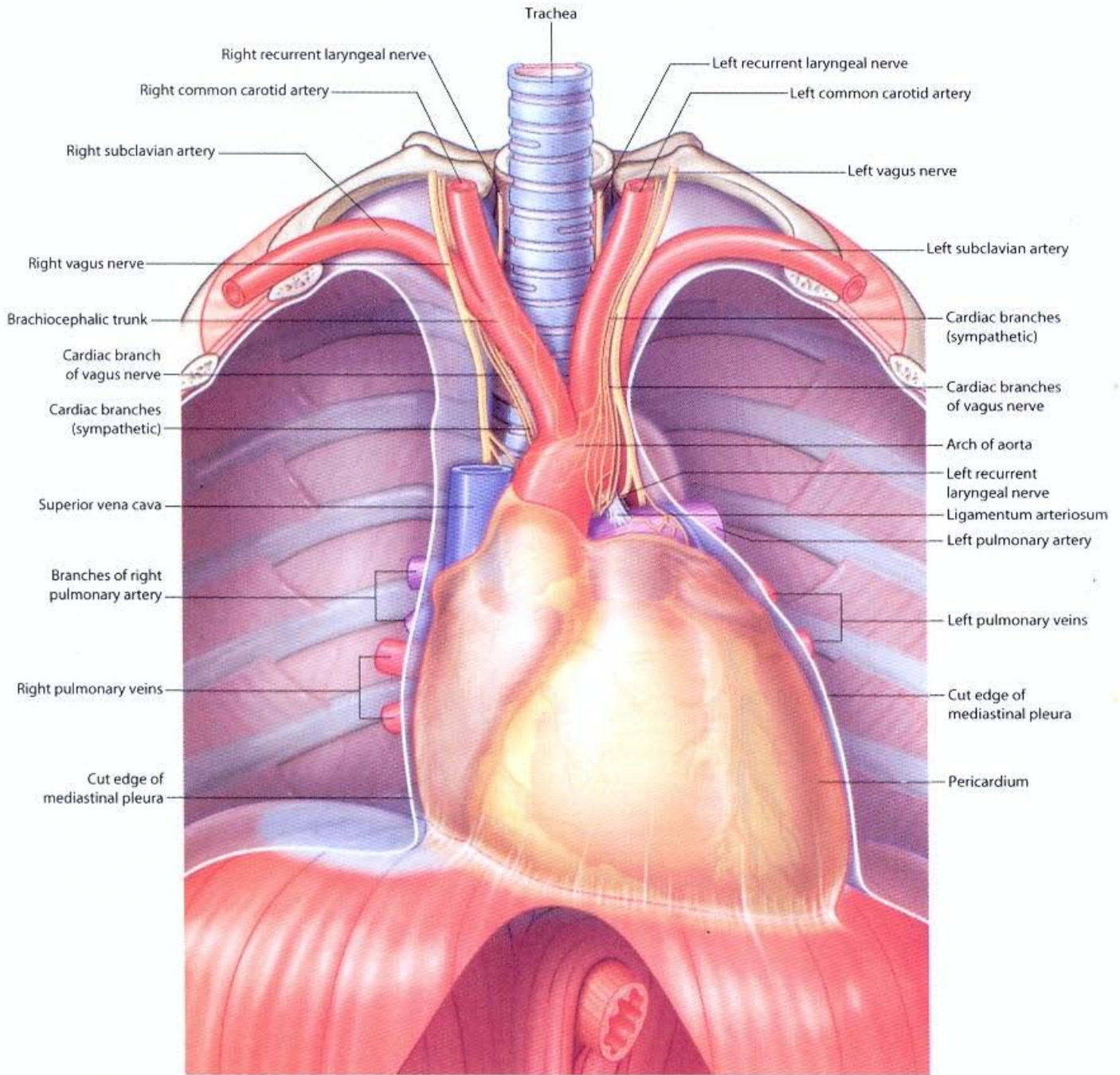
Thymus gland



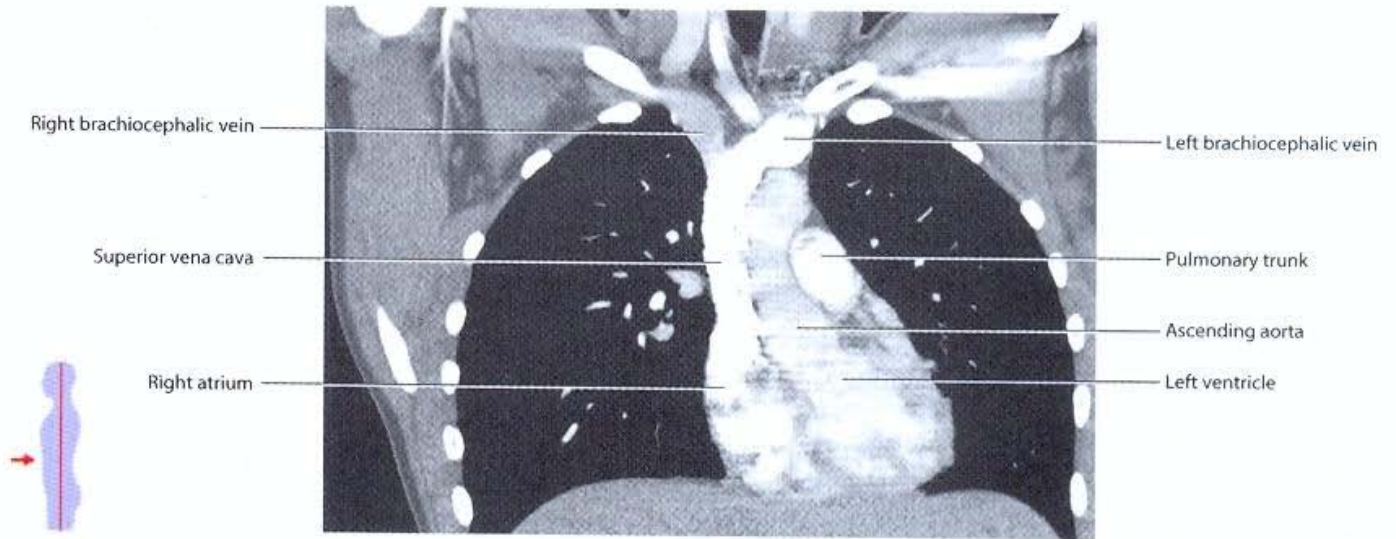
Veins of the superior mediastinum



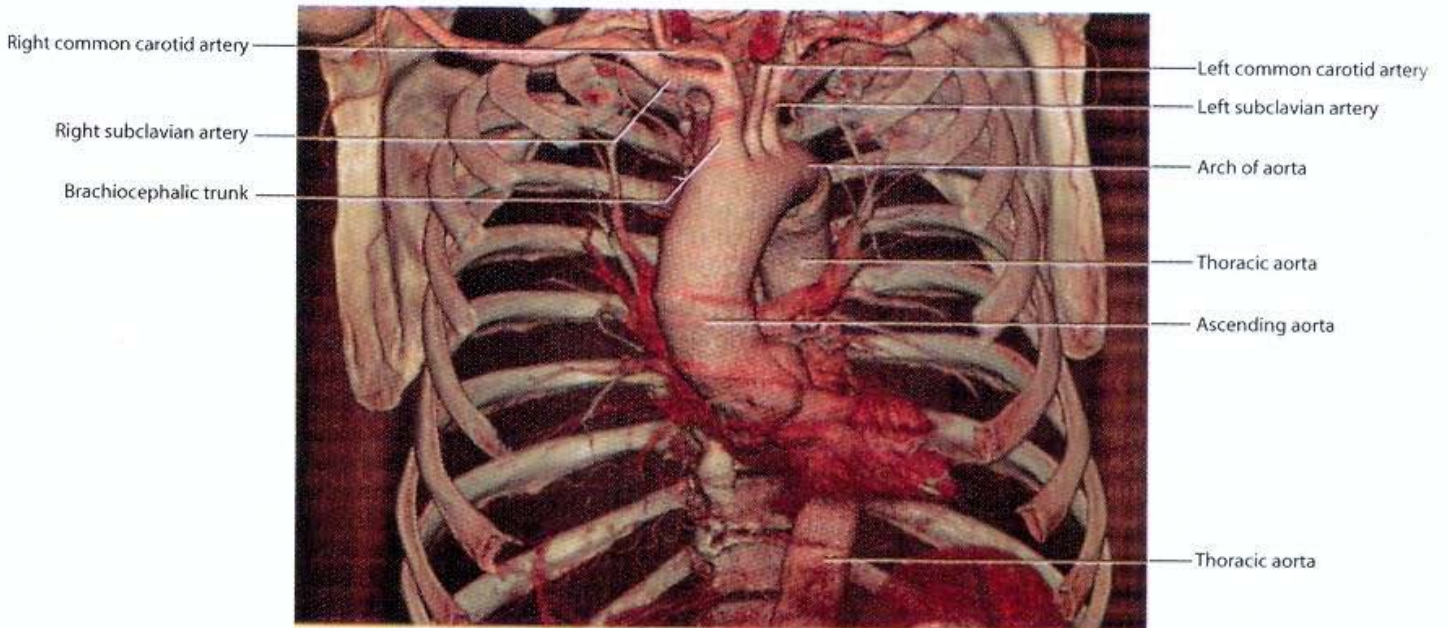
Anterior view of the superior mediastinum showing venous and arterial channels.  
Volume-rendered anterior view using multidetector computed tomography



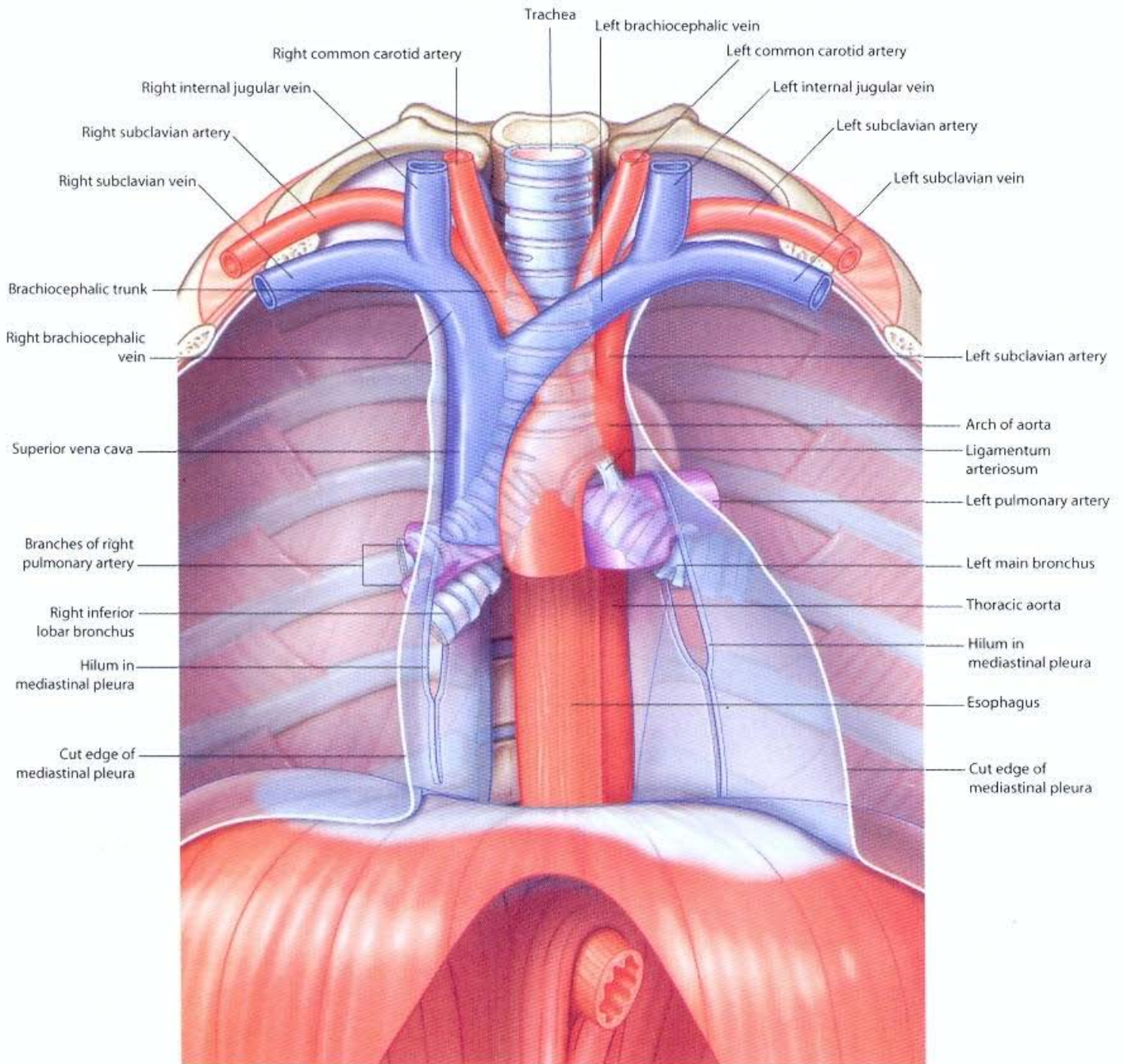
Arteries and nerves of the superior mediastinum



**Positioning of venous channels in the superior mediastinum.**  
CT image, with contrast, in coronal plane

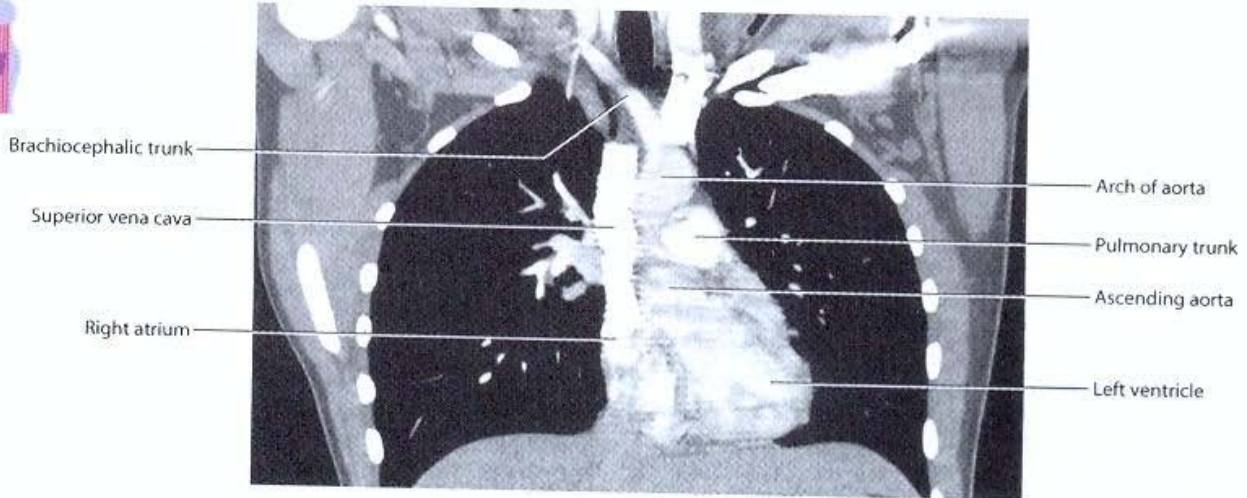
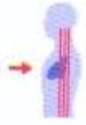


**Anterior view of the superior mediastinum with the venous channels, pulmonary trunk, and heart removed.**  
Volume-rendered anterior view using multidetector computed tomography

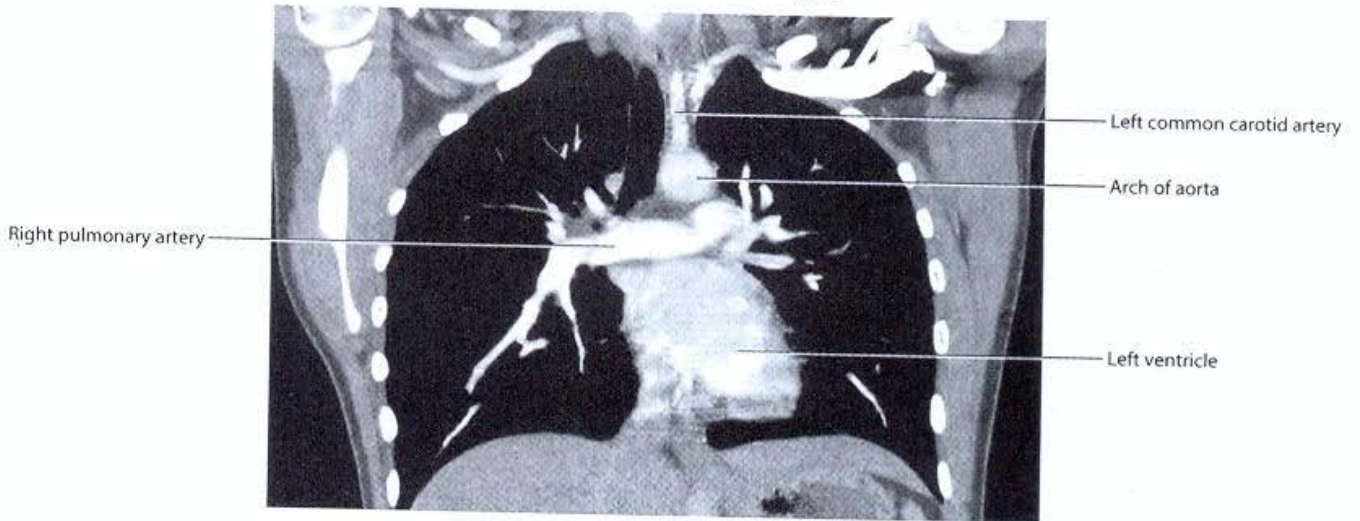


**Trachea and structures relating to it in the superior mediastinum**

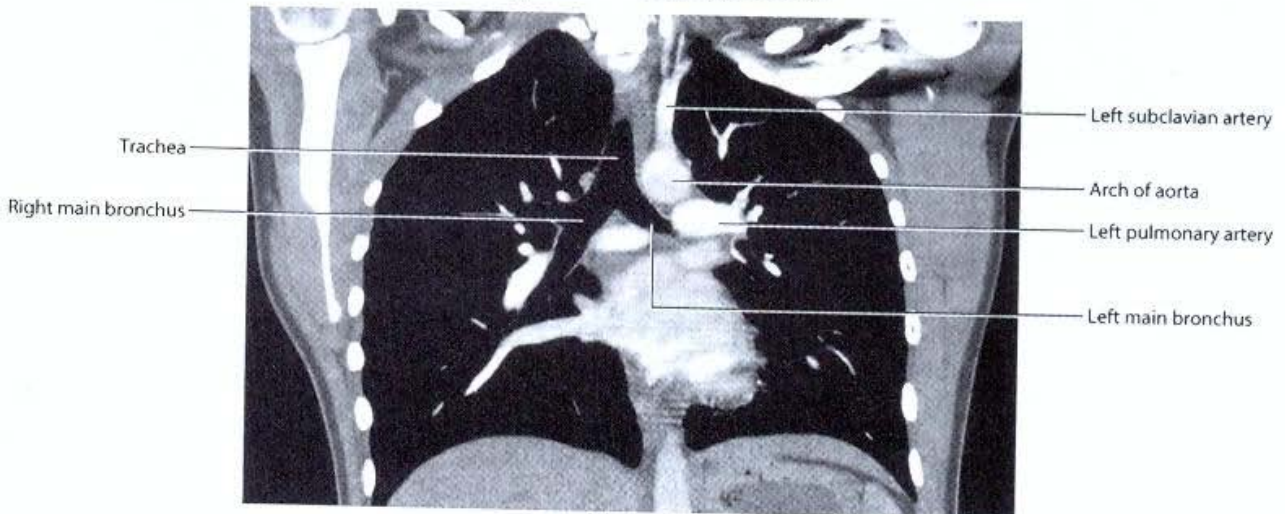




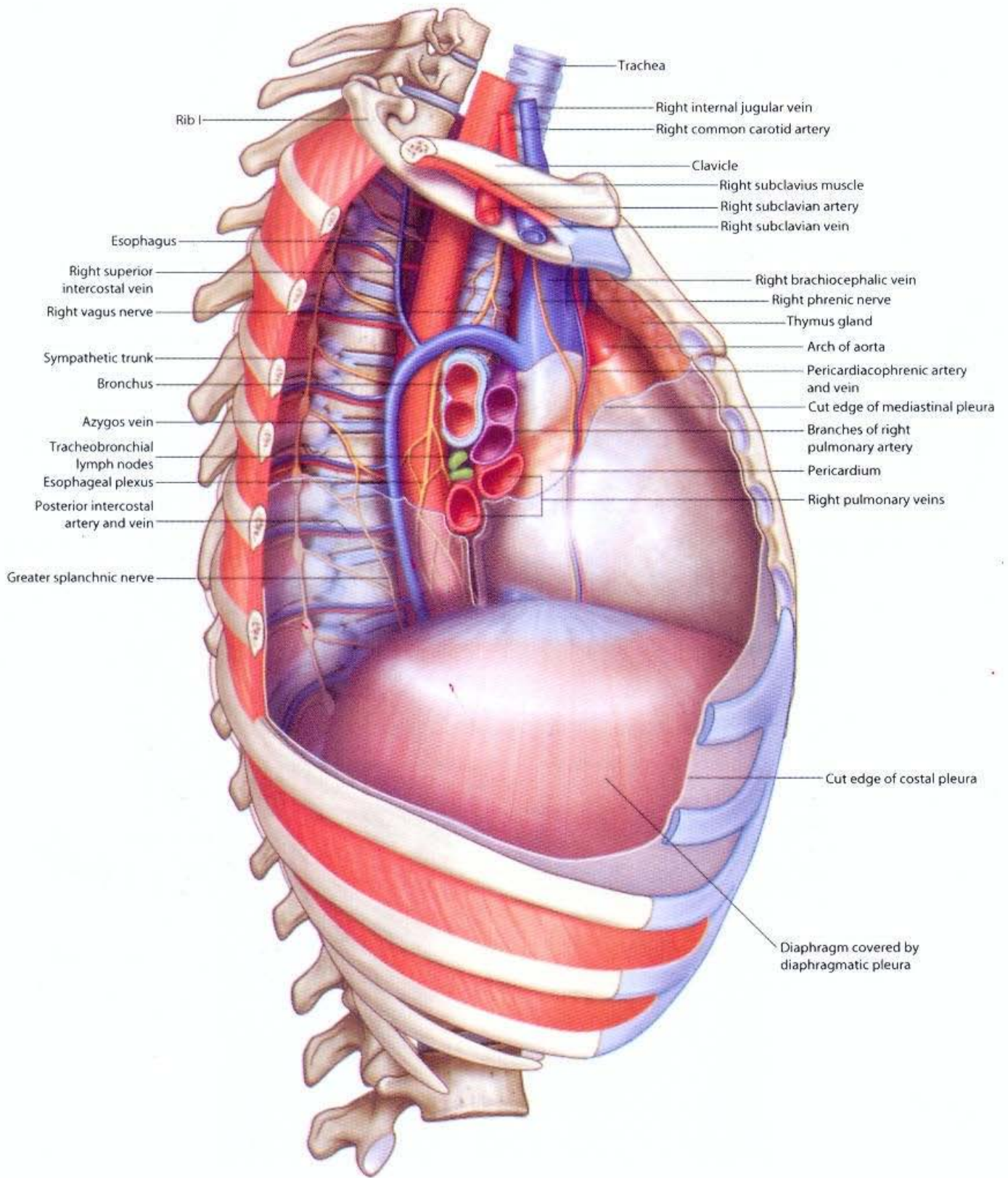
**Positioning of brachiocephalic trunk in relation to other structures in the superior mediastinum.**  
CT image, with contrast, in coronal plane



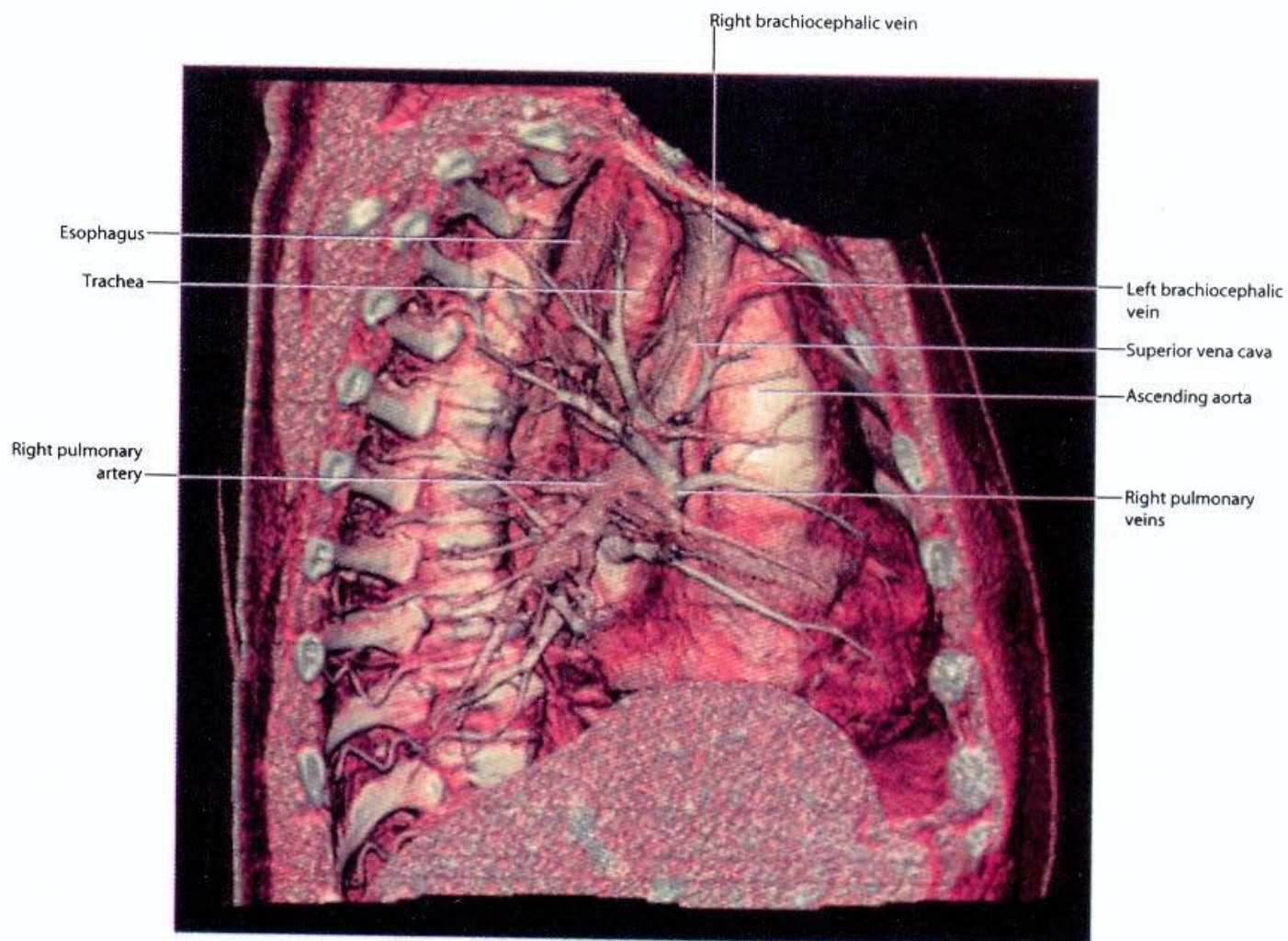
**Positioning of left common carotid artery in relation to other structures in the superior mediastinum.**  
CT image, with contrast, in coronal plane



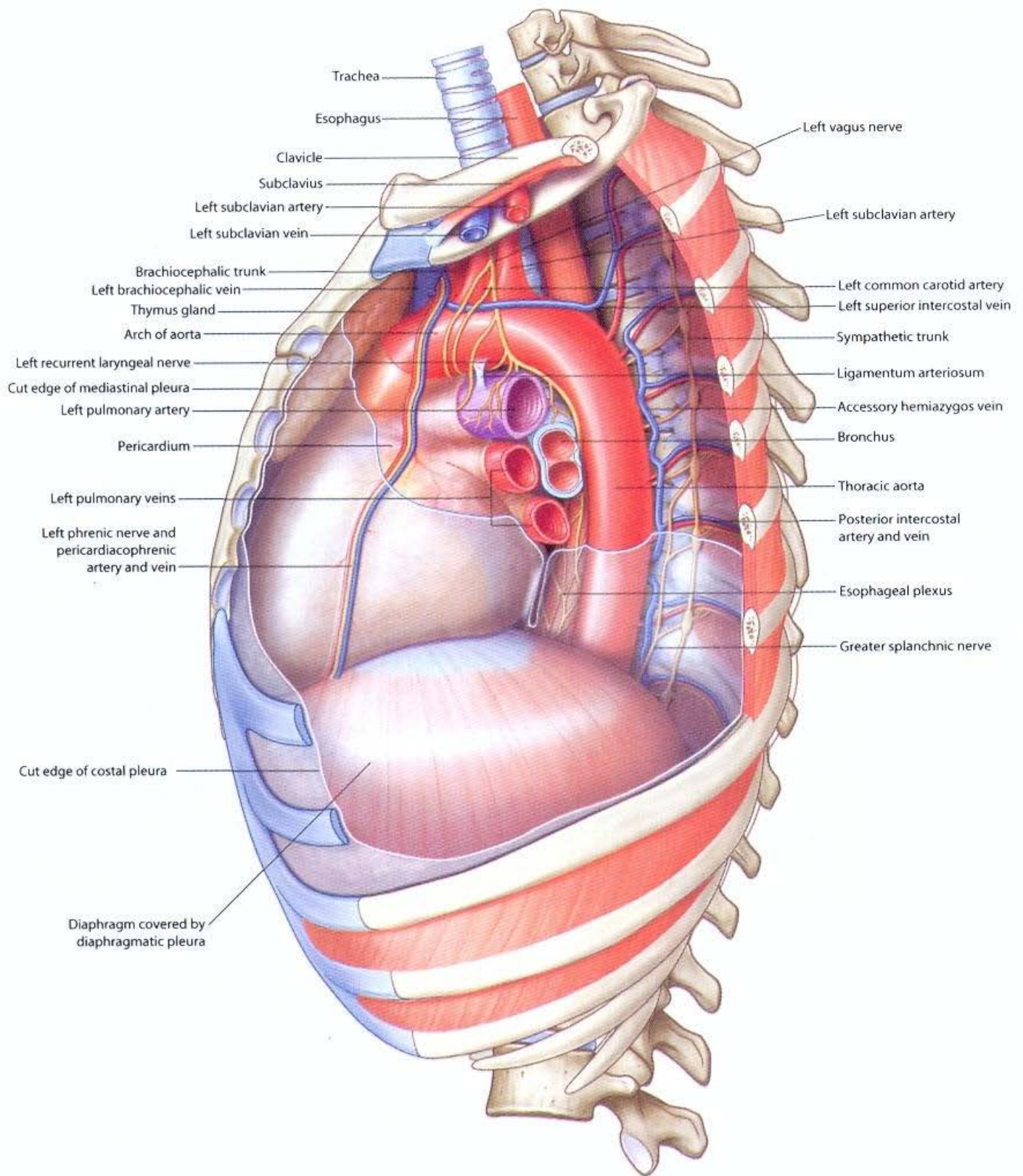
**Positioning of left subclavian artery and the bifurcation of the trachea in relation to other structures in the superior mediastinum.**  
CT image, with contrast, in coronal plane



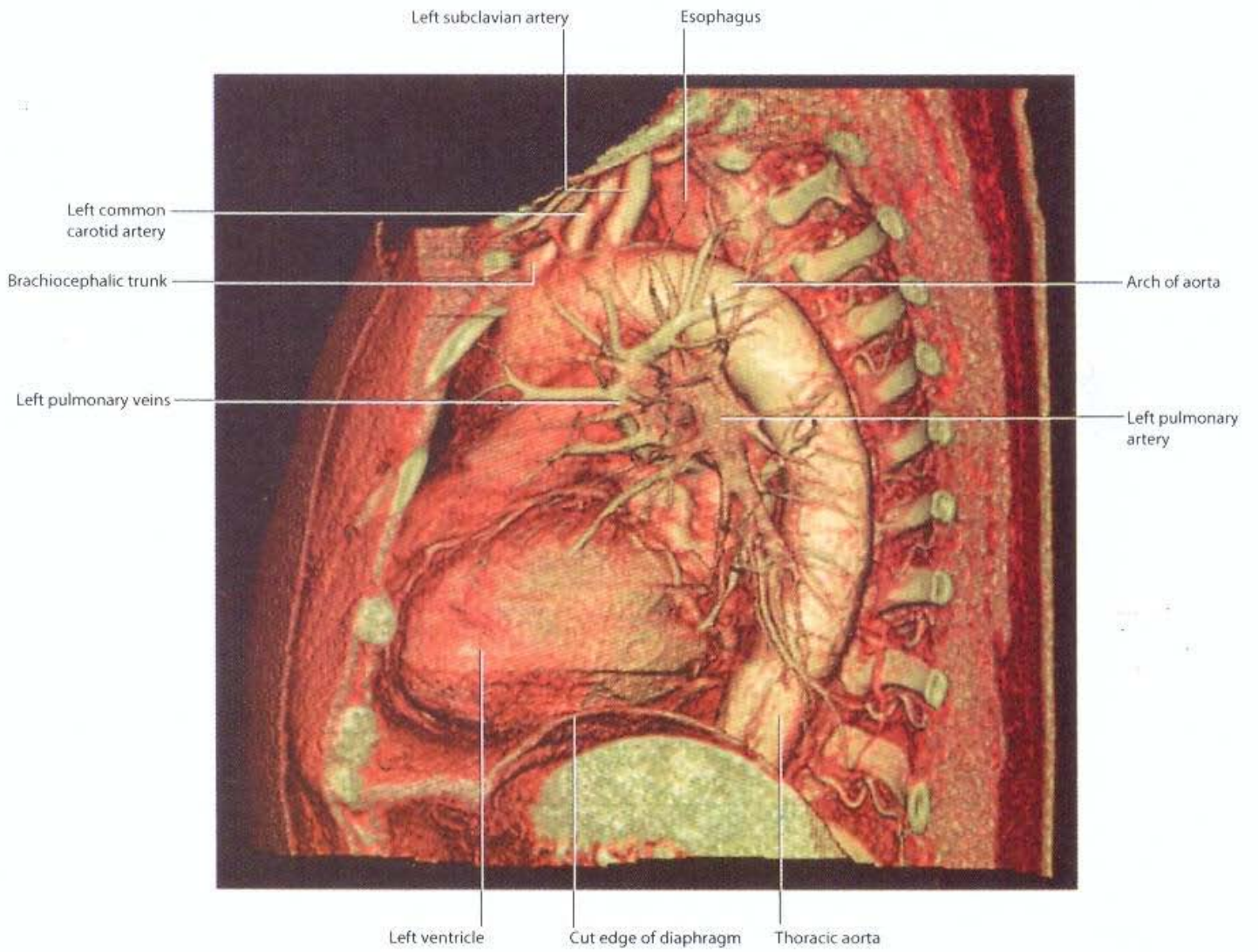
Right side of mediastinum and right thoracic cavity



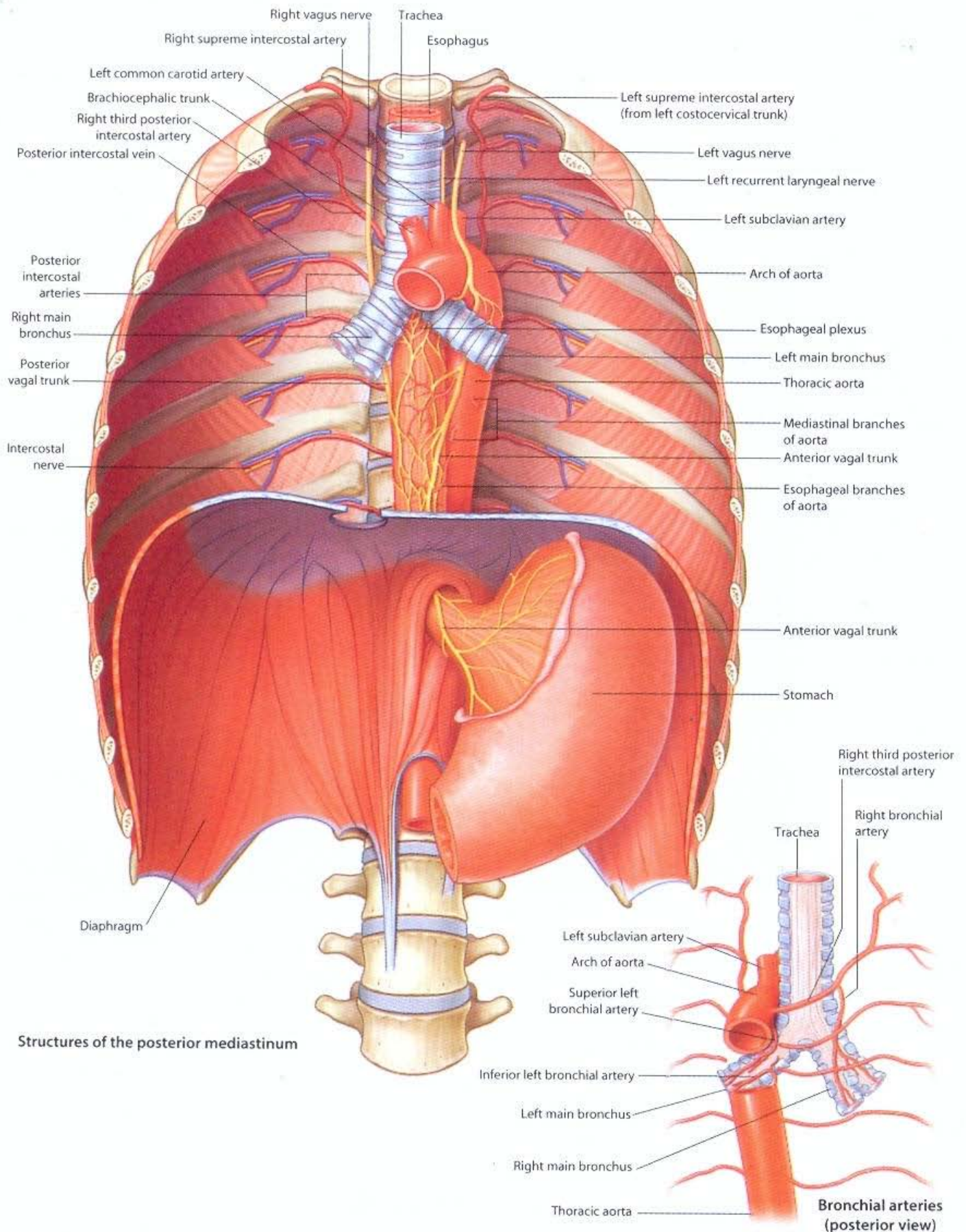
**View of mediastinal structures from the right side of the thorax.**  
 Volume-rendered lateral view from the right side using multidetector computed tomography

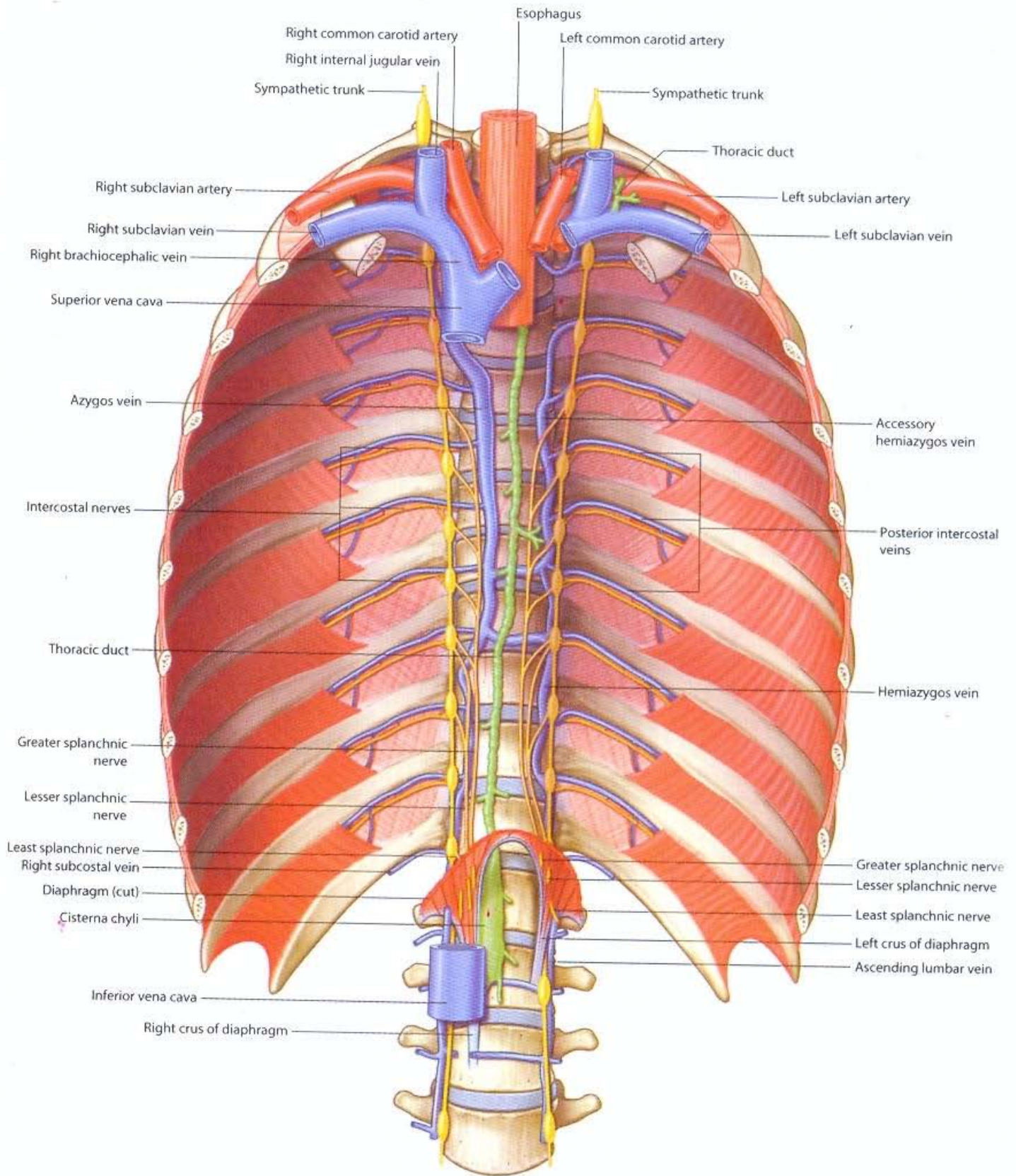


Left side of mediastinum and left thoracic cavity

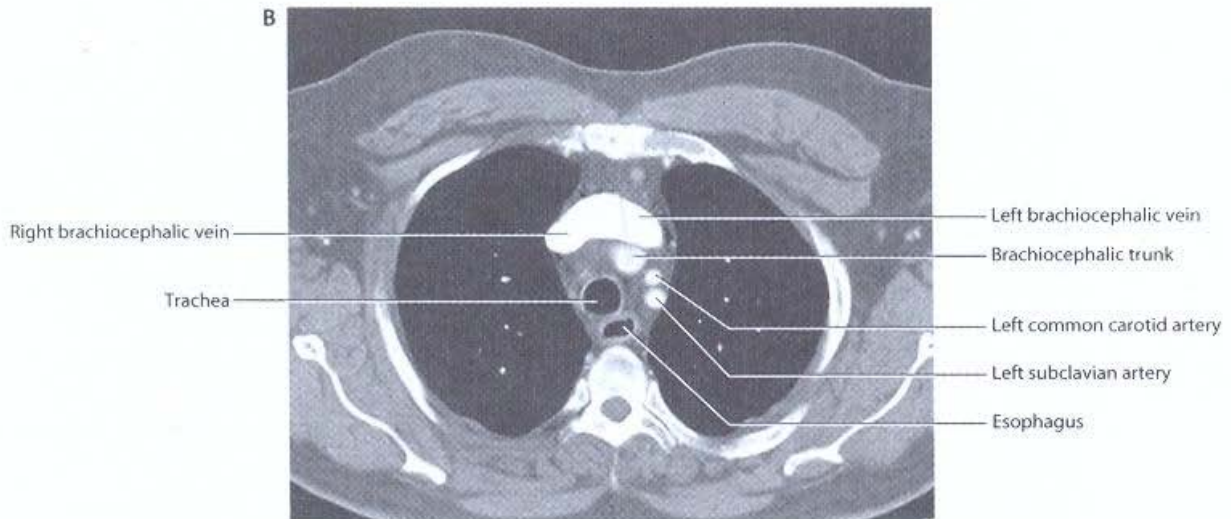
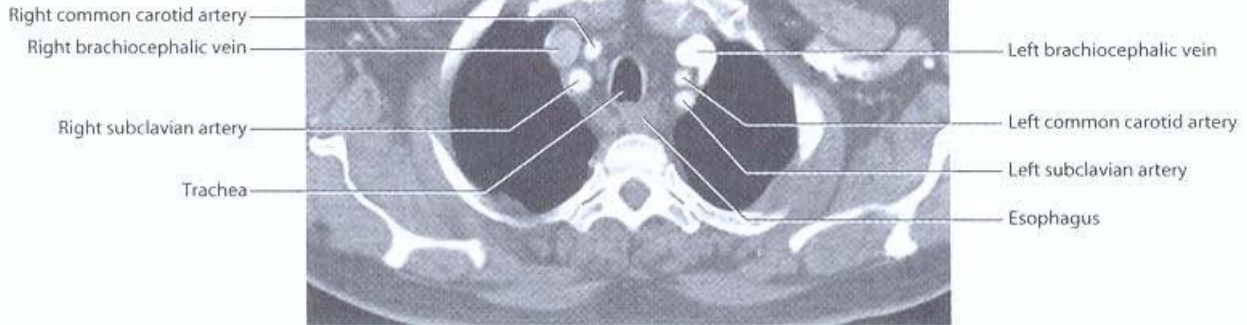
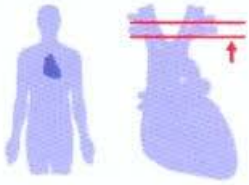


**View of mediastinal structures from the left side of the thorax.**  
Volume-rendered lateral view from the left side using multidetector computed tomography

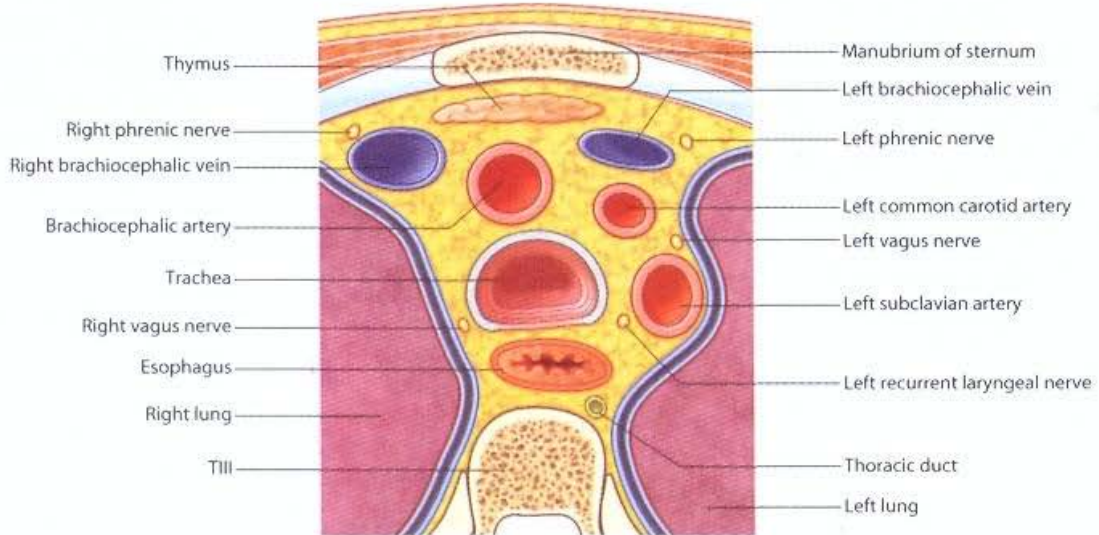




Structures of the posterior mediastinum  
(thoracic aorta and esophagus removed)

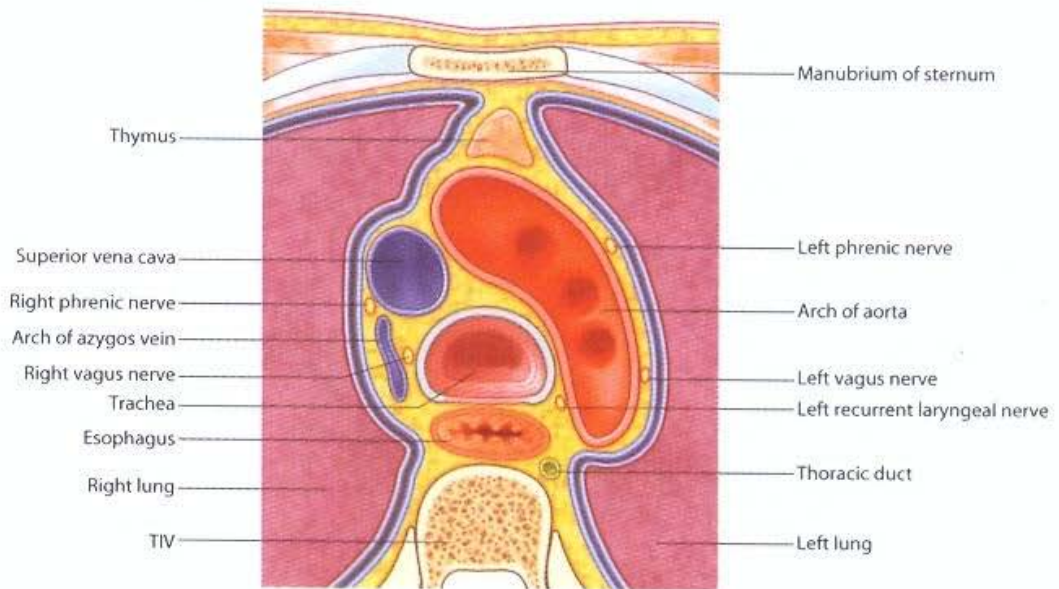
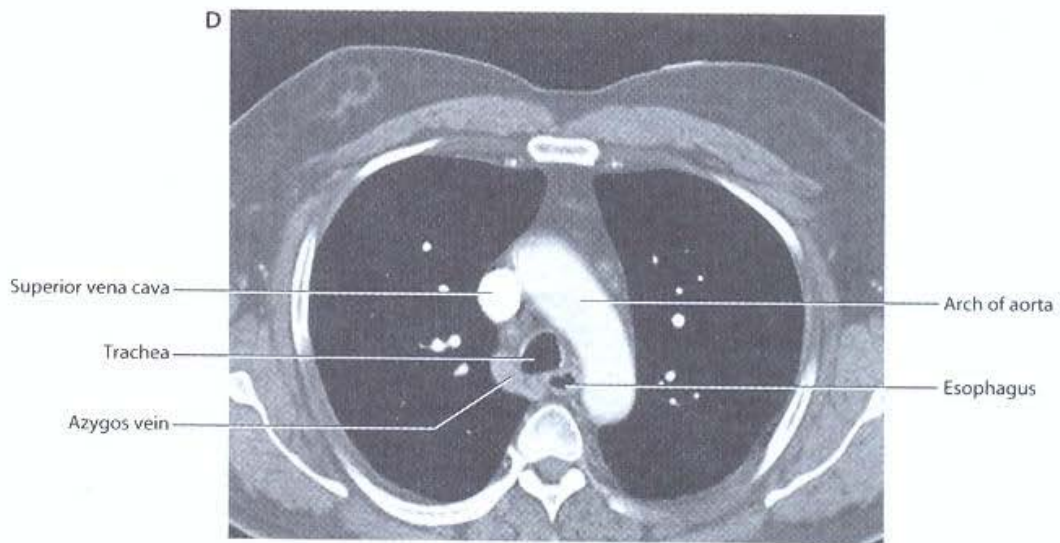
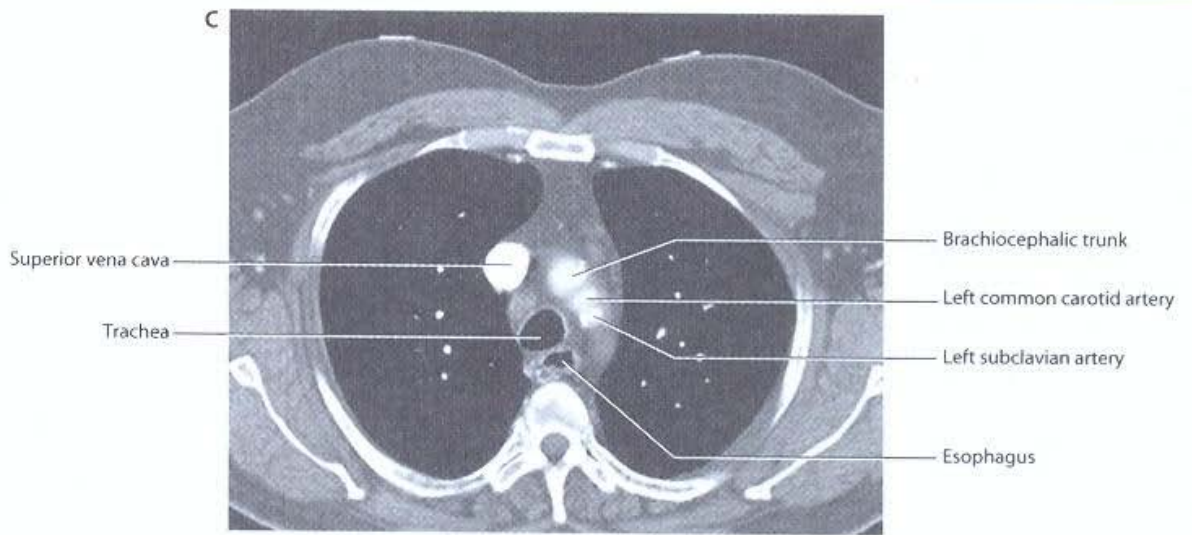


**A through I** – This is a series of images that pass through the thorax from superior to inferior showing the various mediastinal structures and their relationships with each other.  
CT images, with contrast, in axial plane

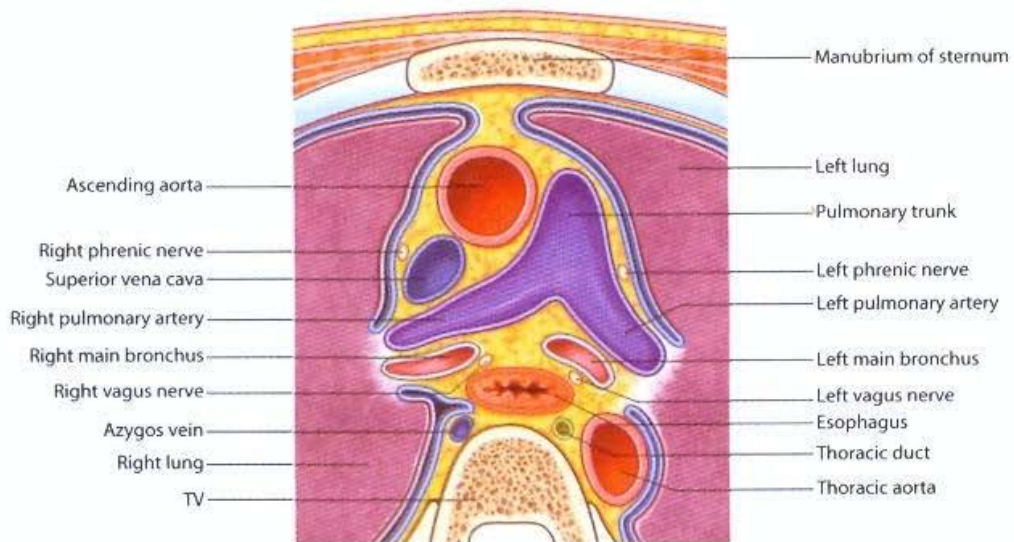
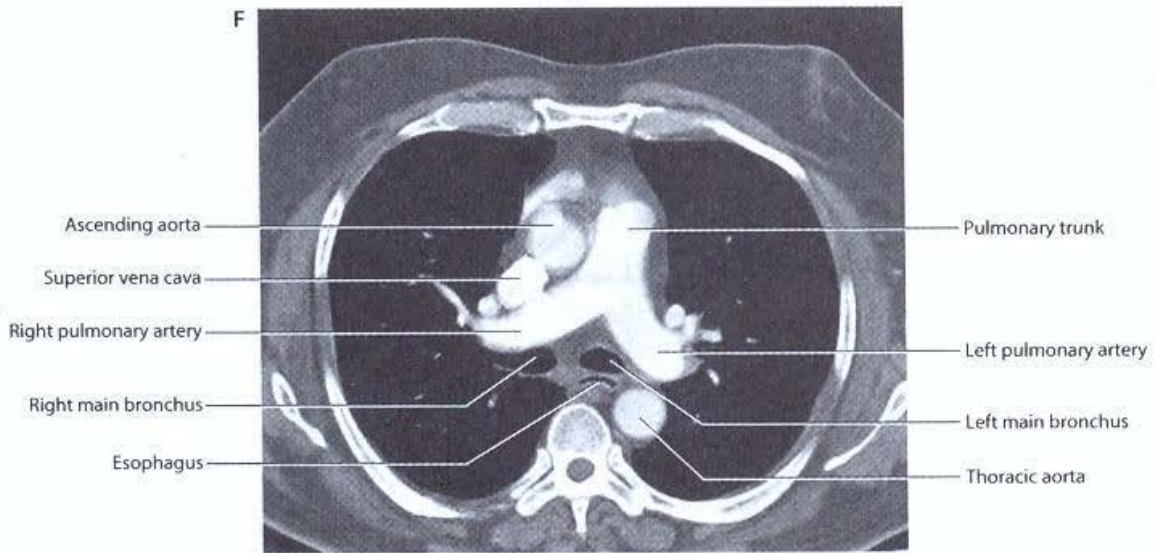
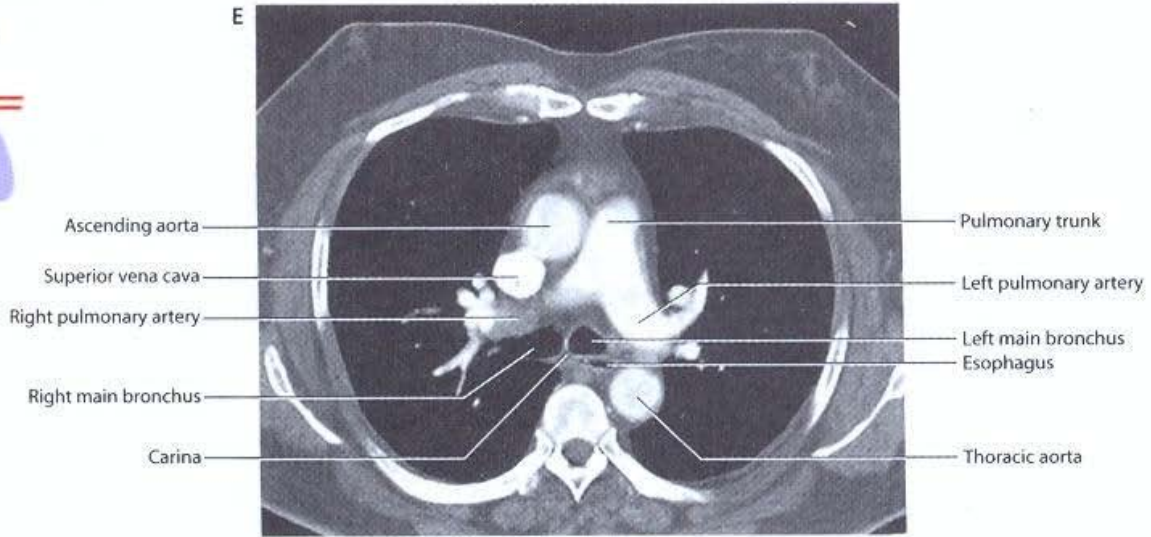



**Transverse section through the superior mediastinum at the level of vertebra T111**

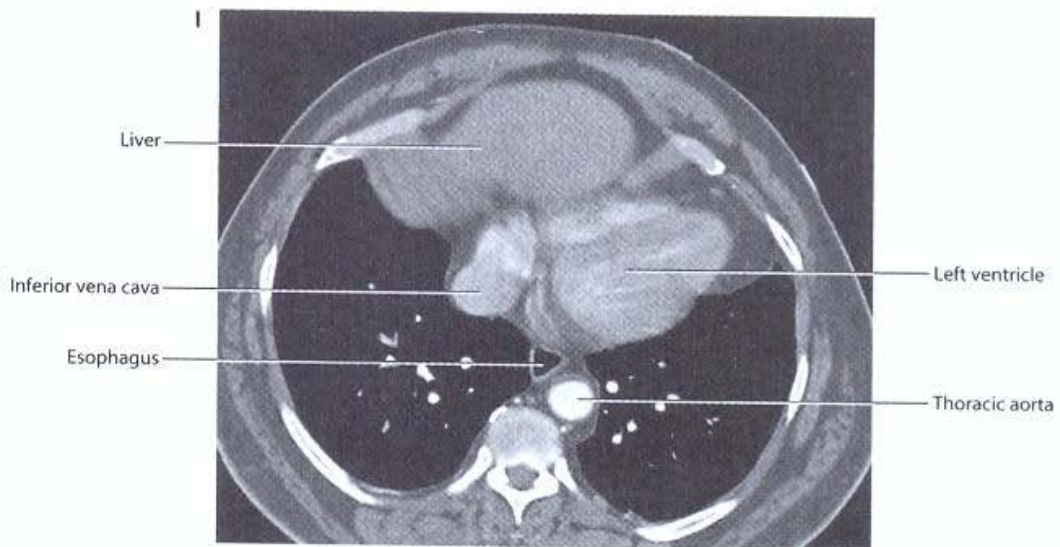
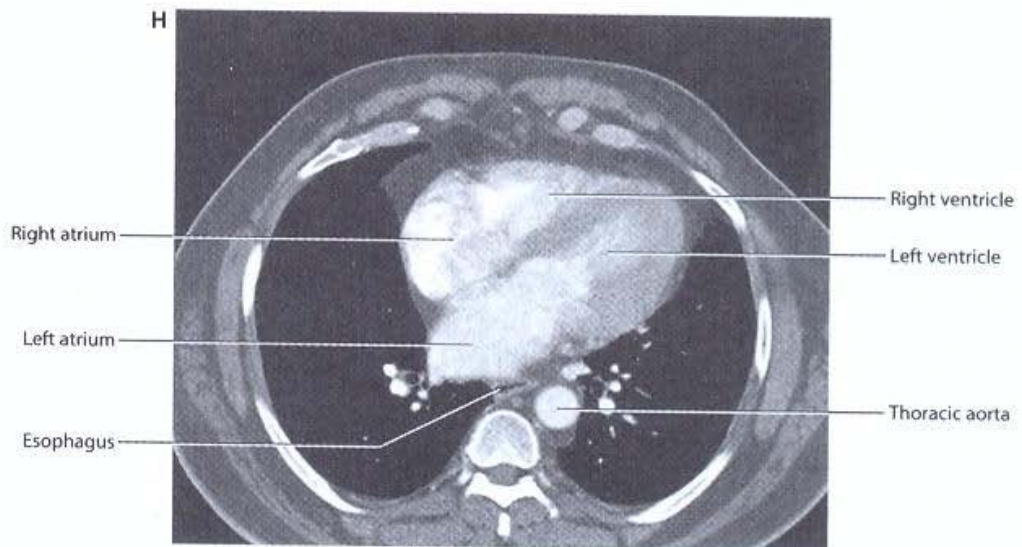
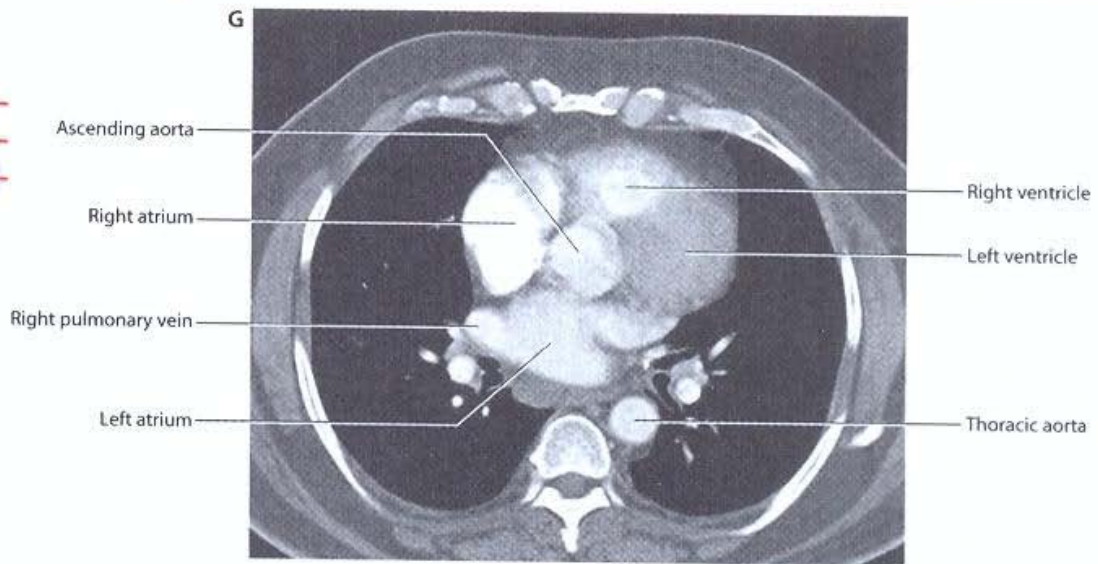




Transverse section through the superior mediastinum at the level of vertebra T4

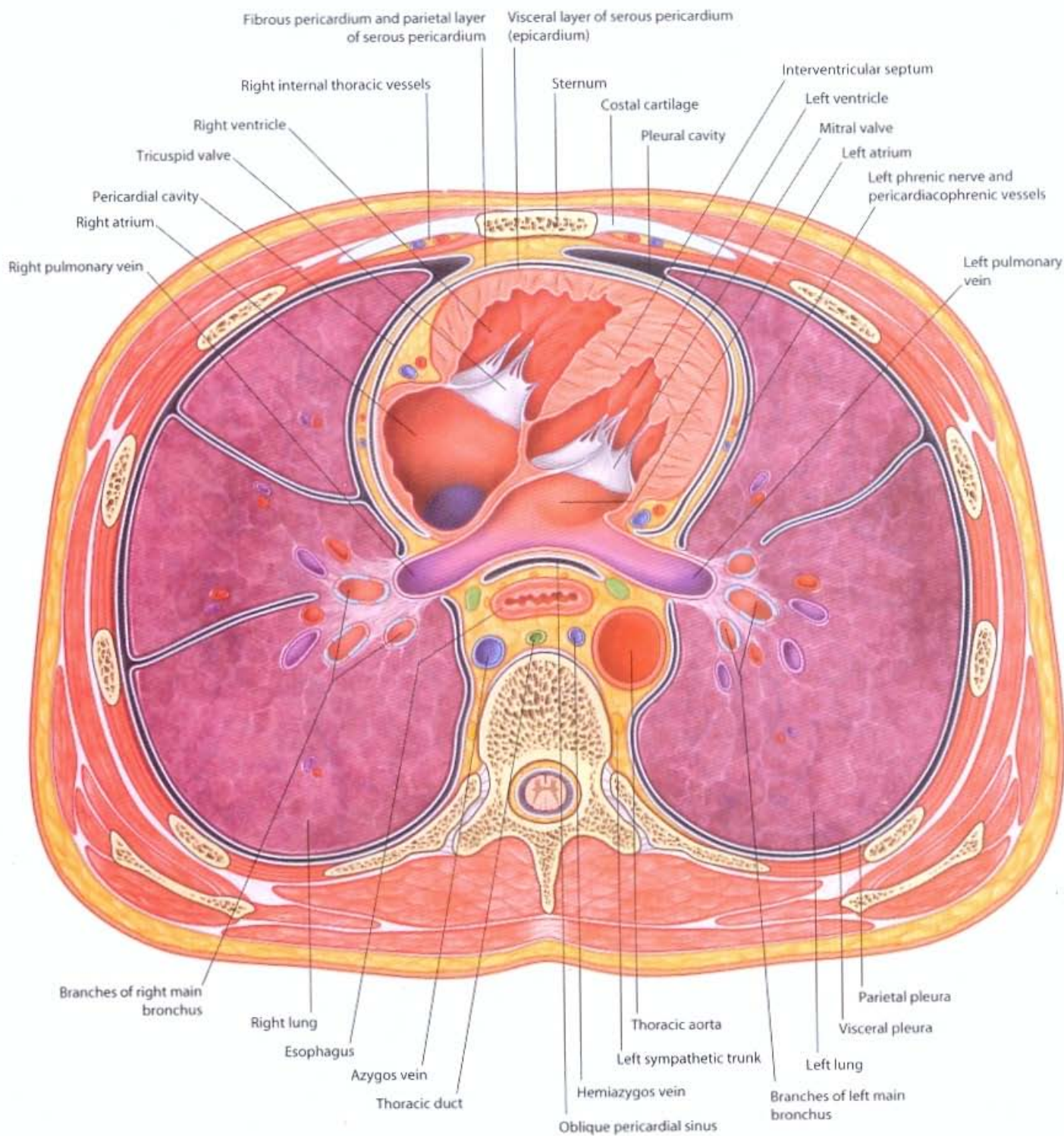


Transverse section through the superior mediastinum at the level of vertebra TV

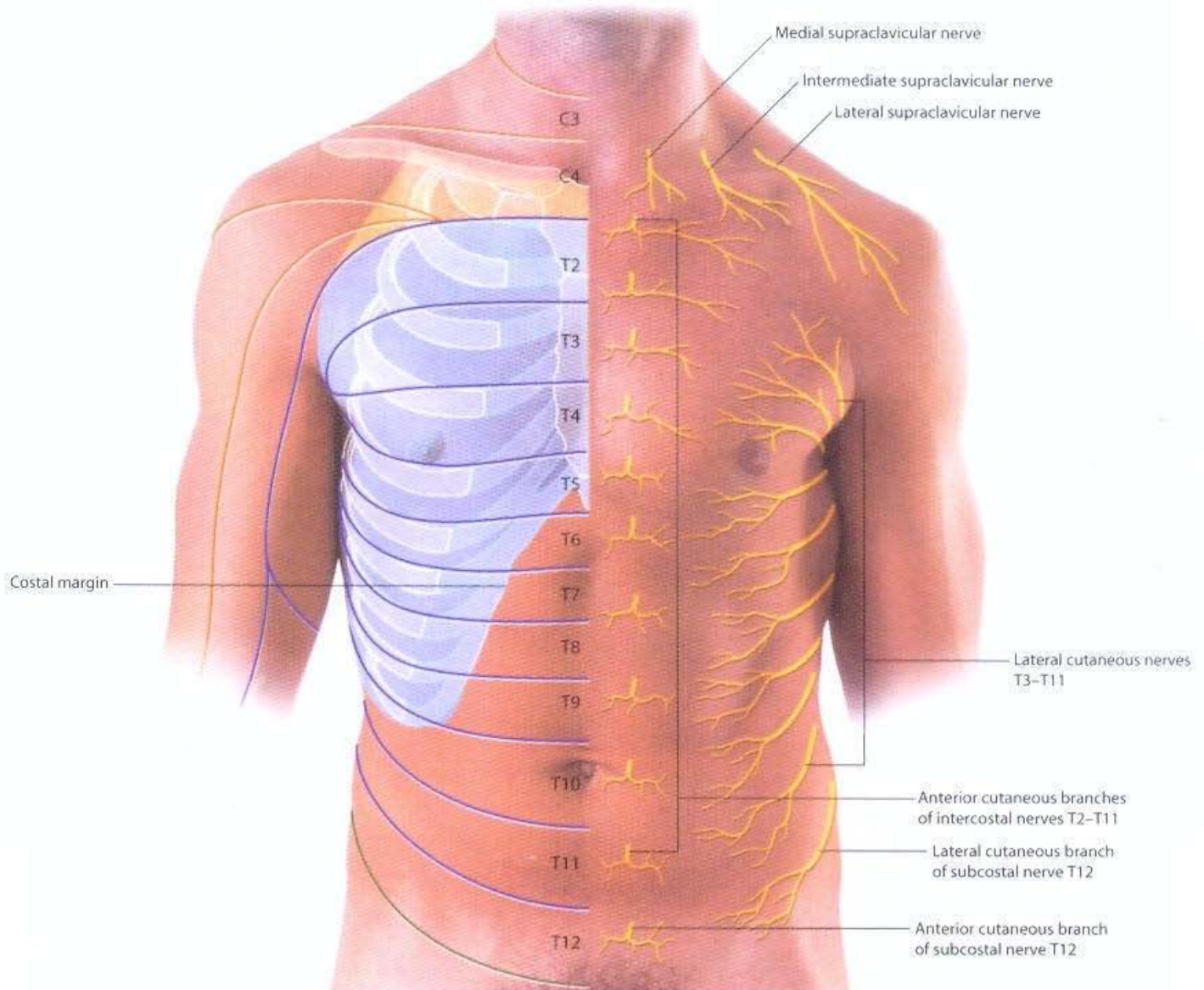


**A through I** – This is a series of images that pass through the thorax from superior to inferior showing the various mediastinal structures and their relationships with each other.  
 CT images, with contrast, in axial plane

# THORAX • Transverse section: TVIII level

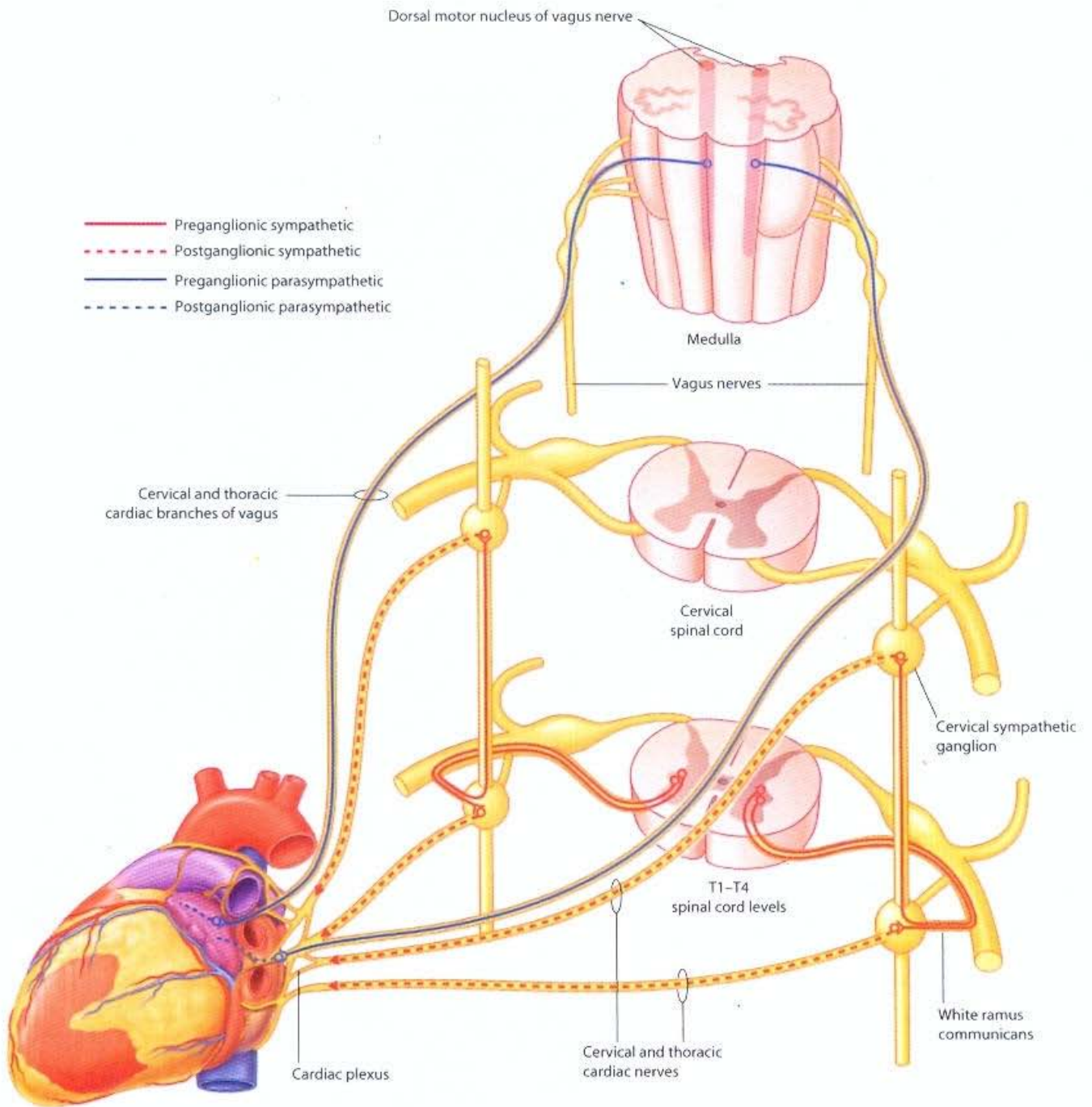


Transverse section through thorax (approximately TVII)

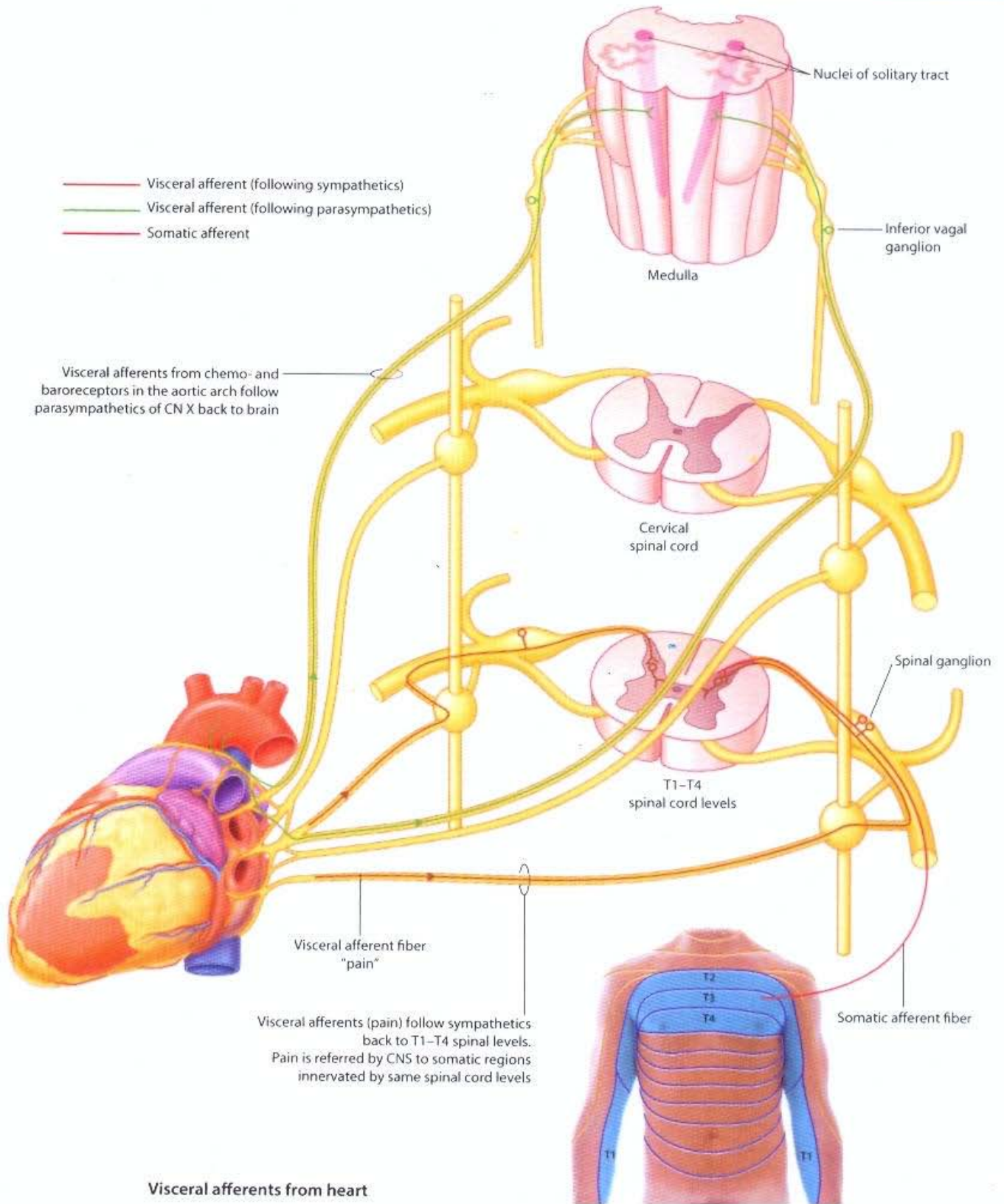


Dermatomes and cutaneous nerves of the thoracic region

**THORAX** • *Visceral efferent (motor) innervation of the heart*



**Visceral efferent (motor) innervation of the heart**  
(sympathetic and parasympathetic)



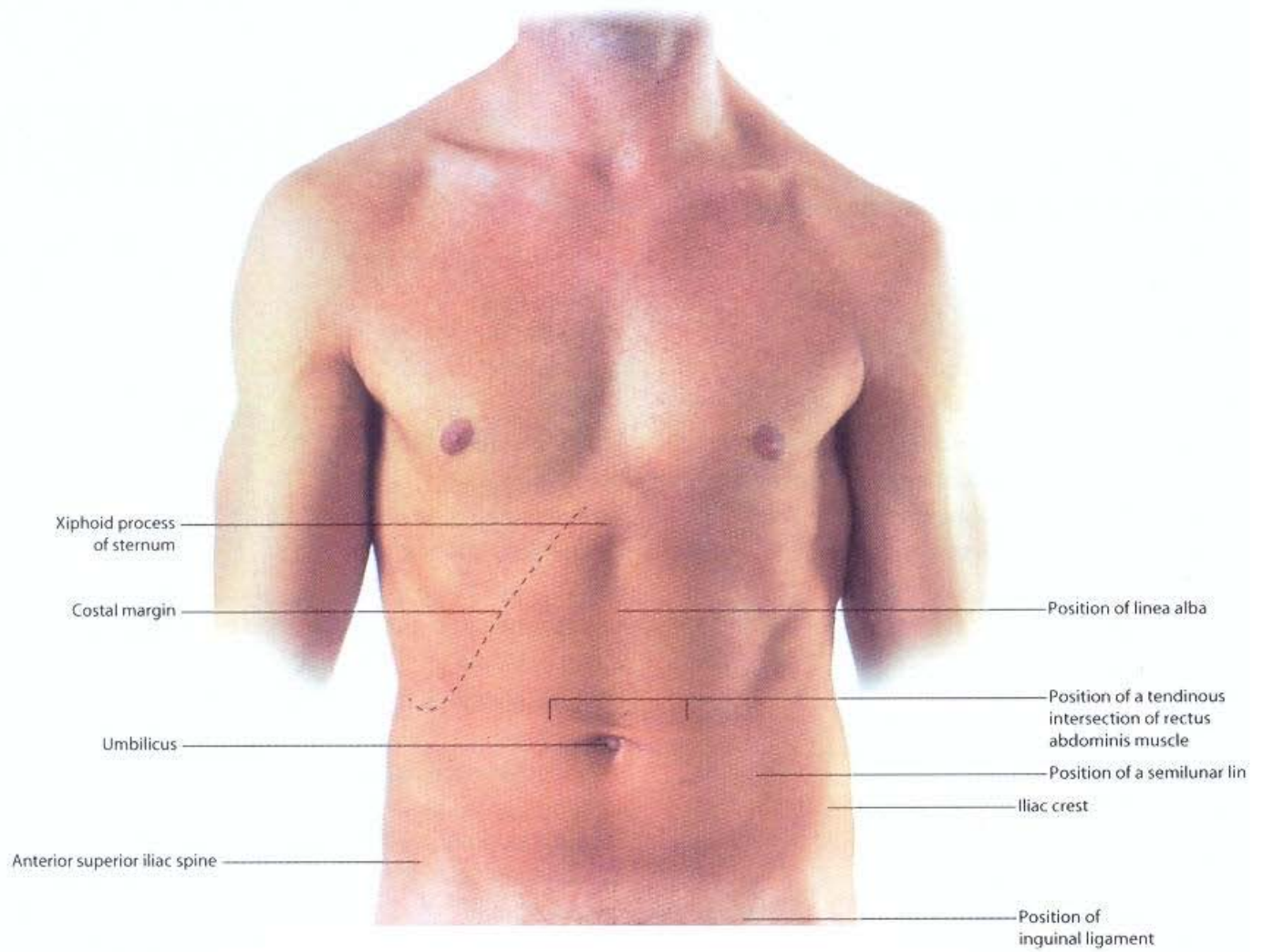
# 4

# ABDOMEN

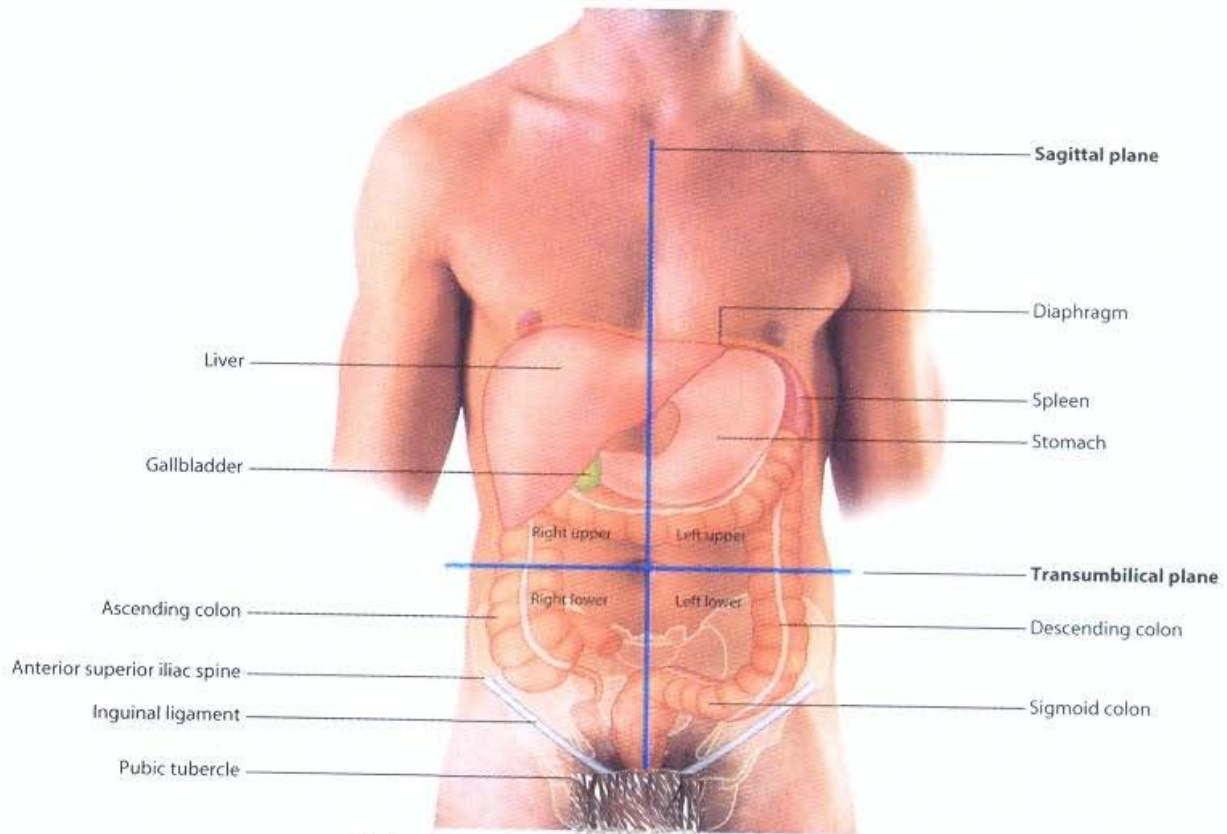
## CONTENTS

<i>Surface anatomy</i>	124	<i>Portosystemic anastomoses</i>	172
<i>Quadrants and regions</i>	125	<i>Posterior wall</i>	173
<i>Abdominal wall</i>	126	<i>Vessels of the posterior wall</i>	174
<i>Muscles</i>	128	<i>Diaphragm</i>	175
<i>Muscles: rectus sheath</i>	131	<i>Kidneys</i>	176
<i>Vessels of the abdominal wall</i>	132	<i>Gross structure of kidneys</i>	178
<i>Arteries and lymphatics of the abdominal wall</i>	133	<i>Kidneys: imaging</i>	179
<i>Nerves of the abdominal wall</i>	134	<i>Renal vasculature</i>	180
<i>Dermatomes and cutaneous nerves</i>	135	<i>Branches of the abdominal aorta</i>	182
<i>Inguinal region</i>	136	<i>Inferior vena cava</i>	183
<i>Inguinal canal</i>	138	<i>Abdominal aorta and inferior vena cava: imaging</i>	184
<i>Inguinal hernias</i>	140	<i>Lumbar plexus</i>	186
<i>Anterior abdominal wall</i>	141	<i>Lumbar plexus: cutaneous distribution</i>	187
<i>Greater omentum</i>	142	<i>Lymphatics</i>	188
<i>Abdominal viscera</i>	143	<i>Abdominal innervation</i>	189
<i>Peritoneal cavity</i>	144	<i>Splanchnic nerves</i>	190
<i>Abdominal sagittal section</i>	145	<i>Visceral efferent (motor) innervation diagram</i>	191
<i>Abdominal coronal section</i>	146	<i>Visceral afferent (sensory) innervation and referred pain diagram</i>	192
<i>Arterial supply of viscera</i>	147	<i>Kidney and ureter visceral afferent (sensory) diagram</i>	194
<i>Stomach</i>	148		
<i>Spleen</i>	149		
<i>Arteries of stomach and spleen</i>	150		
<i>Duodenum</i>	152		
<i>Small intestine</i>	154		
<i>Large intestine</i>	156		
<i>Ileocecal junction</i>	158		
<i>Gastrointestinal tract: imaging</i>	159		
<i>Mesenteric arteries</i>	160		
<i>Liver</i>	162		
<i>Vessels of the liver</i>	164		
<i>Segments of the liver</i>	165		
<i>Pancreas and gallbladder</i>	166		
<i>Vasculature of pancreas and duodenum</i>	169		
<i>Venous drainage of viscera</i>	170		

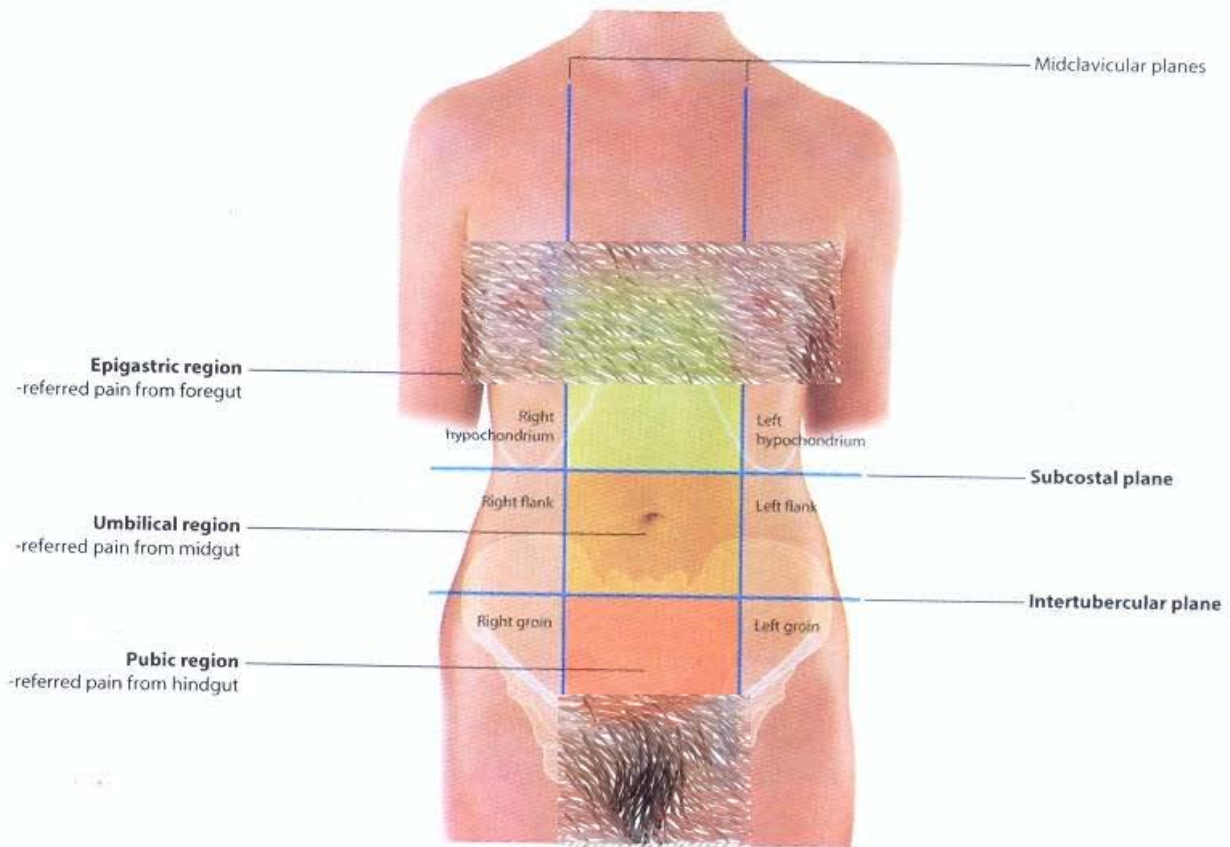




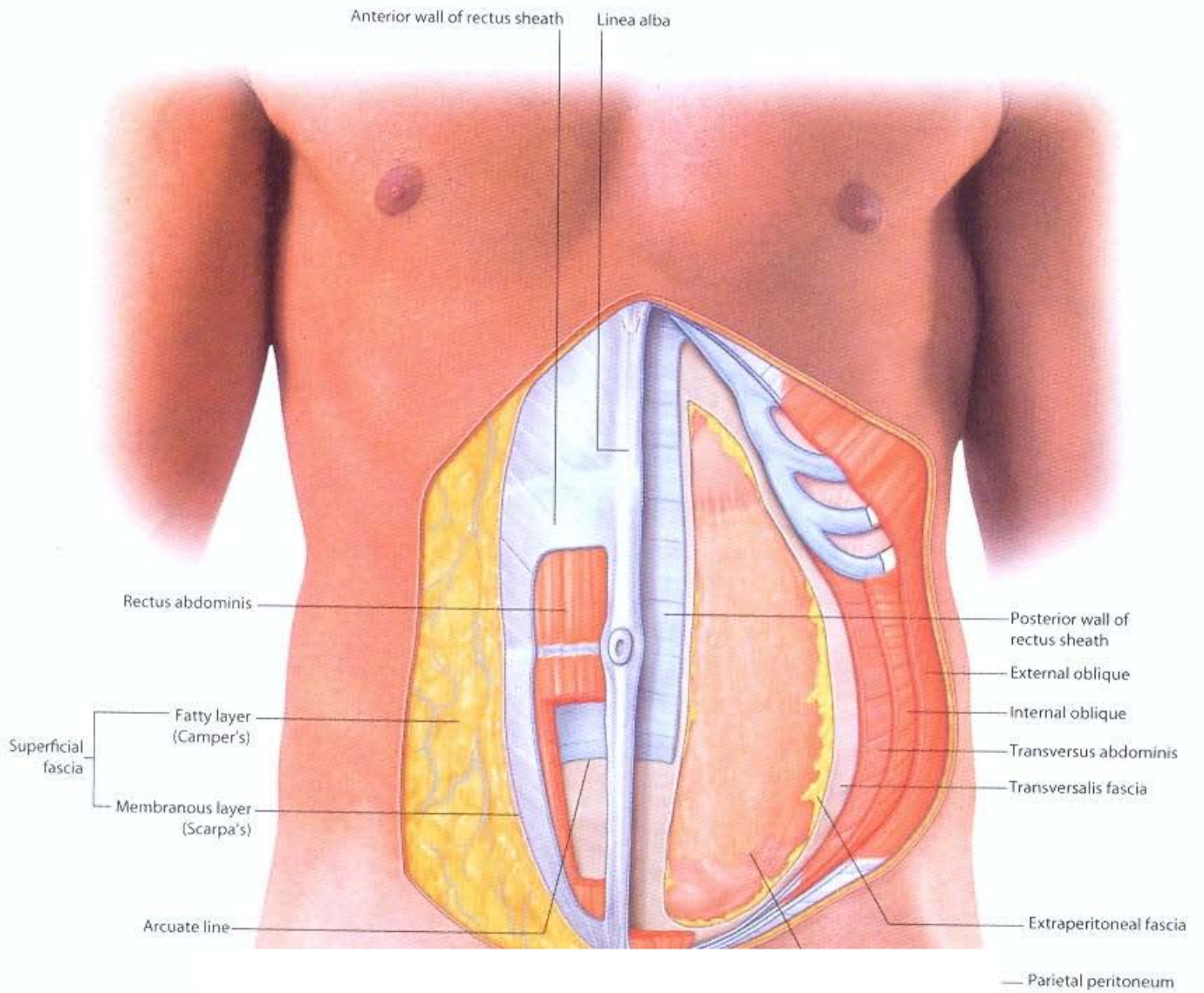
**Anterior abdominal wall surface anatomy**



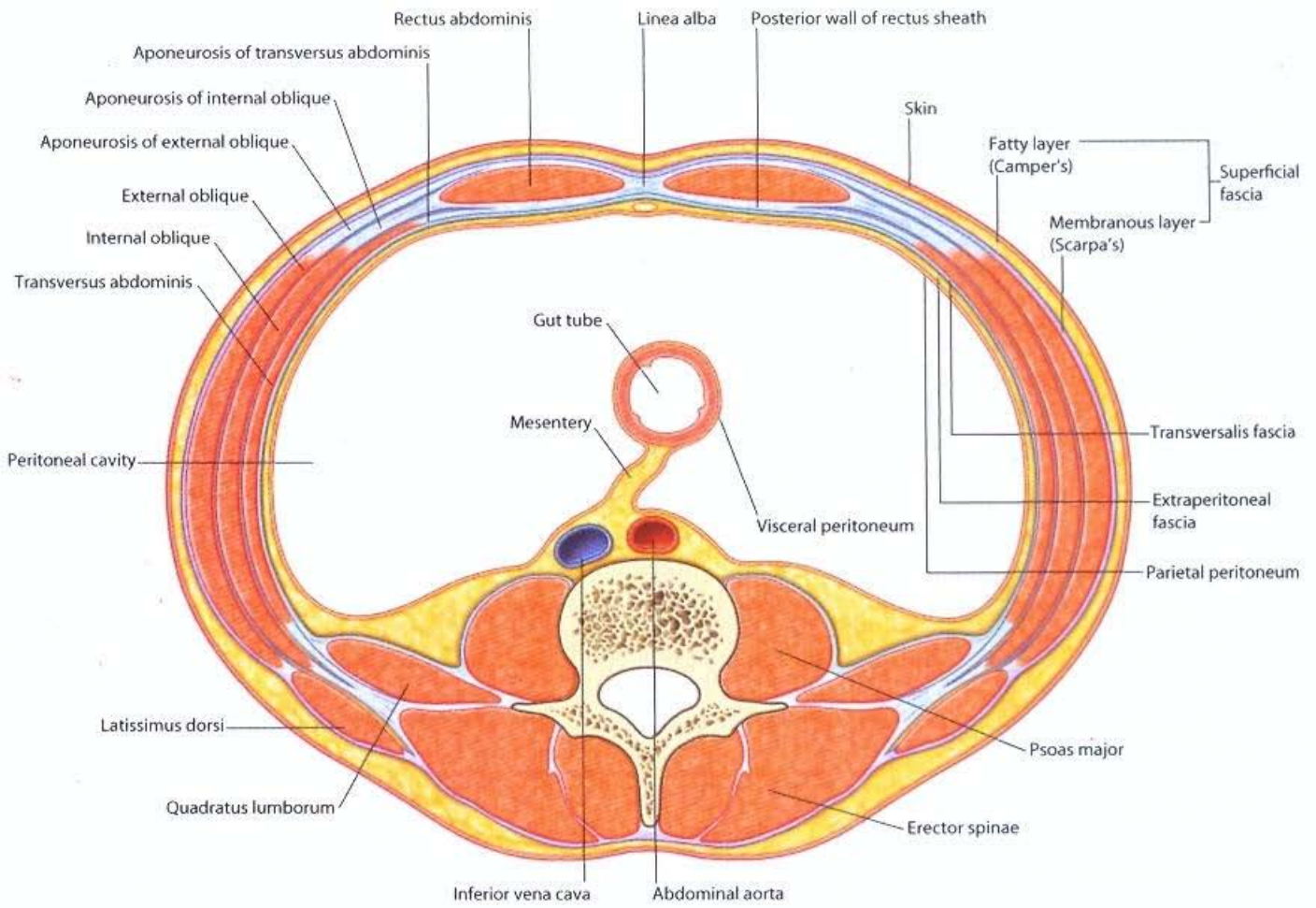
Abdominal quadrants and the positions of major viscera



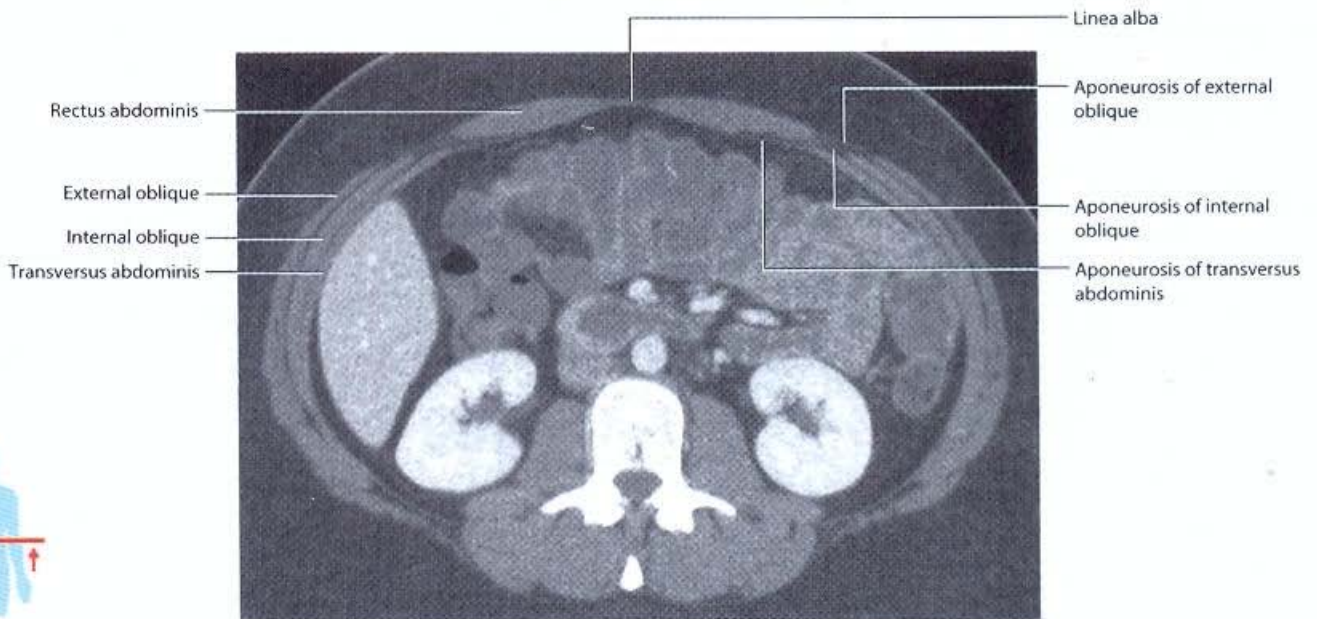
The nine regions of the abdomen



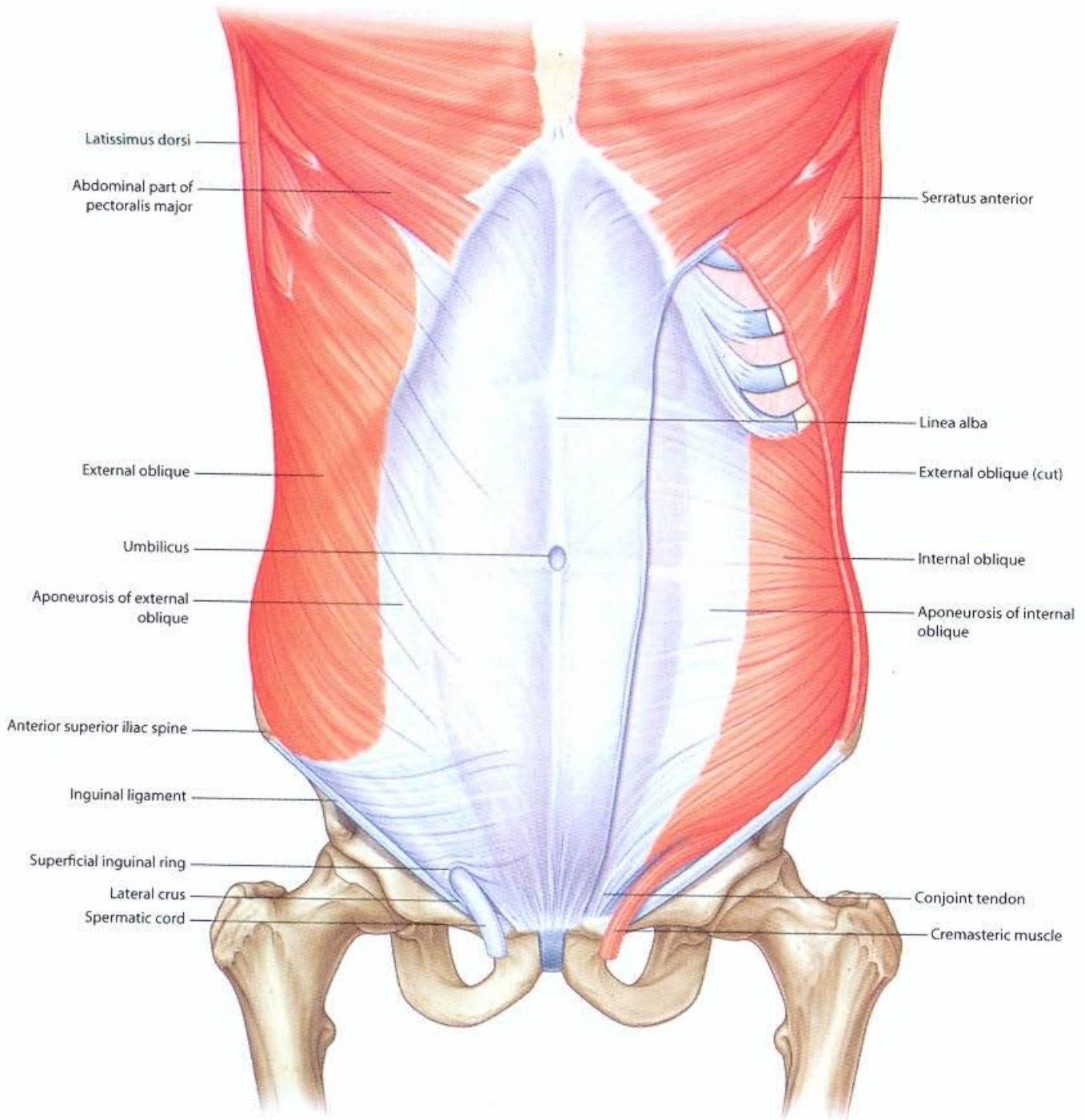
Layers of the abdominal wall



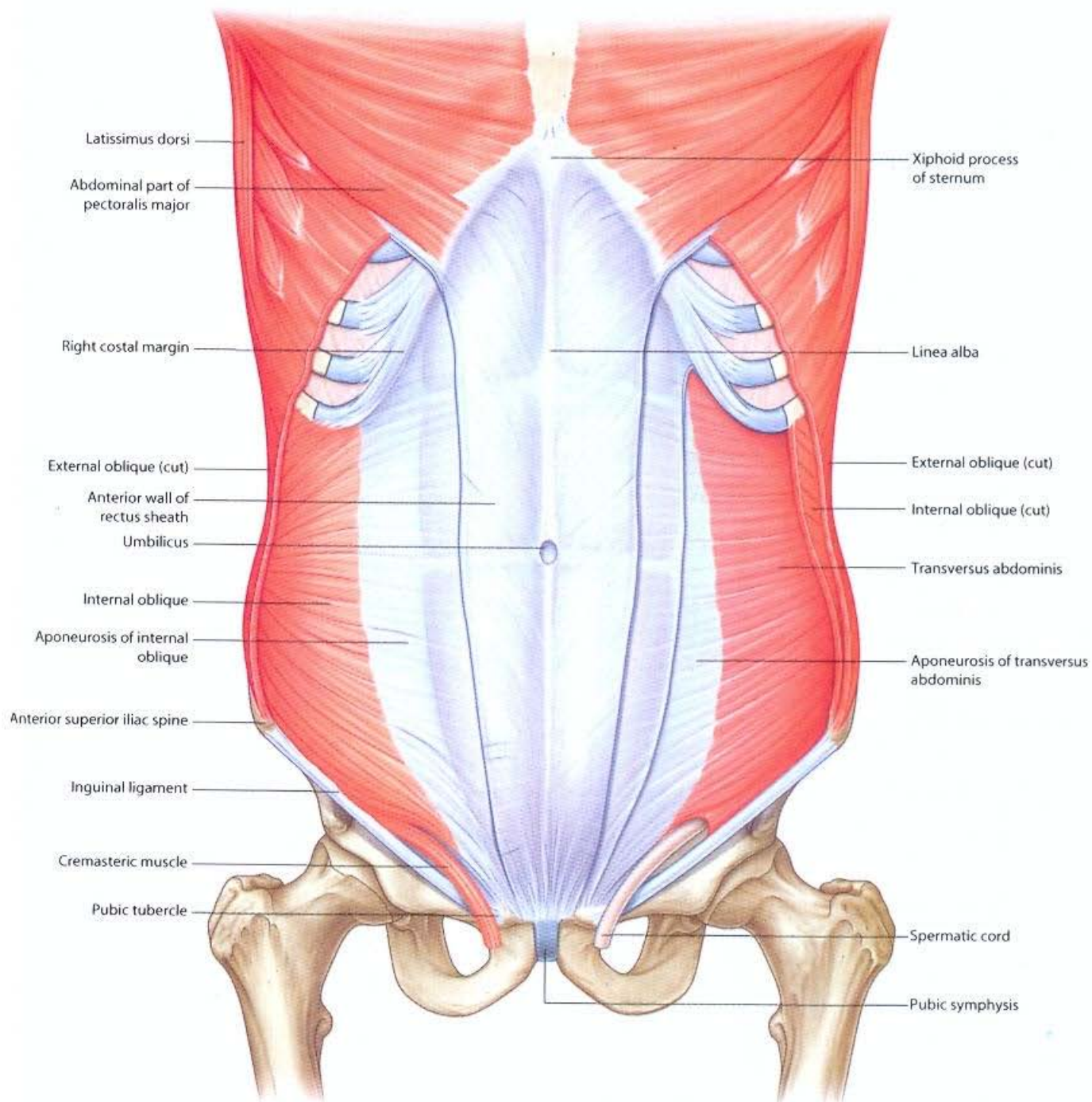
Transverse section showing the layers of the abdominal wall (above umbilicus)



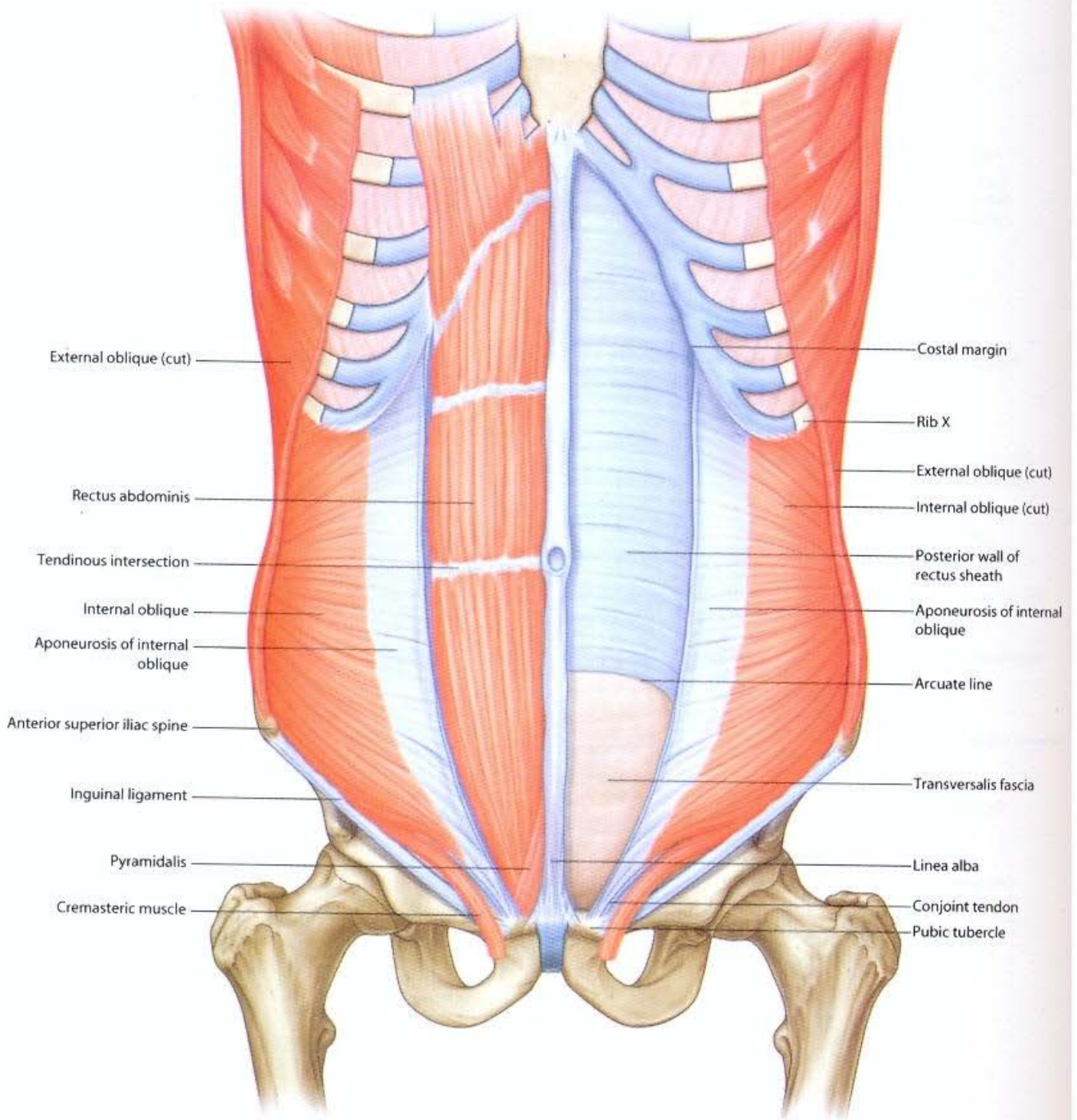
Layers of the abdominal wall. CT image, with contrast, in axial plane



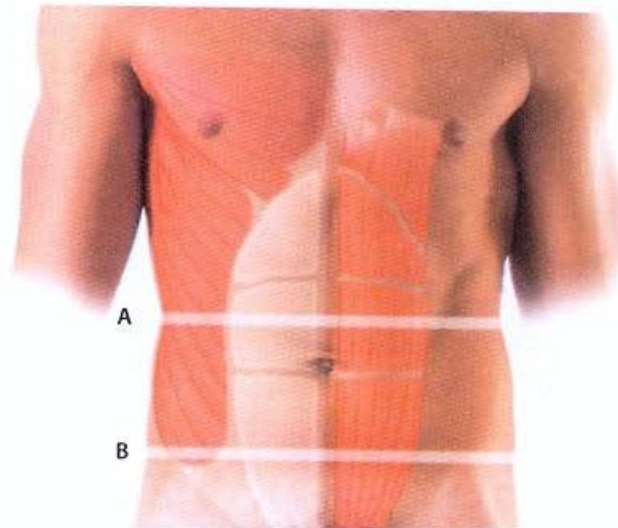
**External and internal oblique muscles**



Internal oblique and transversus abdominis muscles

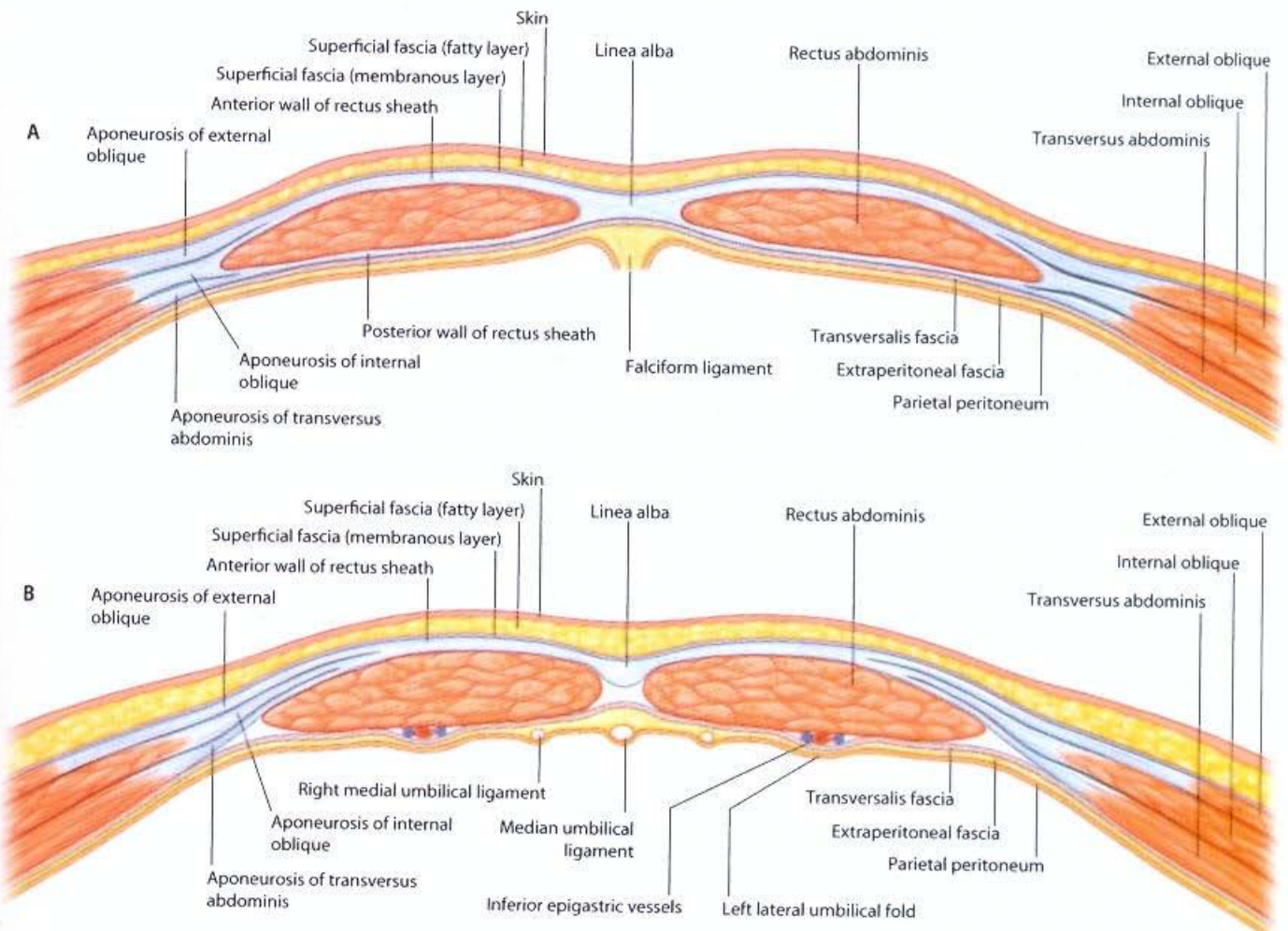


**Rectus abdominis and pyramidalis muscles**

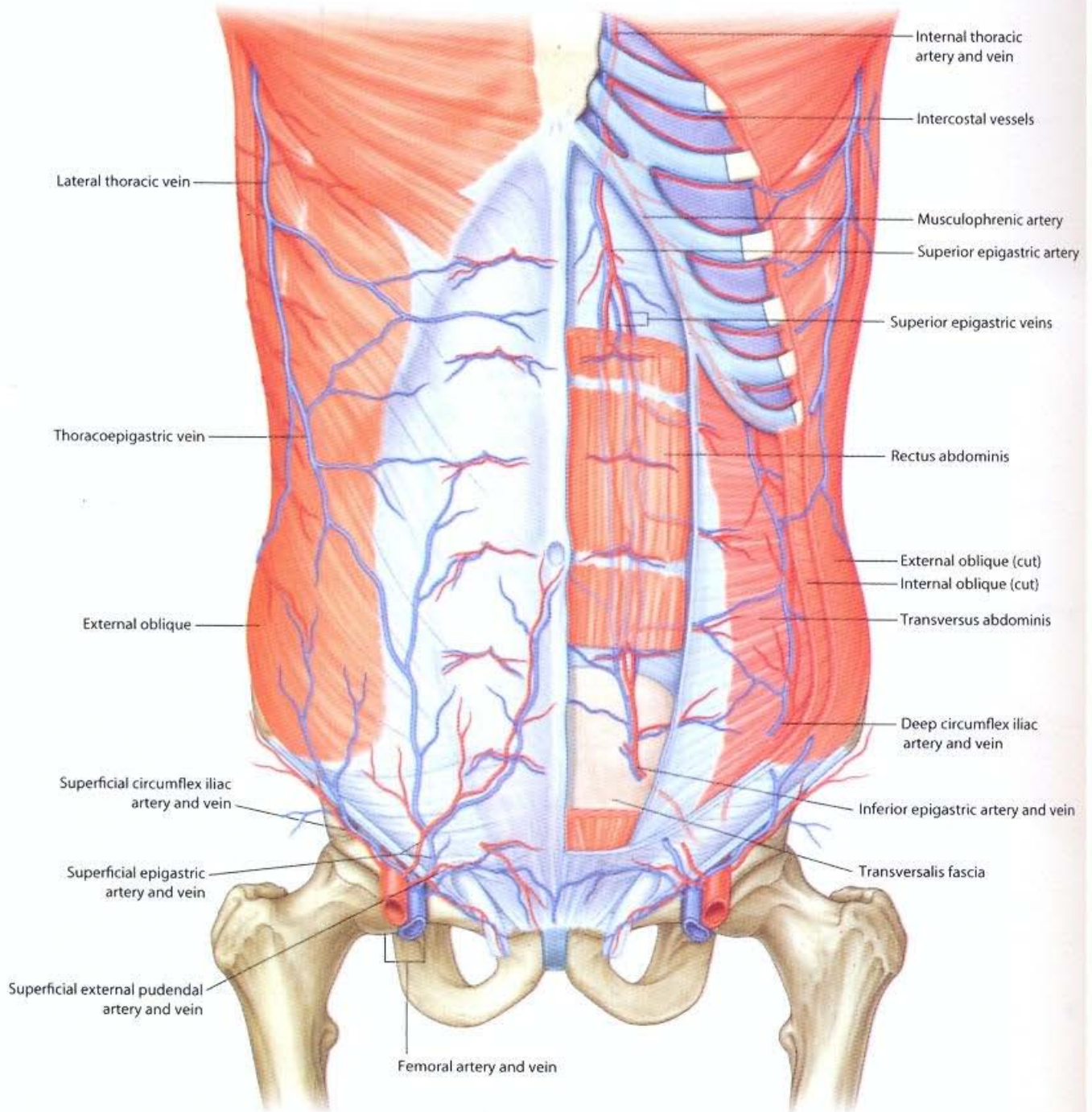


**Organization of the rectus sheath.**

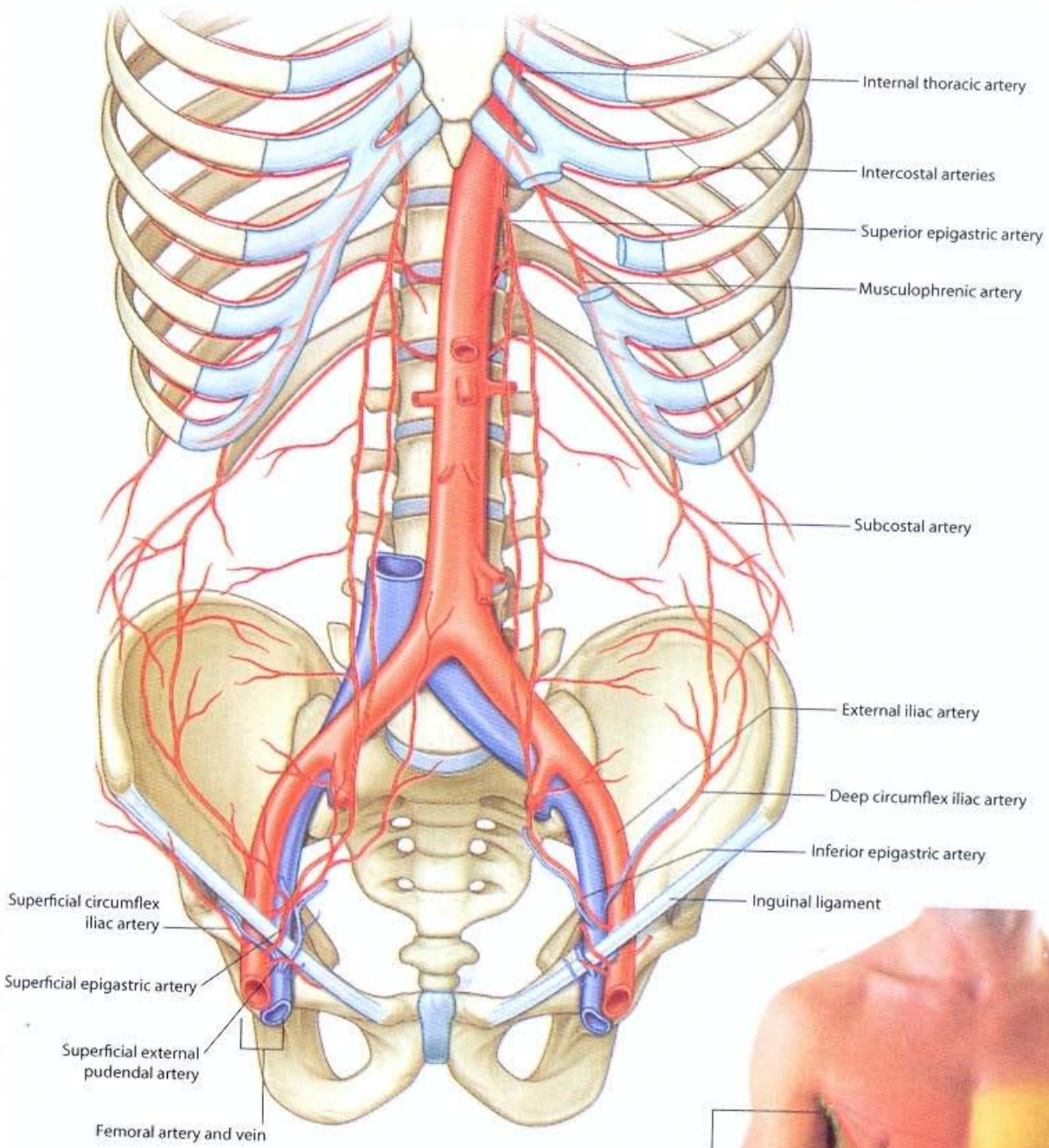
- A. Transverse section through the upper three quarters of the rectus sheath
- B. Transverse section through the lower one quarter of the rectus sheath



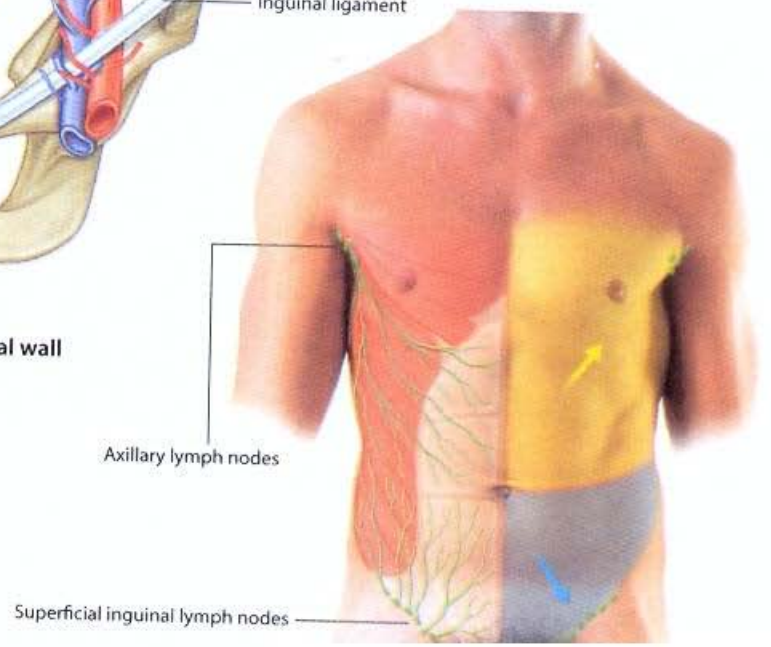




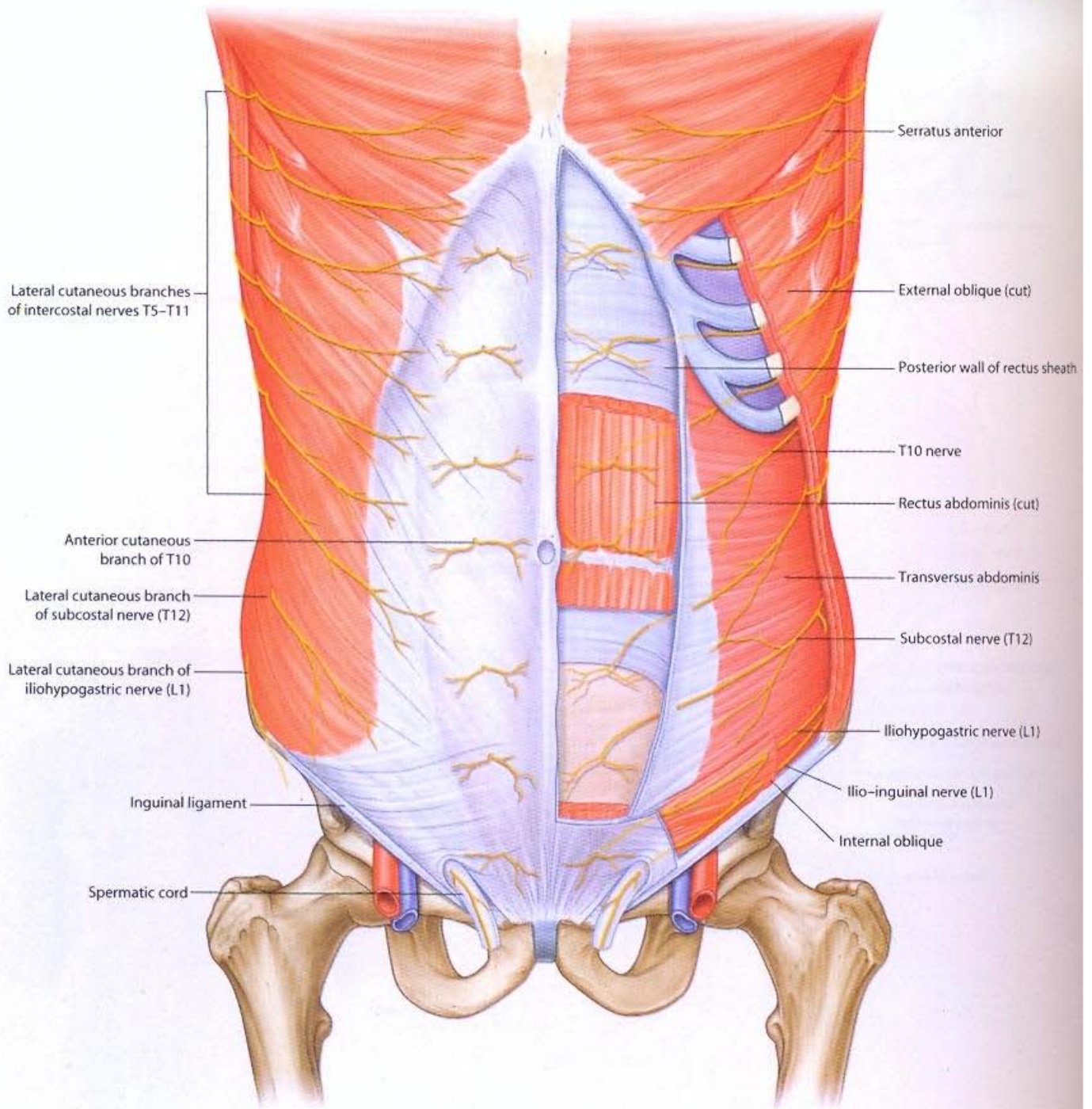
**Vasculature of the anterior abdominal wall**



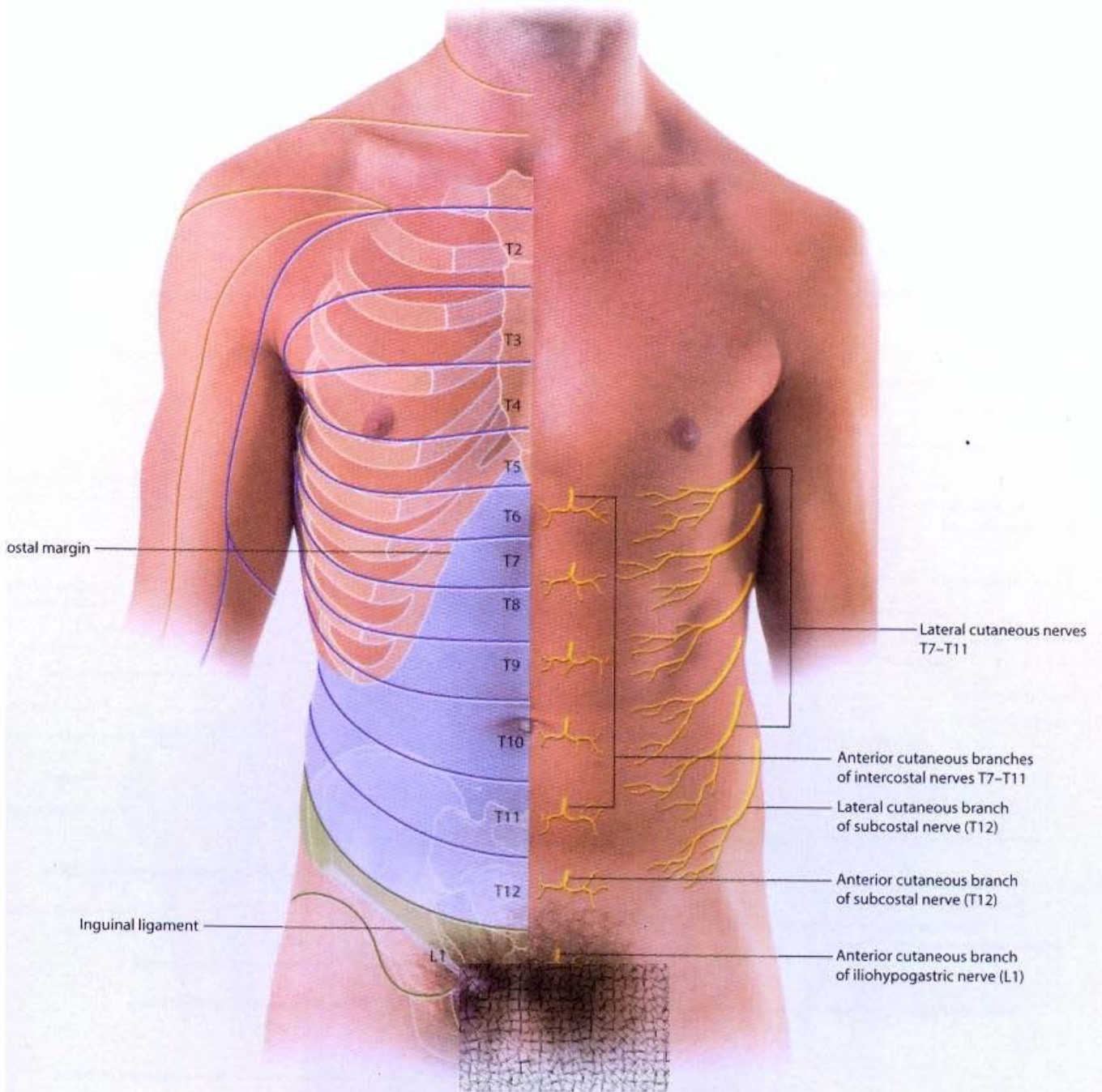
Arteries of the anterior abdominal wall



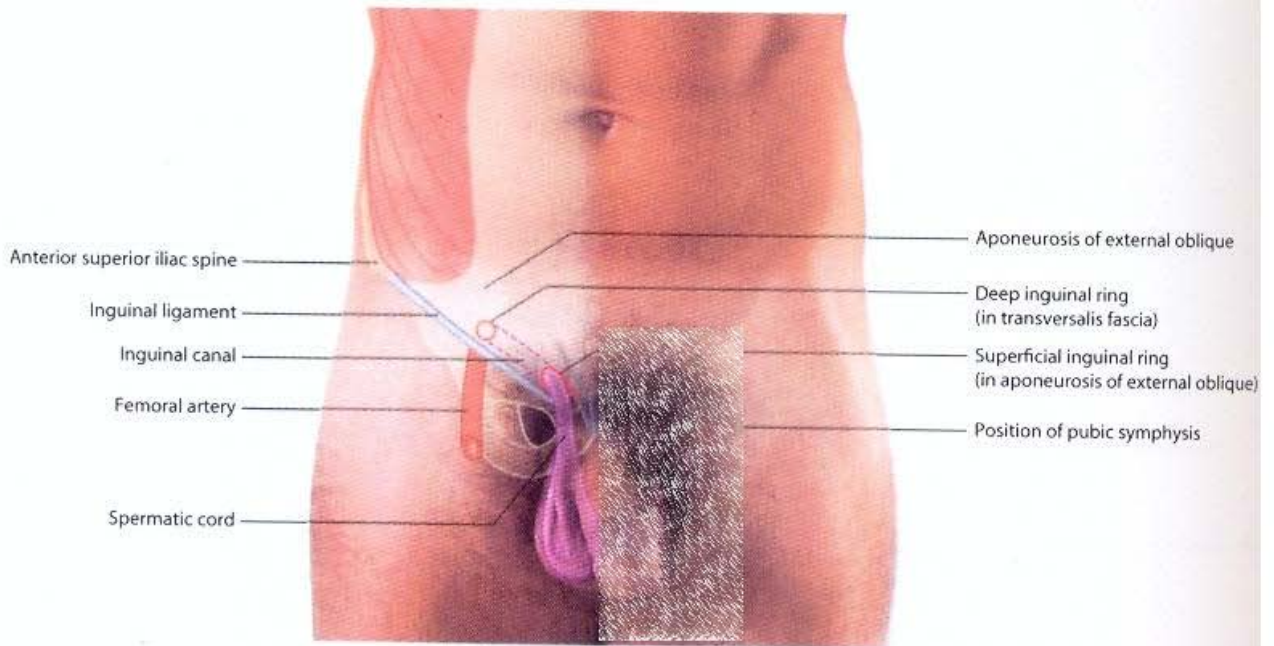
Superficial lymphatic drainage of the anterolateral abdominal wall



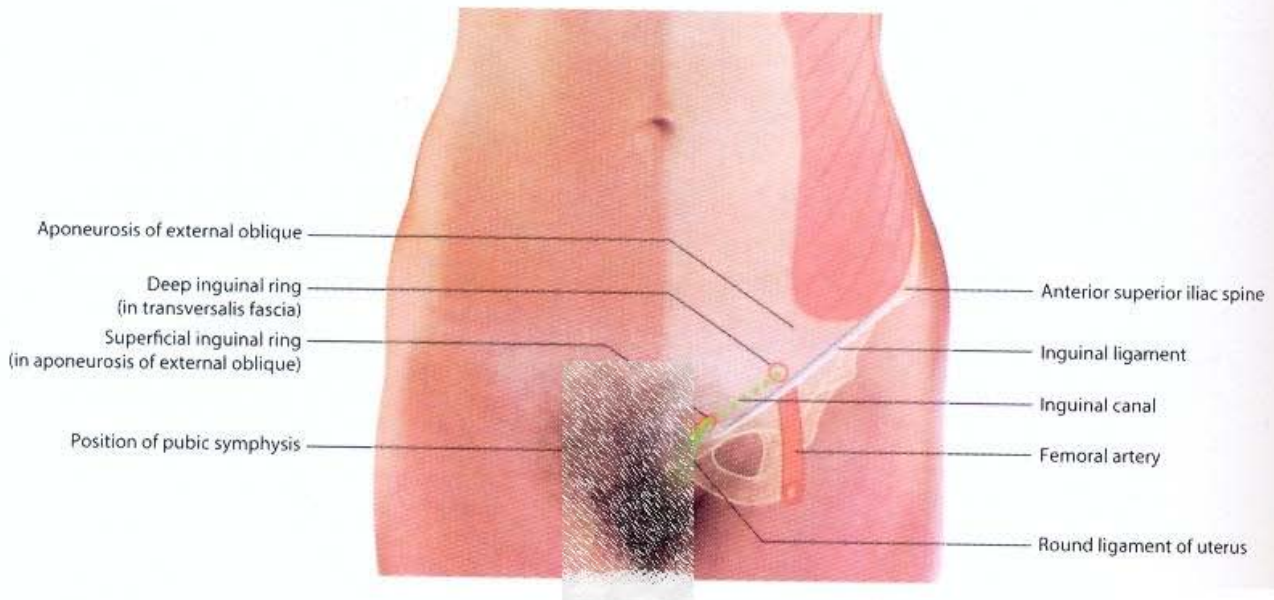
**Nerves of the anterolateral abdominal wall**



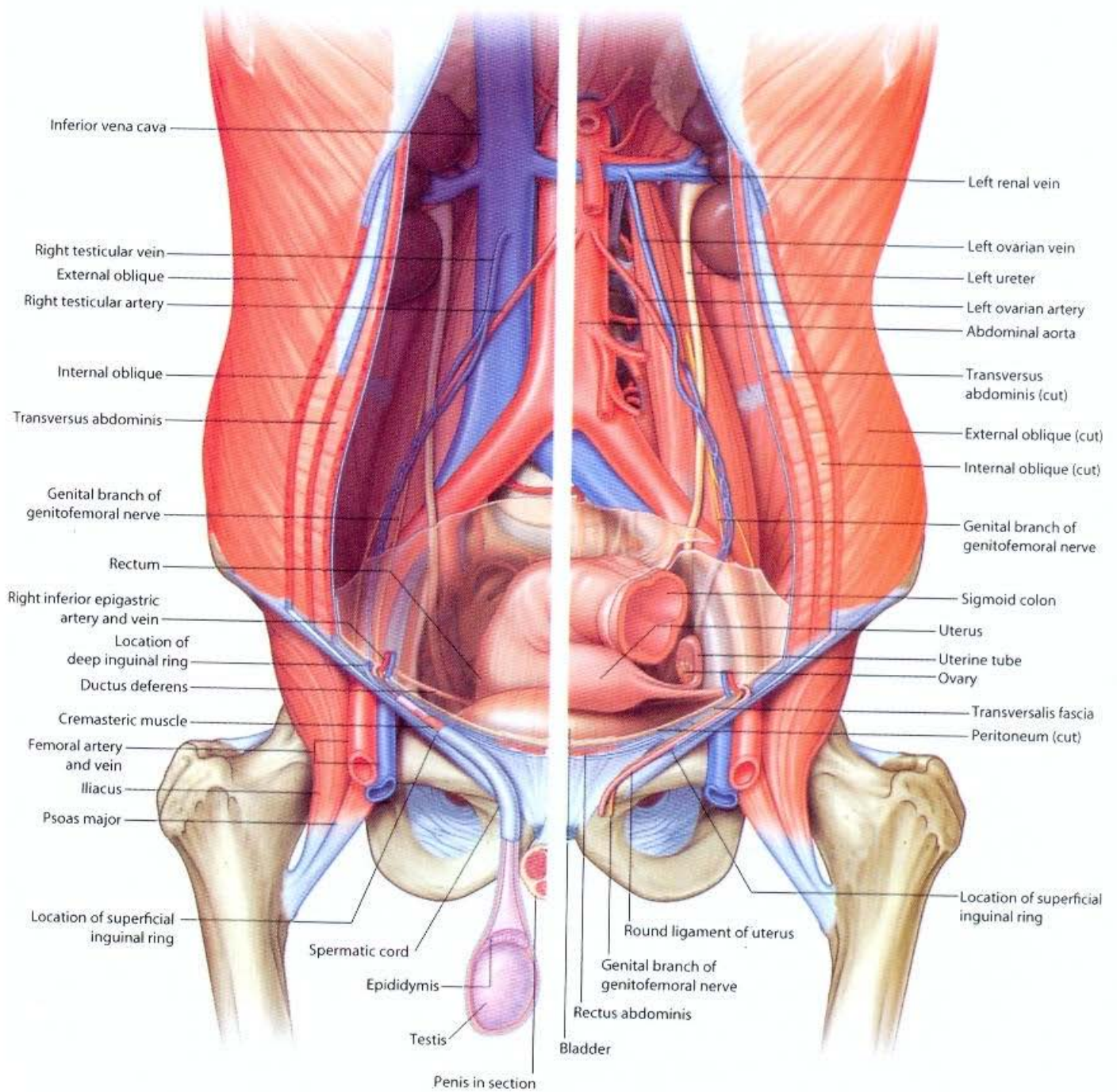
Dermatomes and cutaneous nerves of the anterolateral abdominal wall



**Inguinal region in a man**

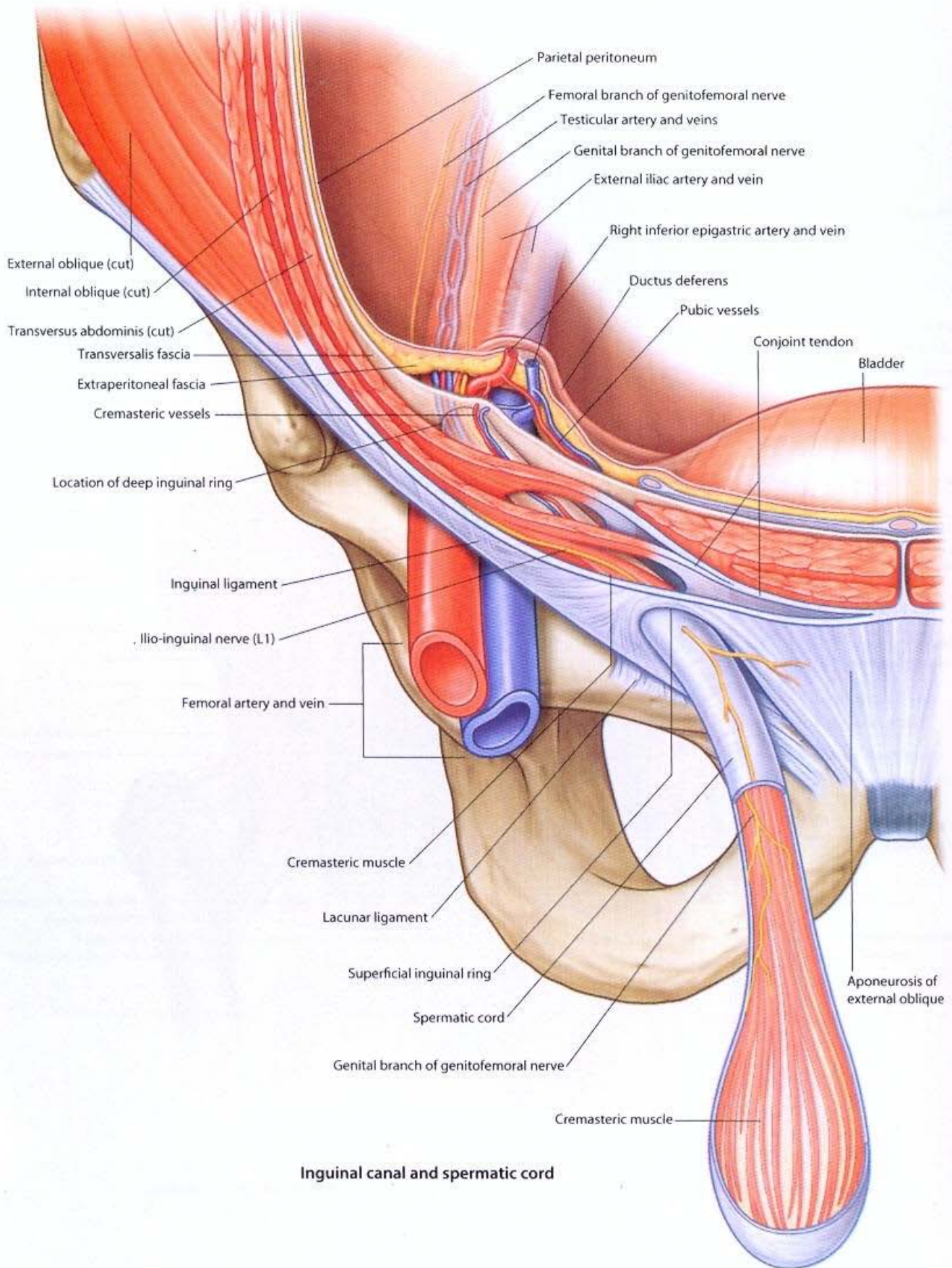


**Inguinal region in a woman**

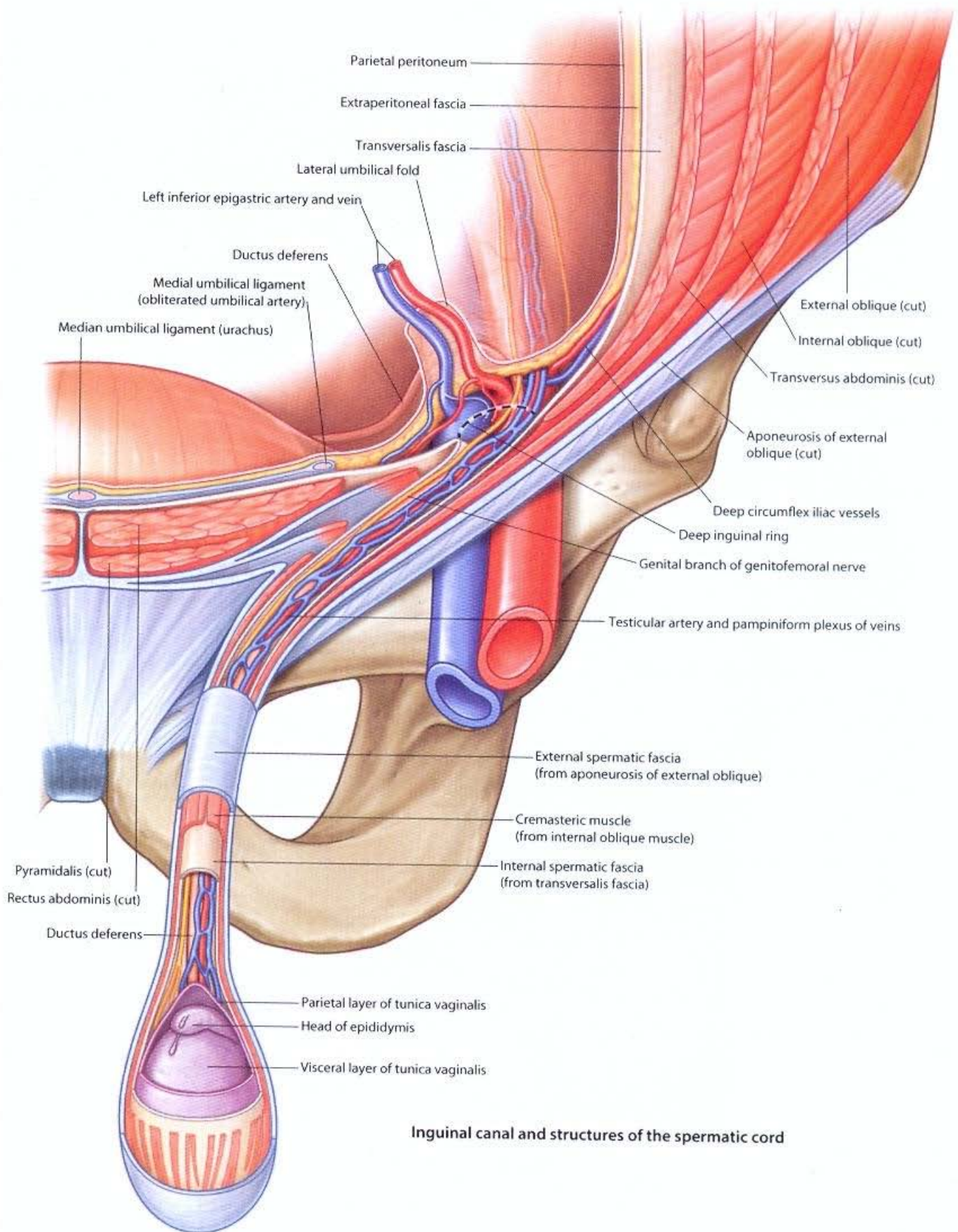


Inguinal region in men

Inguinal region in women

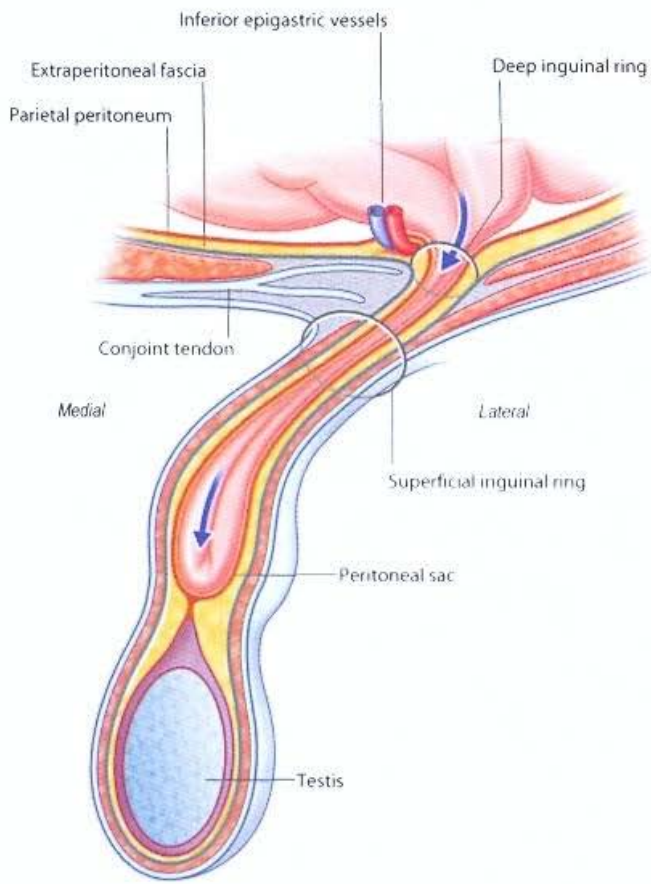


**Inguinal canal and spermatic cord**

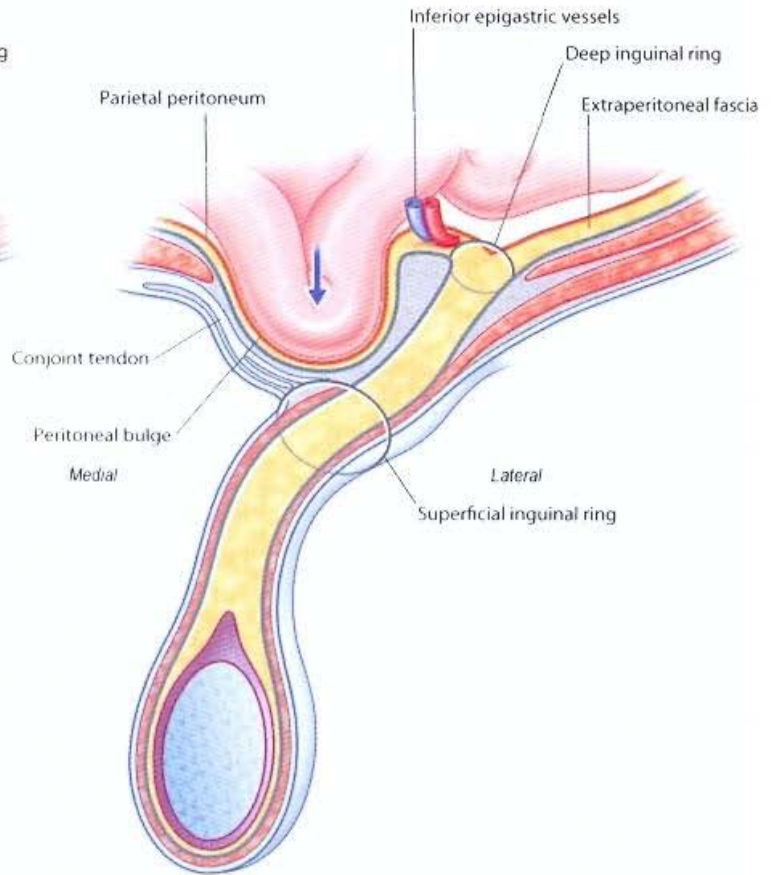


Inguinal canal and structures of the spermatic cord

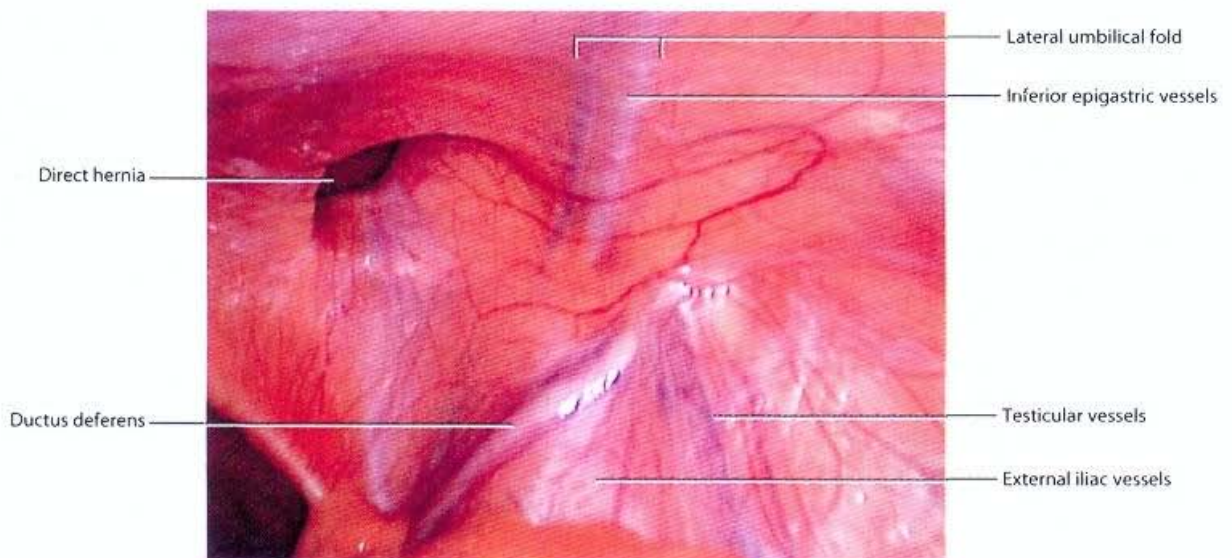




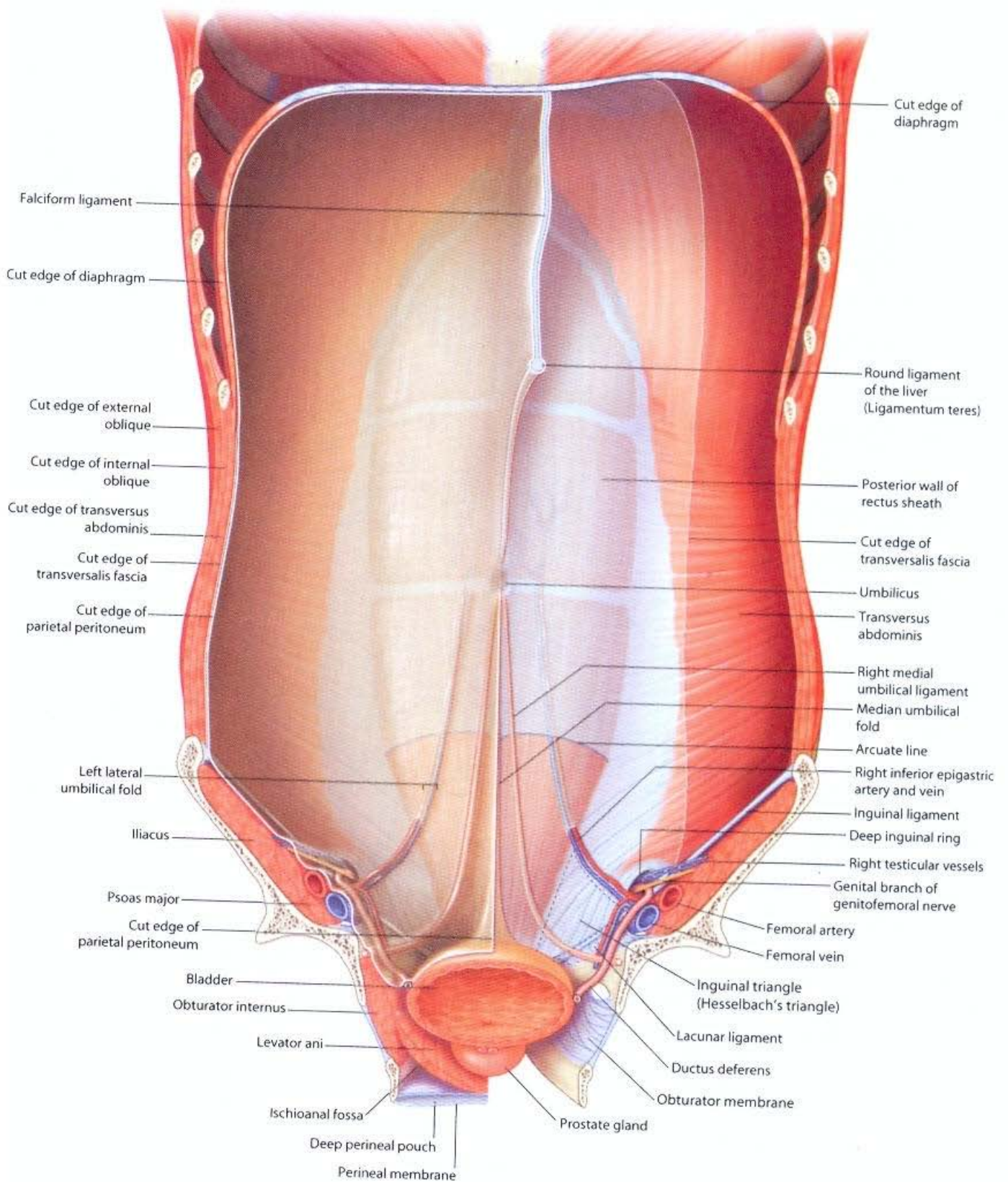
**Indirect inguinal hernia**



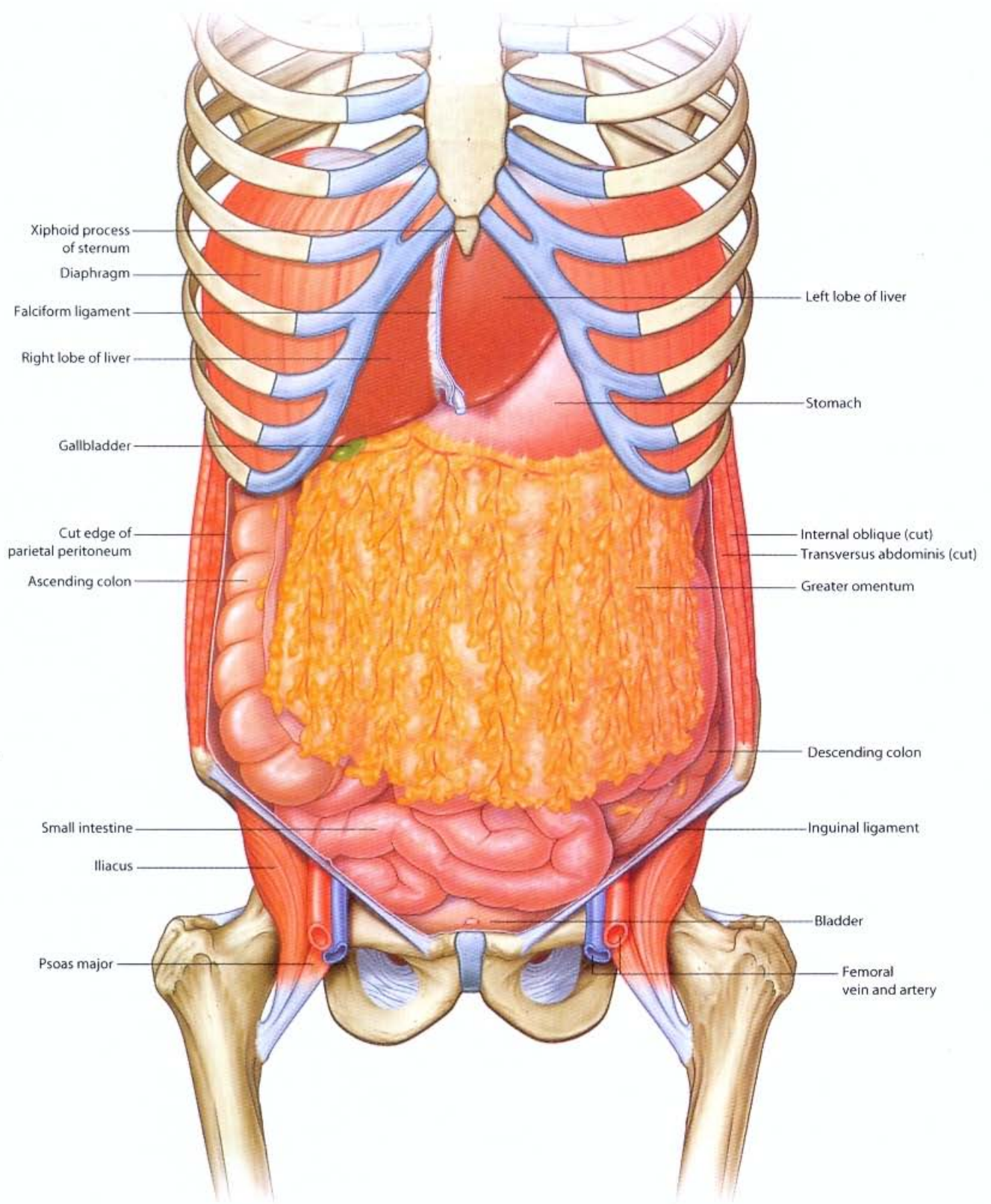
**Direct inguinal hernia**



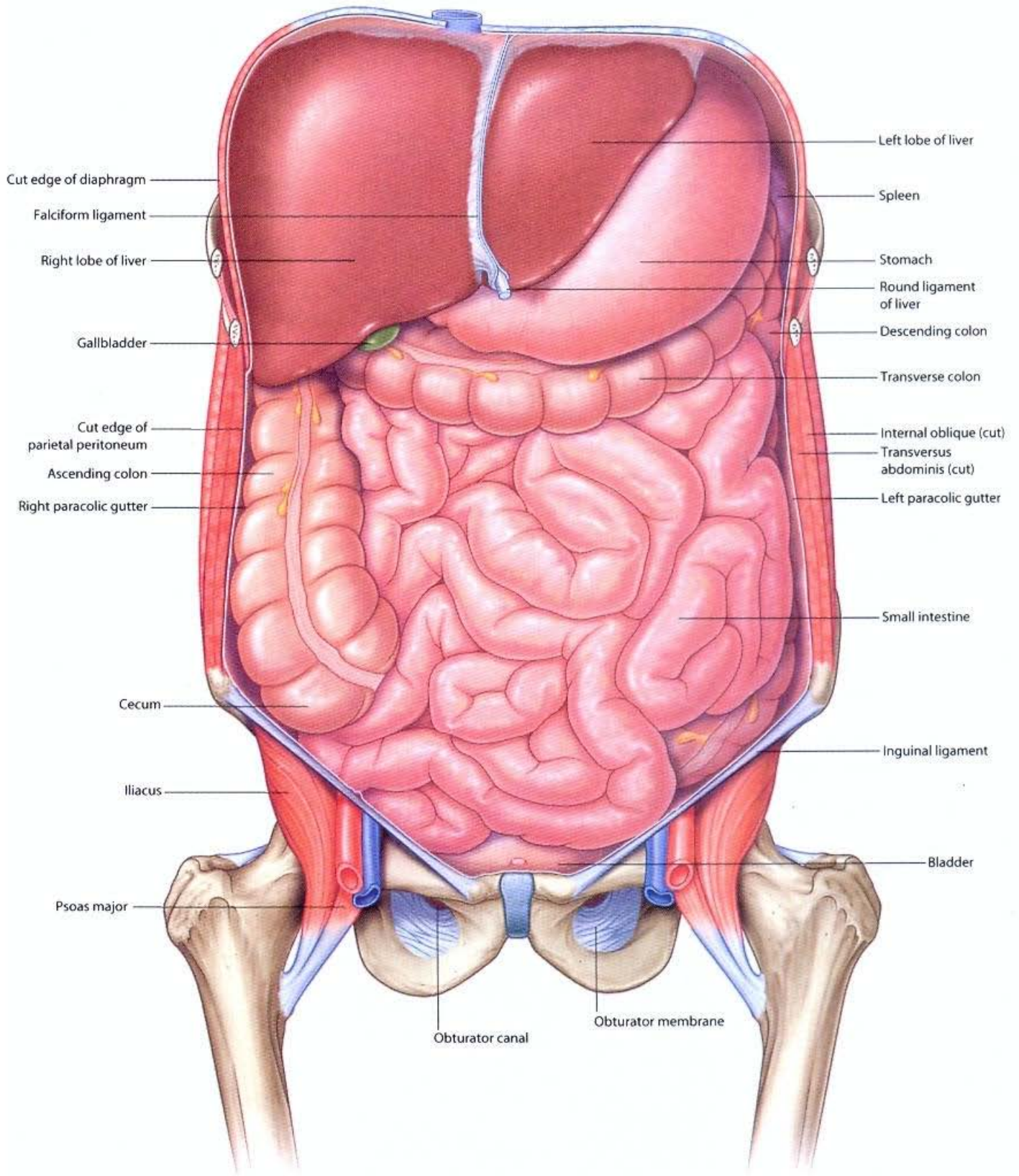
**Right inguinal triangle.**  
Laparoscopic view showing the parietal peritoneum still covering the area (inside the peritoneal cavity looking anteroinferior)



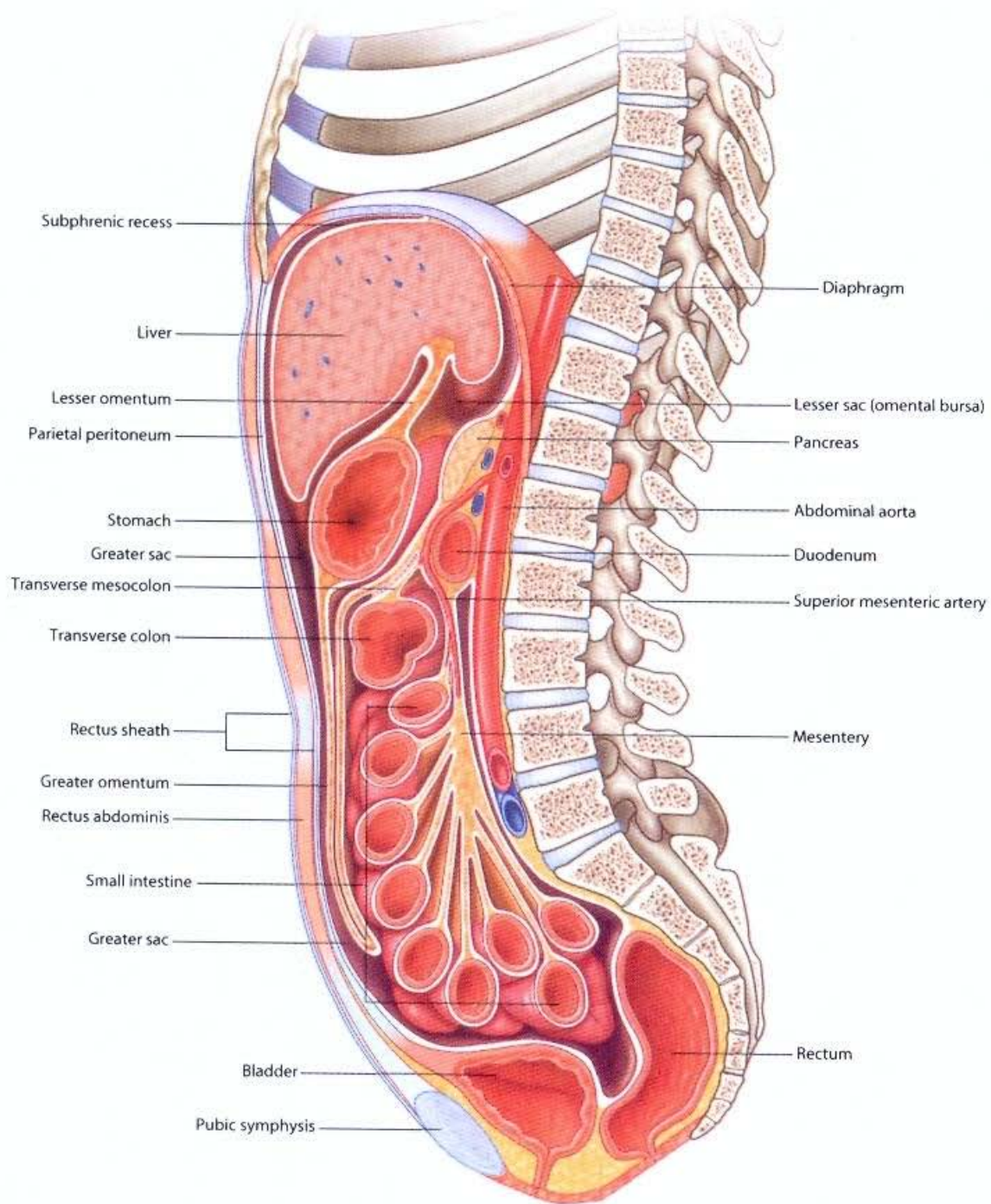
Internal view of anterior abdominal wall in men



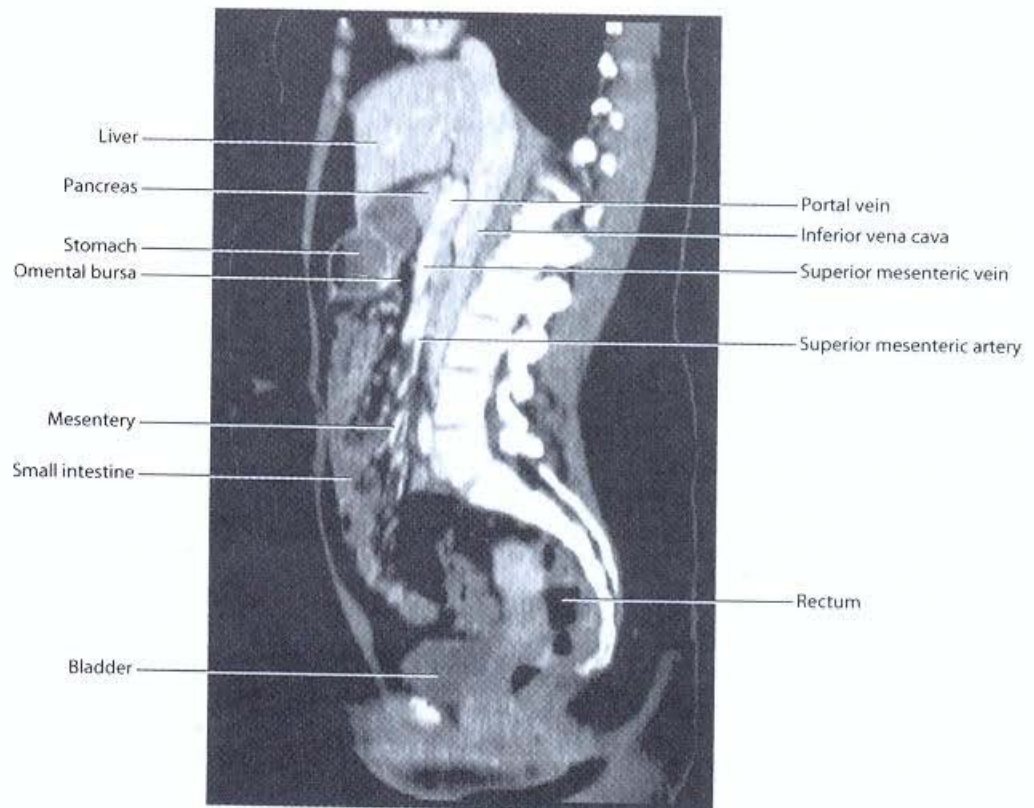
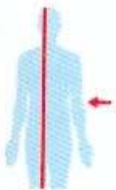
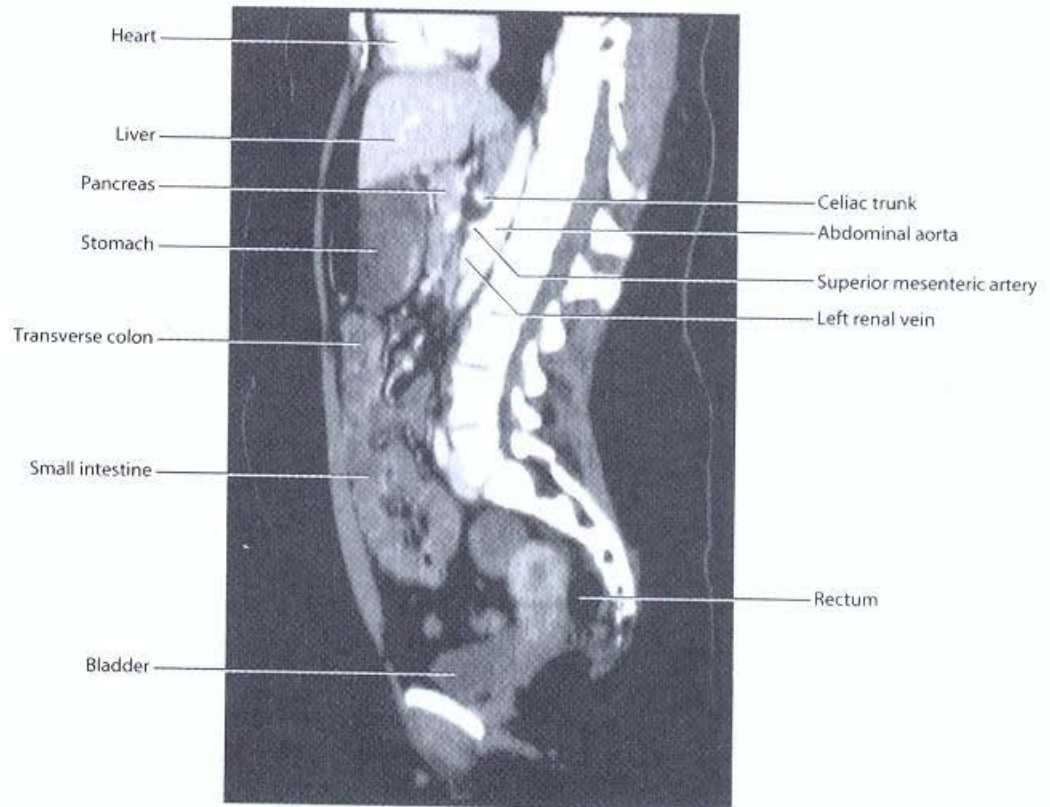
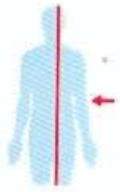
**Greater omentum**



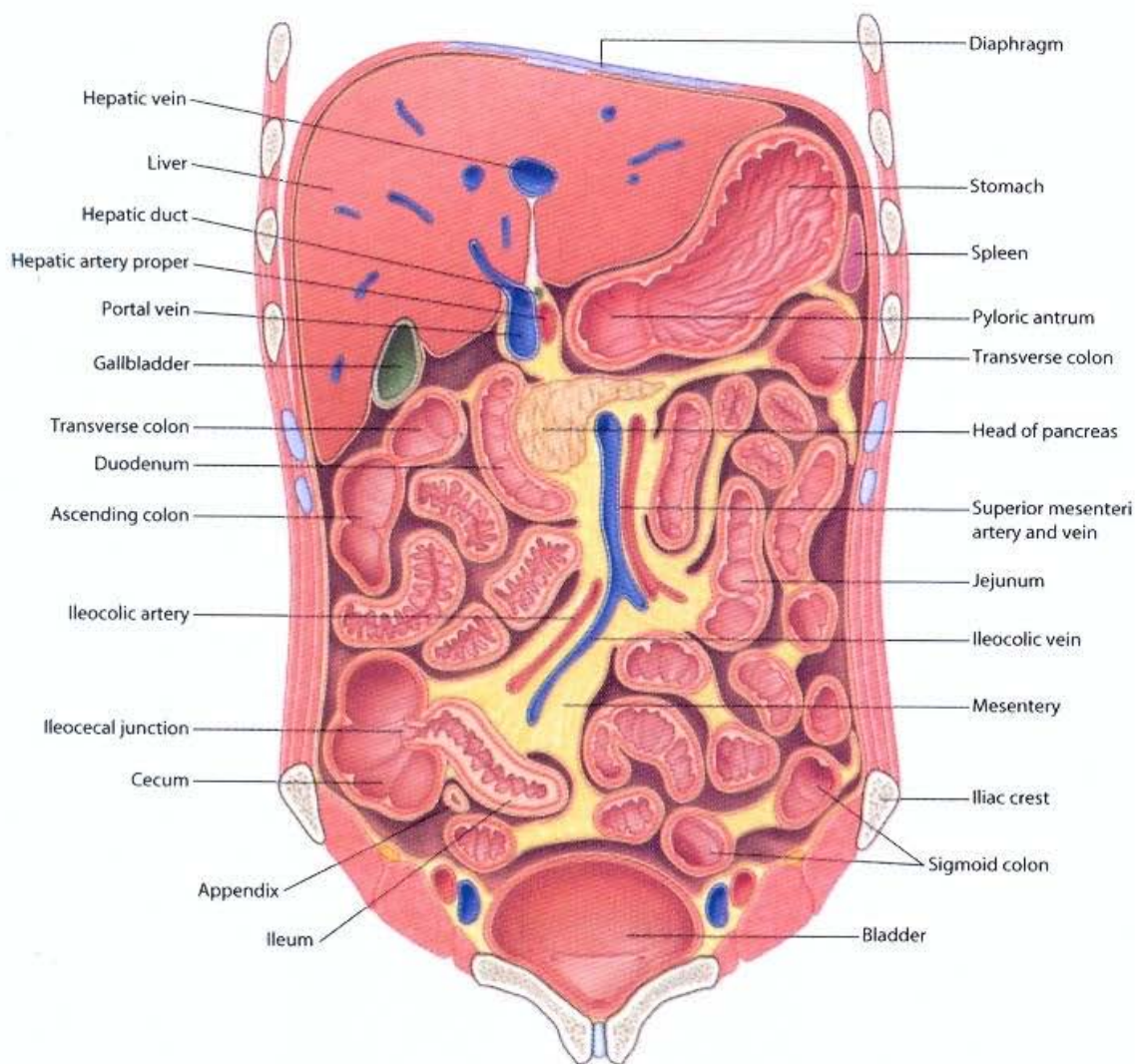
Abdominal viscera (greater omentum removed)



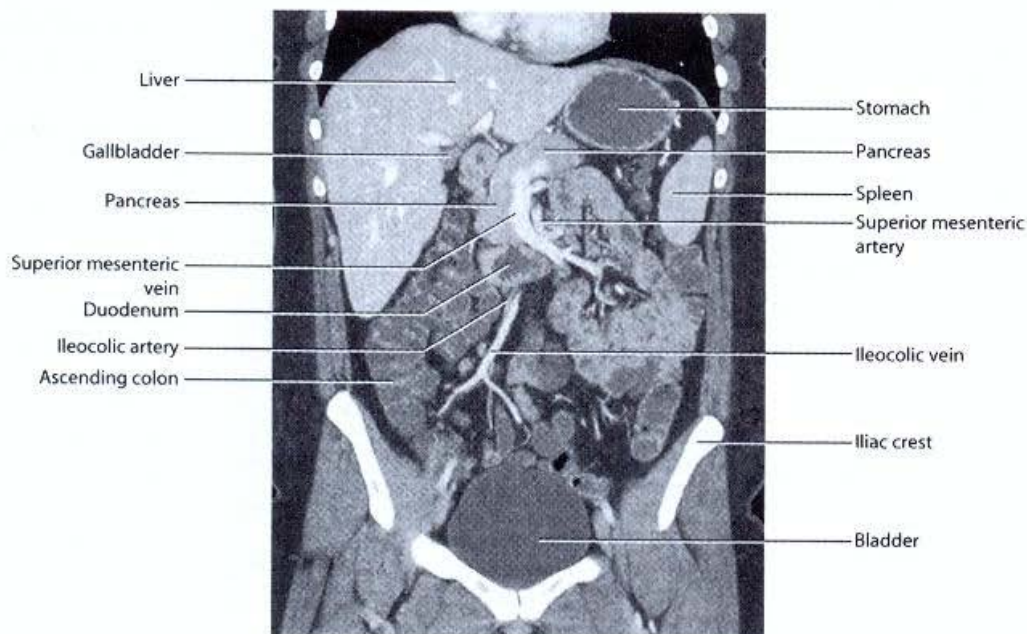
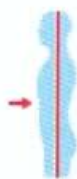
**Greater and lesser sacs of the peritoneal cavity**



Arrangement of abdominal contents in peritoneal cavity.  
CT images with contrast, in sagittal plane

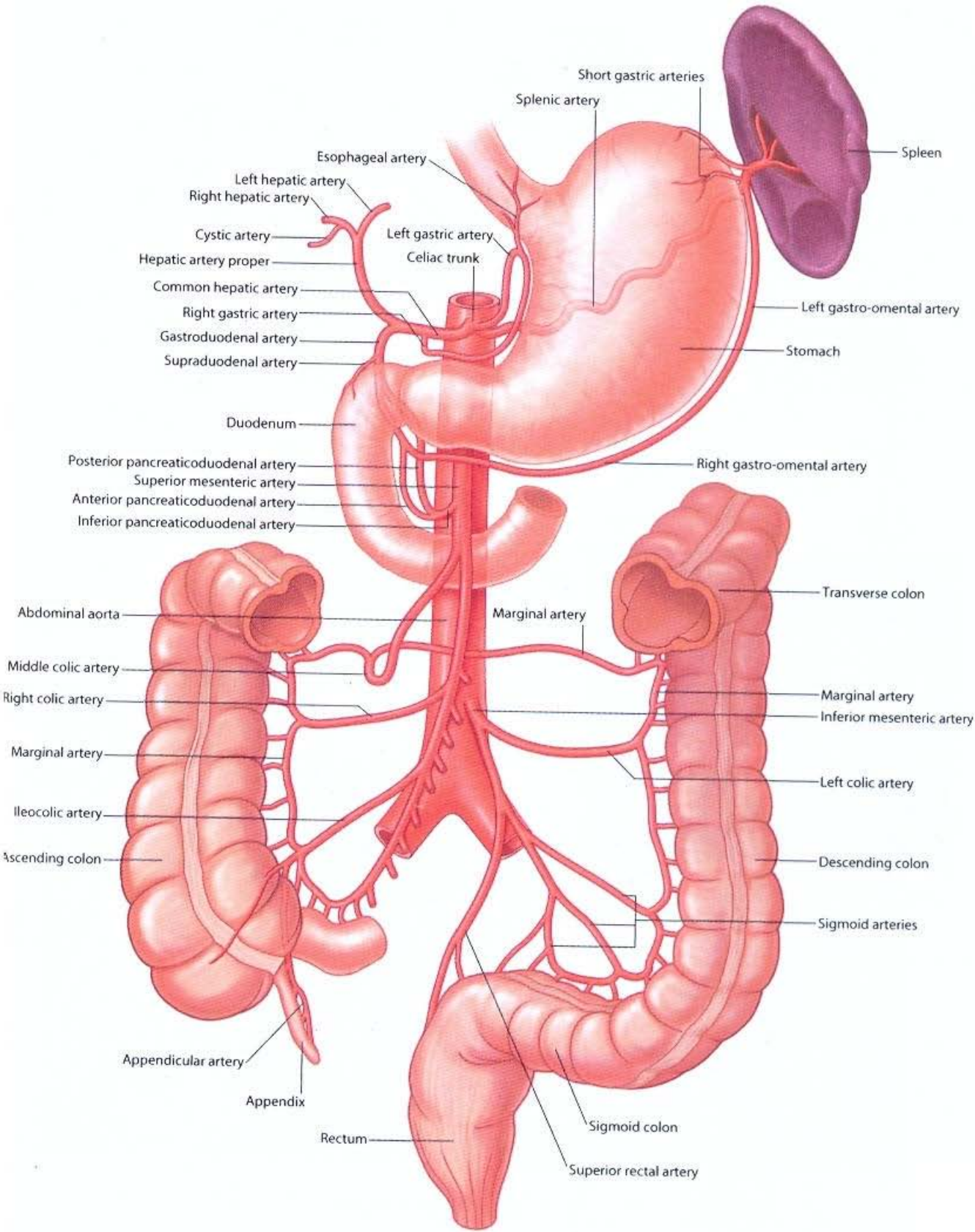


**Coronal section**

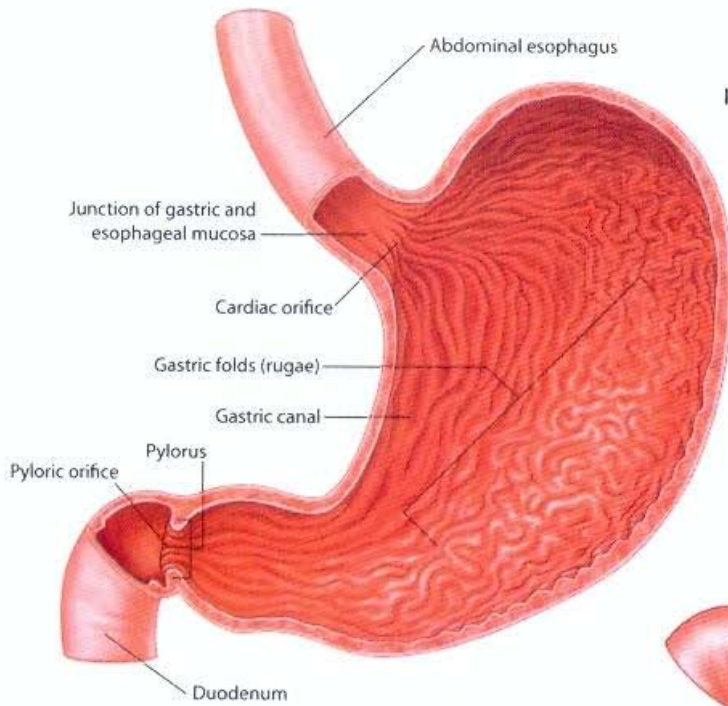


**Coronal section.**

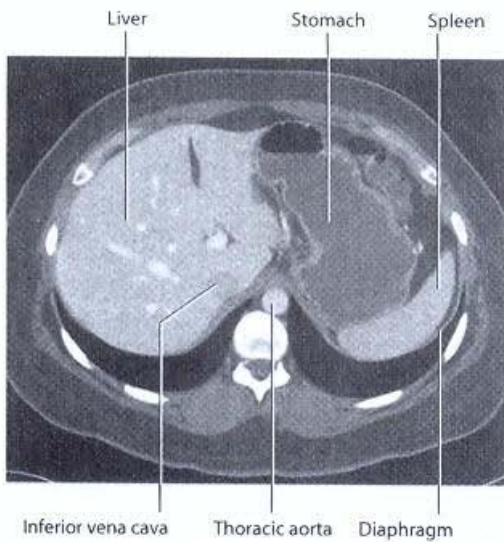
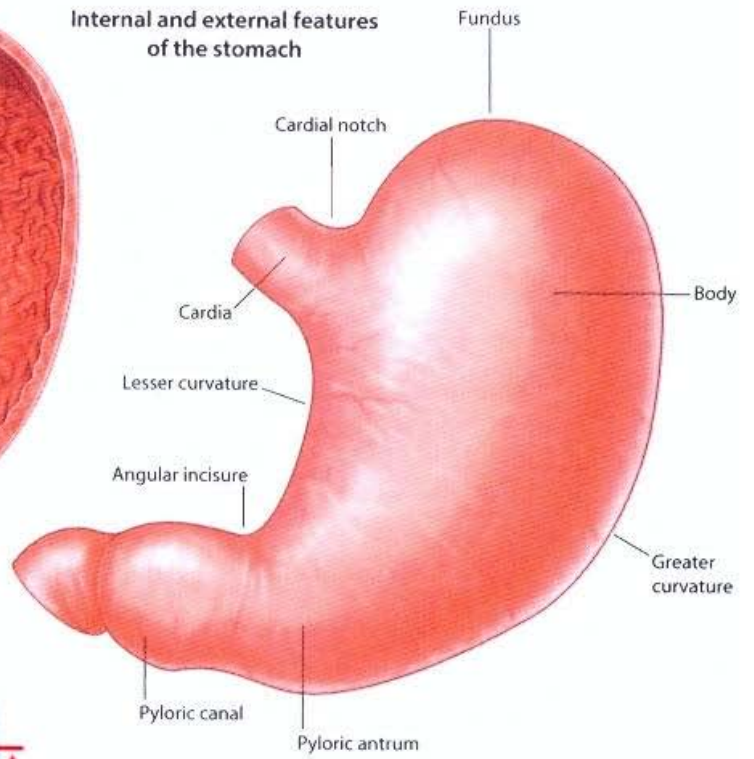
CT image with contrast, in coronal plane



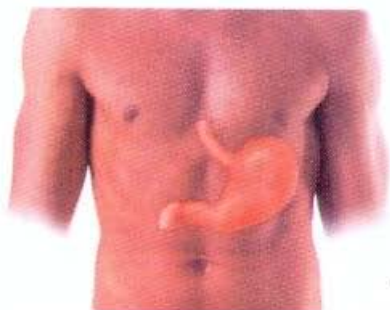



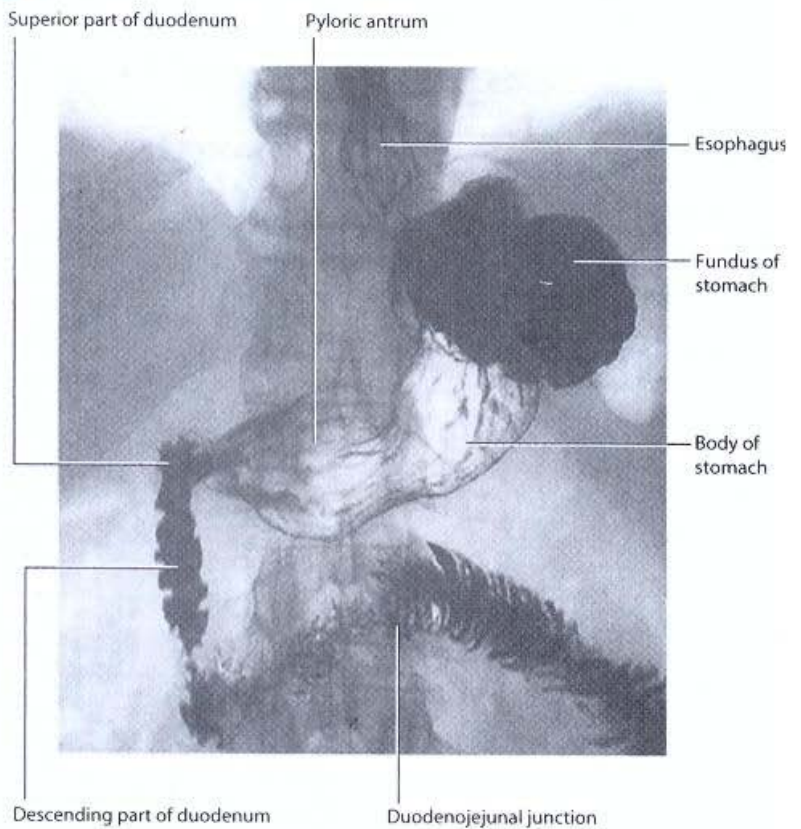
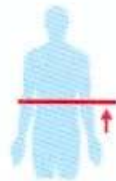
**Internal and external features of the stomach**



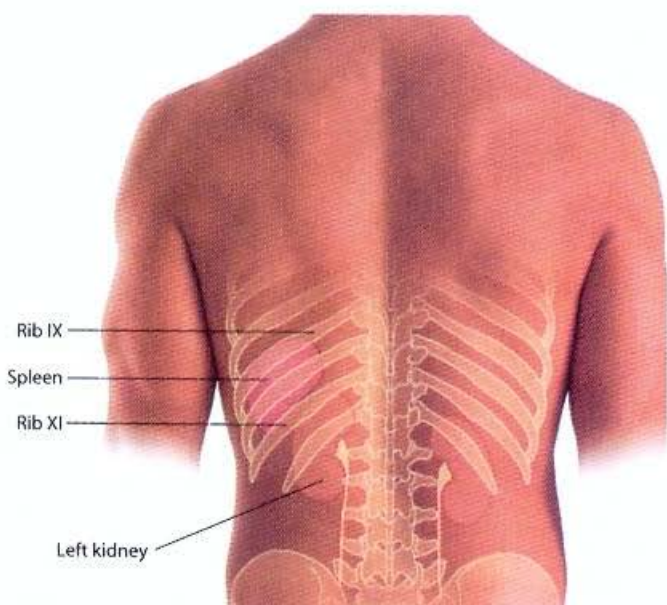
**Positioning of the stomach.**  
CT image, with contrast, in axial plane



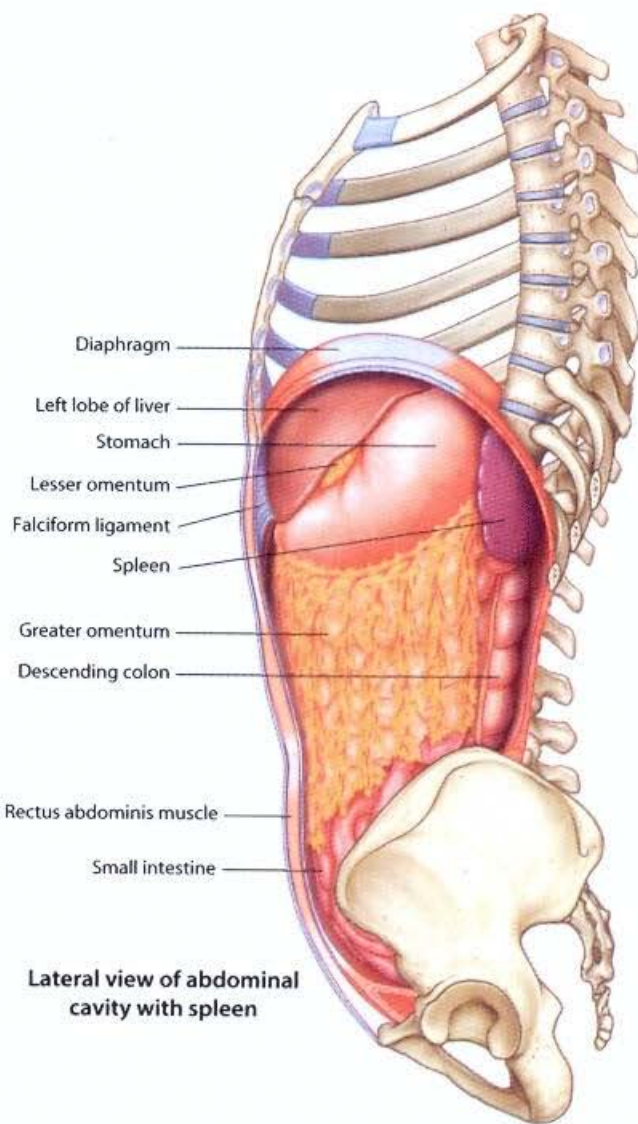
**Surface projection of the stomach**



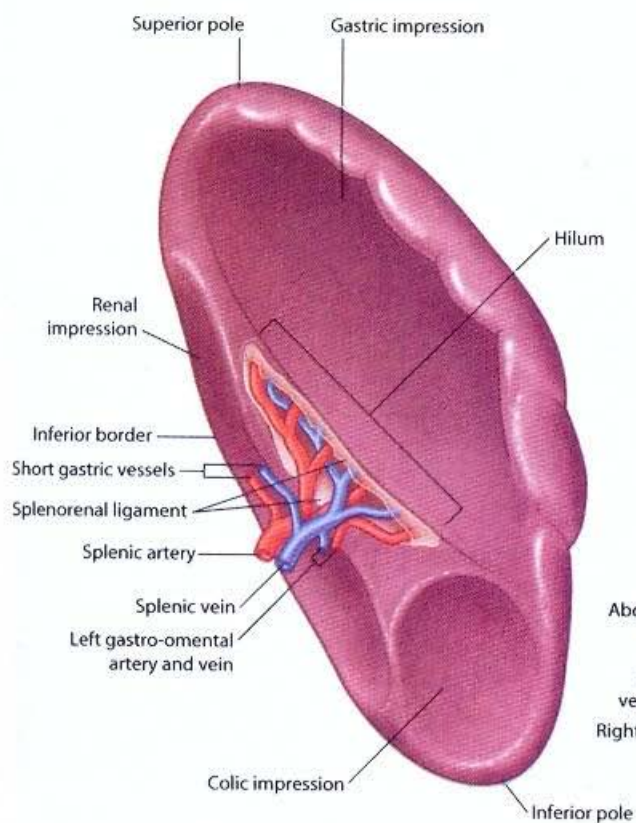
**Stomach. Double contrast radiograph using barium**



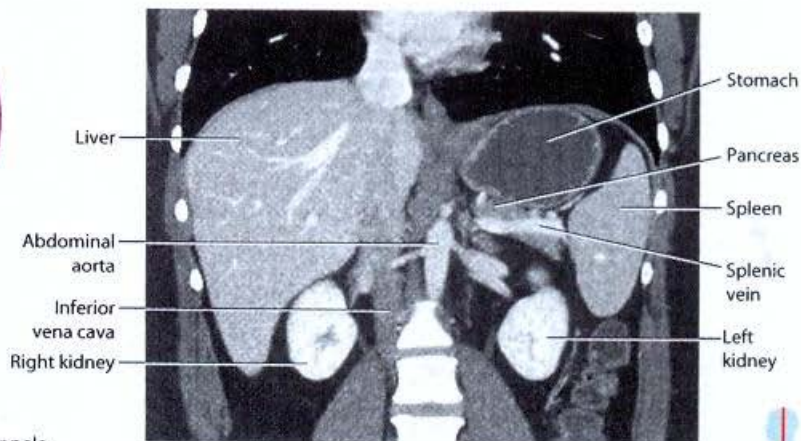
Surface projection of the spleen (posterior view)



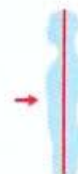Lateral view of abdominal cavity with spleen



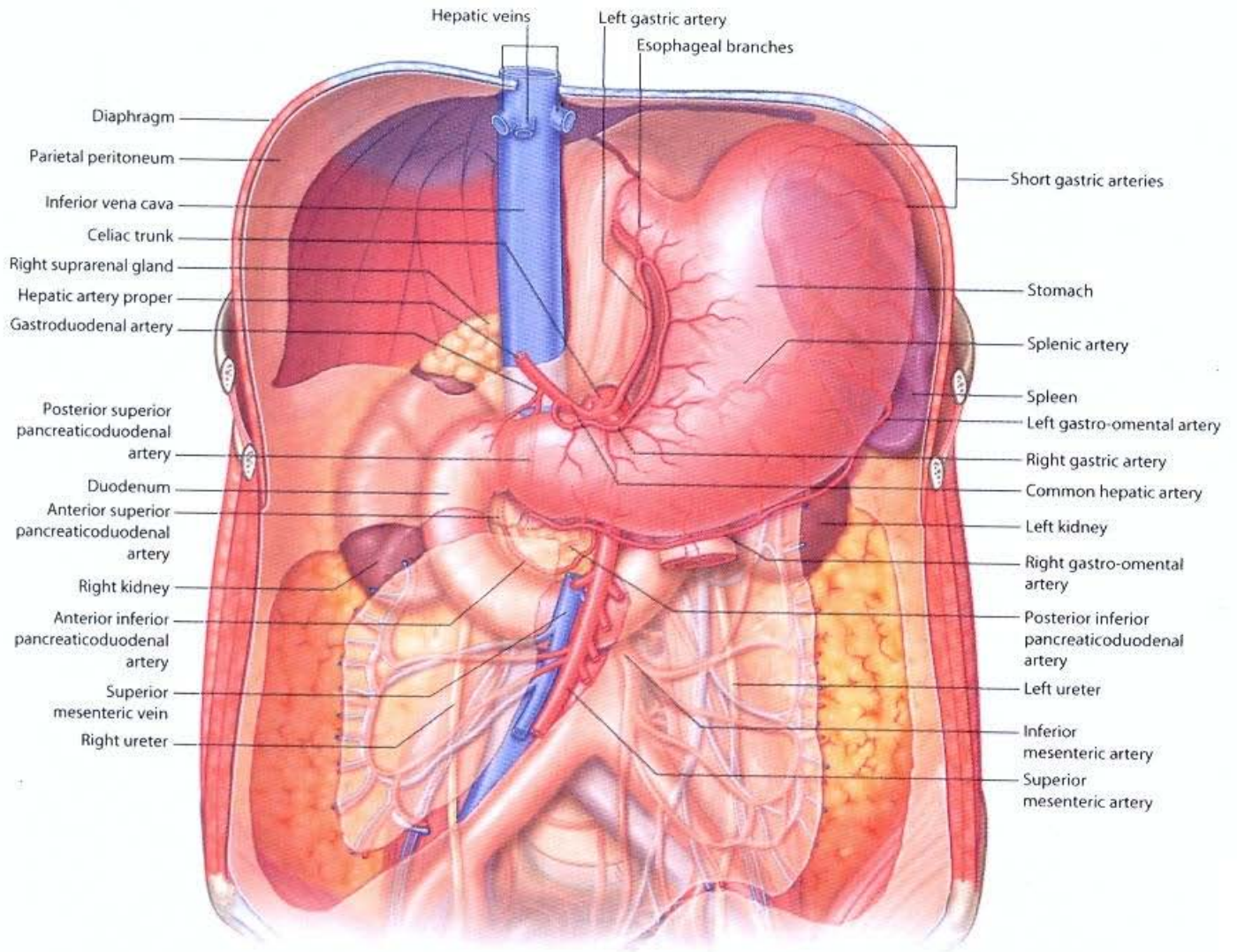
Surfaces and hilum of the spleen



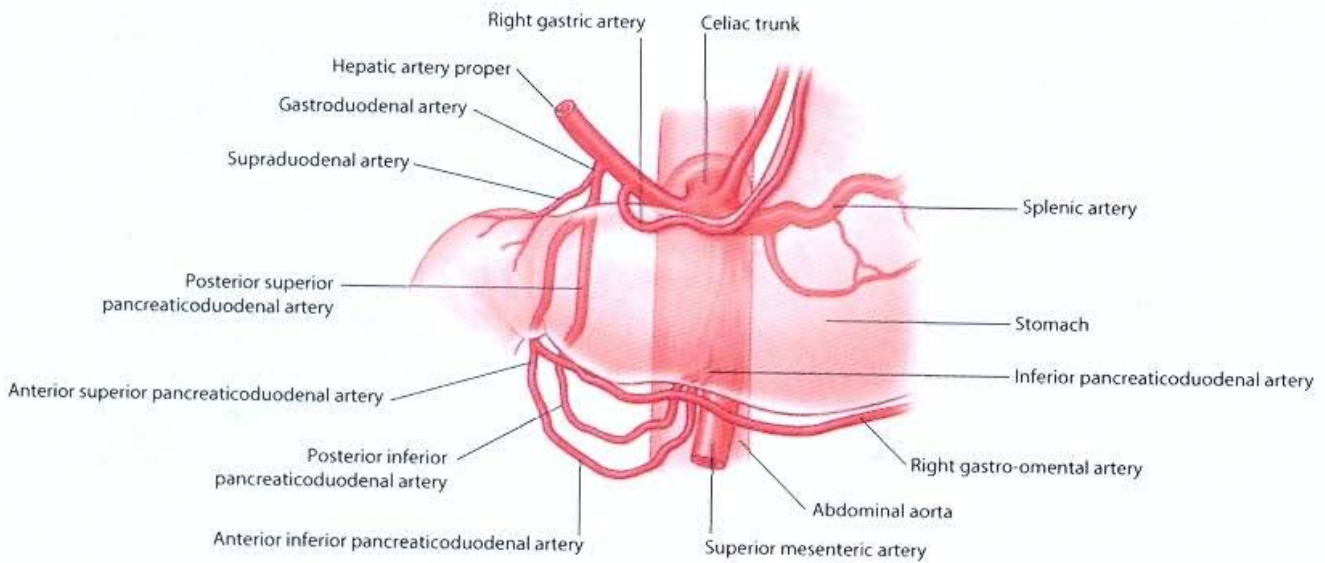
Location of the spleen. CT image, with contrast, in coronal plane



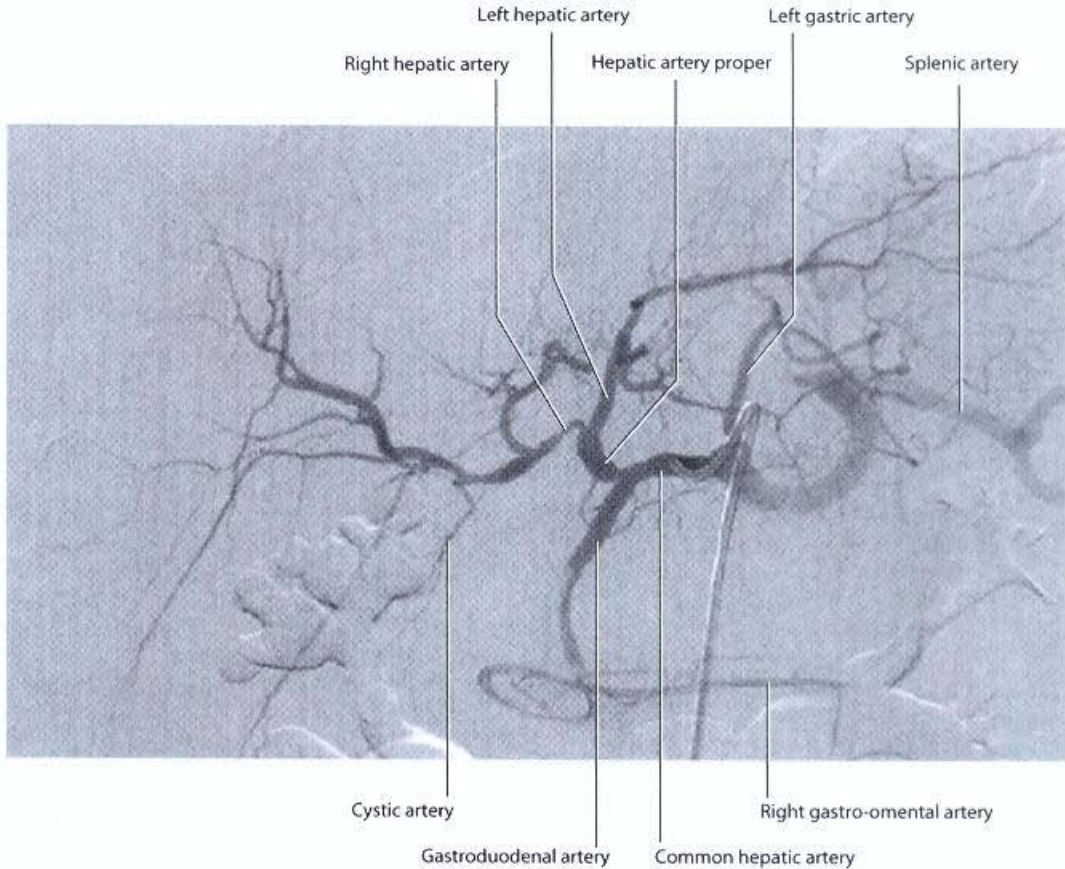
# ABDOMEN • Arteries of stomach and spleen



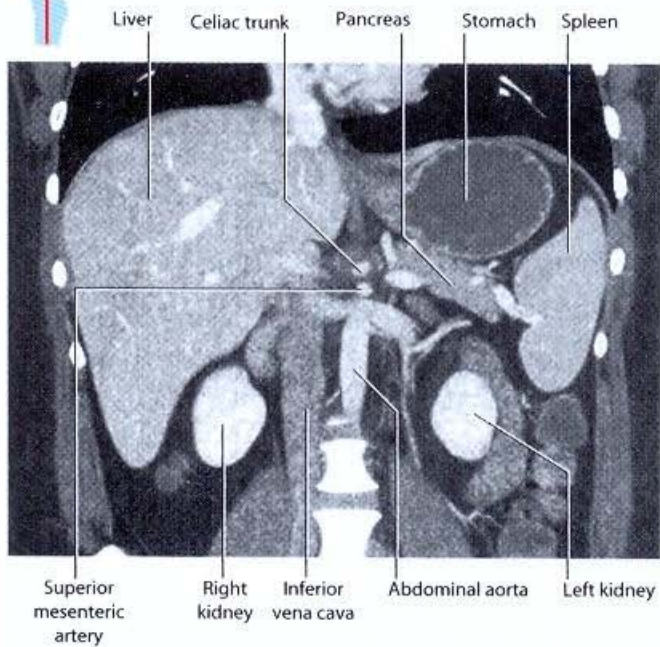
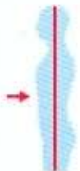
**Distribution of the celiac trunk**



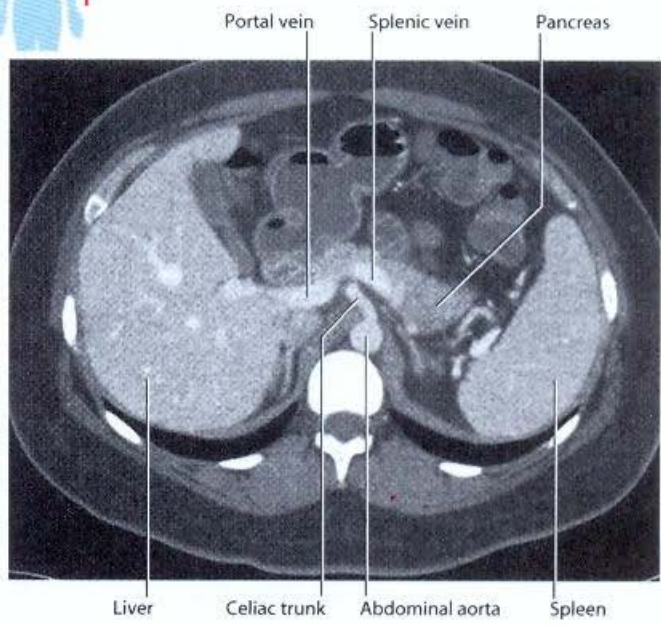
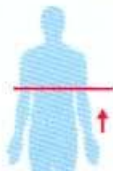
**Branches of the gastroduodenal artery**



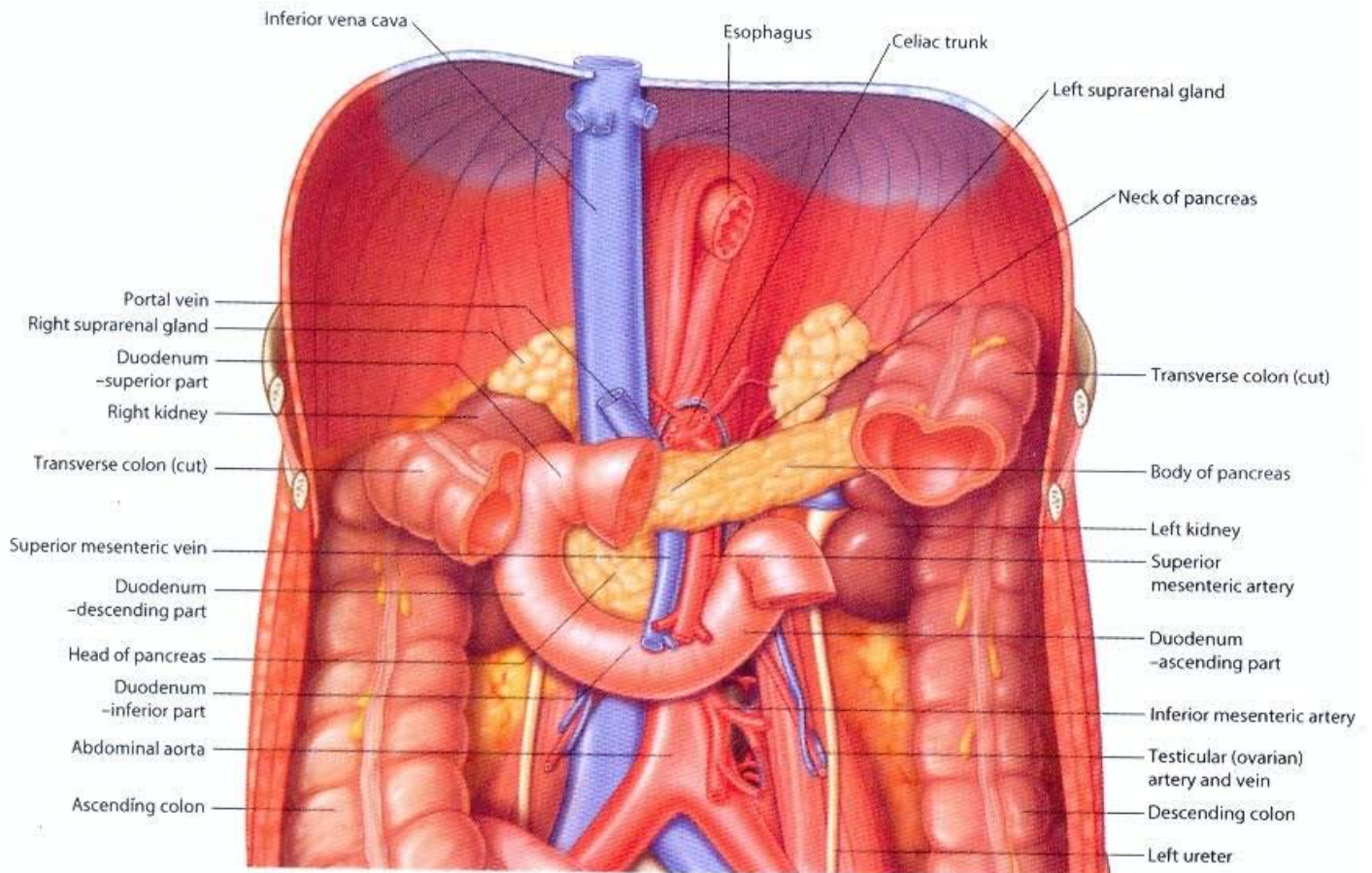
Digital subtraction angiography of the celiac trunk and its branches



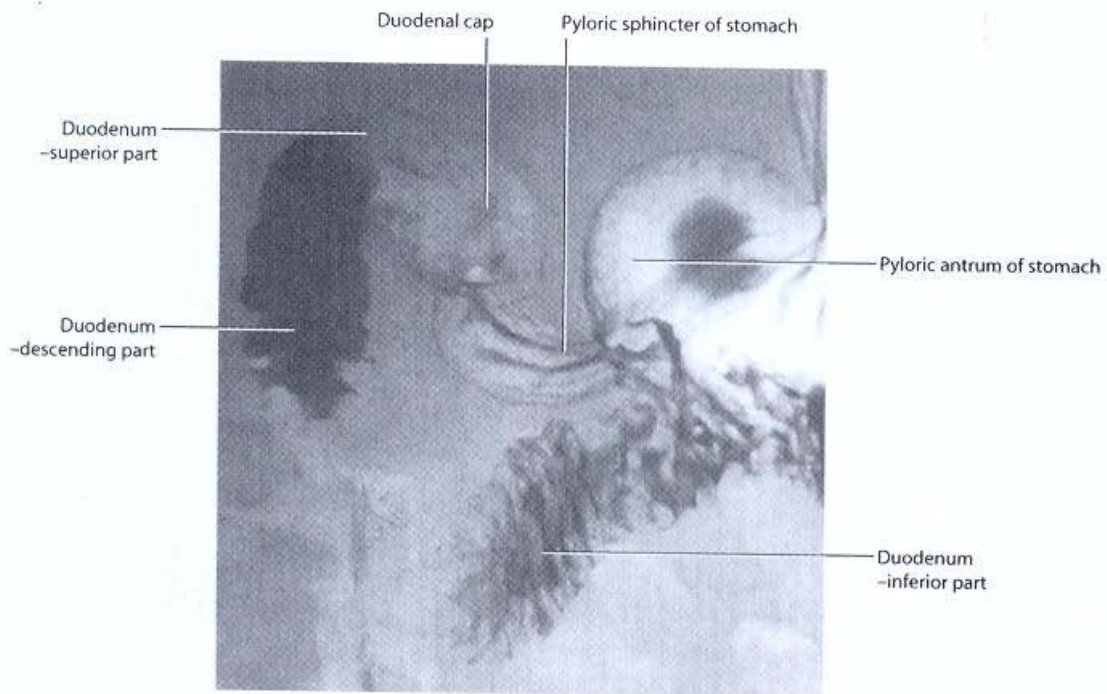
Positioning of the celiac trunk in relation to other structures. CT image, with contrast, in coronal plane



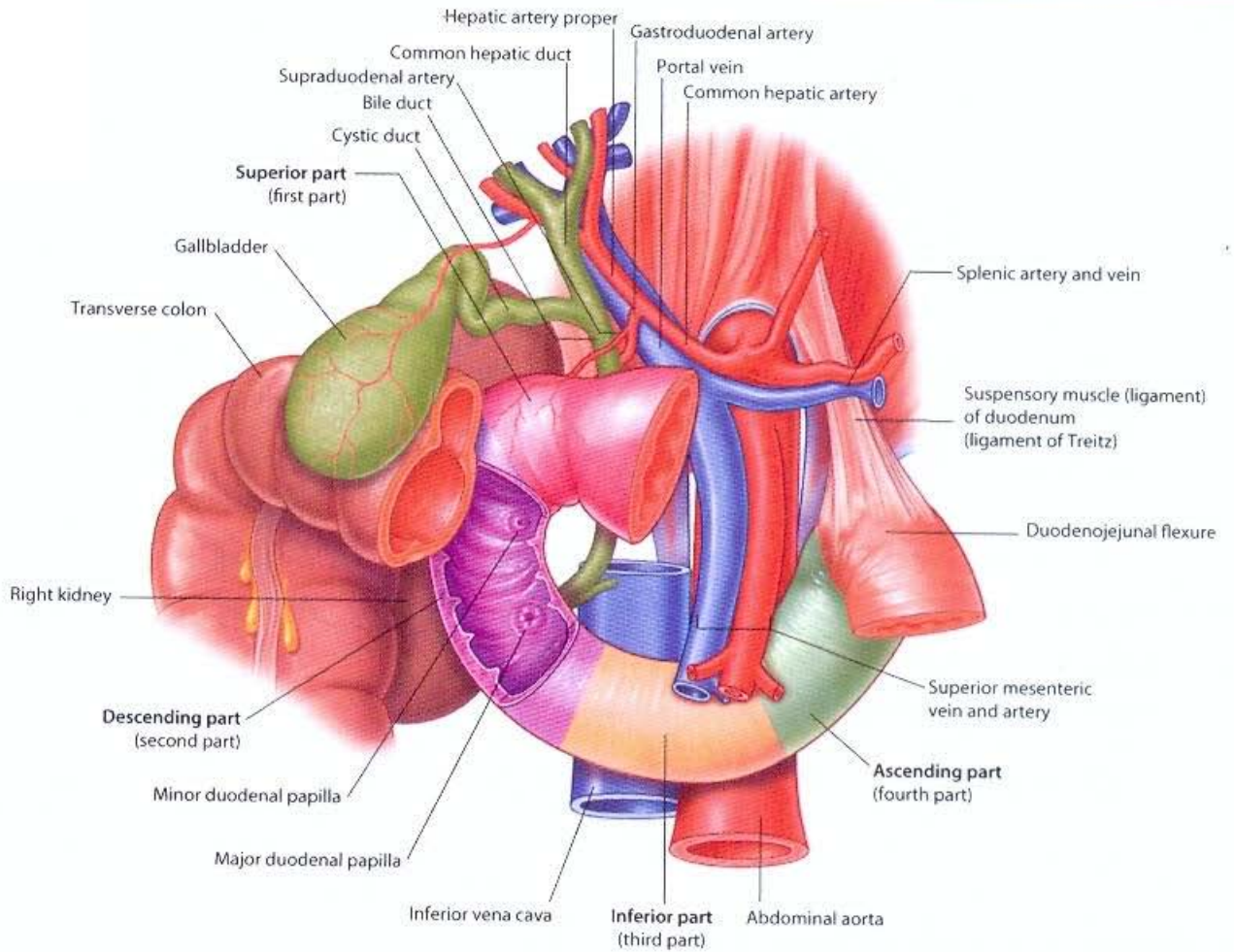
Branching of the celiac trunk from the abdominal aorta. CT image, with contrast, in axial plane



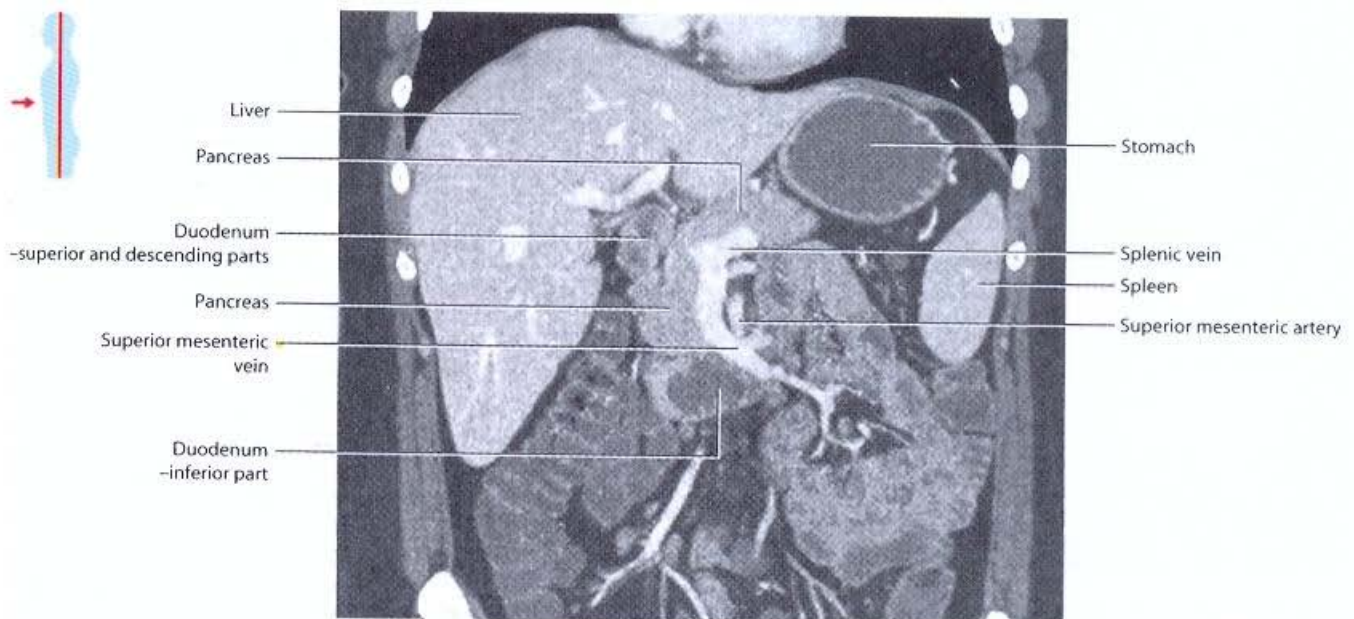
**Duodenum in situ**



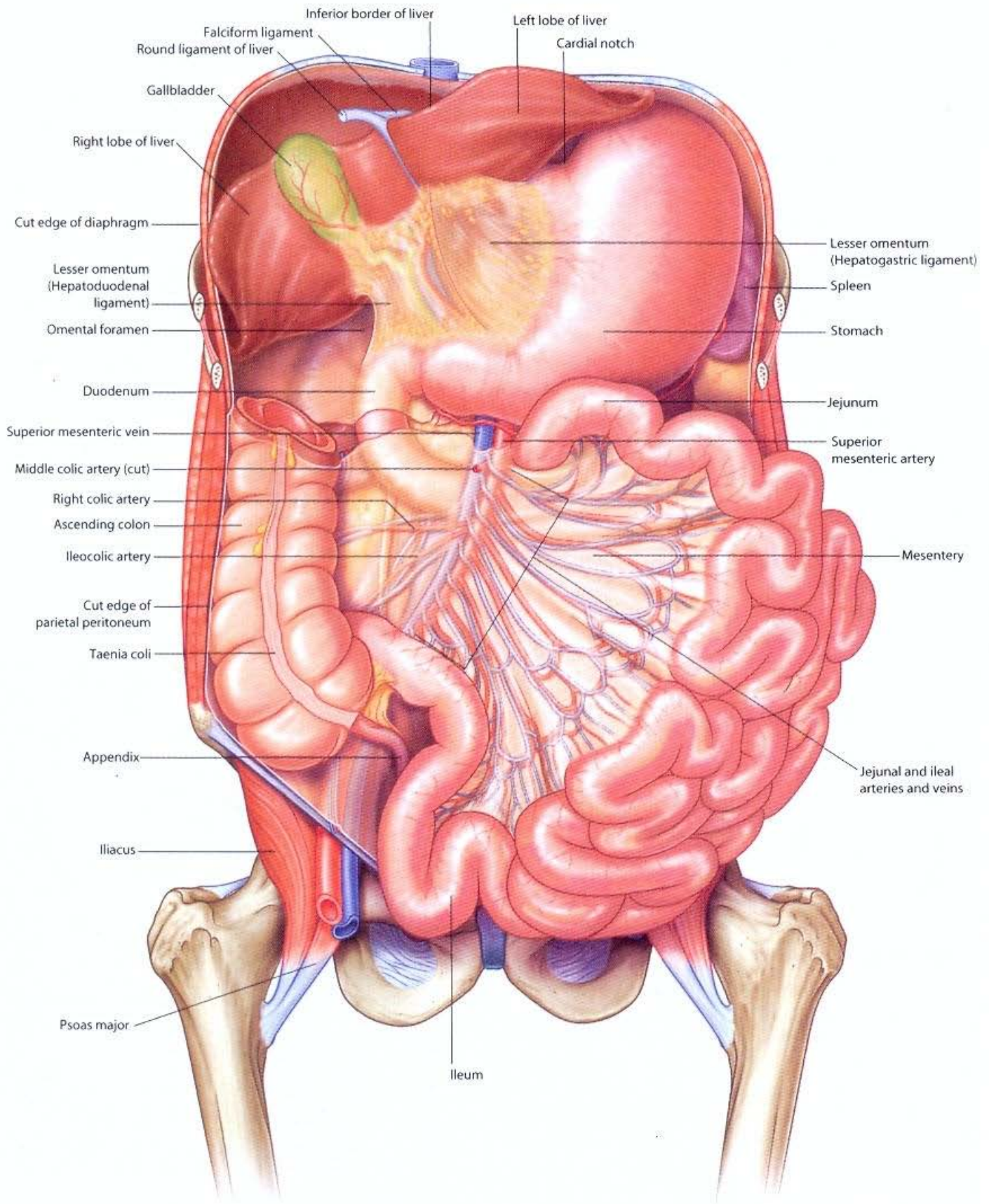
**Double contrast radiograph showing the duodenal cap**



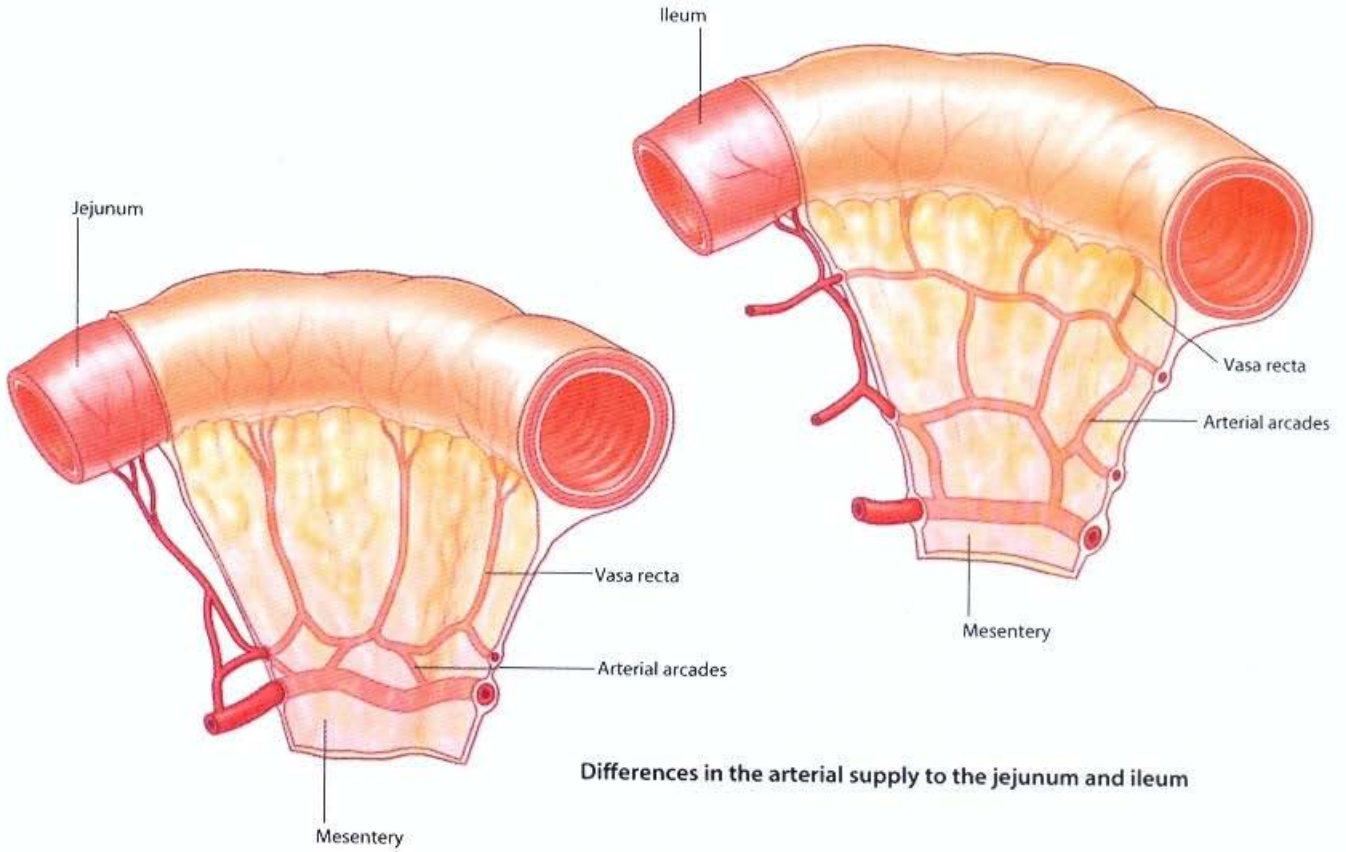
Parts of the duodenum and related structures



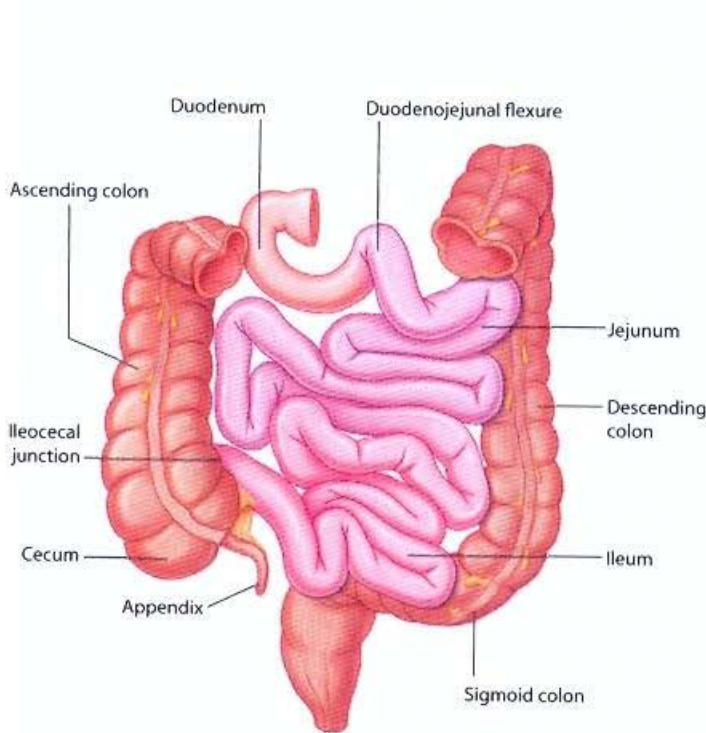
Relationship of duodenum to structures in the vicinity.  
CT image, with contrast, in coronal plane



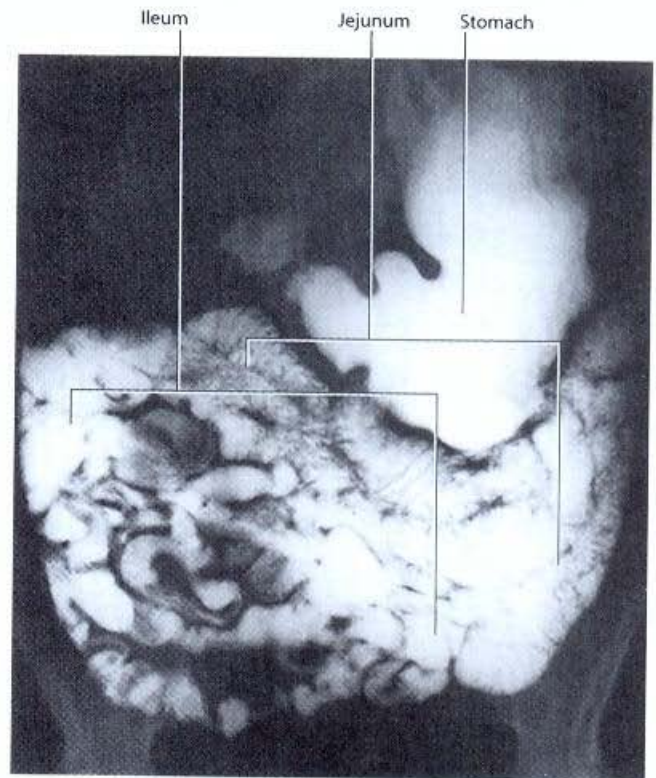
Small intestine displaced to show superior mesenteric vessels



Differences in the arterial supply to the jejunum and ileum

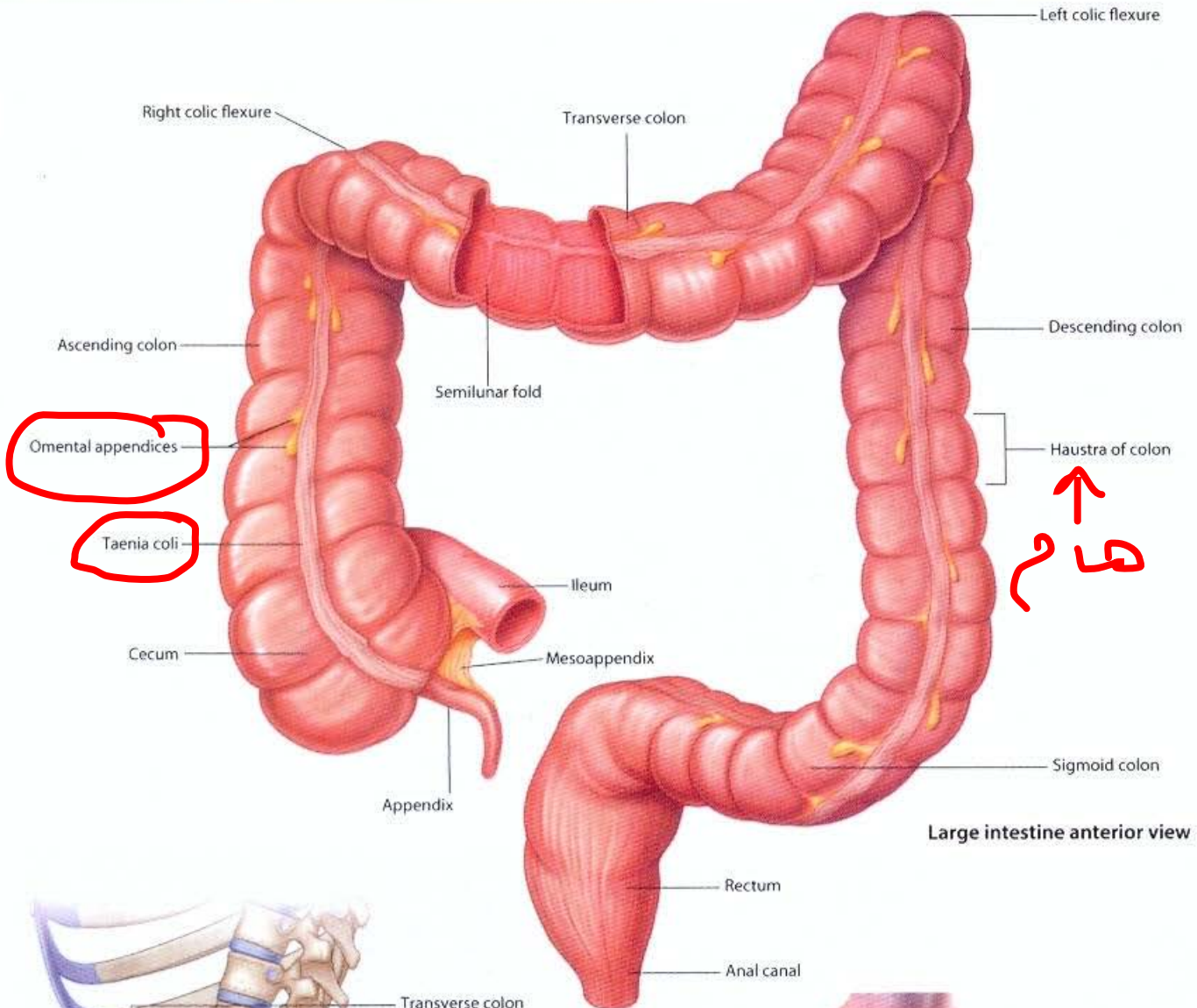


Jejunum and ileum

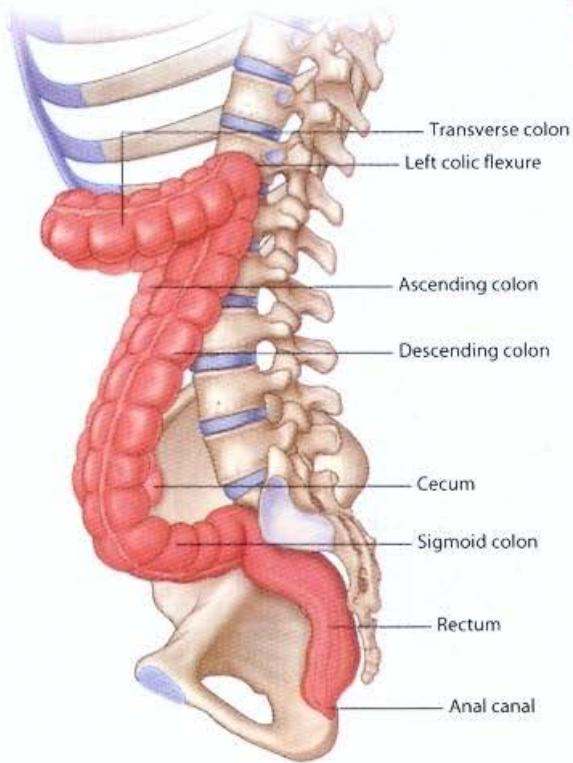


Radiograph using barium, showing jejunum and ileum

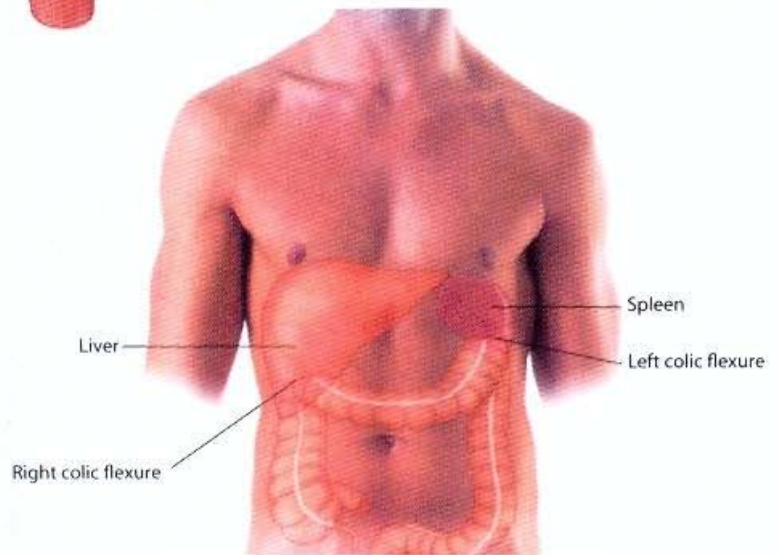




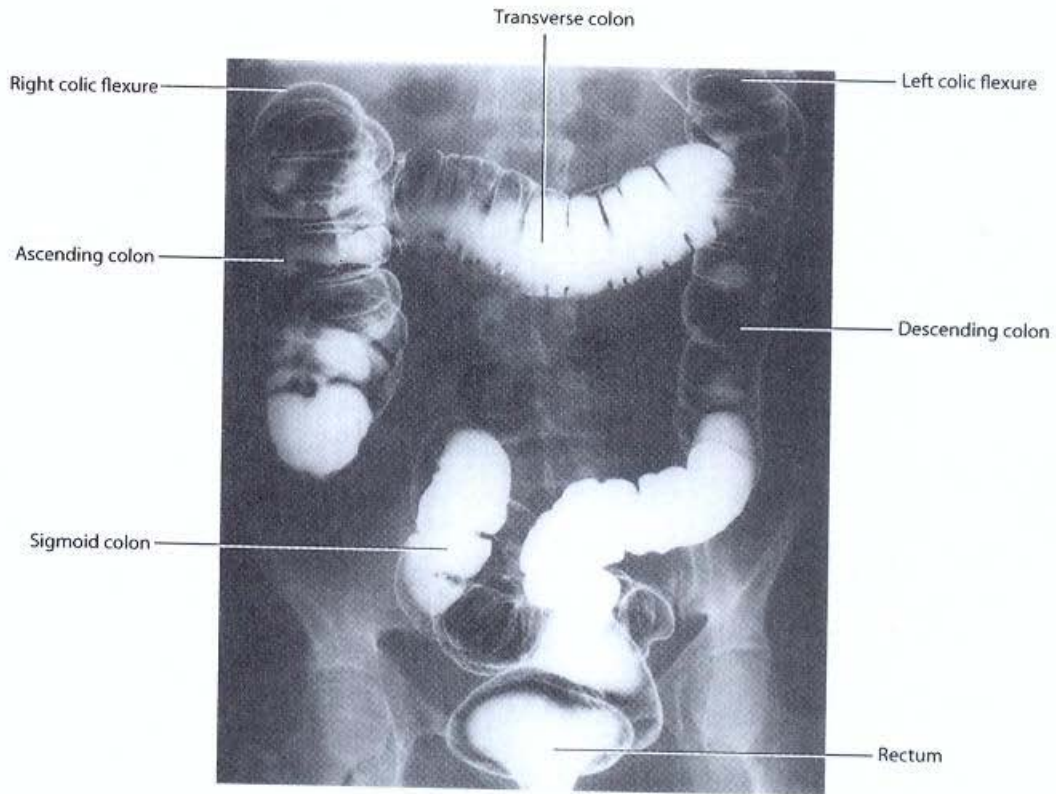
**Large intestine anterior view**



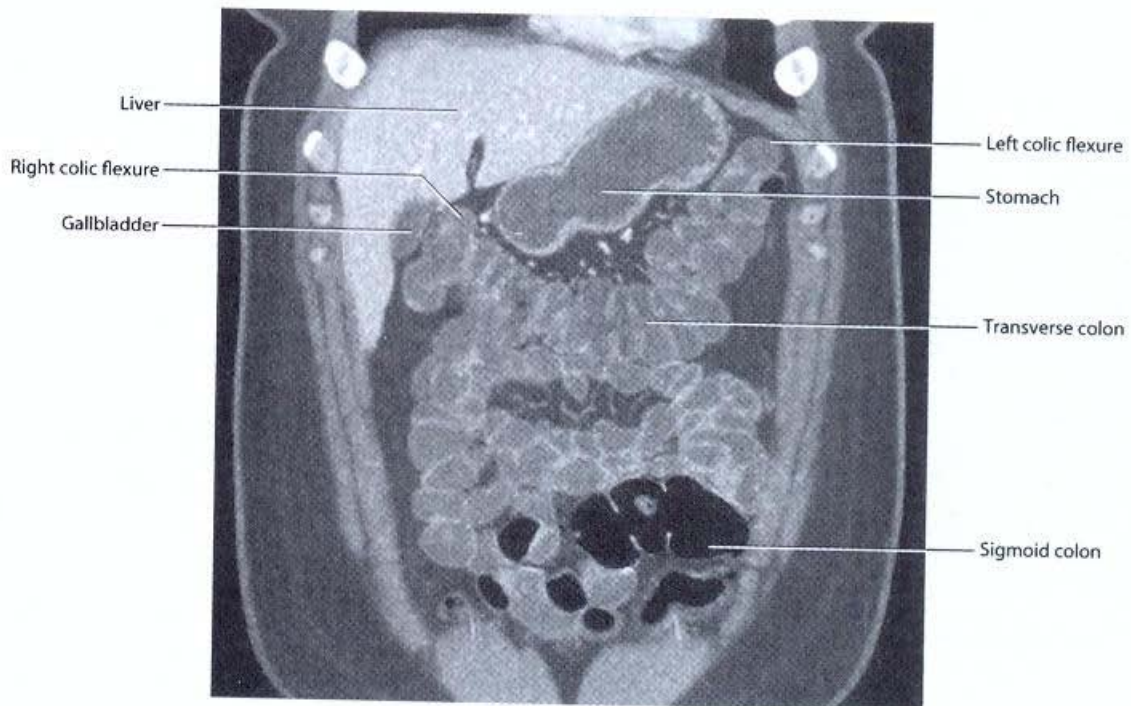
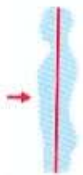
**Large intestine left lateral view**



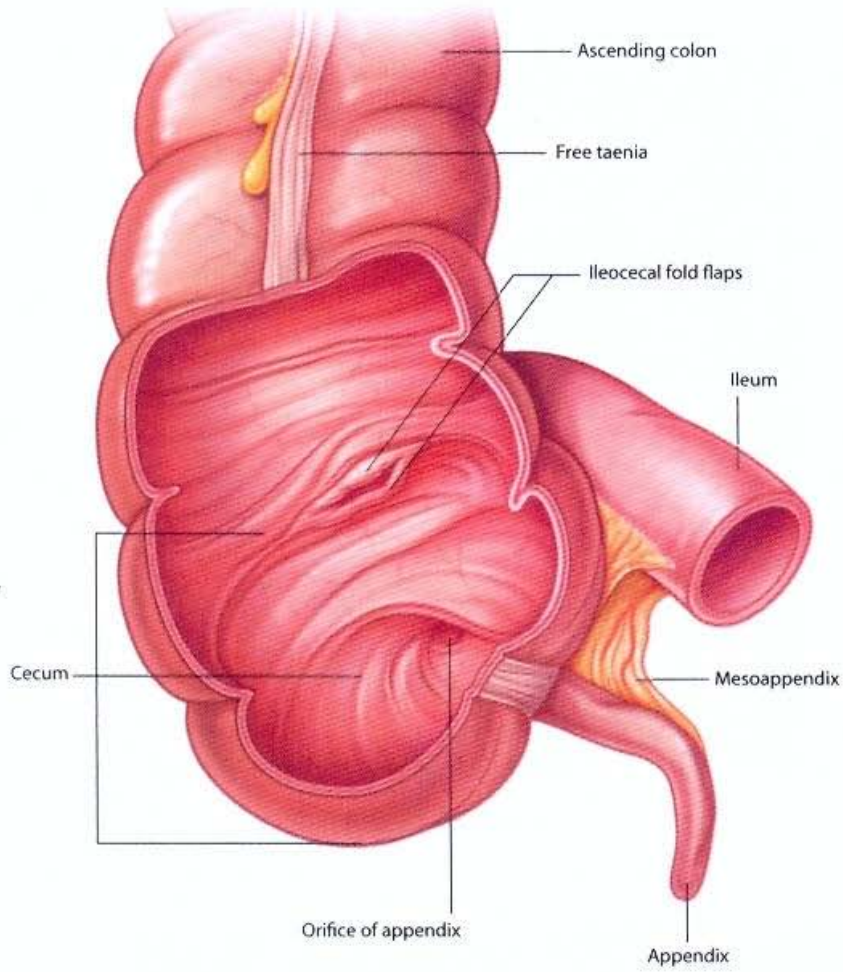
**Surface projection of the large intestine**



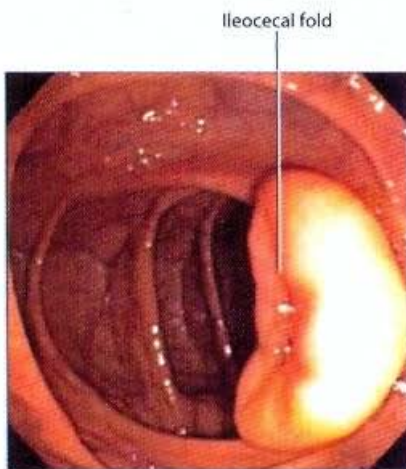
Radiograph using barium showing the large intestine



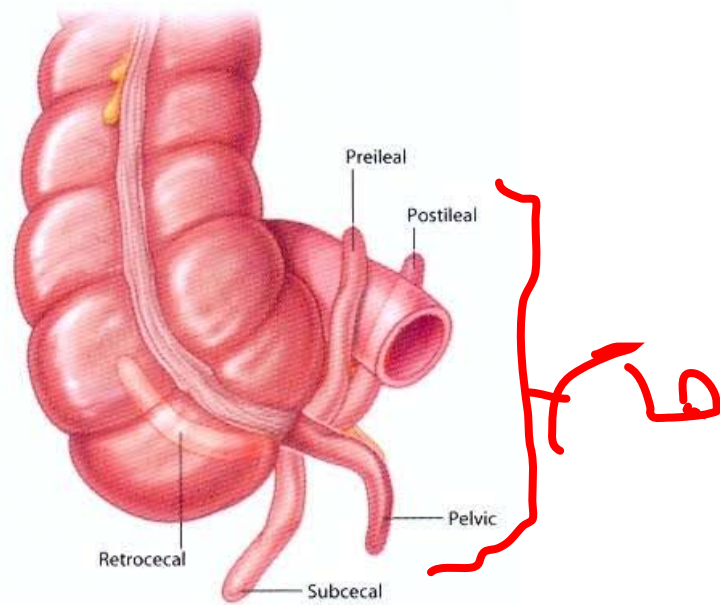
Transverse colon showing right and left colic flexures.  
CT image, with contrast, in coronal plane



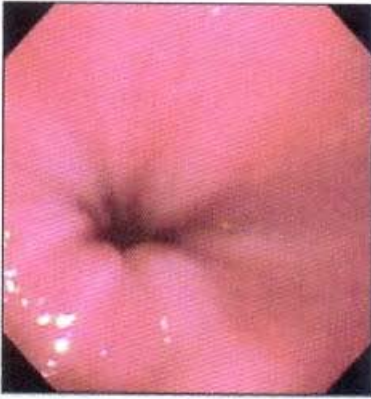
**Ileocecal junction**



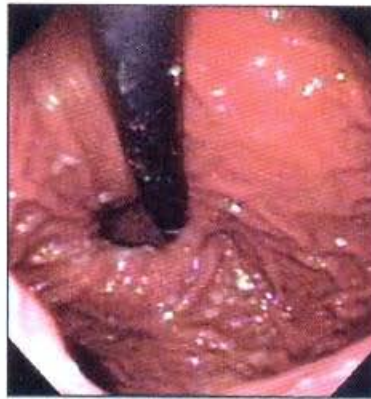**Colonoscopy showing ileocecal fold**



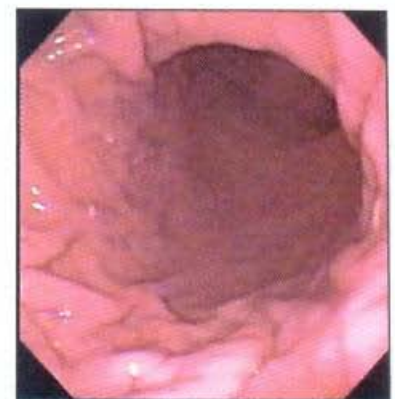**Positions of the appendix**



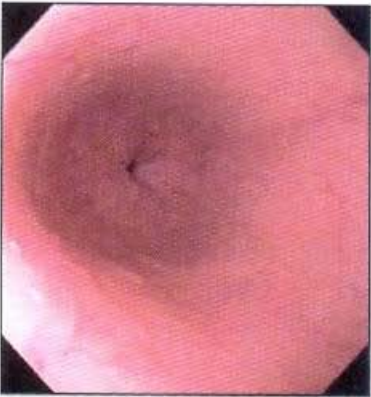
A



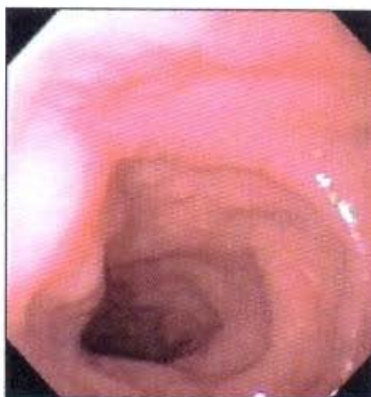B



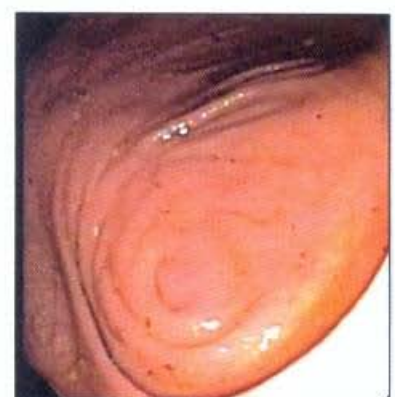
C



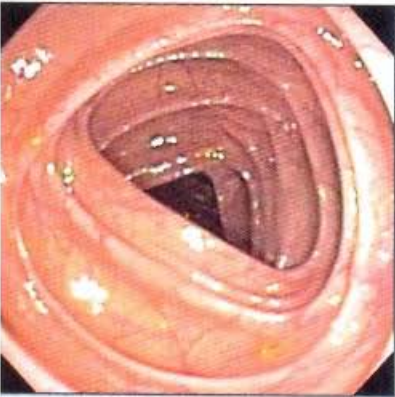D



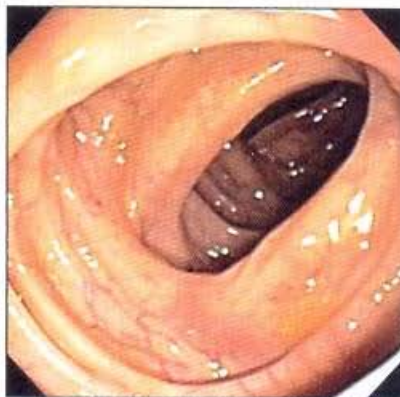
E



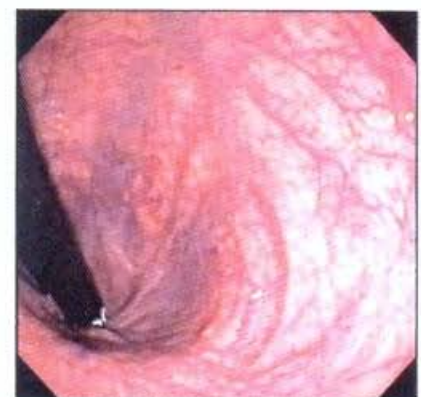F



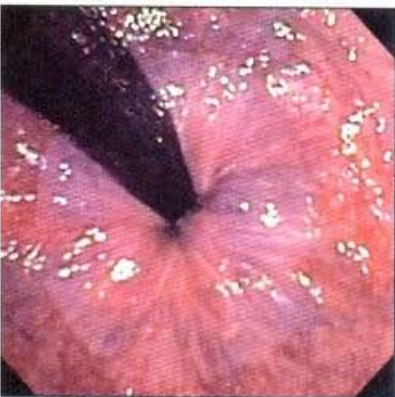G



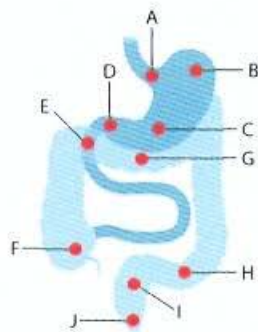
H



I

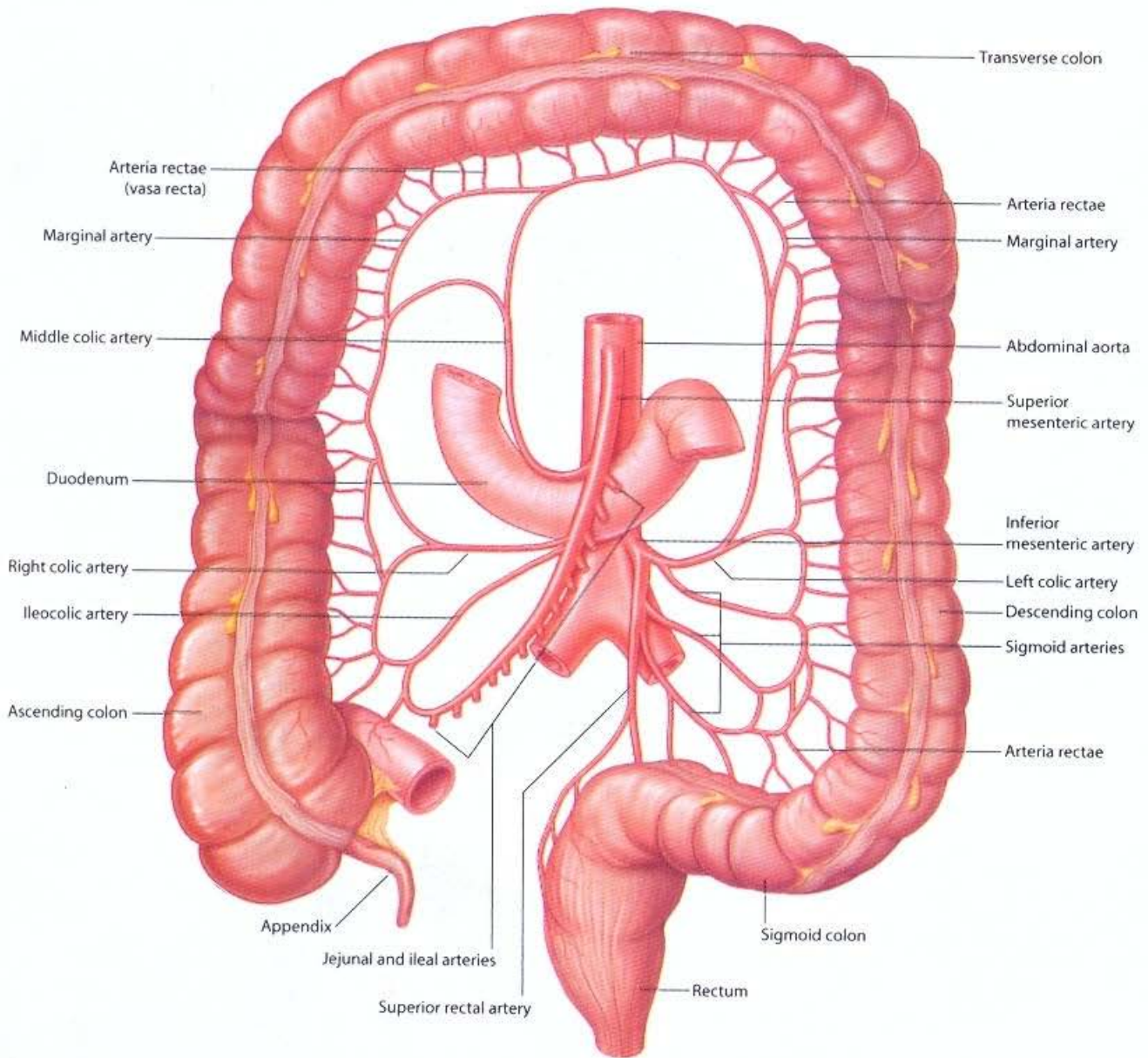


J

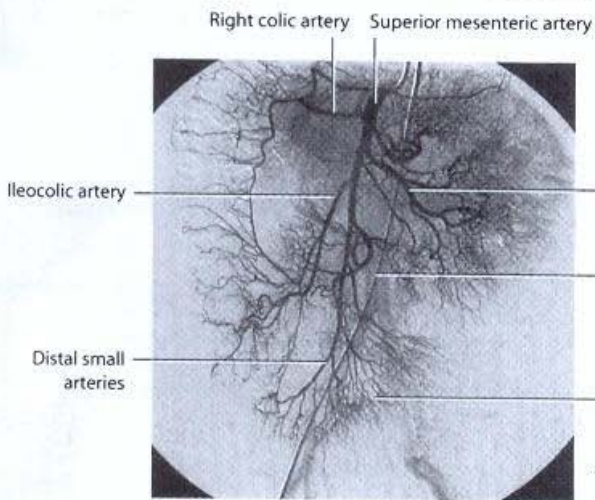


Endoscopy and colonoscopy showing different parts of the gastrointestinal tract.

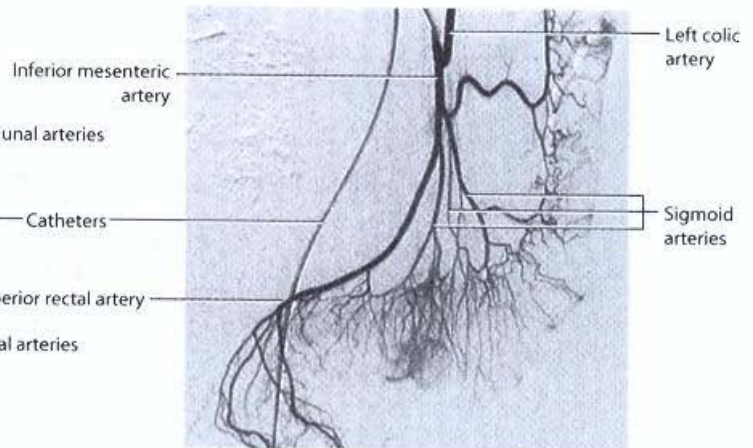
- A. Gastroesophageal junction
- B. Cardiac orifice and fundus of stomach-retroflexed view
- C. Body of stomach
- D. Pylorus of stomach and pyloric sphincter
- E. Duodenum
- F. Cecum showing appendiceal opening.
- G. Transverse colon
- H. Sigmoid colon
- I. Rectum-retroflexed view
- J. Pectinate line



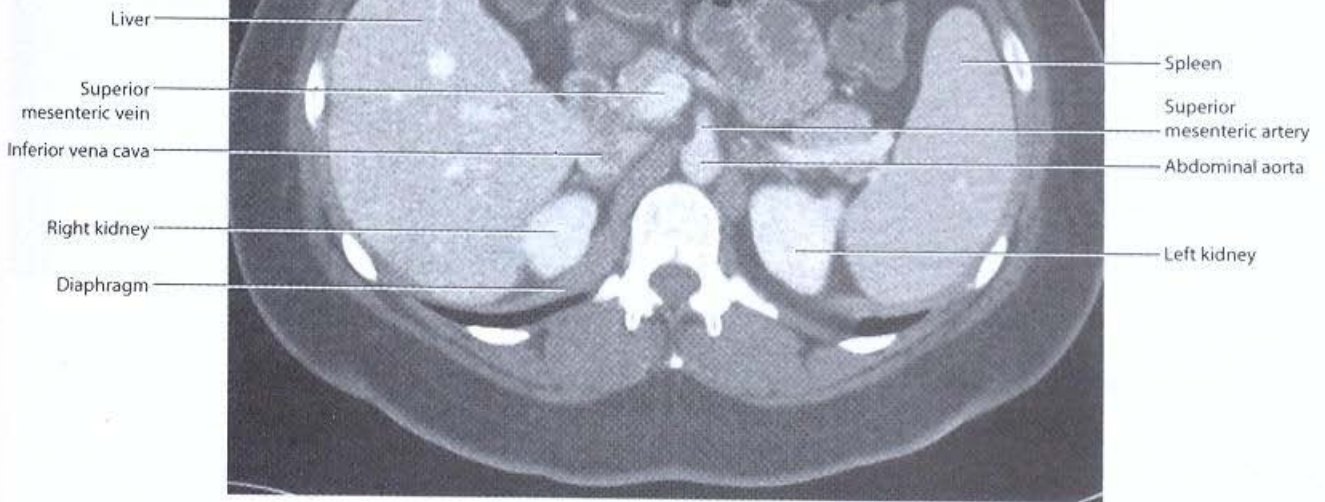
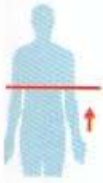
**Superior and inferior mesenteric arteries**



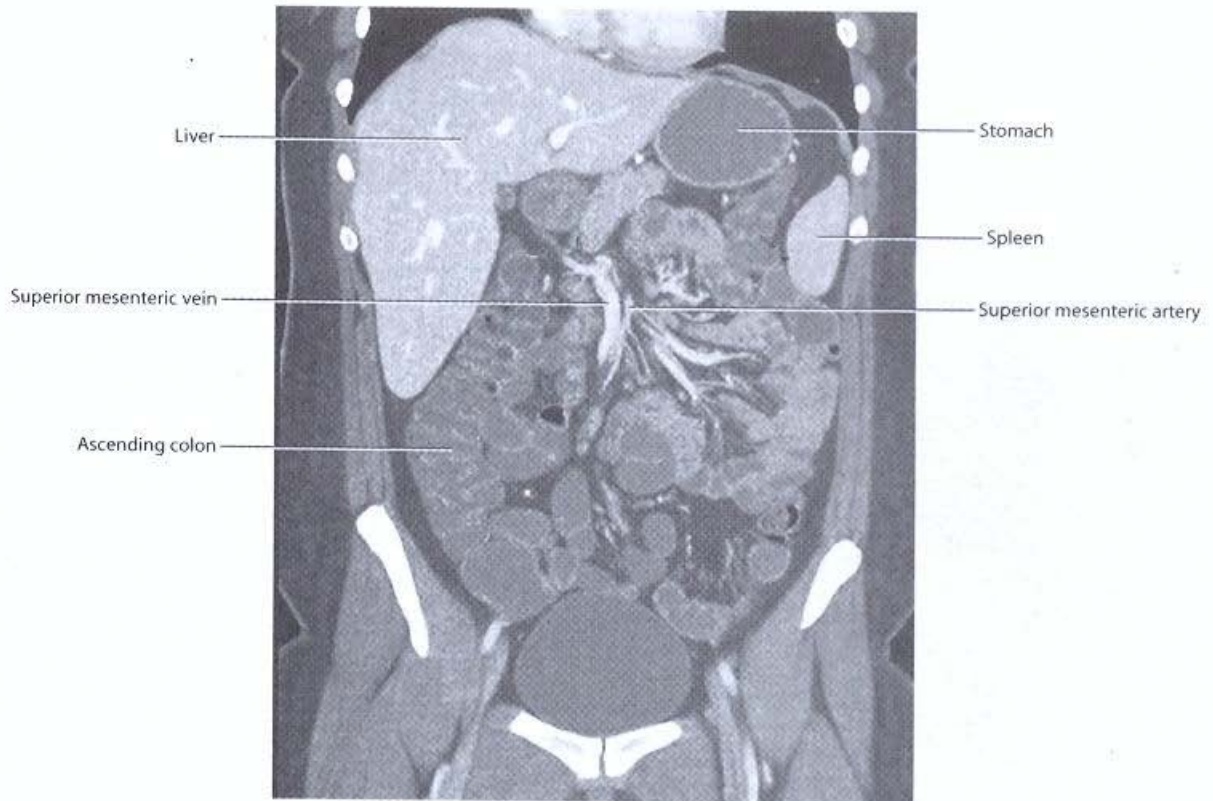
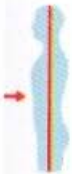
**Digital subtraction angiography of the superior mesenteric artery and its branches**



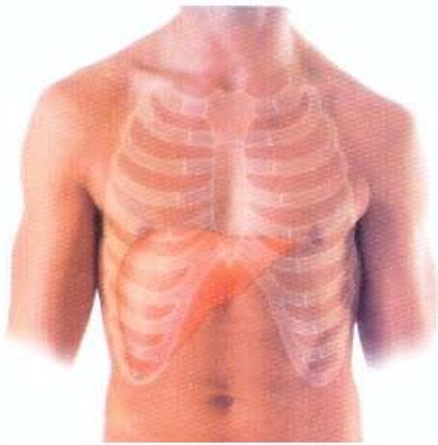
**Digital subtraction angiography of the inferior mesenteric artery and its branches**



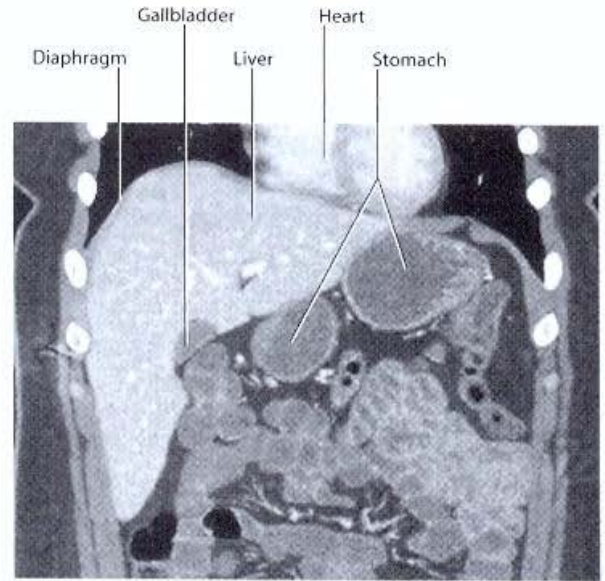
Branching of the superior mesenteric artery from the abdominal aorta.  
CT image, with contrast, in axial plane



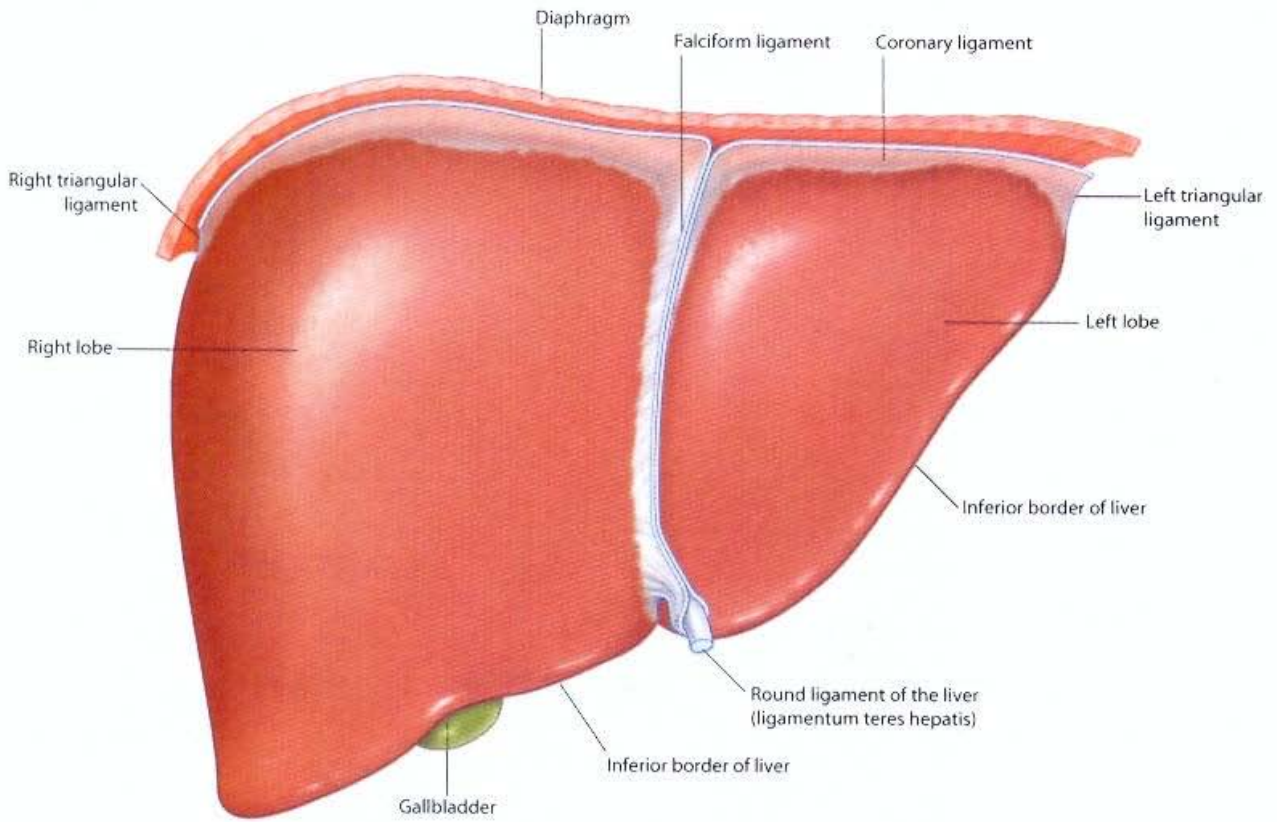
Positioning of the superior mesenteric artery in relation to other structures.  
CT image, with contrast, in coronal plane



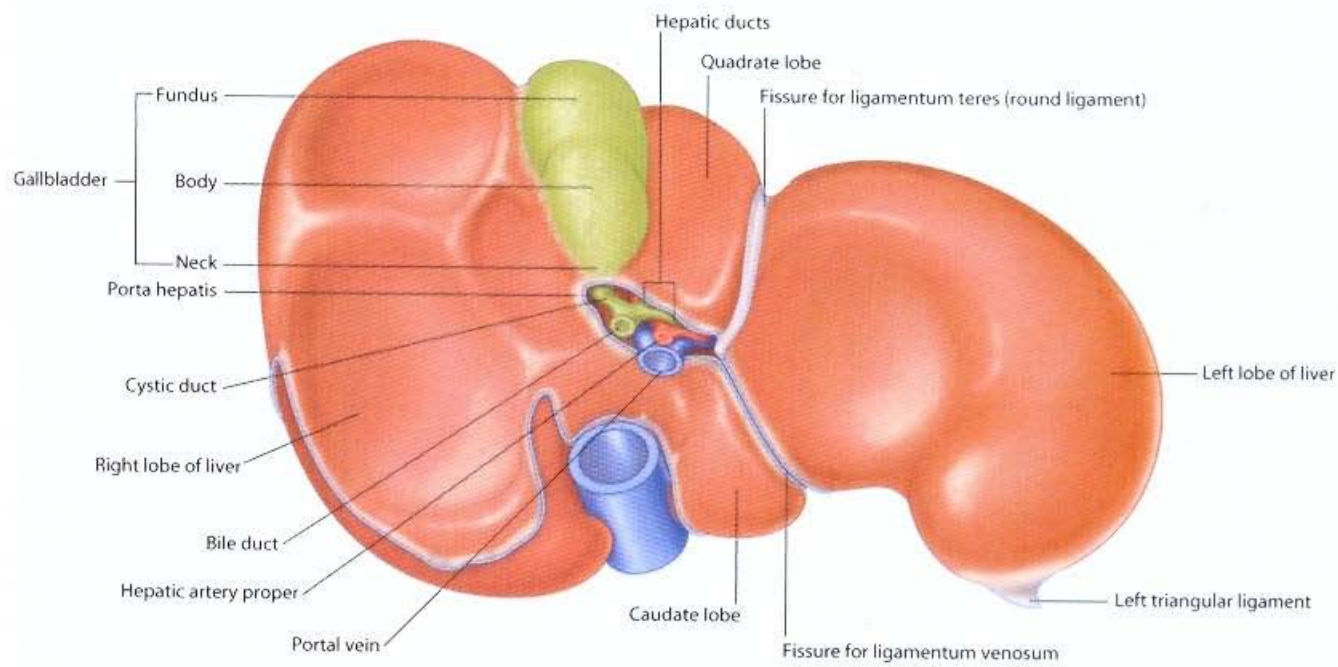
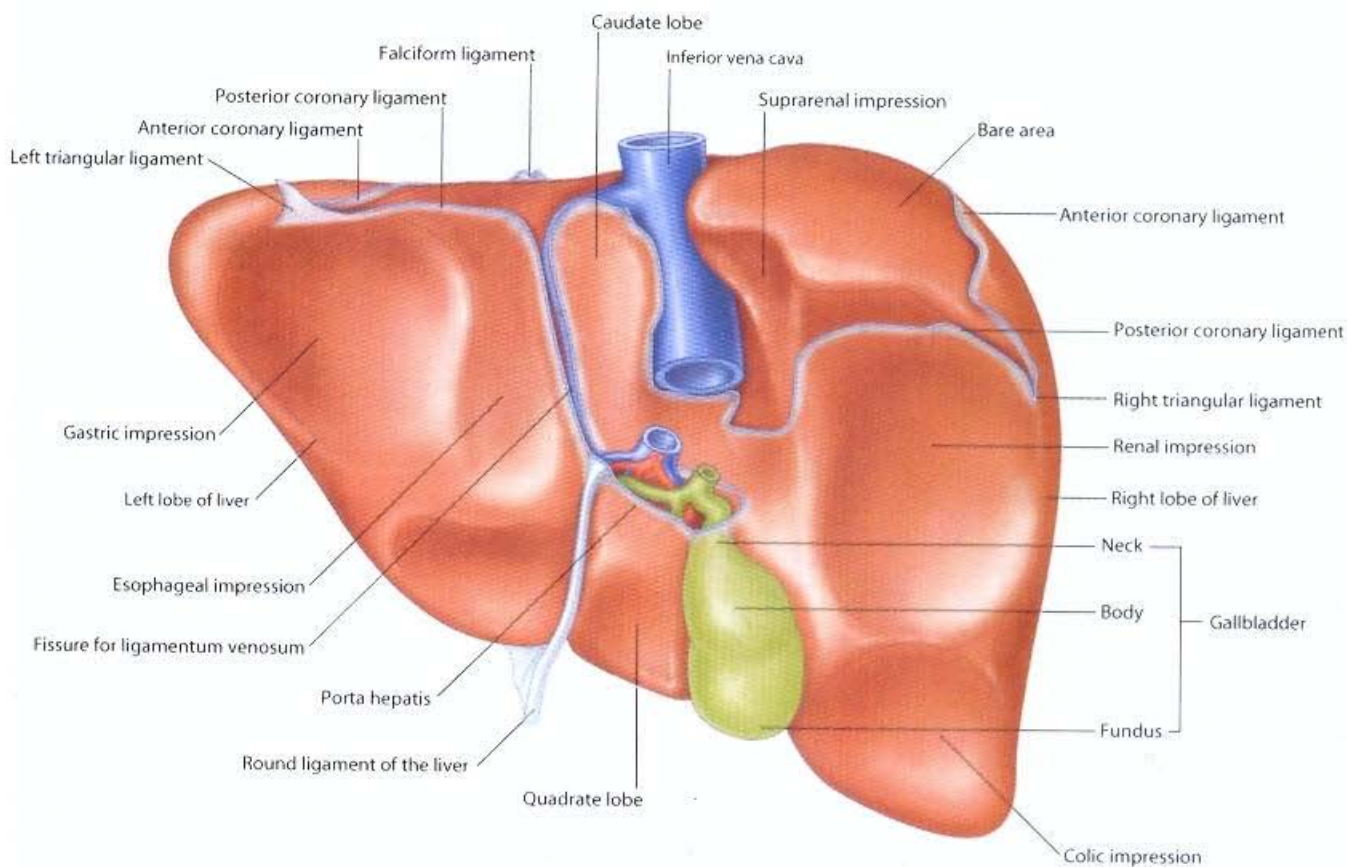
Surface projection of the liver anterior view



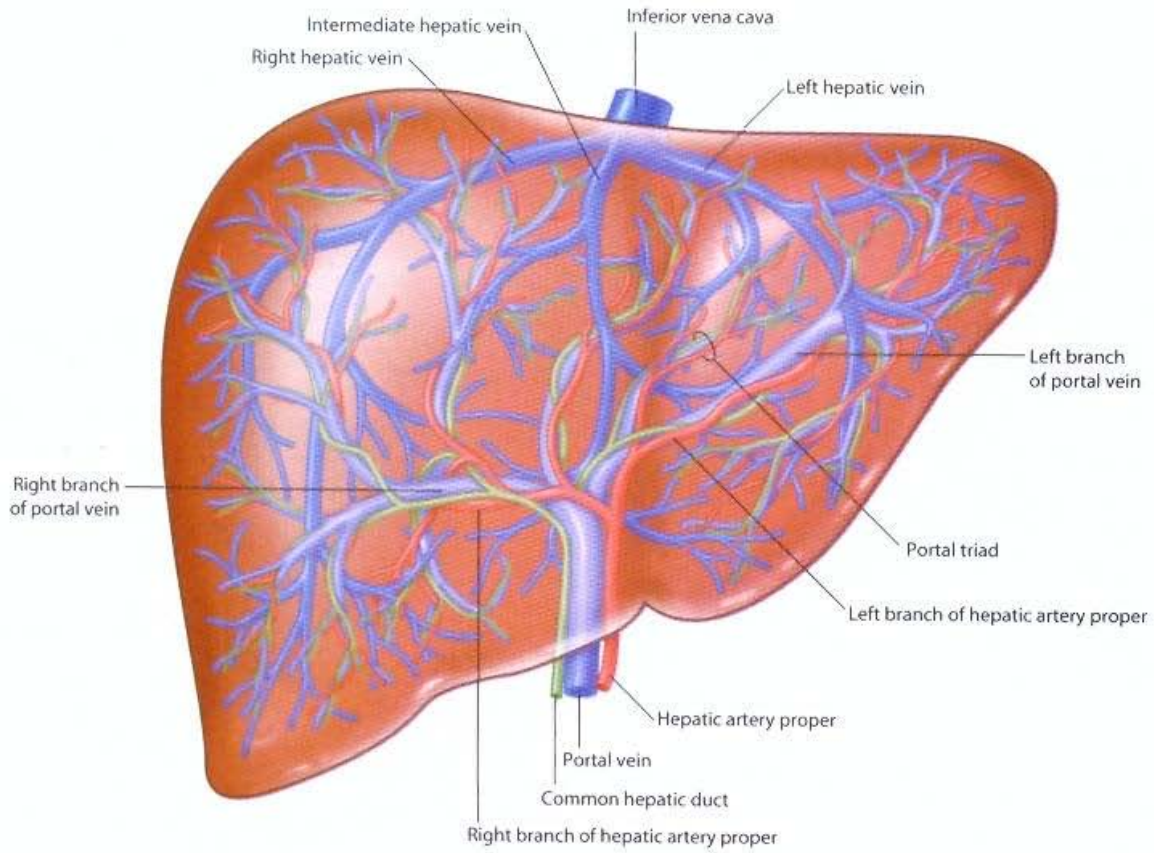
Location of the liver.  
CT image, with contrast, in coronal plane



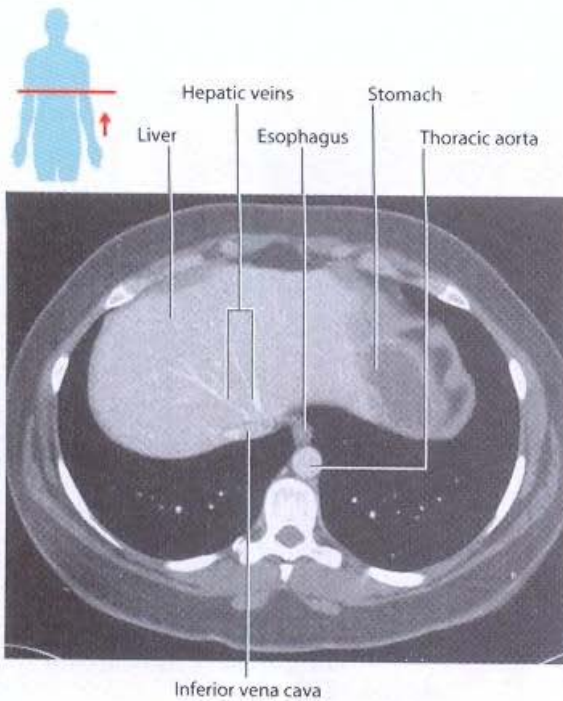
Anterior surface of liver



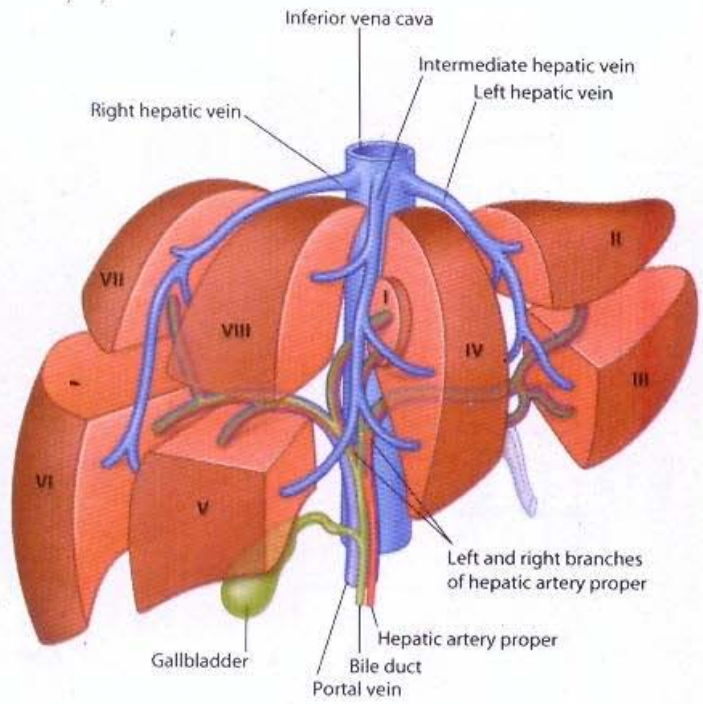




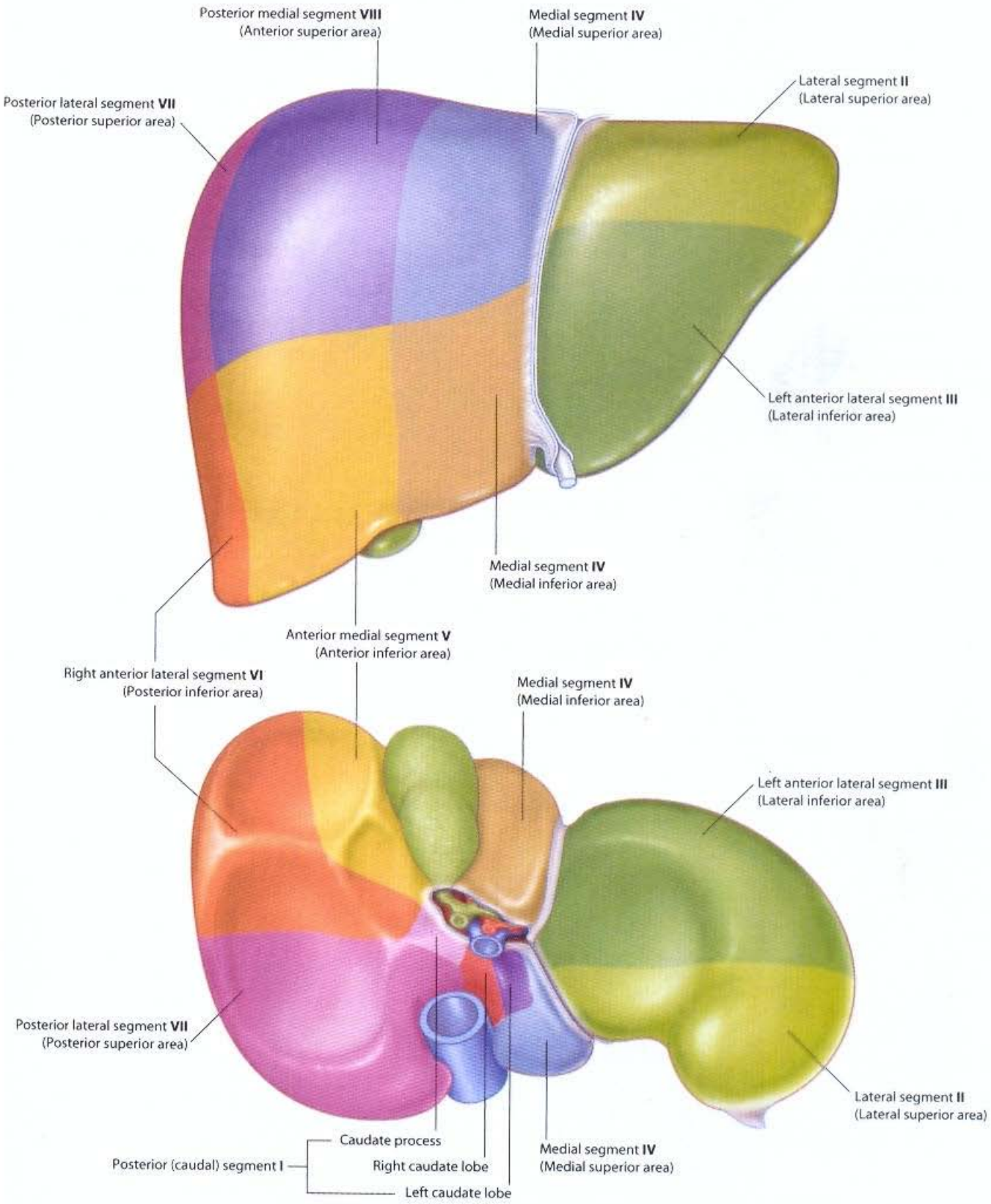
Anterior surface of liver with hepatic veins, portal vein, and associated vessels



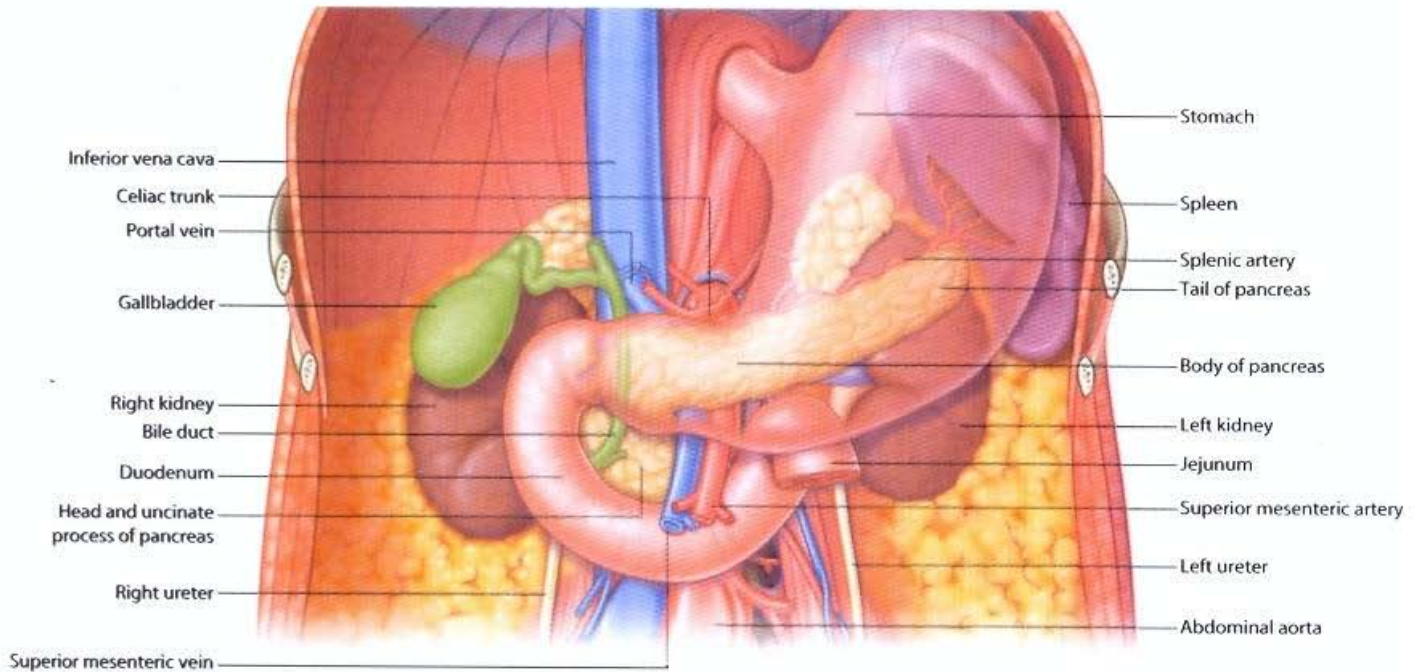
Hepatic veins entering the inferior vena cava in the substance of the liver. CT image, with contrast, in axial plane



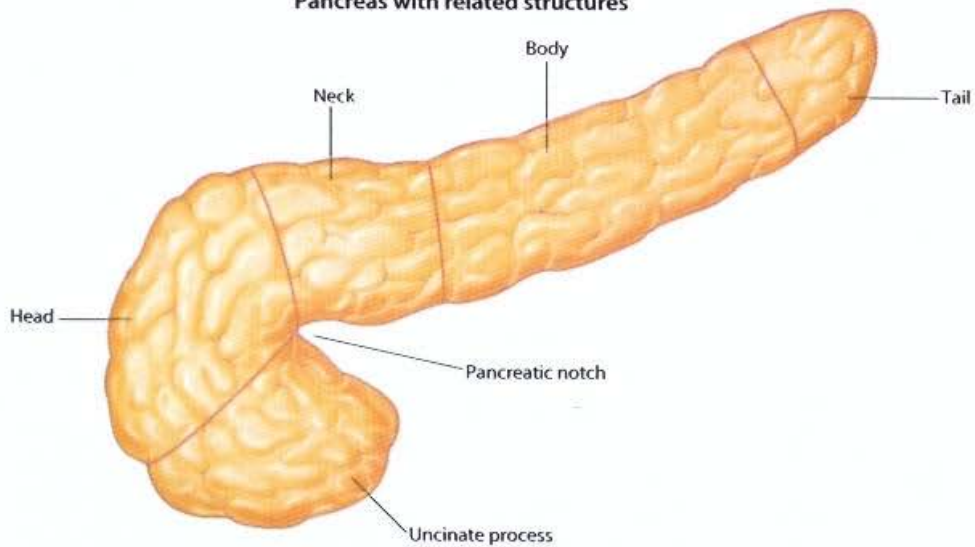
Arrangement of the hepatic venous segments



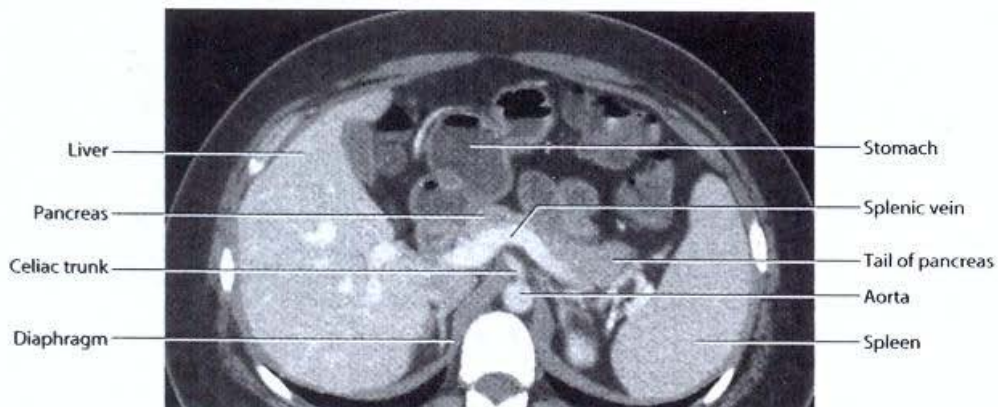
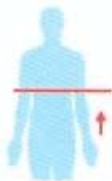
Segments of the liver shown on anterior and visceral surfaces



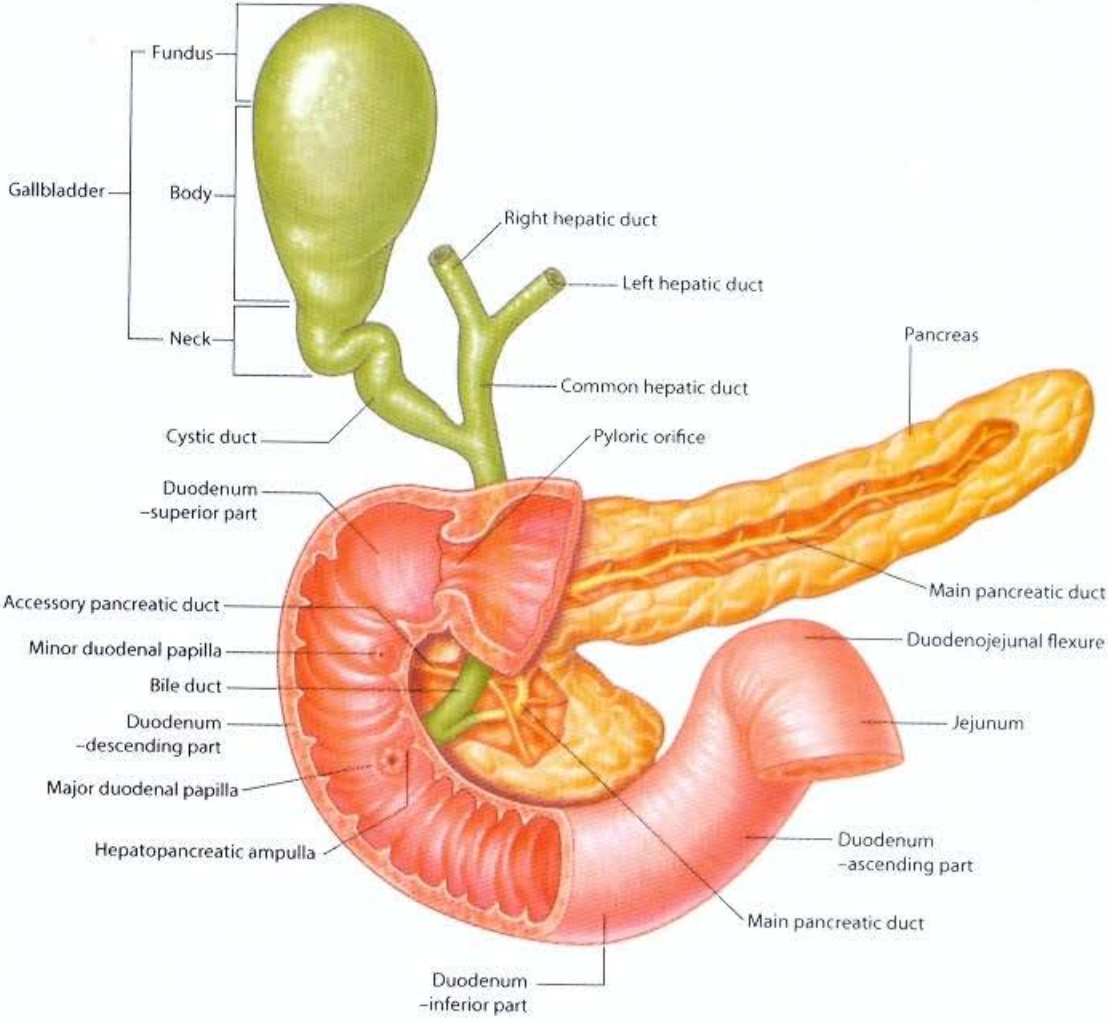
**Pancreas with related structures**



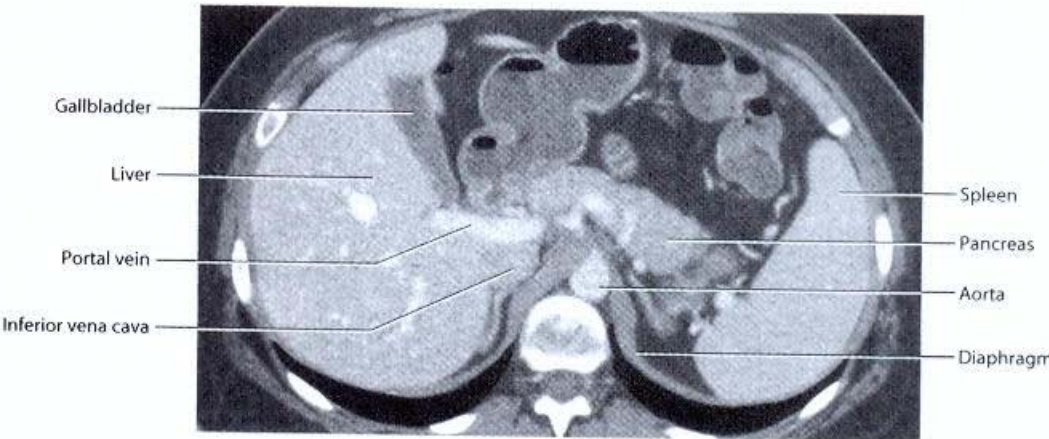
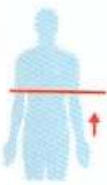**Anterior surface of the pancreas**



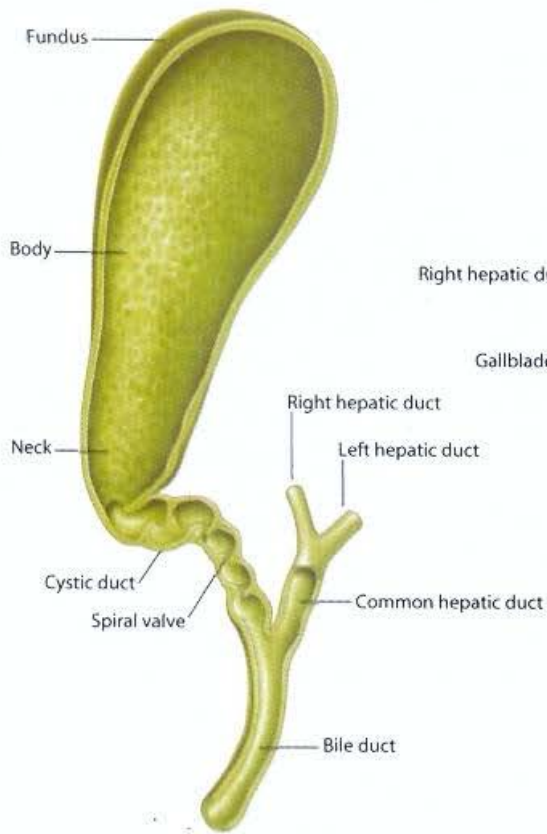
**Pancreas.**  
 CT image, with contrast, in axial plane



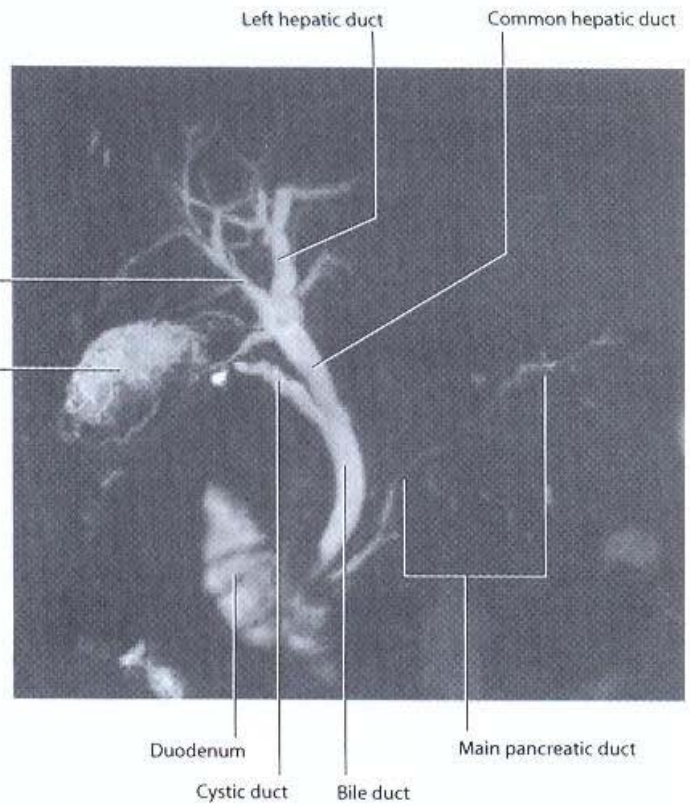
Bile and pancreatic ducts



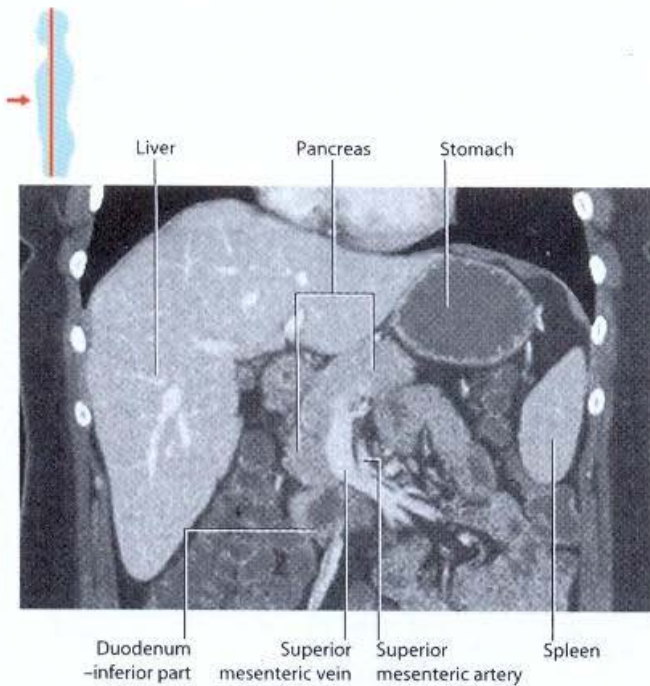
Positioning of the gallbladder in relation to other structures. CT image, with contrast, in axial plane



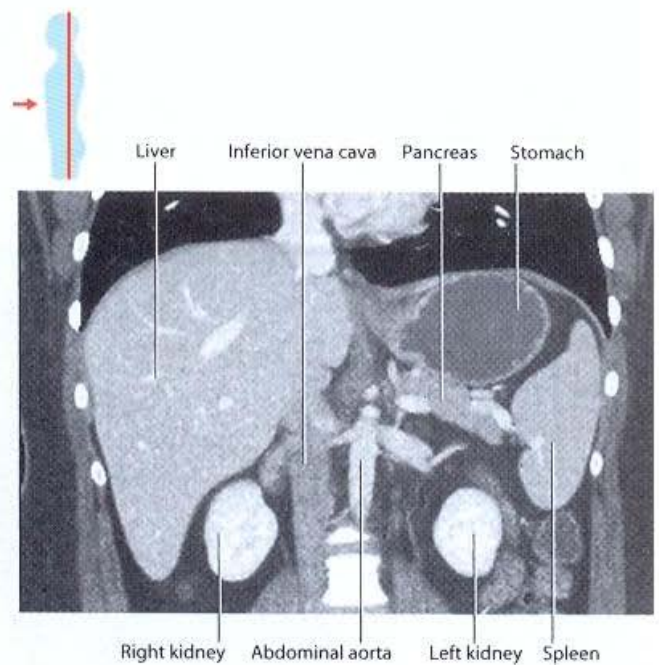
**Section through gallbladder and bile ducts**



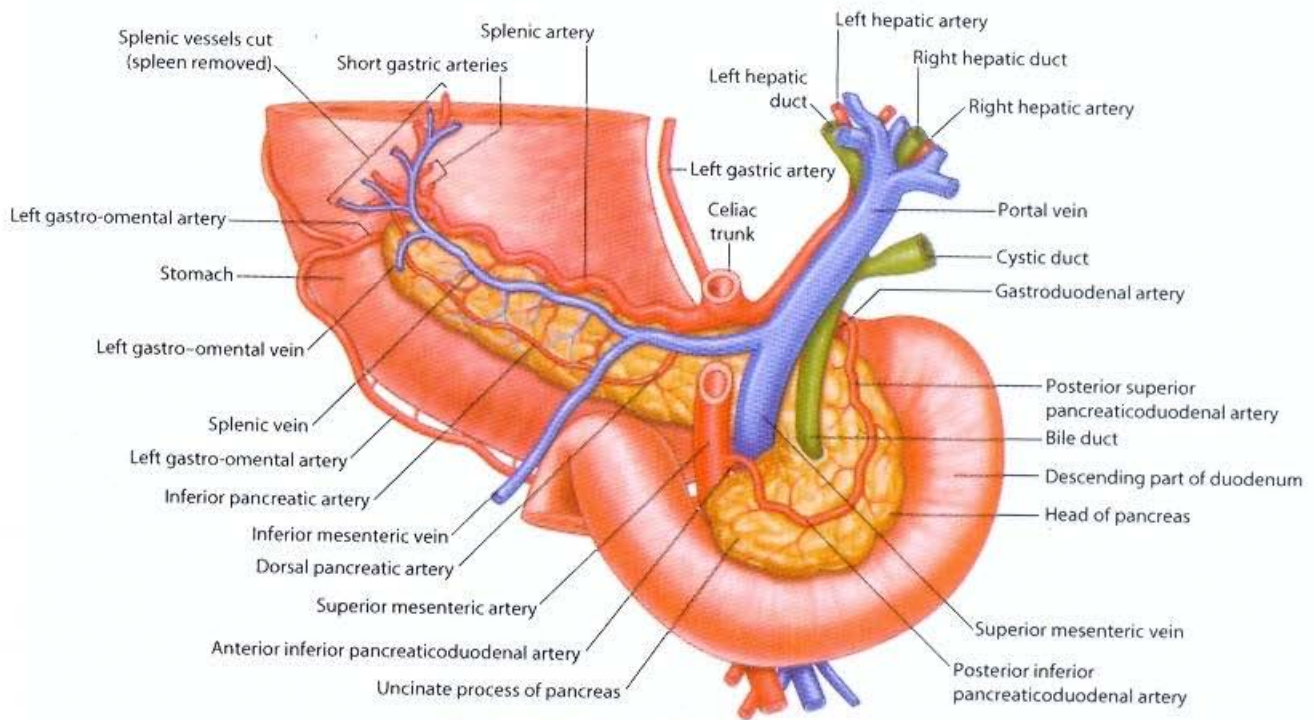
**Bile duct system.**  
Percutaneous transhepatic cholangiogram



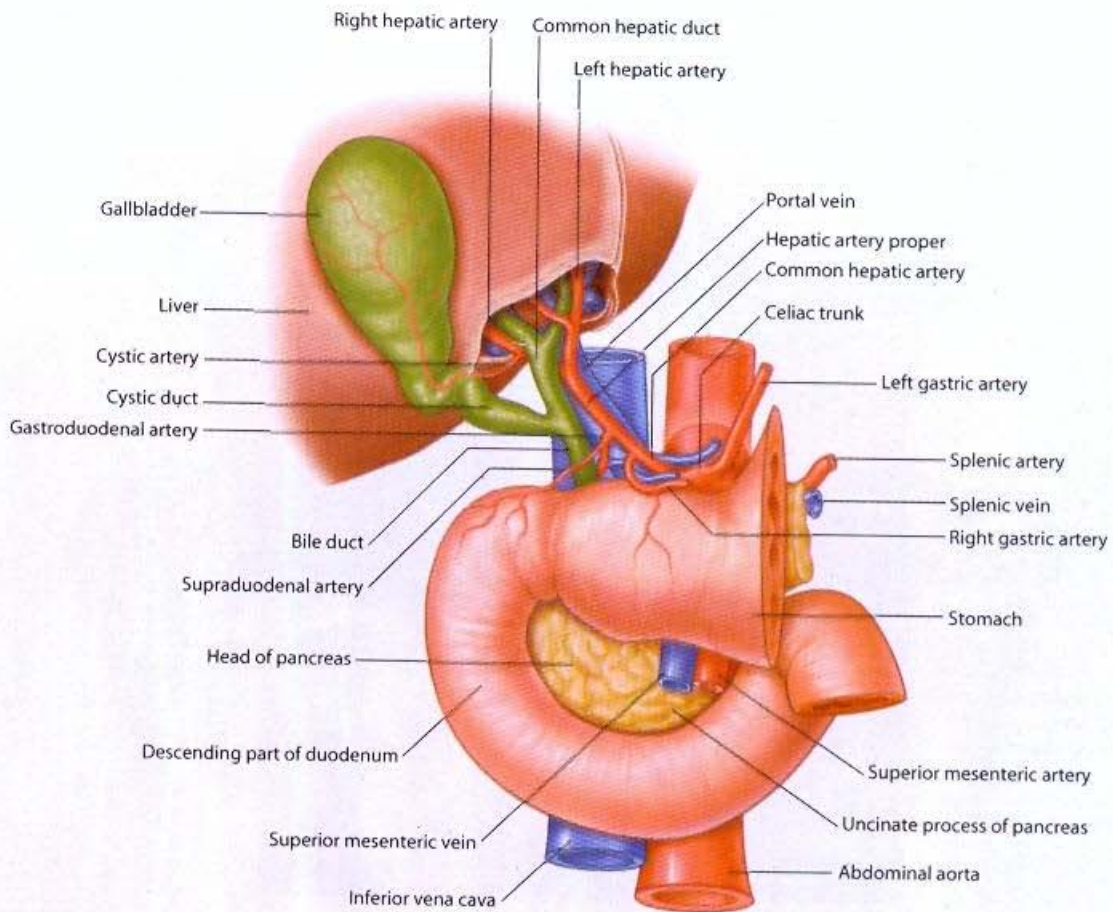
**Positioning of the pancreas in relation to other structures.**  
CT image, with contrast, in coronal plane



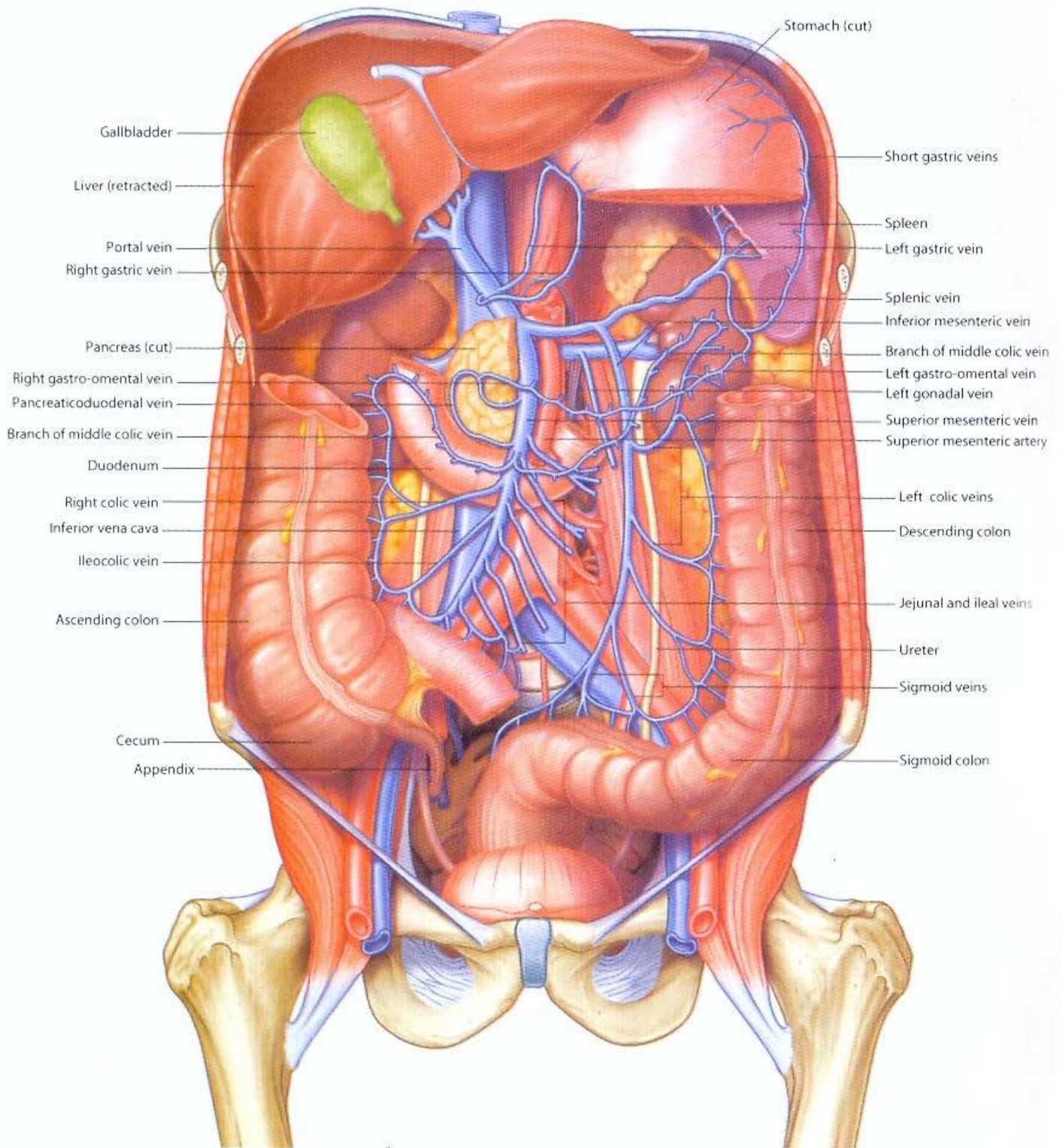
**Relationship of pancreas to the stomach and spleen.**  
CT image, with contrast, in coronal plane



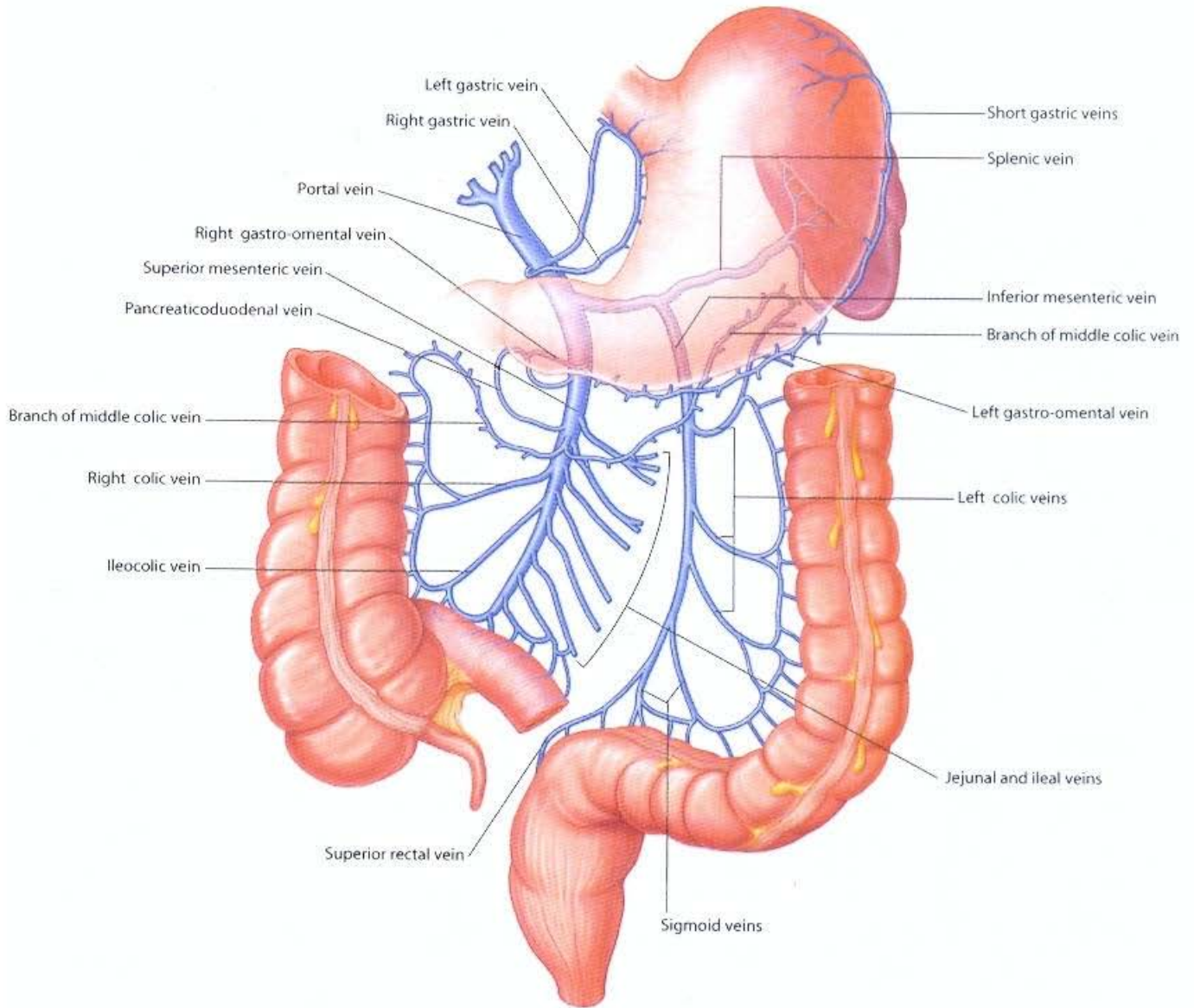
**Vasculature of the pancreas posterior view**



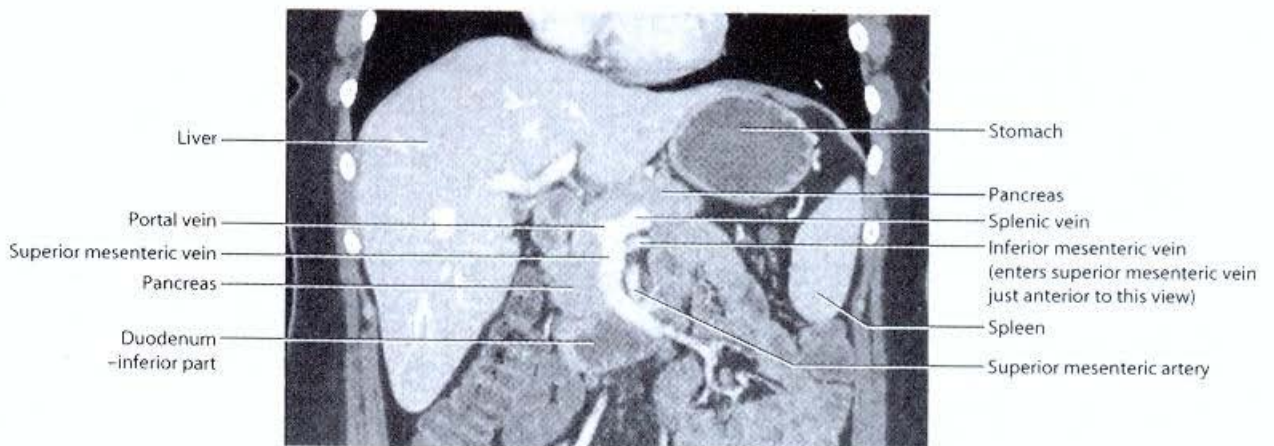

**Distribution of the common hepatic artery**



Venous drainage of the abdominal portion of the gastrointestinal tract in situ

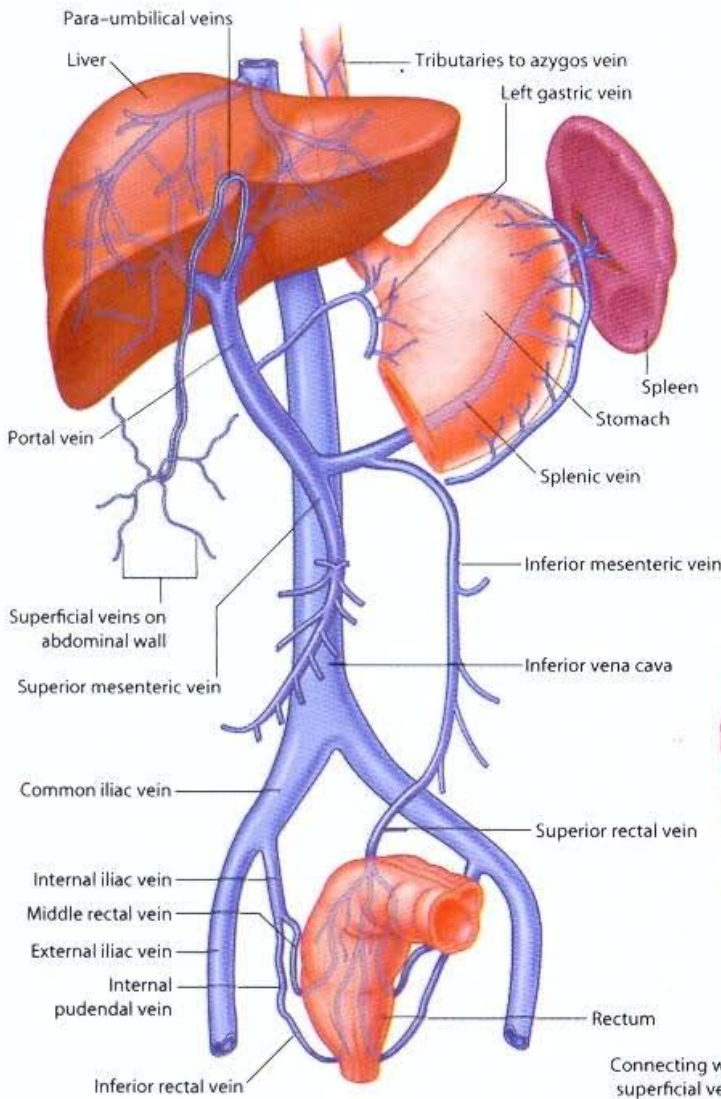


Venous drainage of the abdominal portion of the gastrointestinal tract



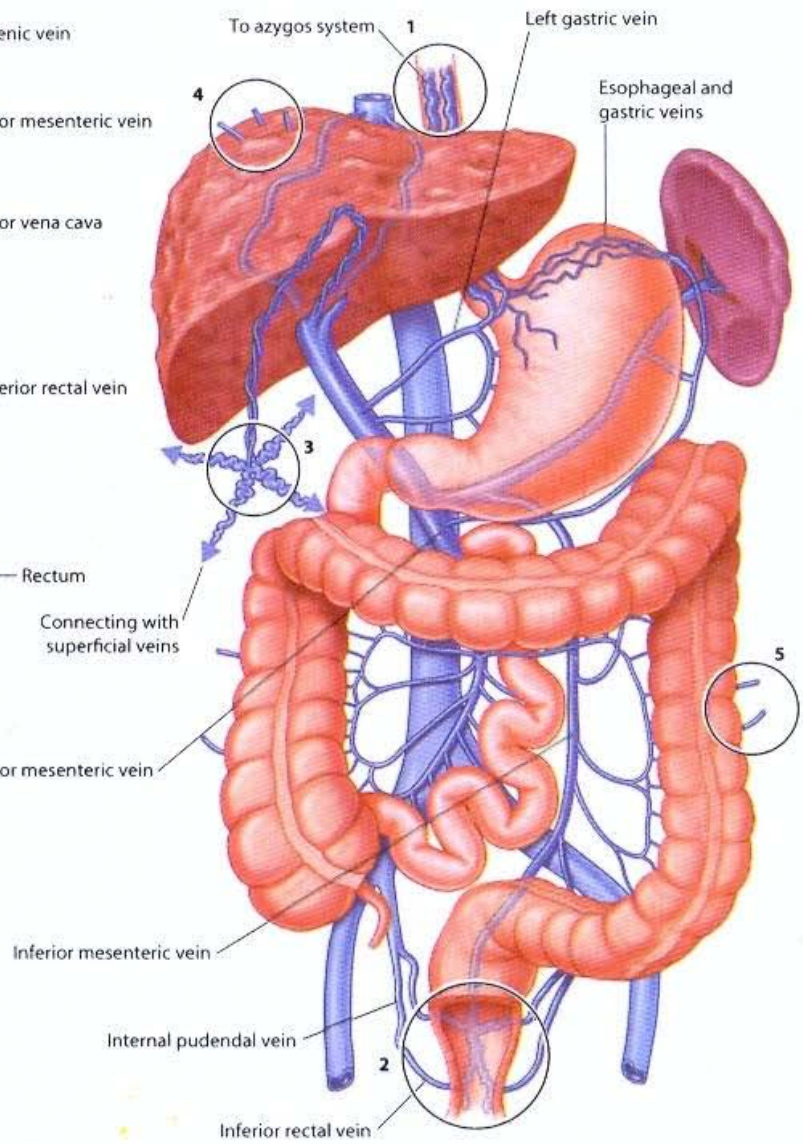
Formation of the portal vein.  
CT image, with contrast, in coronal plane



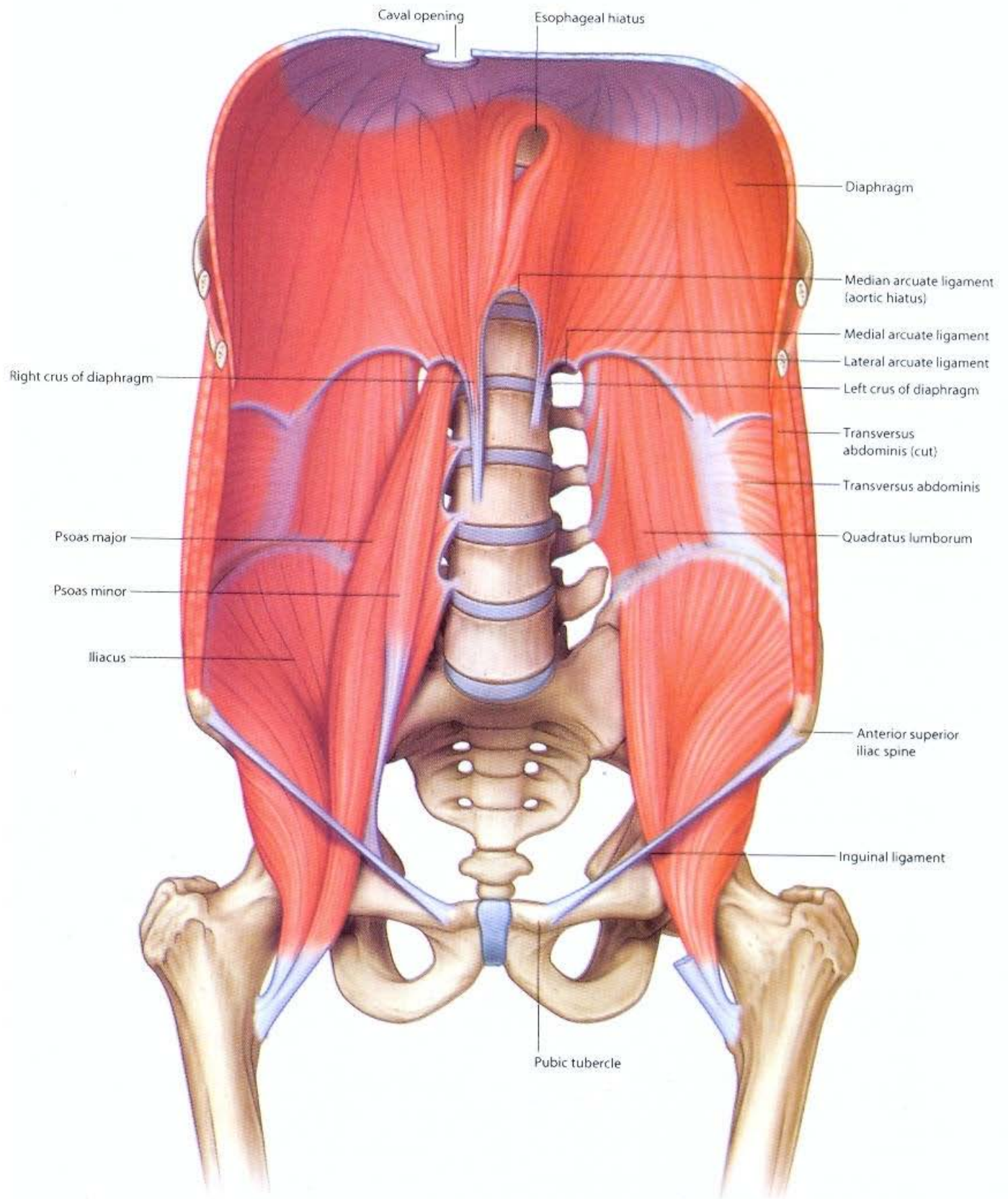


**Portosystemic anastomoses**

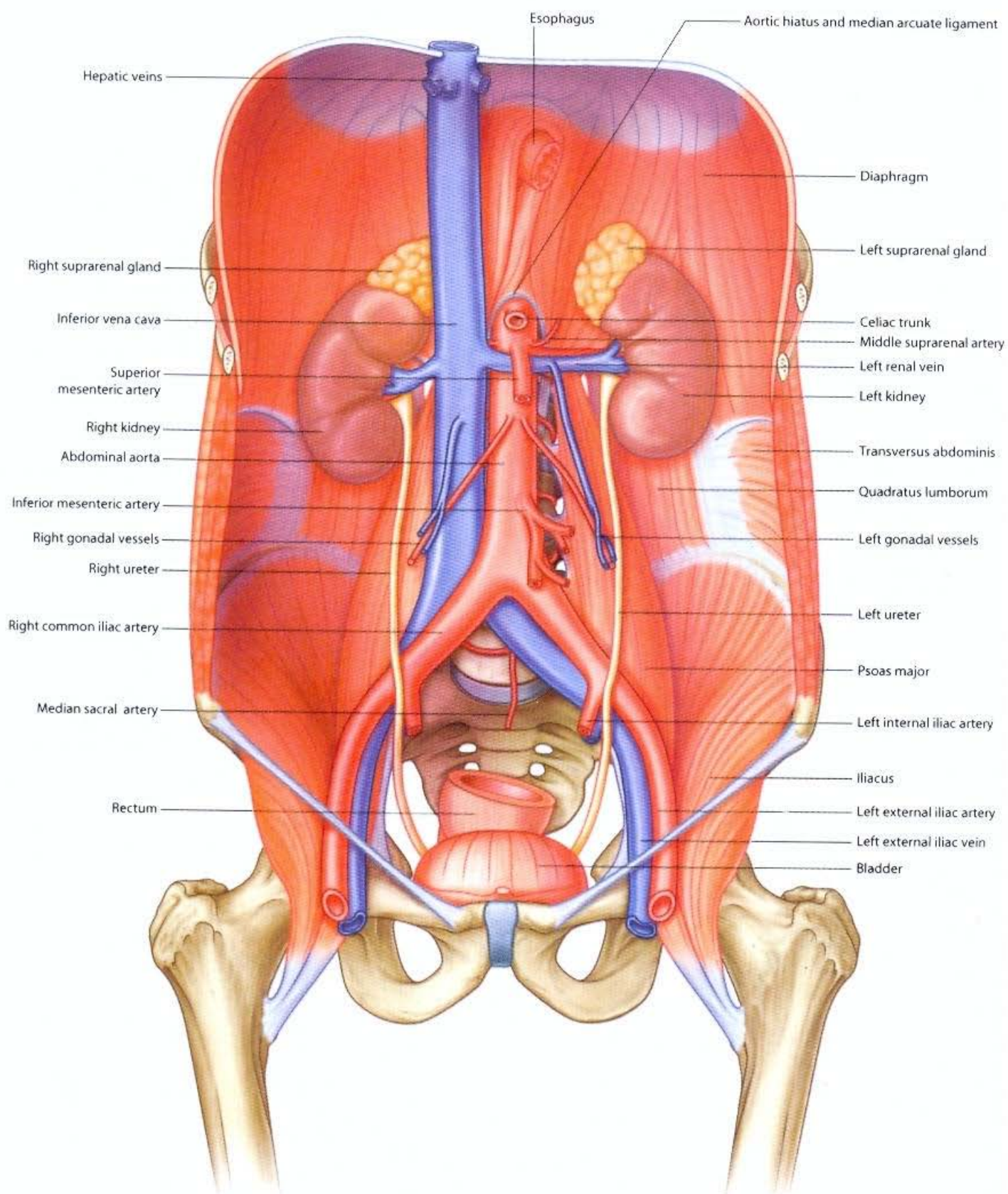
- 1 Esophageal varices: swollen connections between systemic and portal systems at inferior end of esophagus
- 2 Hemorrhoids: swollen connections between systemic and portal systems at inferior end of rectum and anal canal
- 3 Caput medusae: swollen connections between systemic and portal systems around umbilicus
- 4 Swollen connections between systemic and portal systems at bare area of liver
- 5 Swollen connections between veins associated with retroperitoneal parts of the gastro-intestinal tract and the body wall



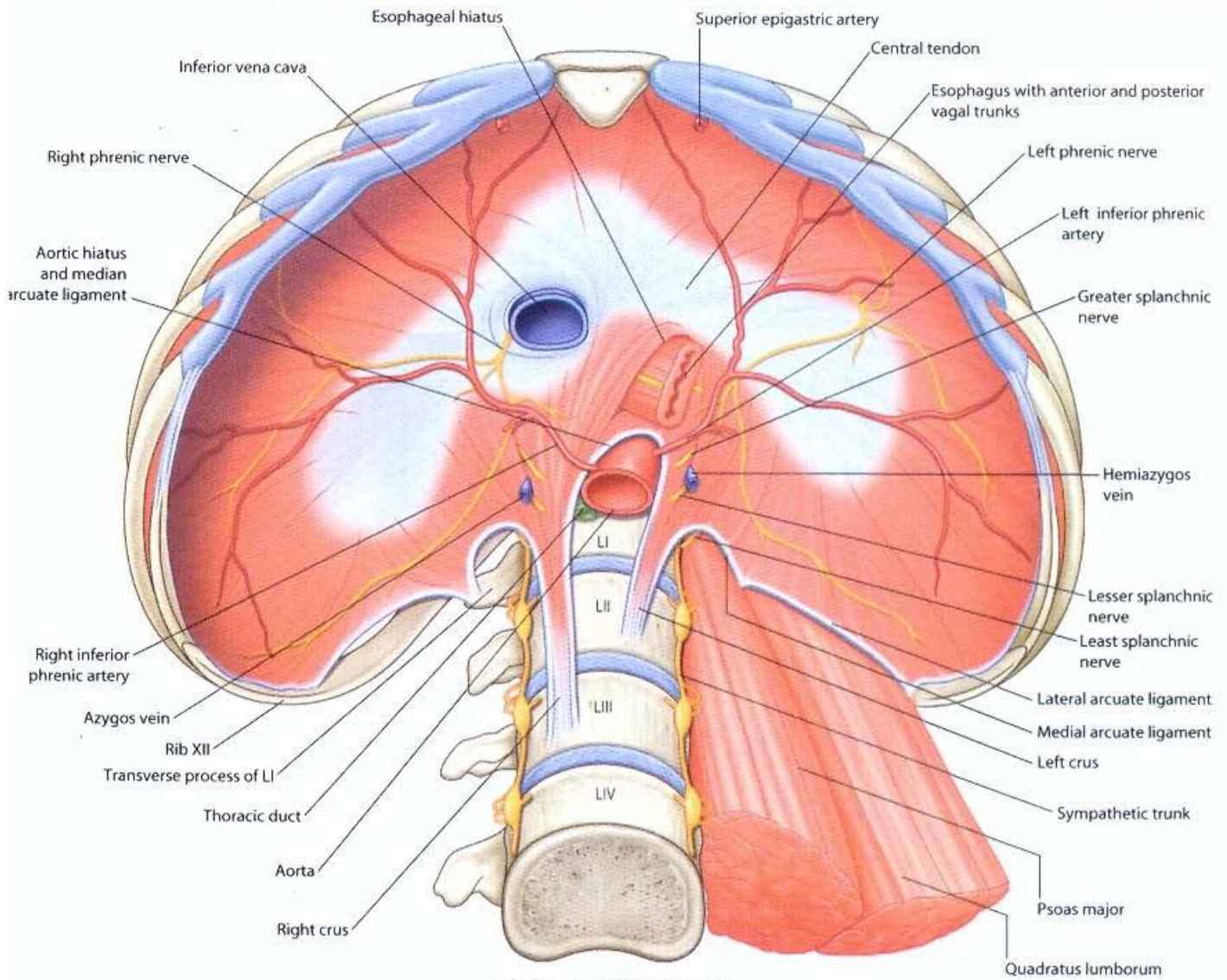
**Venous enlargement in portal hypertension(varices)**



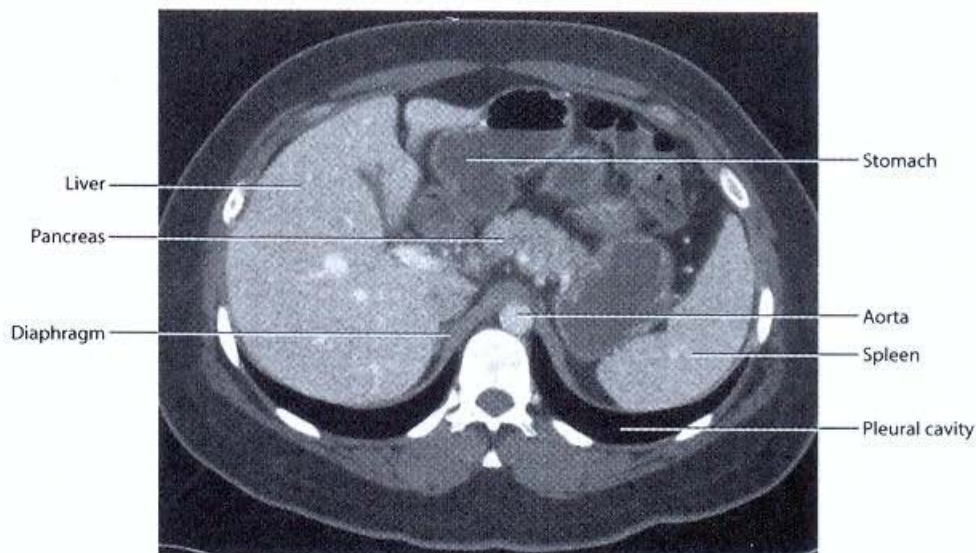
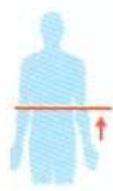
Muscles of the posterior abdominal wall



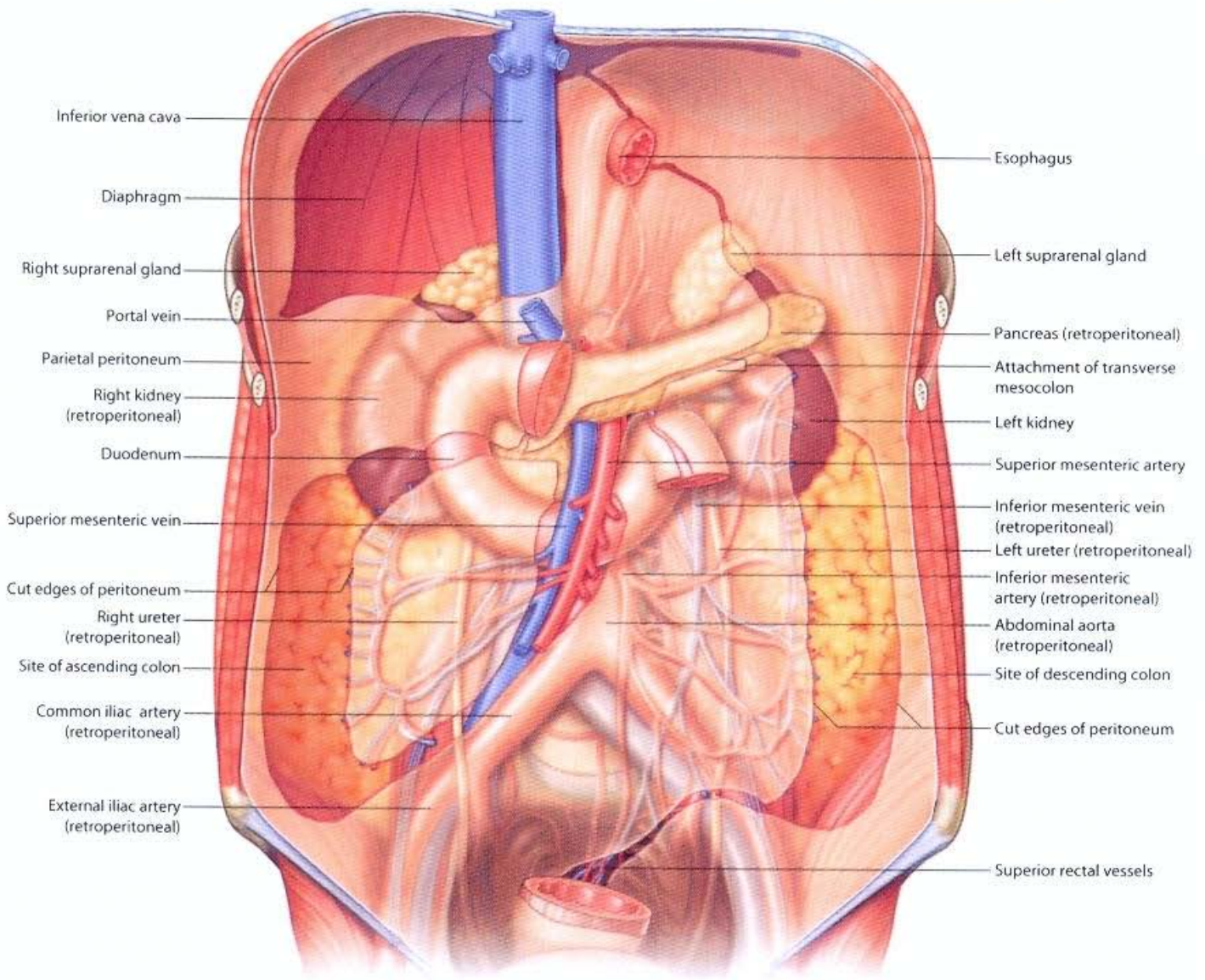
Vessels and their relationship to the posterior abdominal wall



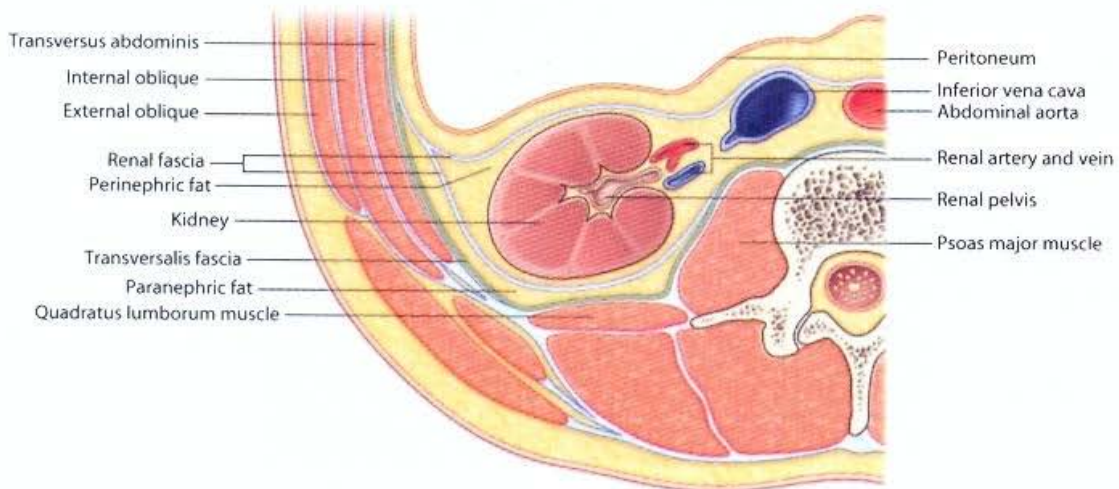
Inferior view of diaphragm



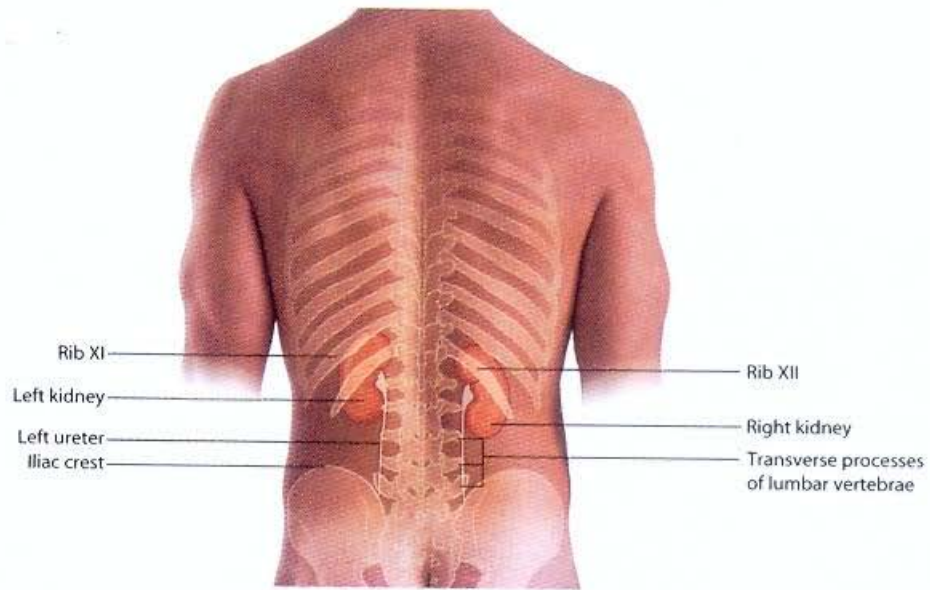
Positioning of the diaphragm in relation to other structures. CT image, with contrast, in axial plane



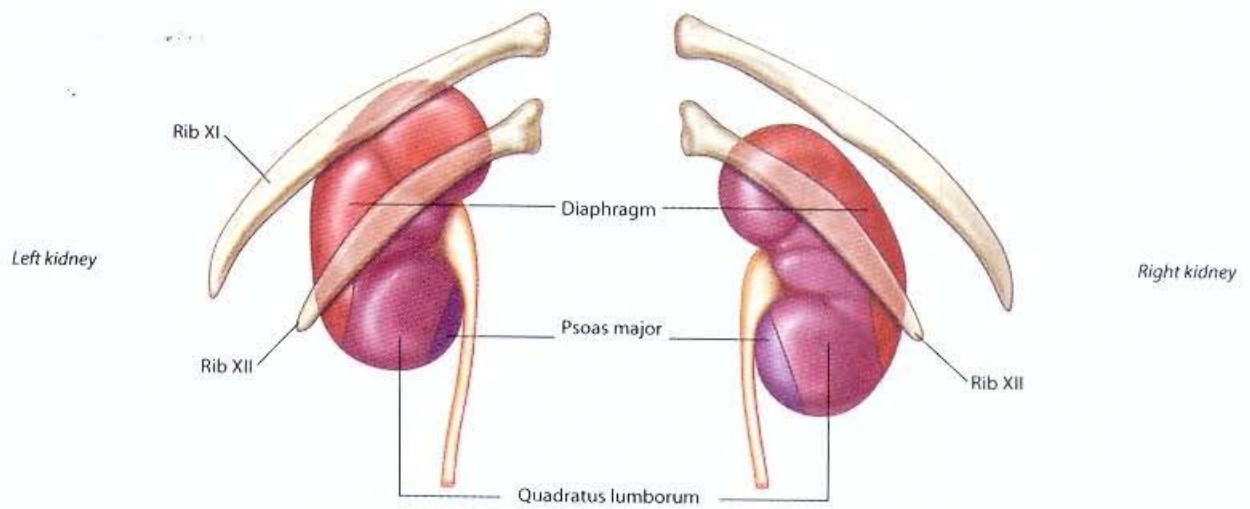
**Peritoneum and the retroperitoneal position of the kidneys**



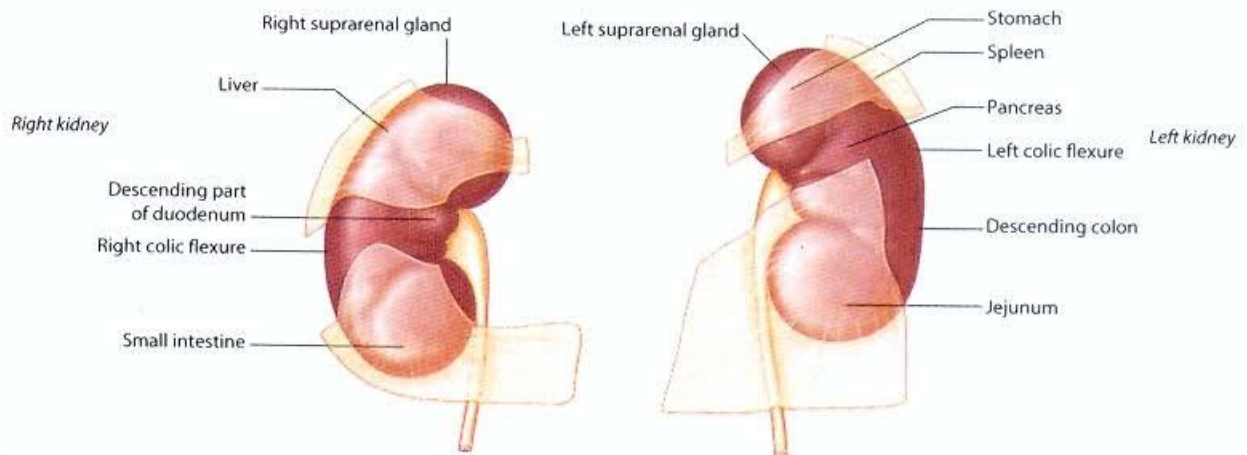
**Organization of fat and fascia surrounding the kidneys**



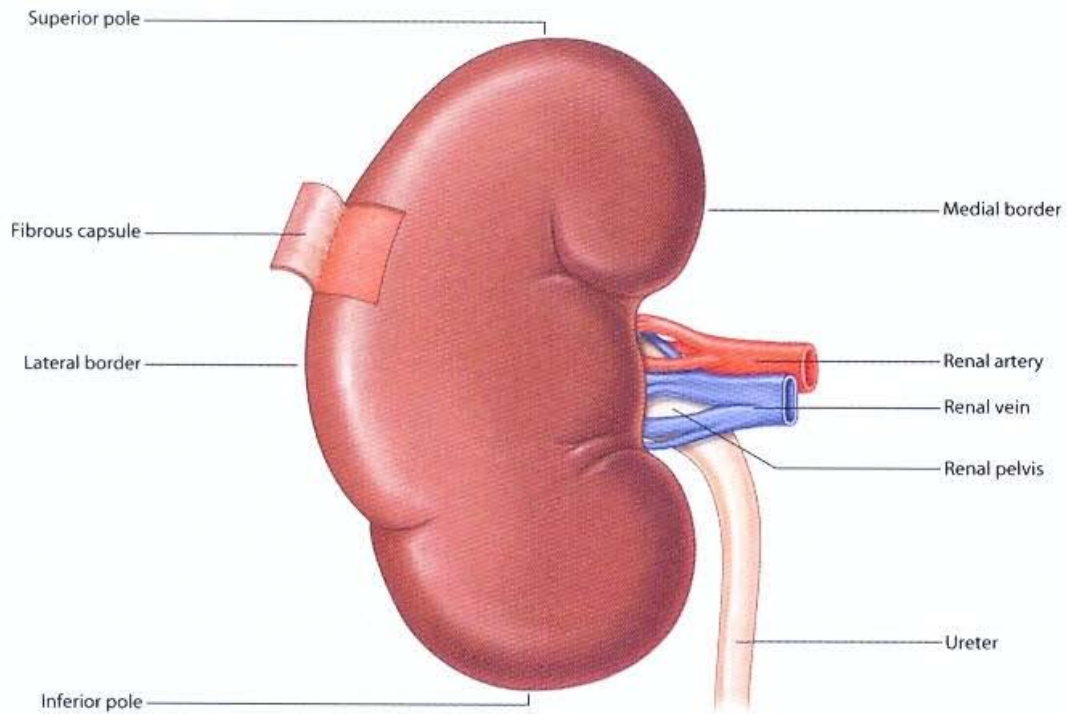
Surface projection of the kidneys and ureters (posterior view)



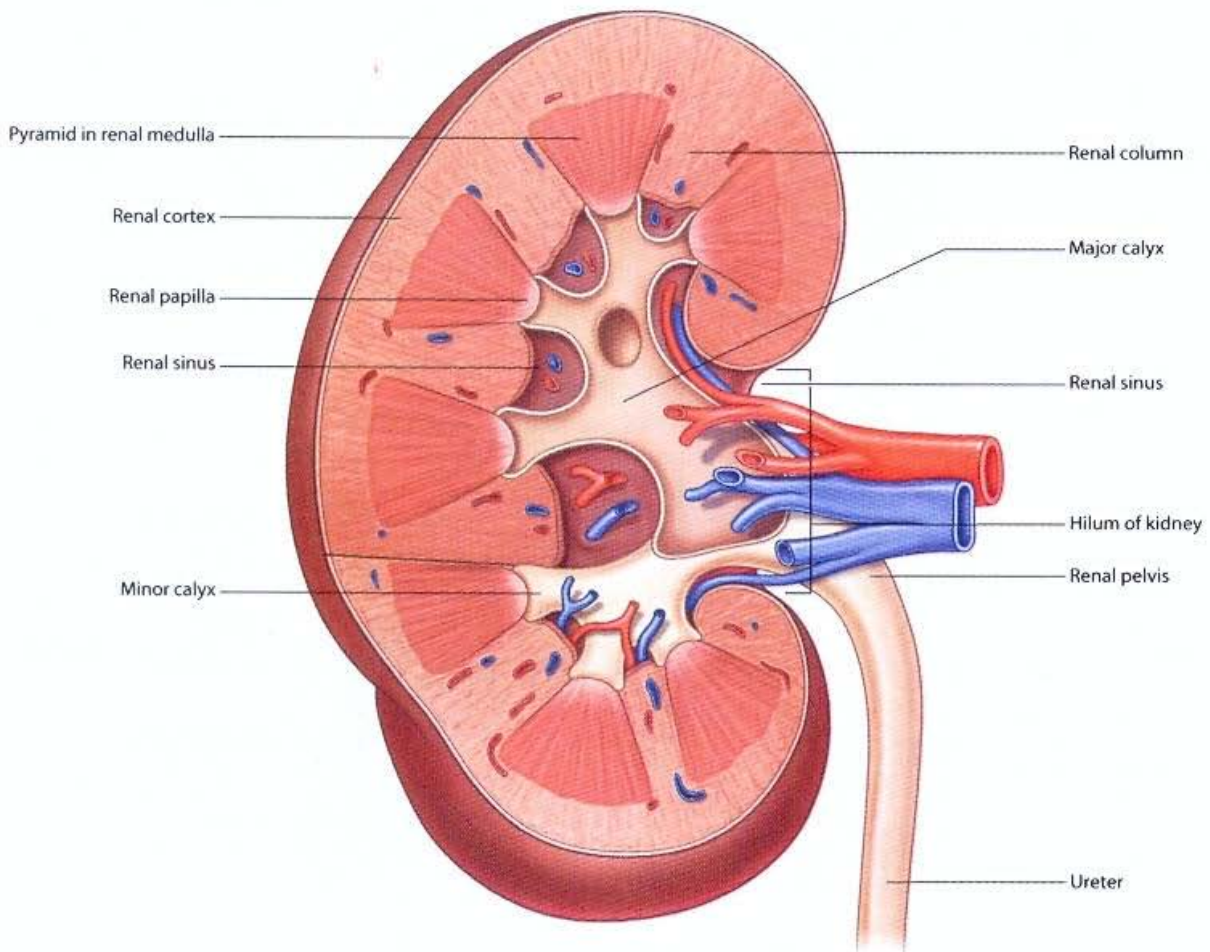
Structures related to the posterior surface of each kidney



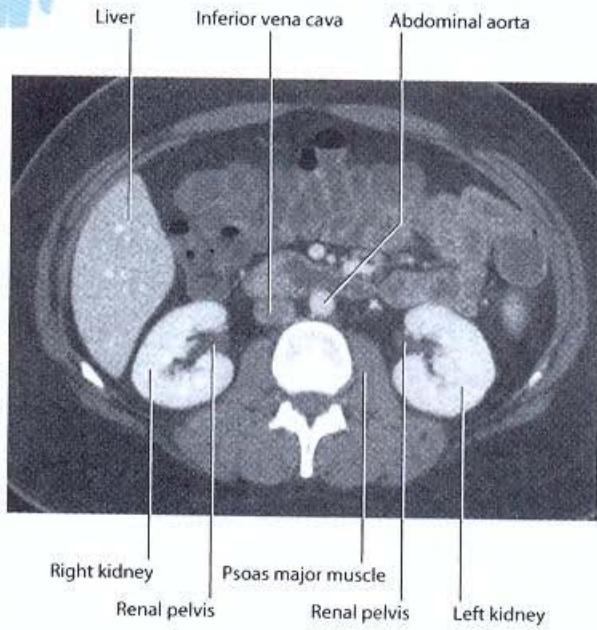
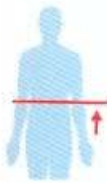
Structures related to the anterior surface of each kidney



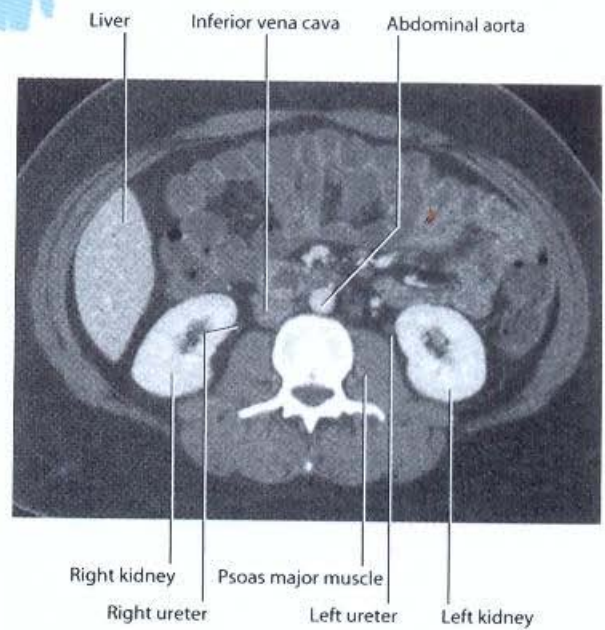
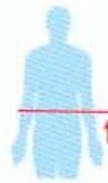**Anterior surface of right kidney**



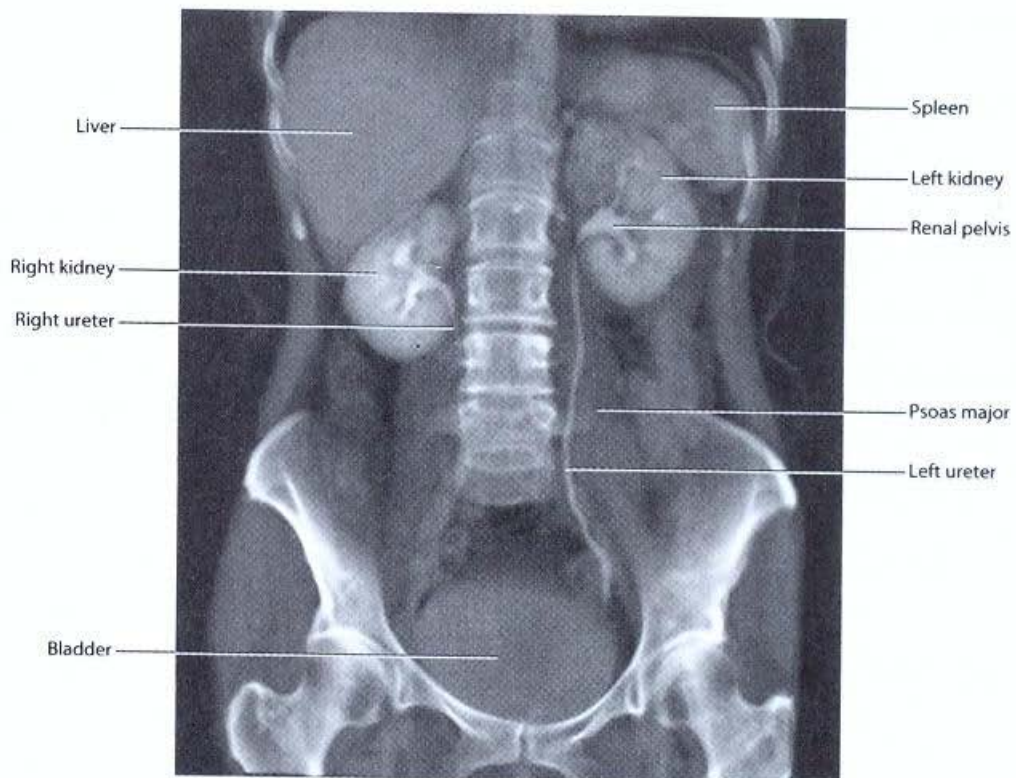**Internal structure of the right kidney**



**Renal pelvis.**  
CT image, with contrast, in axial plane

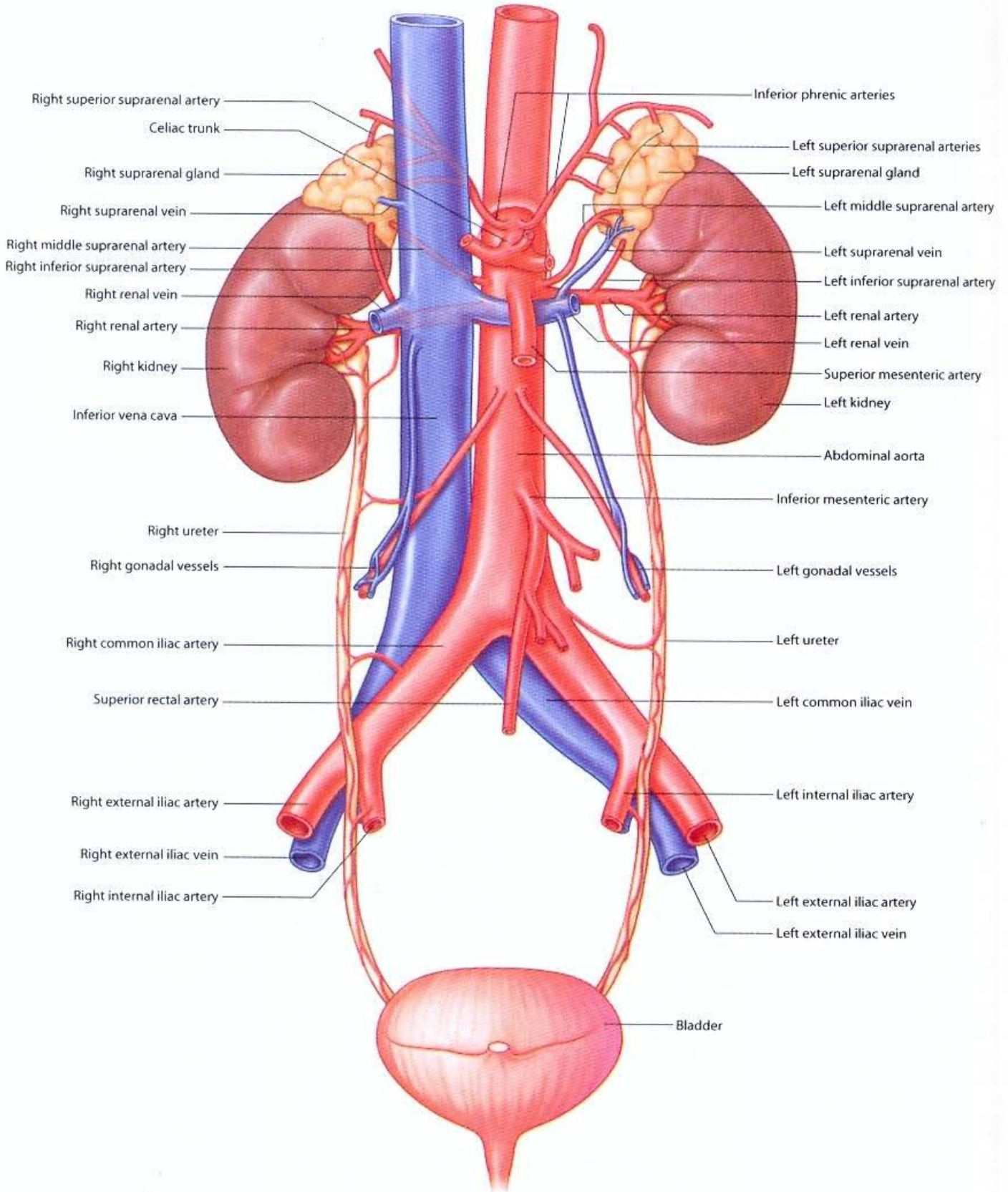


**Location of ureters.**  
CT image, with contrast, in axial plane

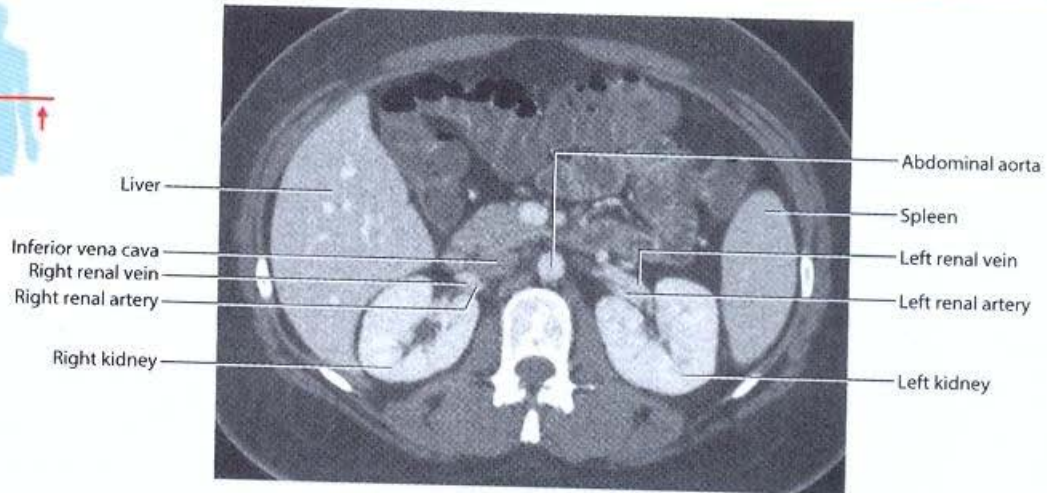
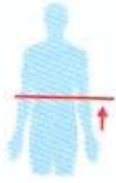


**Pathway of ureter in relation to other structures.**  
Coronal view of 3-D urogram using multidetector computed tomography

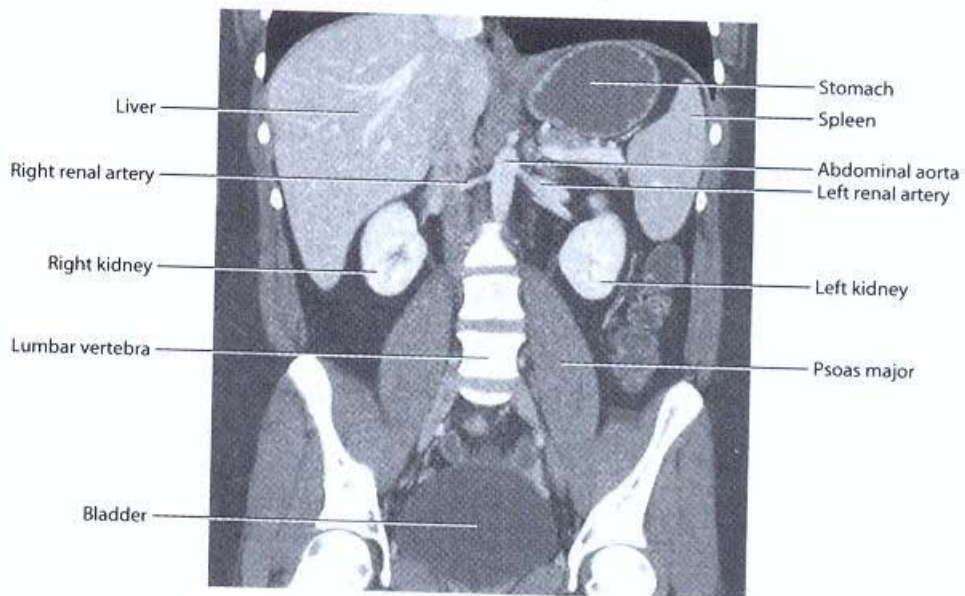
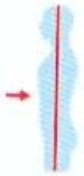




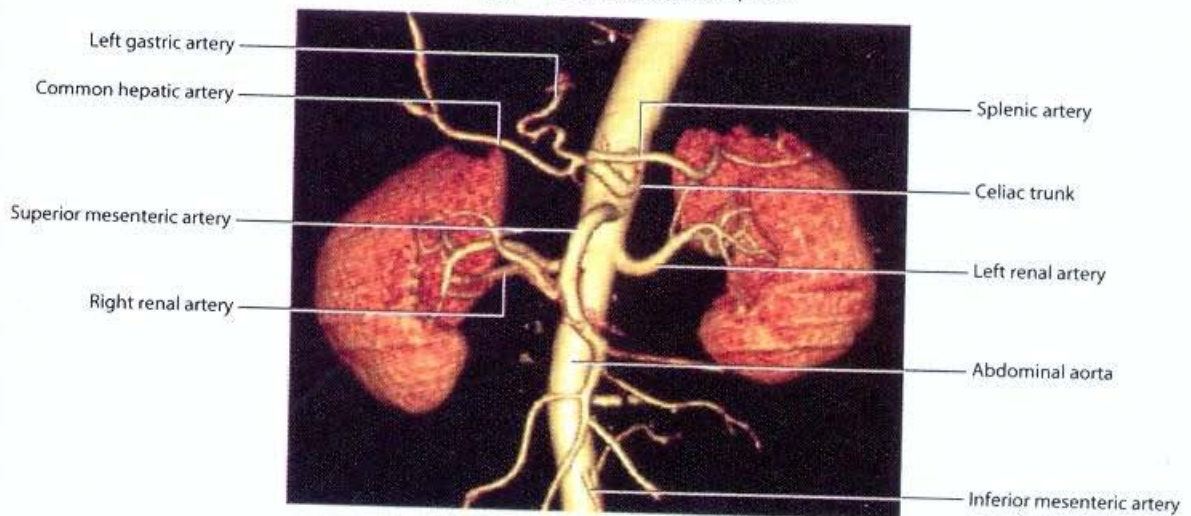
Vasculature relating to kidneys, suprarenal glands, and ureters



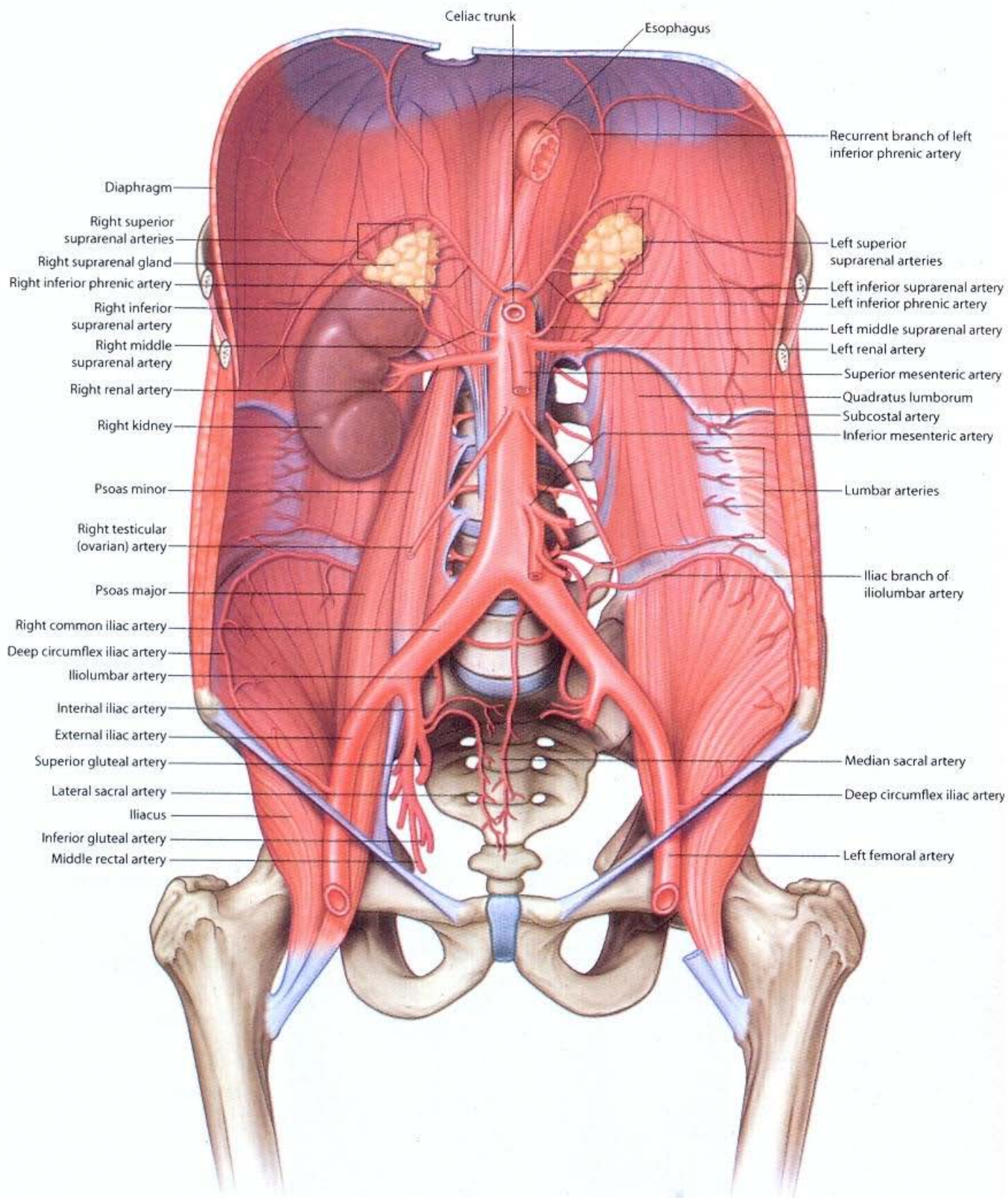
**Renal vasculature.**  
CT image, with contrast, in axial plane



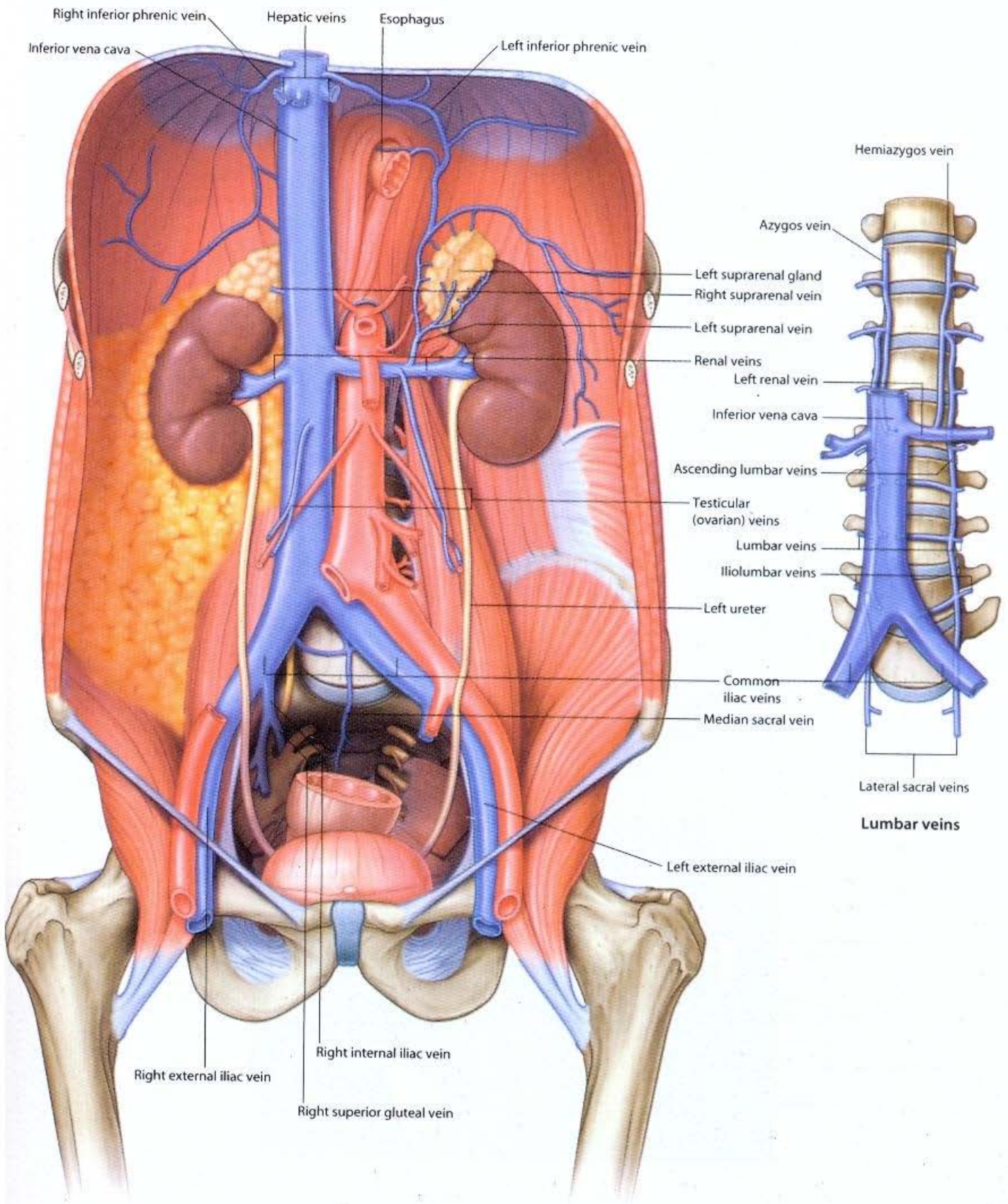
**Renal arteries.**  
CT image, with contrast, in coronal plane



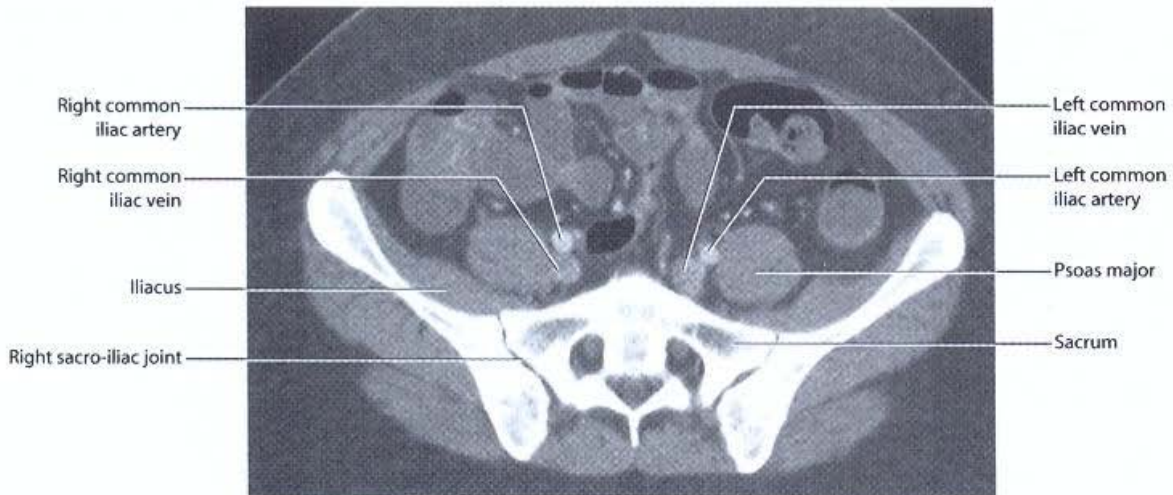
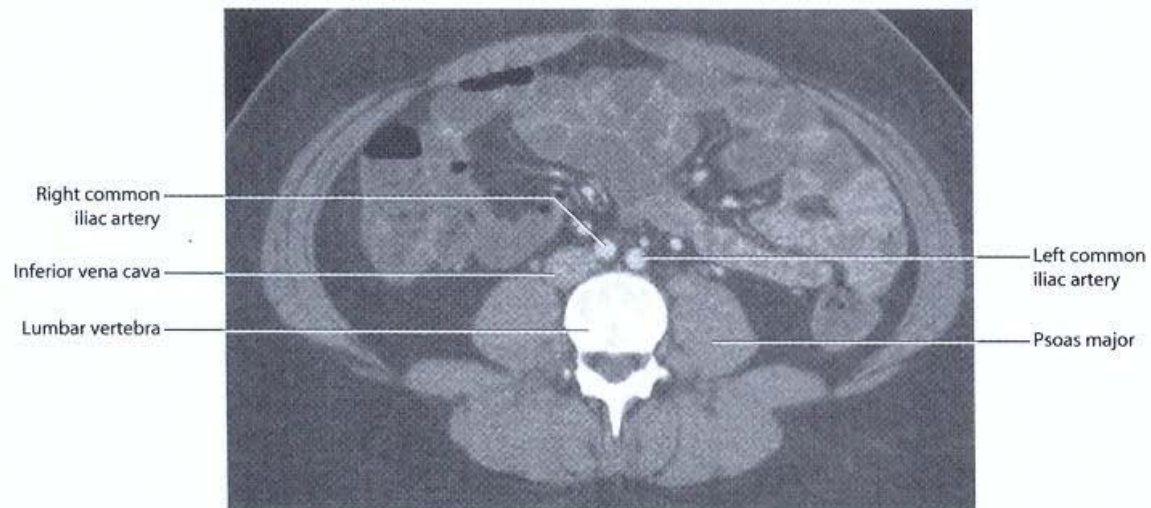
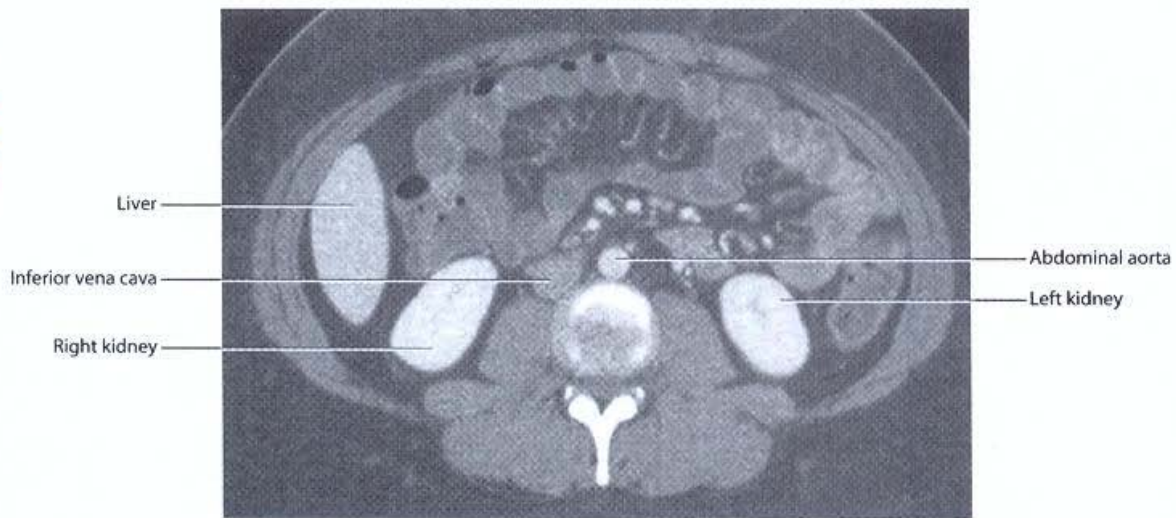
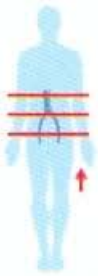
**Renal arteries.**  
Volume-rendered anterior view using multidetector computer tomography



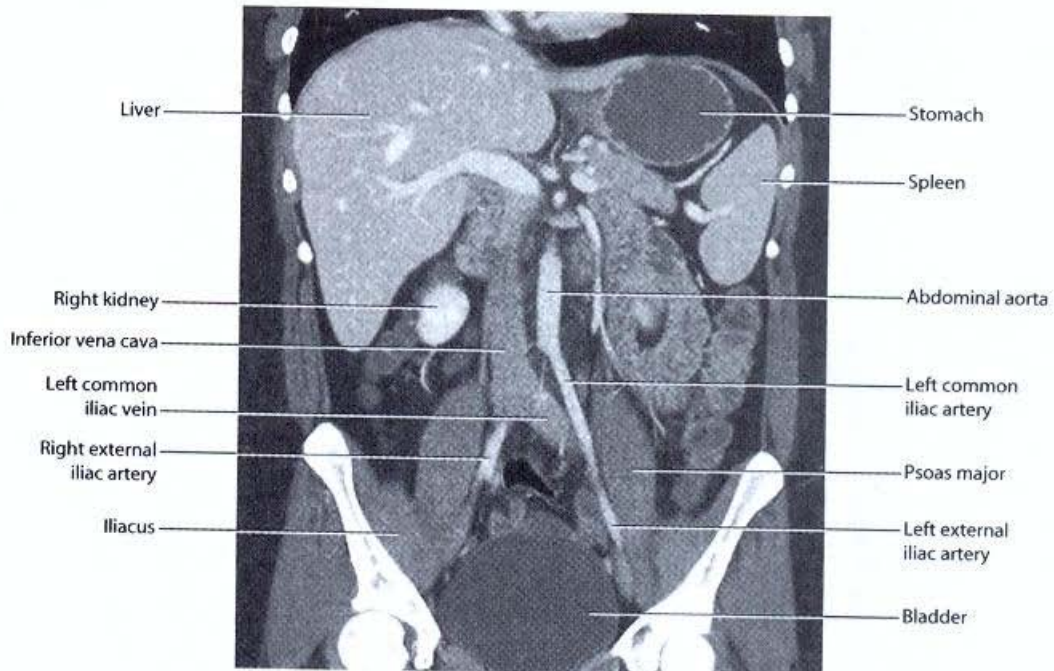
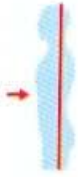
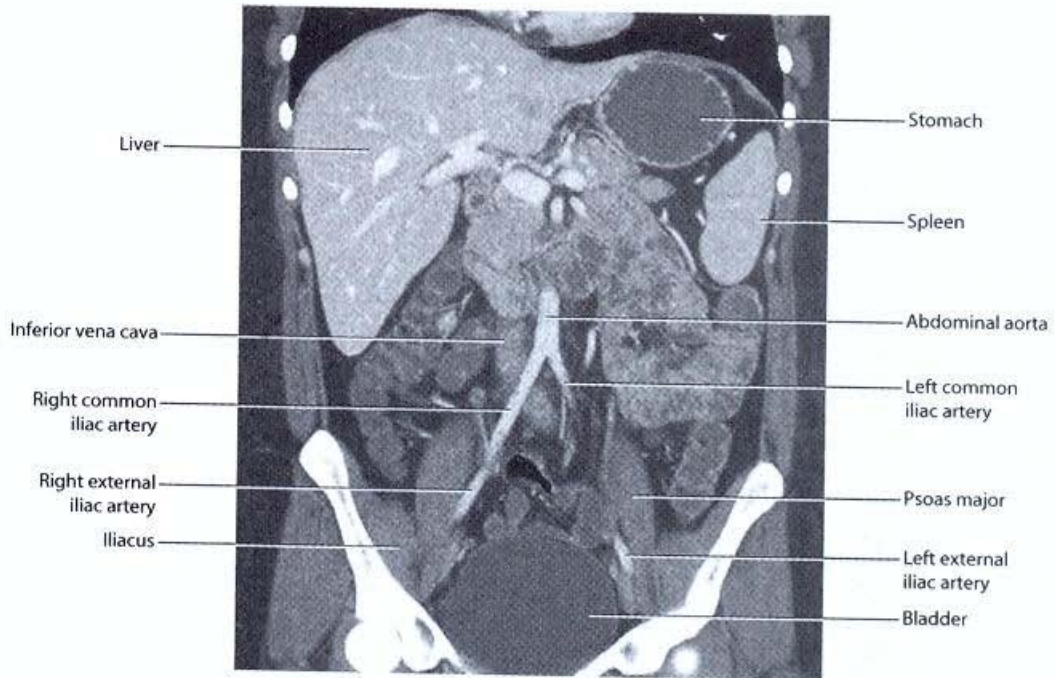
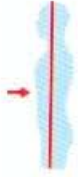
Abdominal aorta and branches



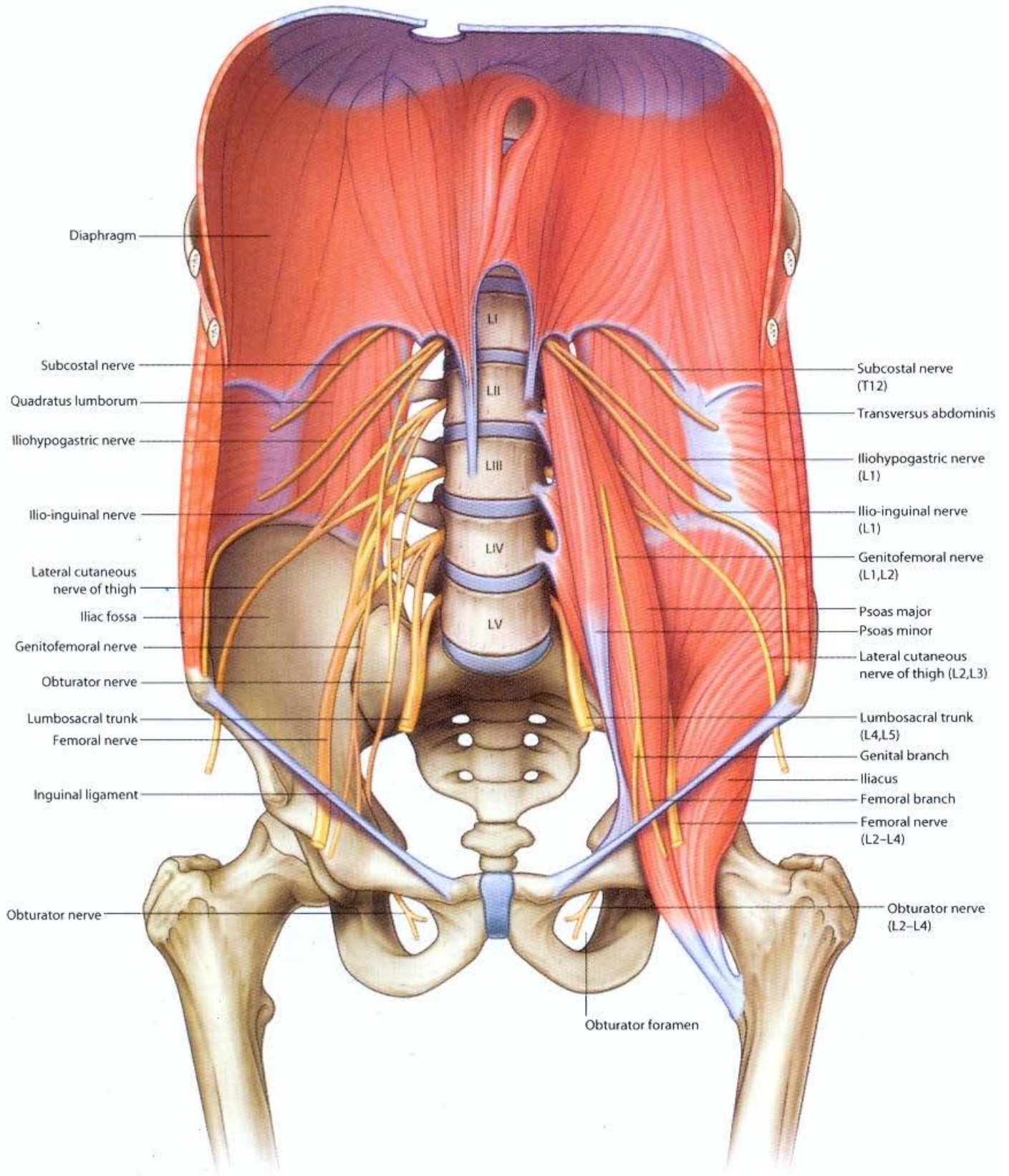
Inferior vena cava and tributaries



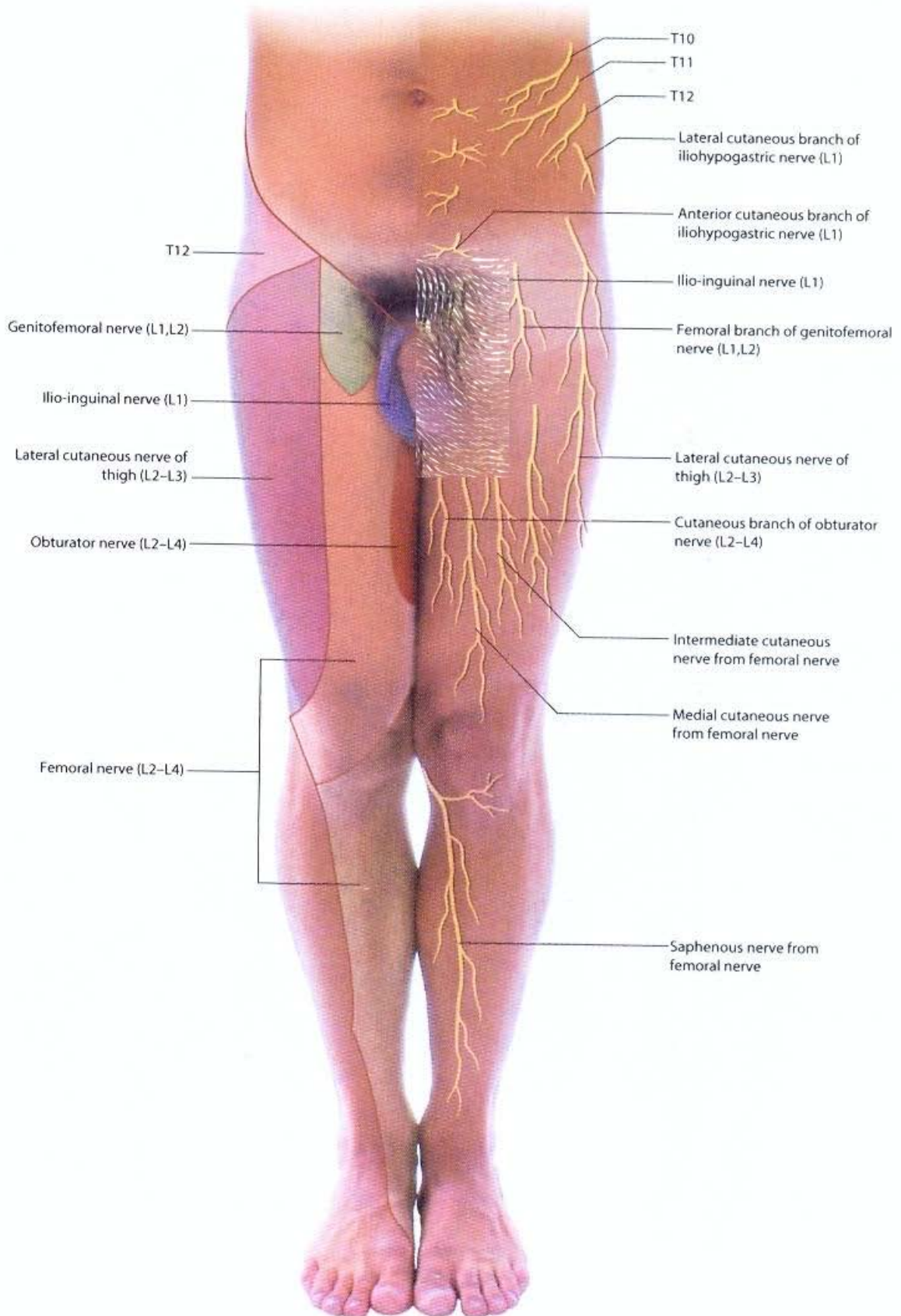
**Abdominal aorta and inferior vena cava.**  
CT images, with contrast, in axial plane



Positioning of the abdominal aorta and inferior vena cava in relation to other structures.  
 CT images, with contrast, in coronal plane

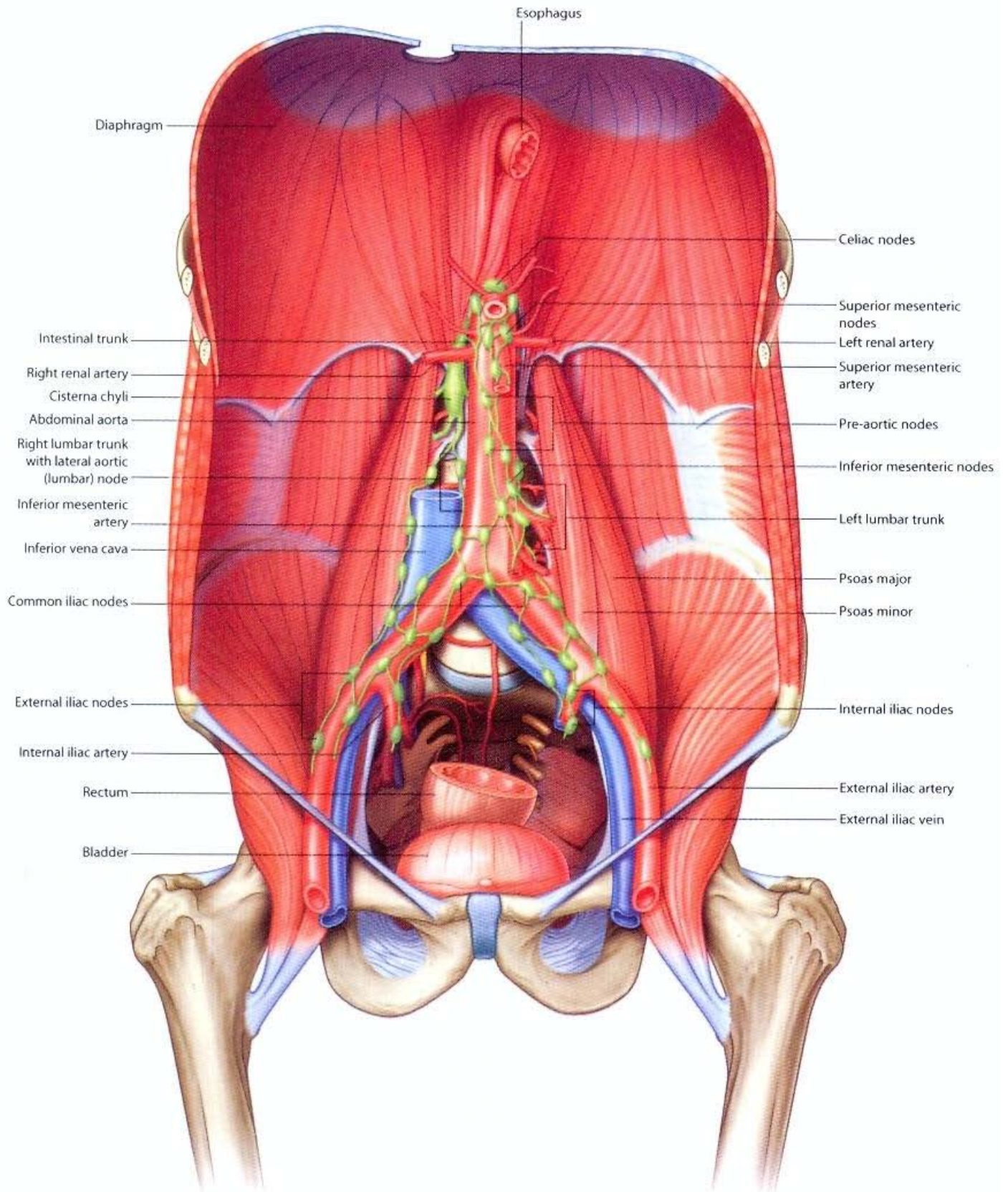


Lumbar plexus

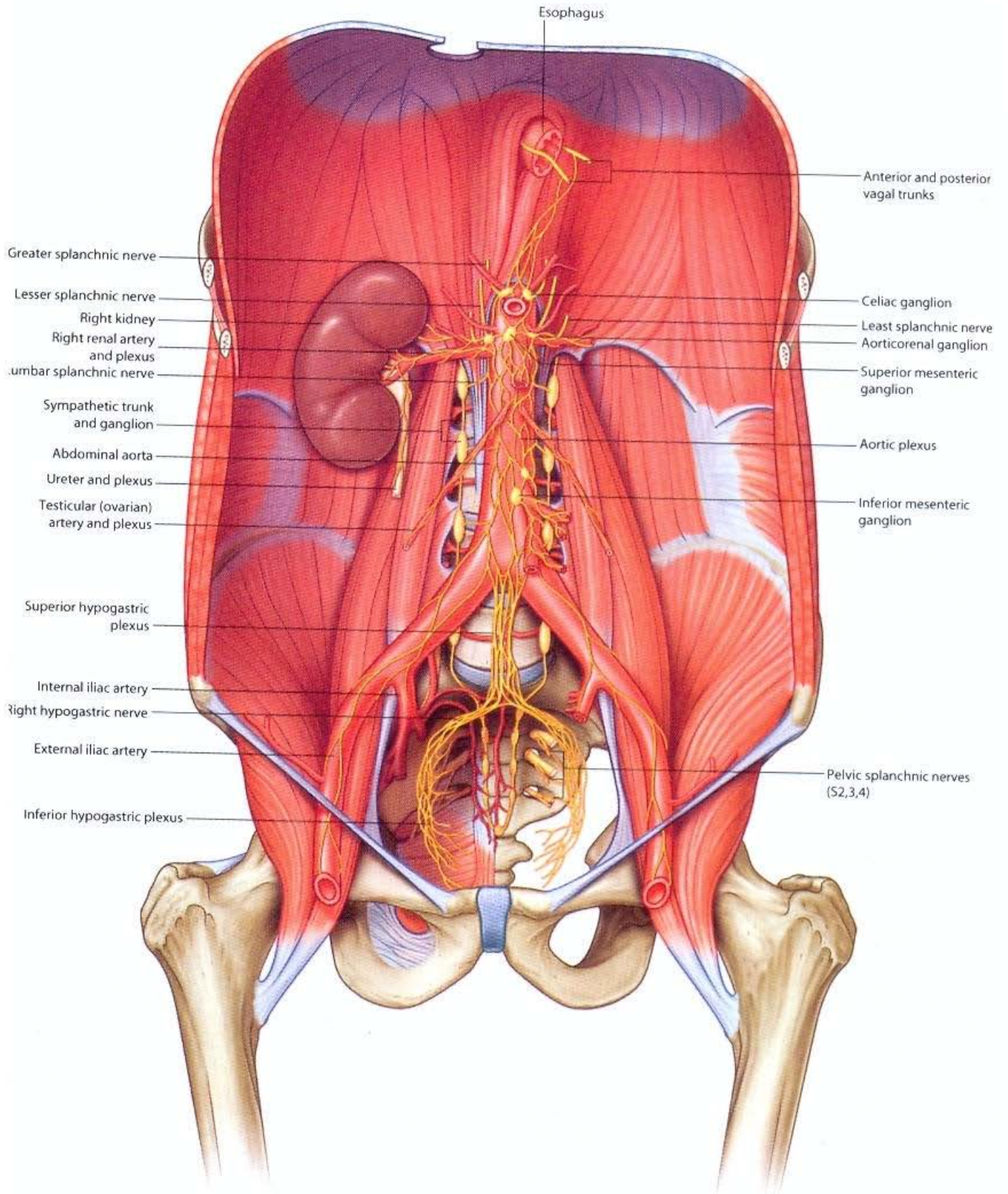


Cutaneous distribution of the nerves from the lumbar plexus

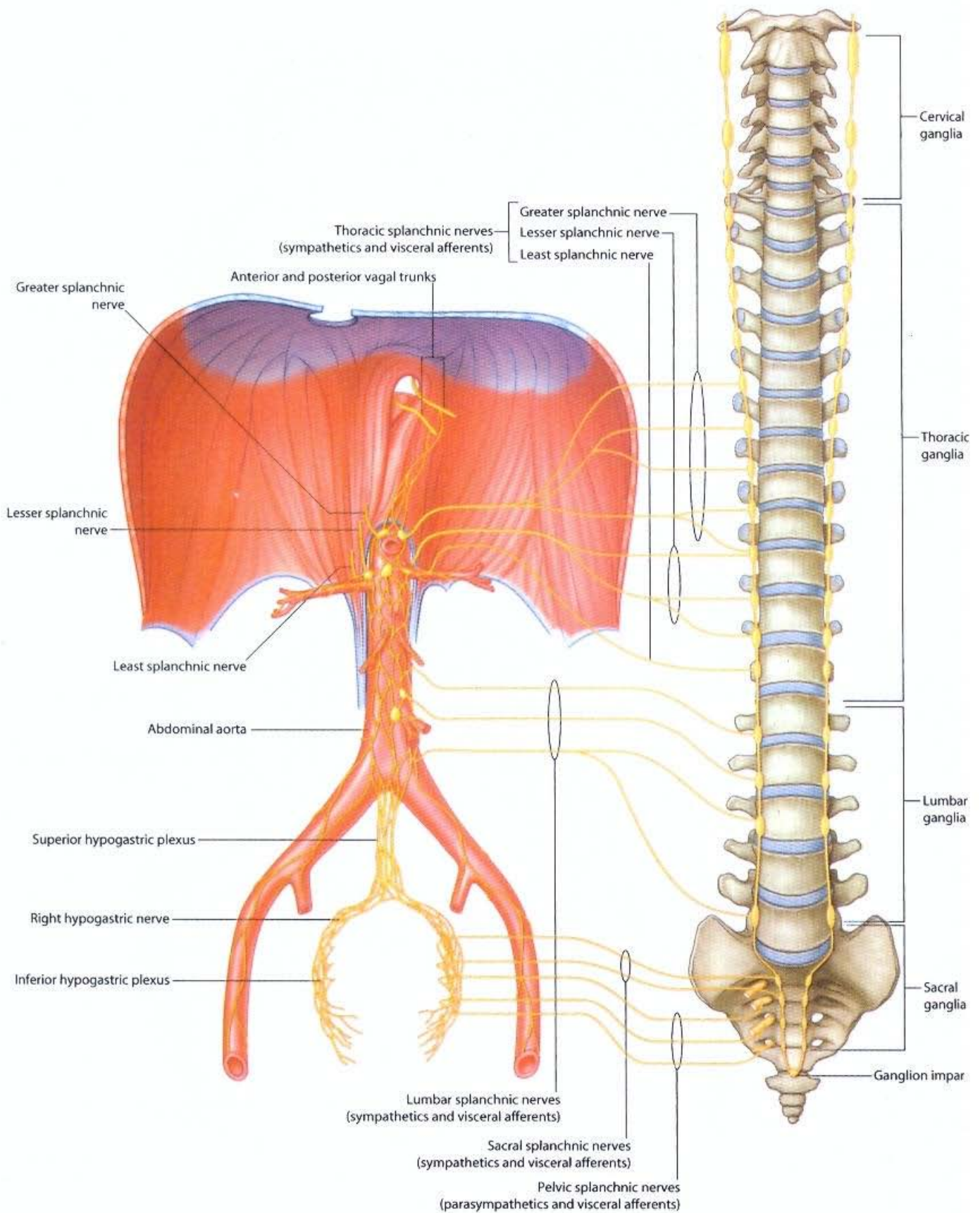




Abdominal lymphatics

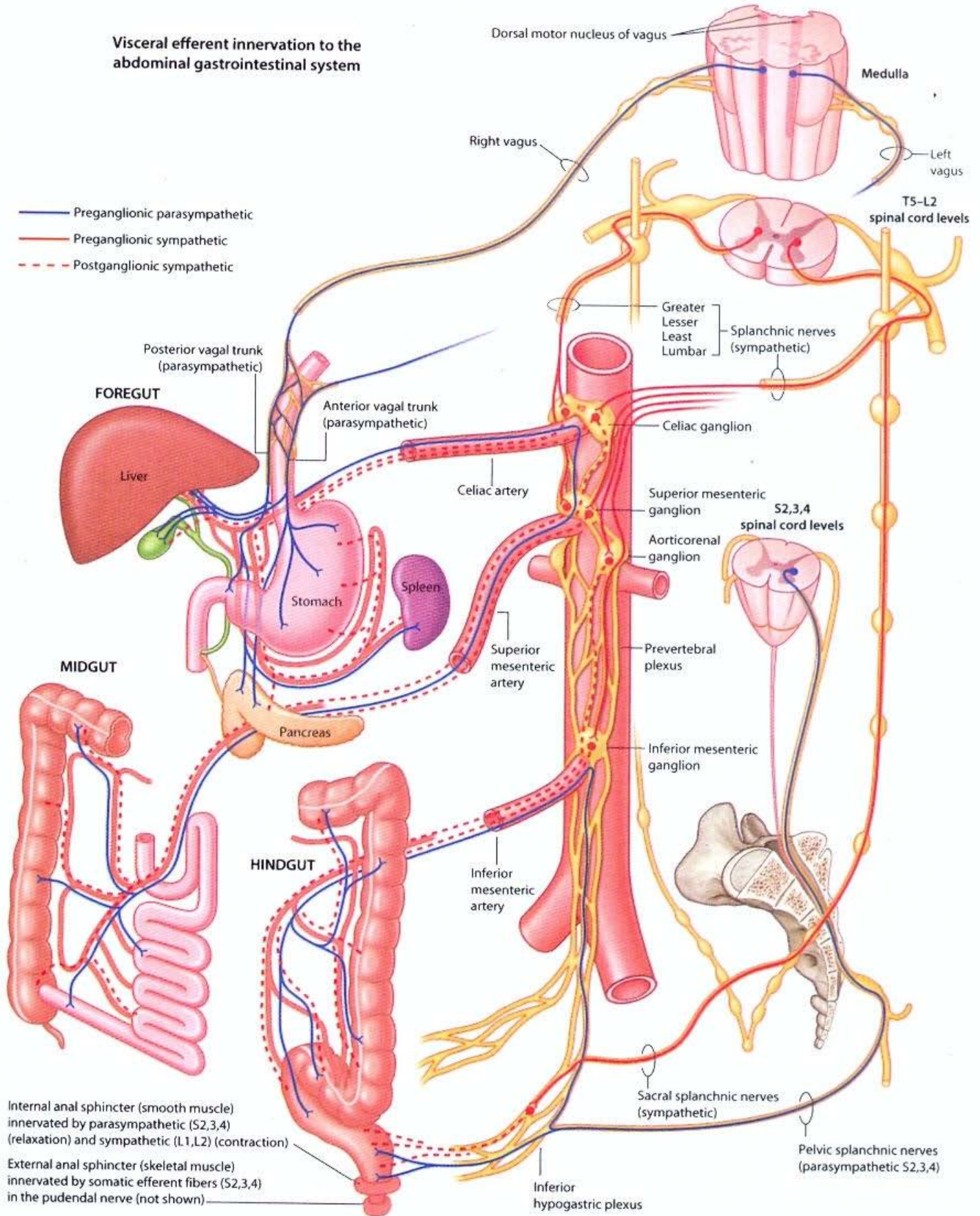


Prevertebral plexuses and ganglia with sympathetic trunks

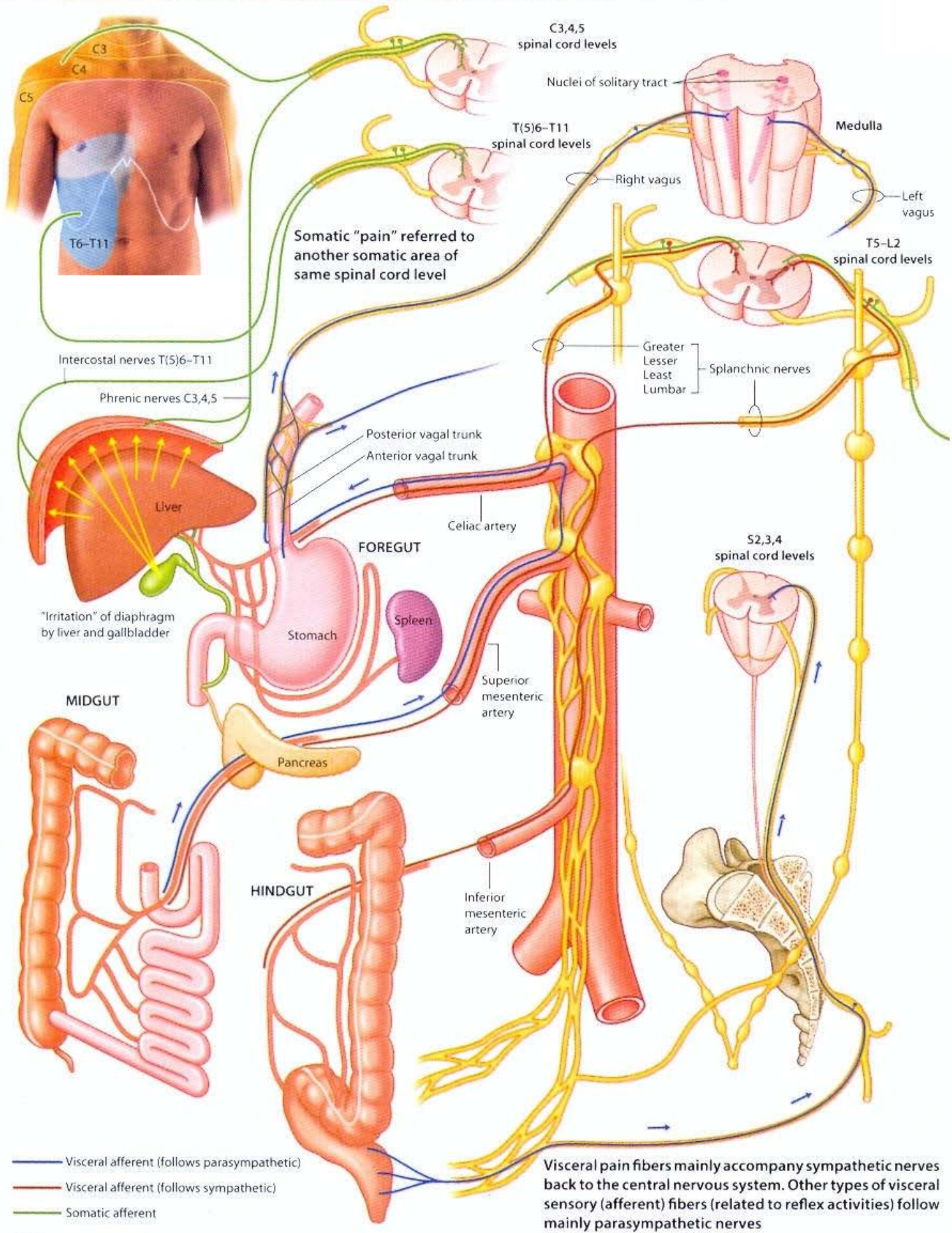


**Splanchnic nerves**

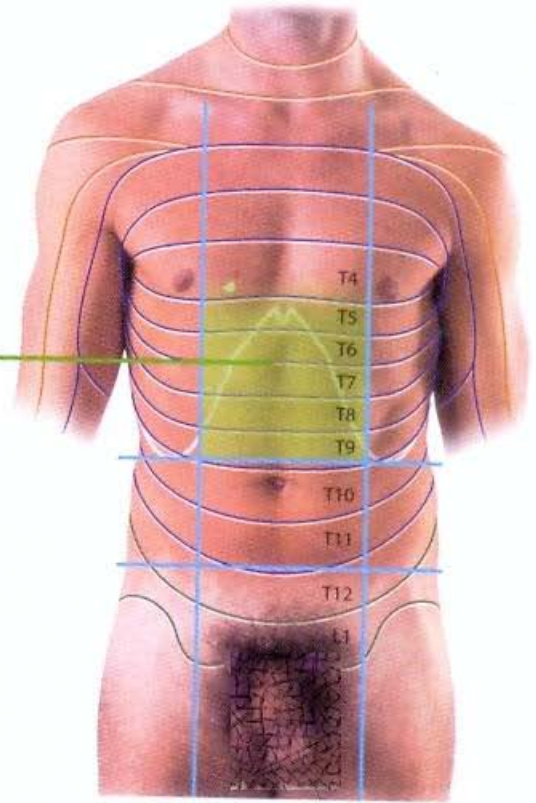
**Visceral efferent innervation to the abdominal gastrointestinal system**



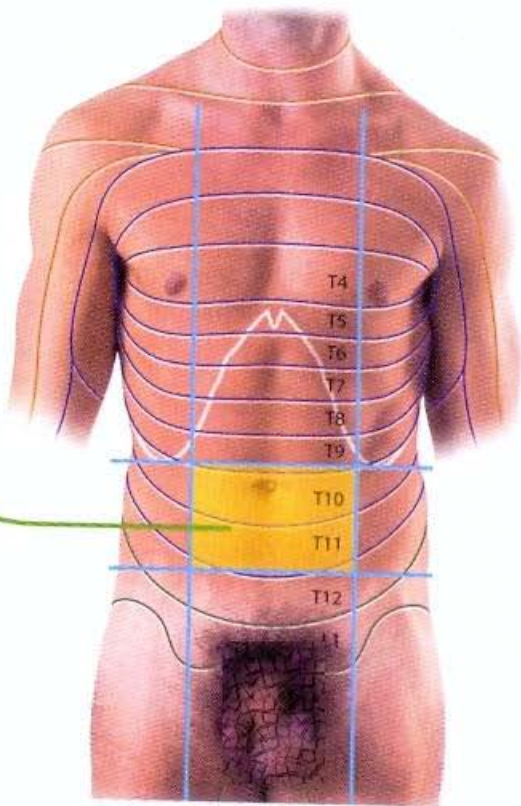
# ABDOMEN • Visceral afferent (sensory) innervation and referred pain diagram



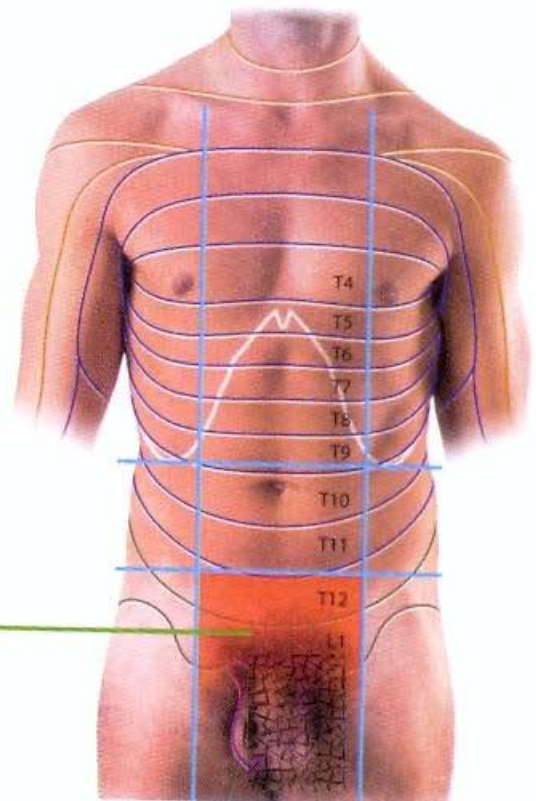
Visceral "pain" referred to somatic area innervated by same spinal cord level



FOREGUT



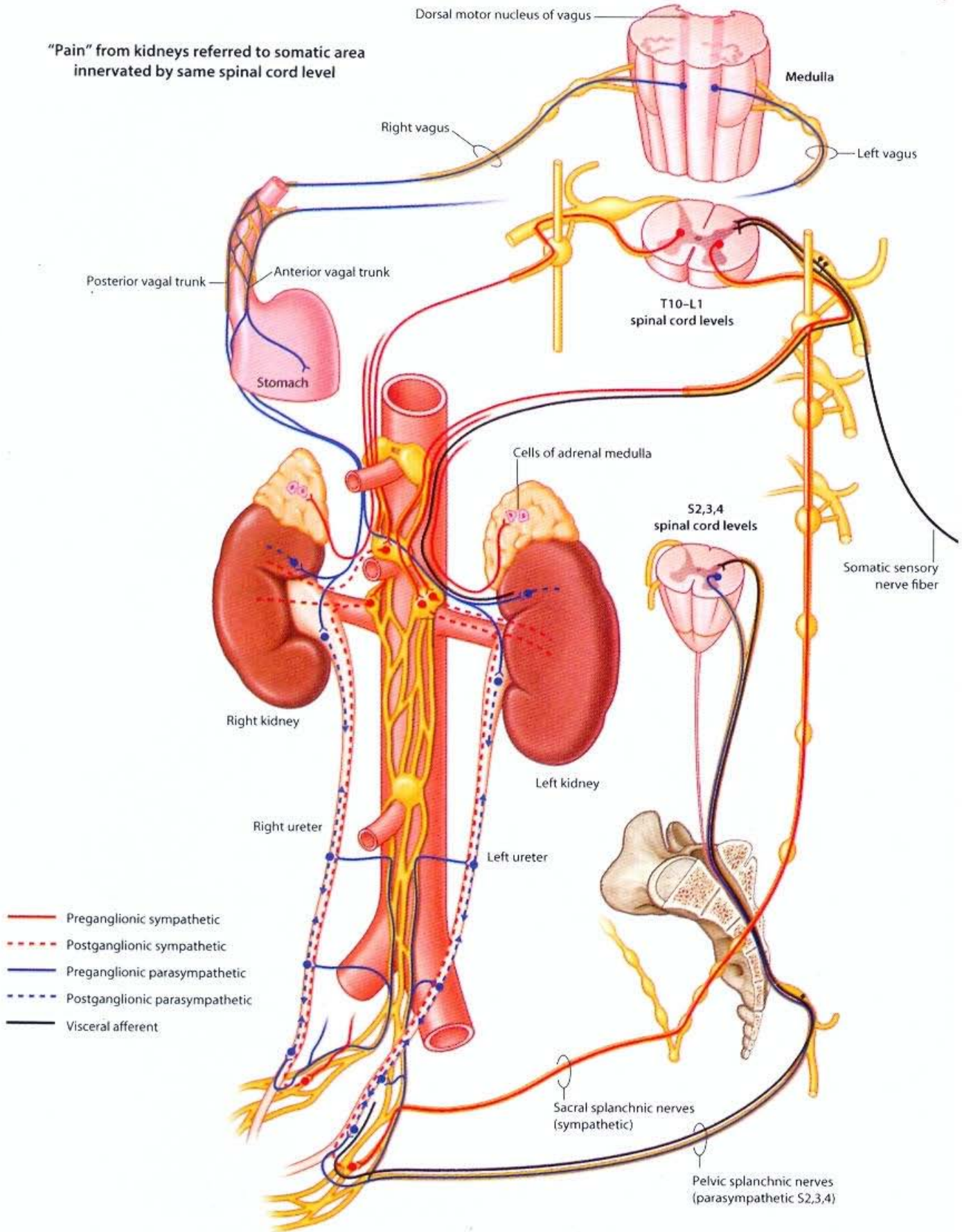
MIDGUT

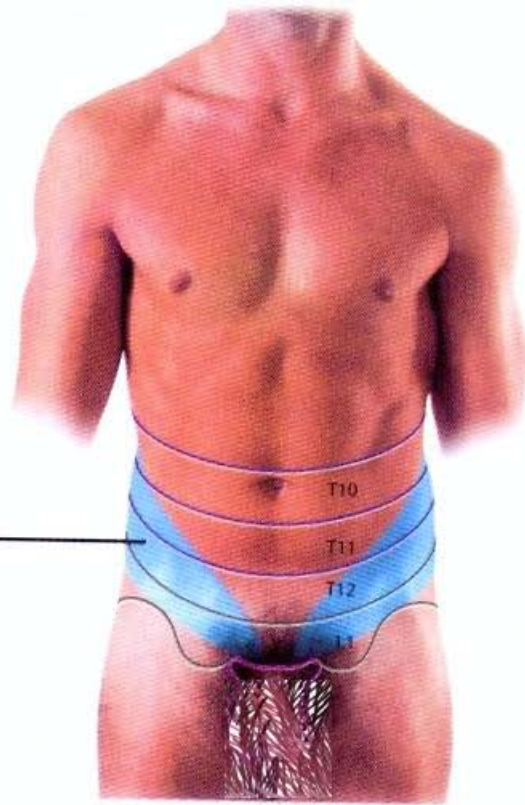


HINDGUT

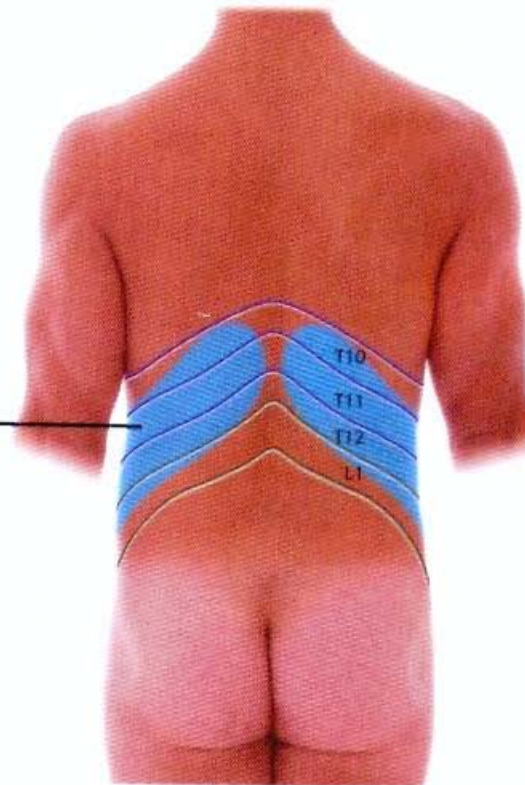
# ABDOMEN • Kidney and ureter visceral afferent (sensory) diagram

"Pain" from kidneys referred to somatic area innervated by same spinal cord level





T10-L1 dermatomes



Pain fibers mainly follow sympathetic nerves to the central nervous system (CNS). This pain is 'referred' by the CNS to the somatic area innervated by the same spinal levels. Other types of visceral afferent (sensory) fibers (related to reflex activities) follow mainly parasympathetic nerves

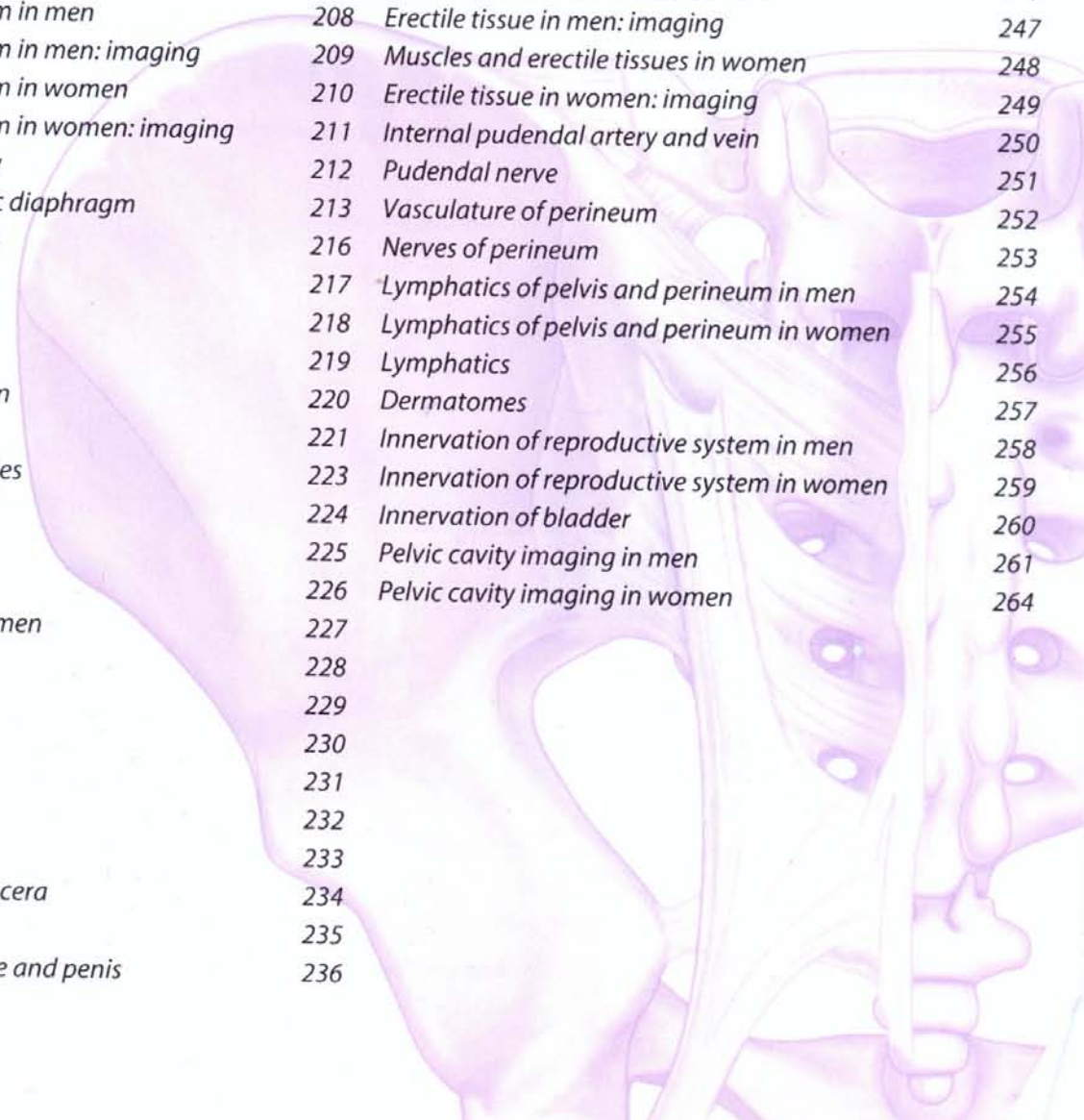


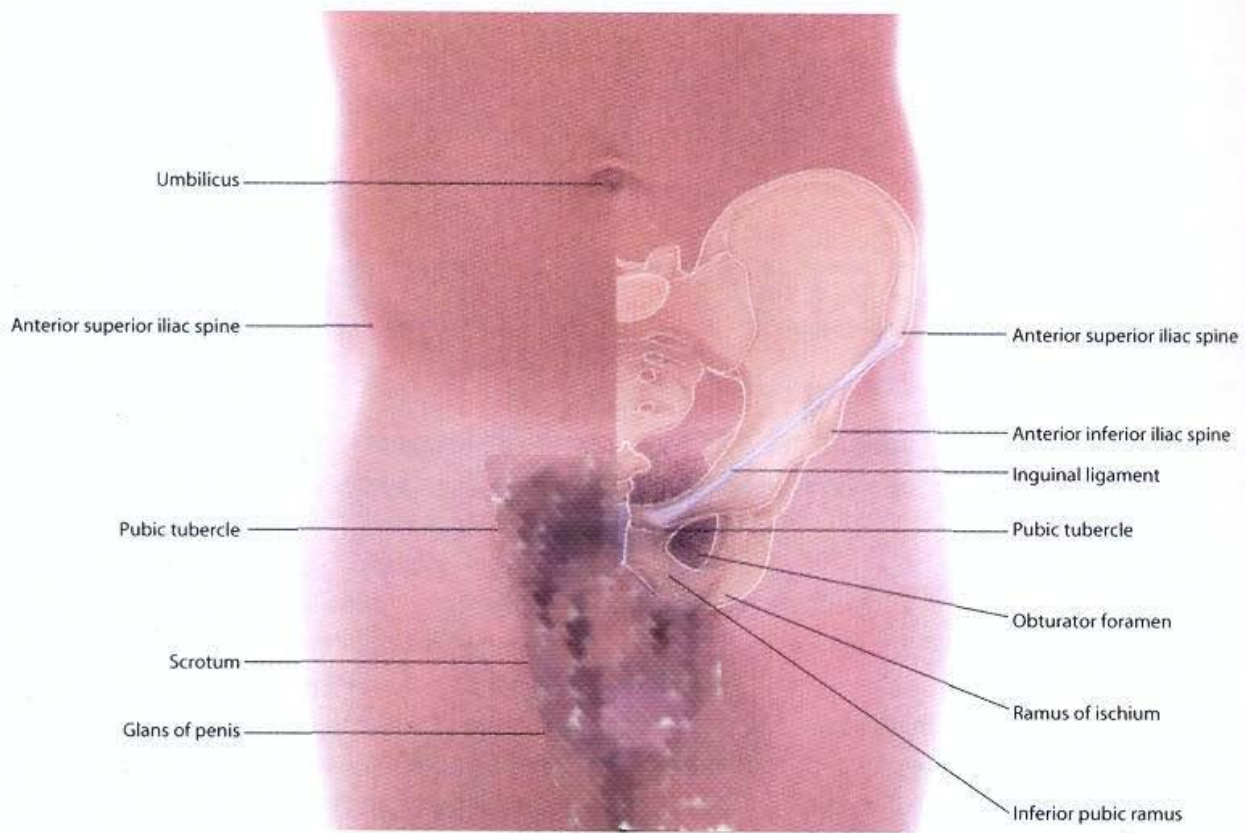
# 5

## PELVIS AND PERINEUM

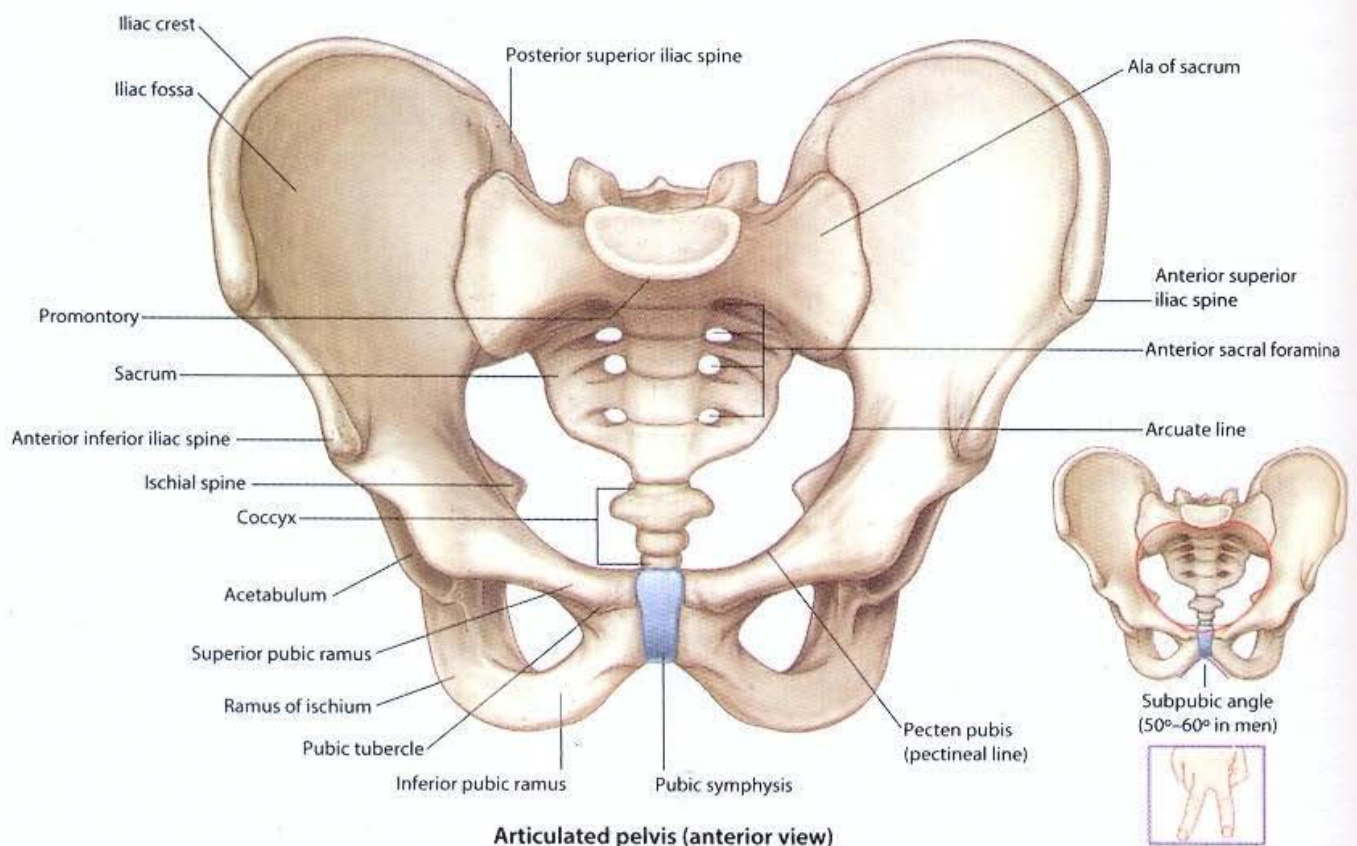
### CONTENTS

<i>Surface anatomy and articulated pelvis in men</i>	198	<i>Venous drainage of rectum</i>	237
<i>Surface anatomy and articulated pelvis in women</i>	200	<i>Sacral and coccygeal nerve plexuses</i>	238
<i>Pelvic girdle</i>	202	<i>Pelvic nerve plexus</i>	239
<i>Pelvic girdle: imaging</i>	203	<i>Hypogastric plexus</i>	240
<i>Lumbosacral joint</i>	204	<i>Surface anatomy of the perineum</i>	241
<i>Sacro-iliac joint</i>	205	<i>Borders and ceiling of the perineum</i>	244
<i>Pelvic inlet and outlet</i>	206	<i>Deep pouch and perineal membrane</i>	245
<i>Orientation of pelvic girdle and pelvic brim</i>	207	<i>Muscles and erectile tissues in men</i>	246
<i>Pelvic viscera and perineum in men</i>	208	<i>Erectile tissue in men: imaging</i>	247
<i>Pelvic viscera and perineum in men: imaging</i>	209	<i>Muscles and erectile tissues in women</i>	248
<i>Pelvic viscera and perineum in women</i>	210	<i>Erectile tissue in women: imaging</i>	249
<i>Pelvic viscera and perineum in women: imaging</i>	211	<i>Internal pudendal artery and vein</i>	250
<i>Lateral wall of pelvic cavity</i>	212	<i>Pudendal nerve</i>	251
<i>Floor of pelvic cavity: pelvic diaphragm</i>	213	<i>Vasculature of perineum</i>	252
<i>Rectum and bladder in situ</i>	216	<i>Nerves of perineum</i>	253
<i>Rectum</i>	217	<i>Lymphatics of pelvis and perineum in men</i>	254
<i>Bladder in men</i>	218	<i>Lymphatics of pelvis and perineum in women</i>	255
<i>Bladder in women</i>	219	<i>Lymphatics</i>	256
<i>Reproductive system in men</i>	220	<i>Dermatomes</i>	257
<i>Prostate</i>	221	<i>Innervation of reproductive system in men</i>	258
<i>Prostate and seminal vesicles</i>	223	<i>Innervation of reproductive system in women</i>	259
<i>Scrotum</i>	224	<i>Innervation of bladder</i>	260
<i>Testes</i>	225	<i>Pelvic cavity imaging in men</i>	261
<i>Penis</i>	226	<i>Pelvic cavity imaging in women</i>	264
<i>Reproductive system in women</i>	227		
<i>Uterus and ovaries</i>	228		
<i>Uterus</i>	229		
<i>Uterus: imaging</i>	230		
<i>Pelvic fascia</i>	231		
<i>Arterial supply of pelvis</i>	232		
<i>Venous drainage of pelvis</i>	233		
<i>Vasculature of the pelvic viscera</i>	234		
<i>Vasculature of uterus</i>	235		
<i>Venous drainage of prostate and penis</i>	236		

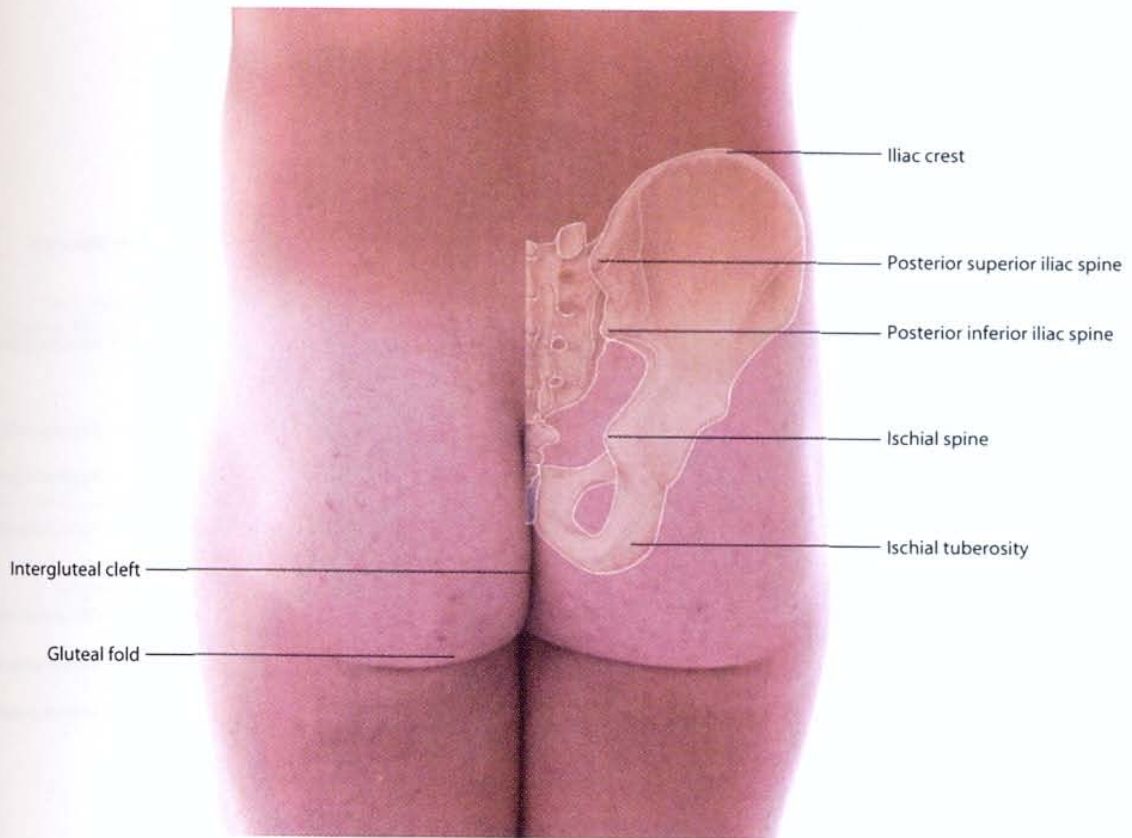




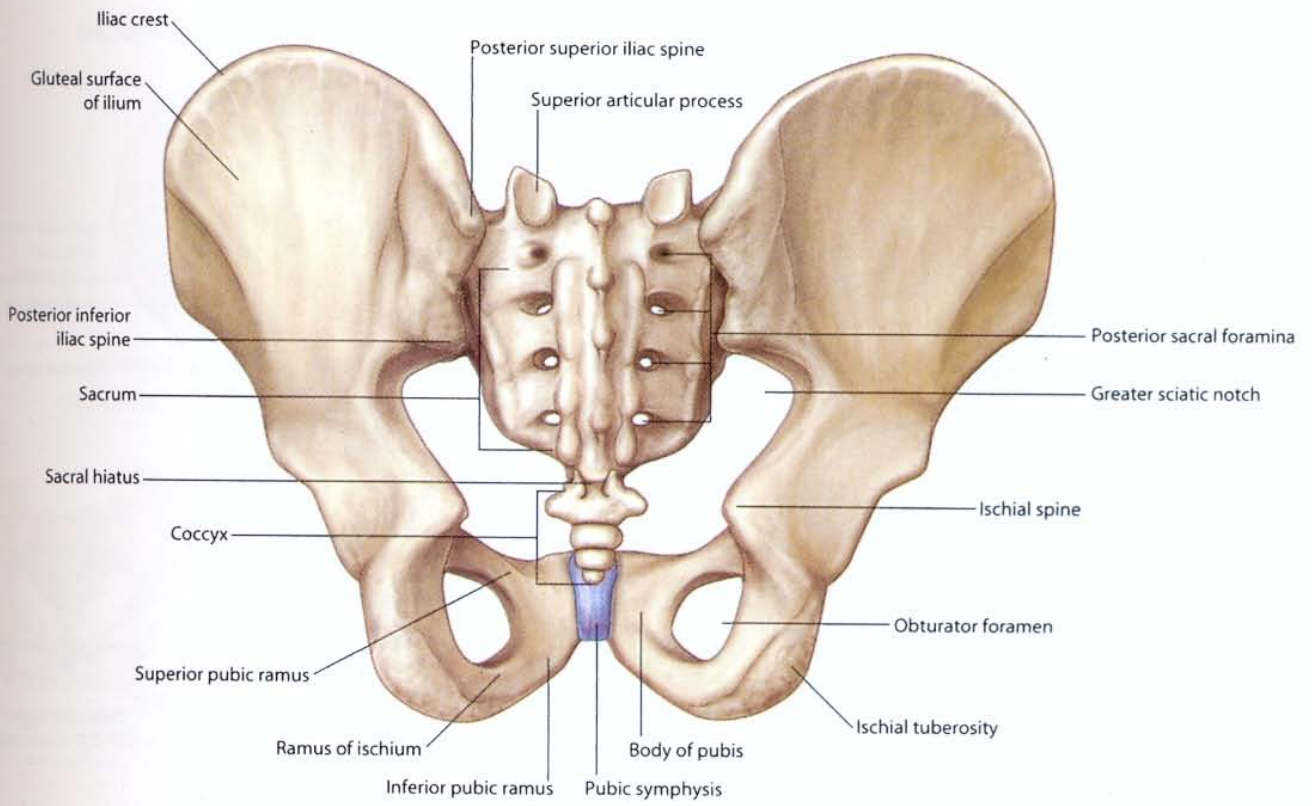
**Surface anatomy with bones (anterior view)**



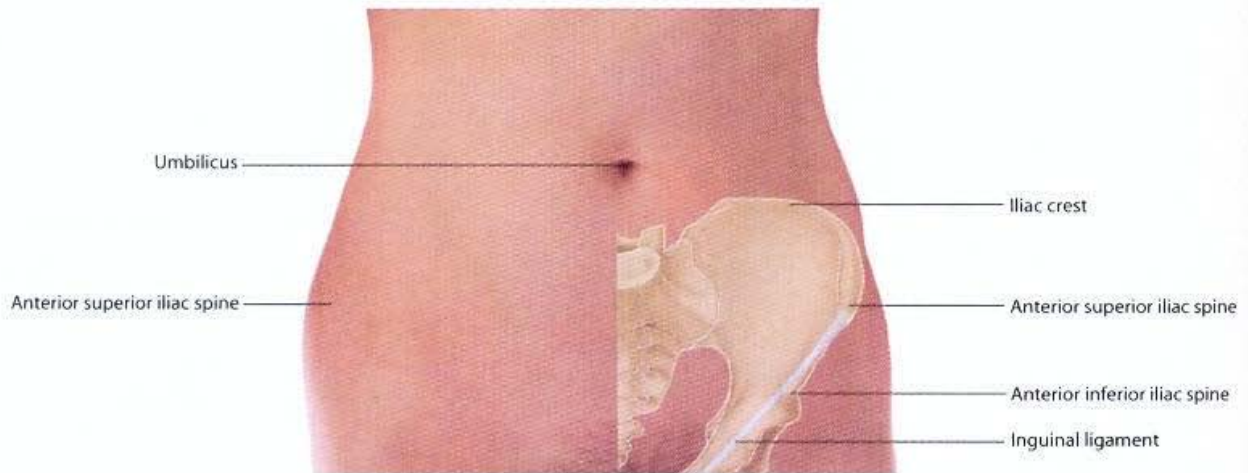
**Articulated pelvis (anterior view)**



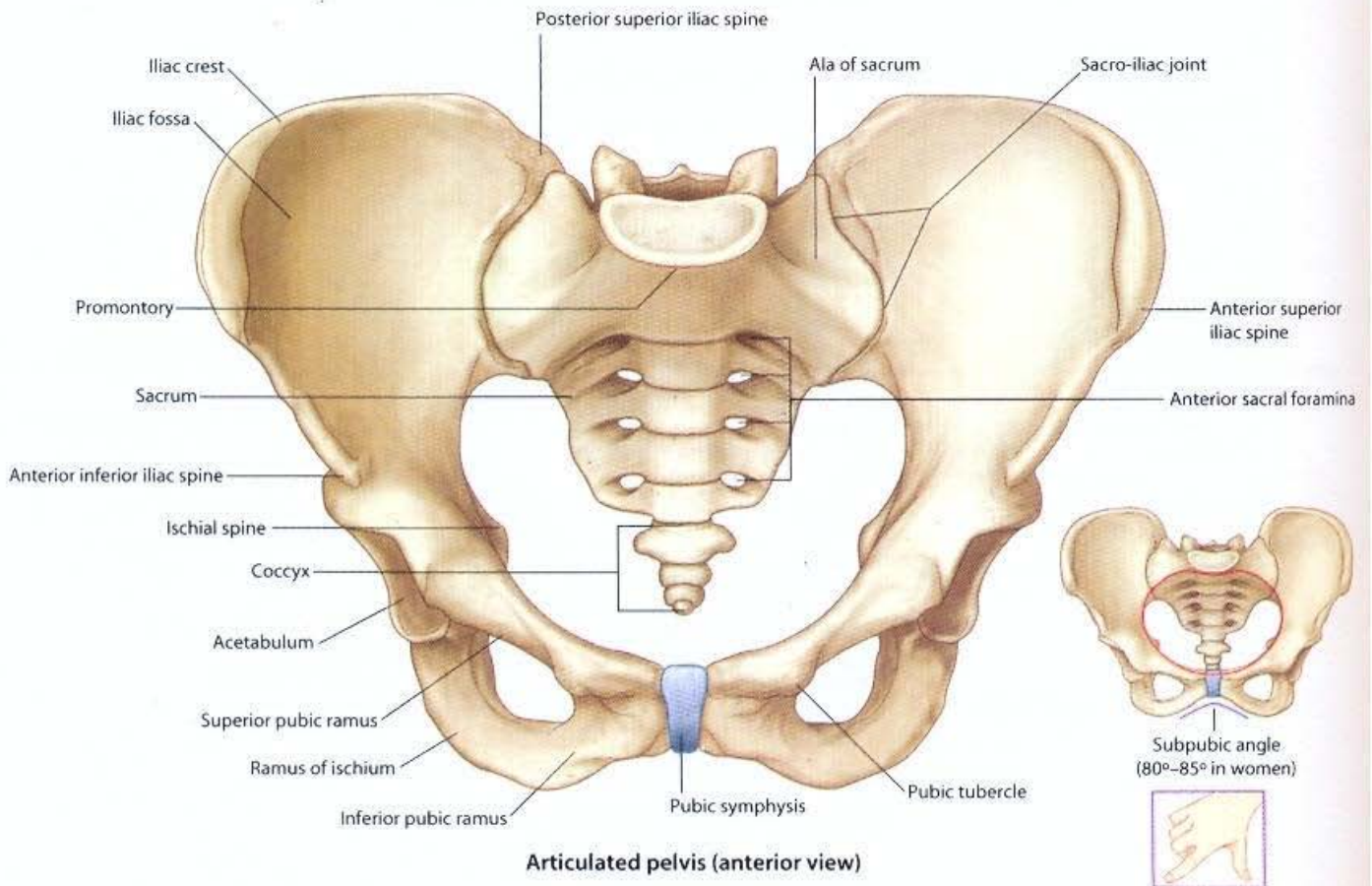
Surface anatomy with bones (posterior view)



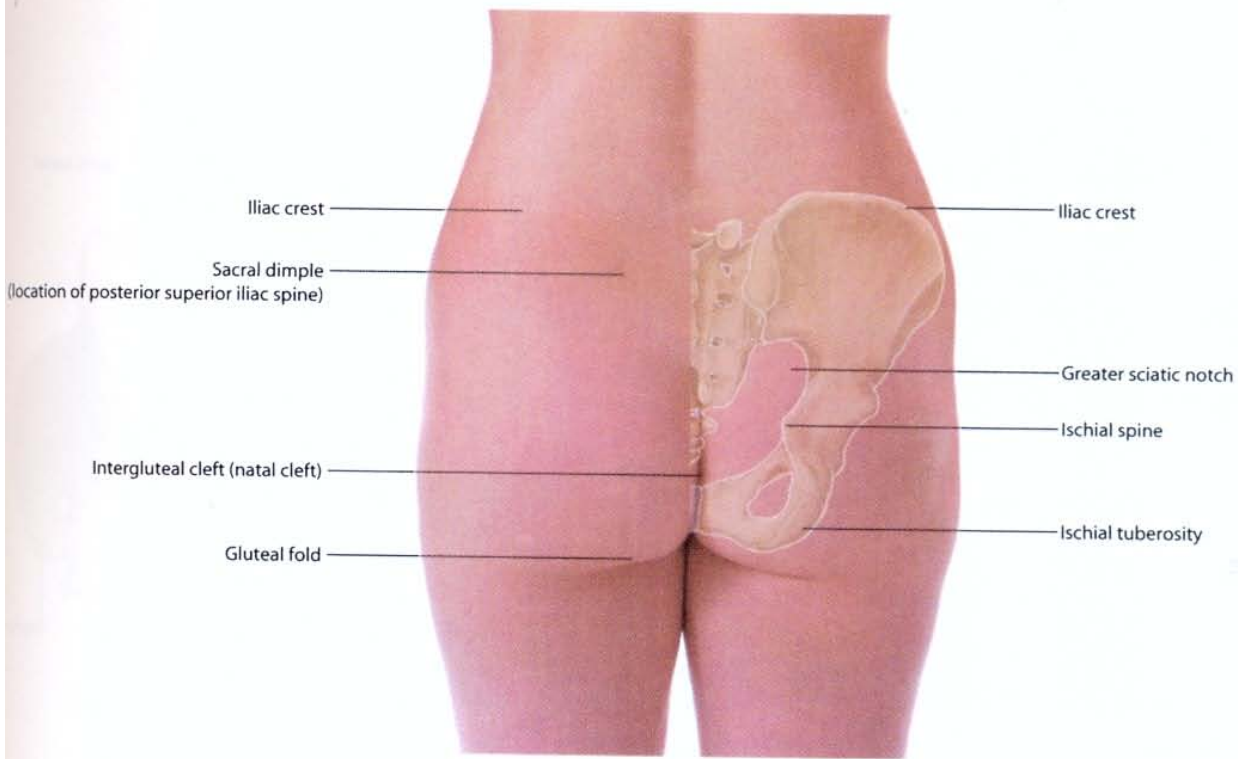
Articulated pelvis (posterior view)



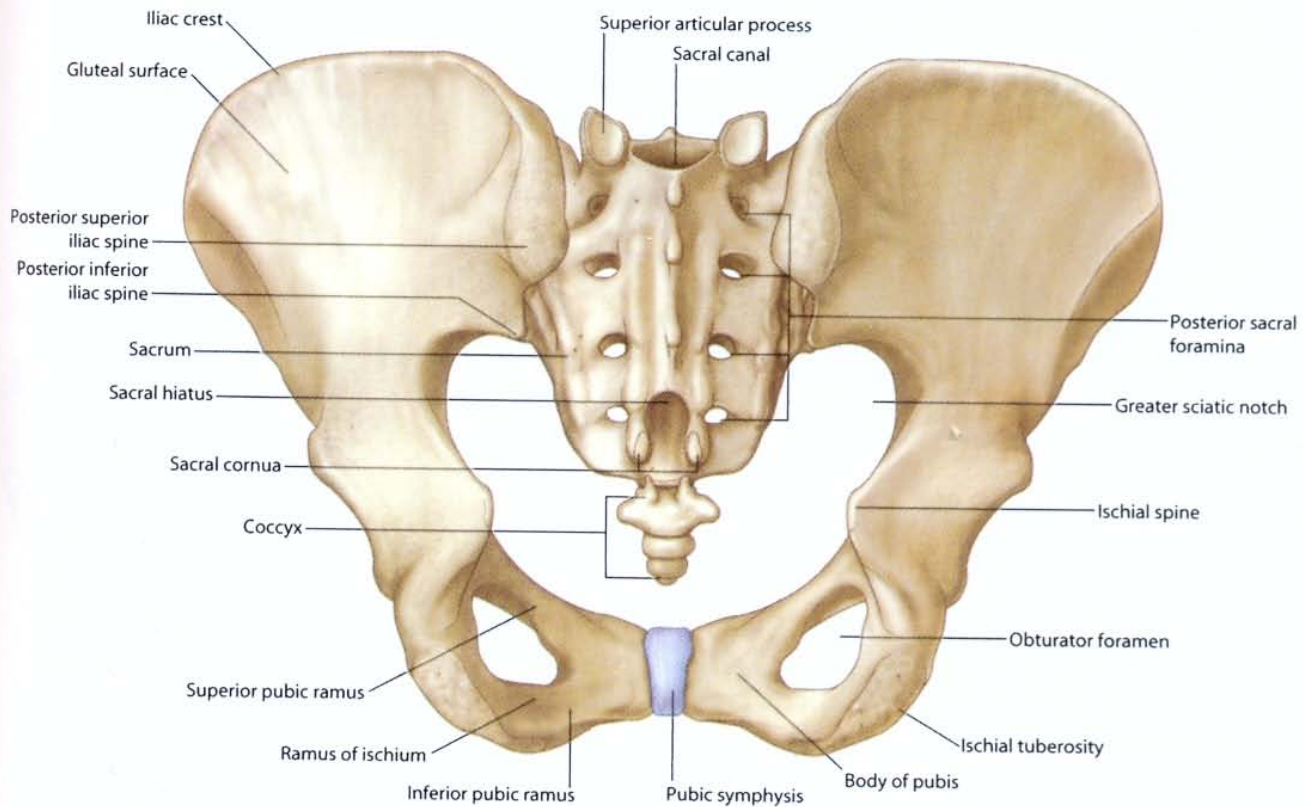
**Surface anatomy with bones (anterior view)**



**Articulated pelvis (anterior view)**

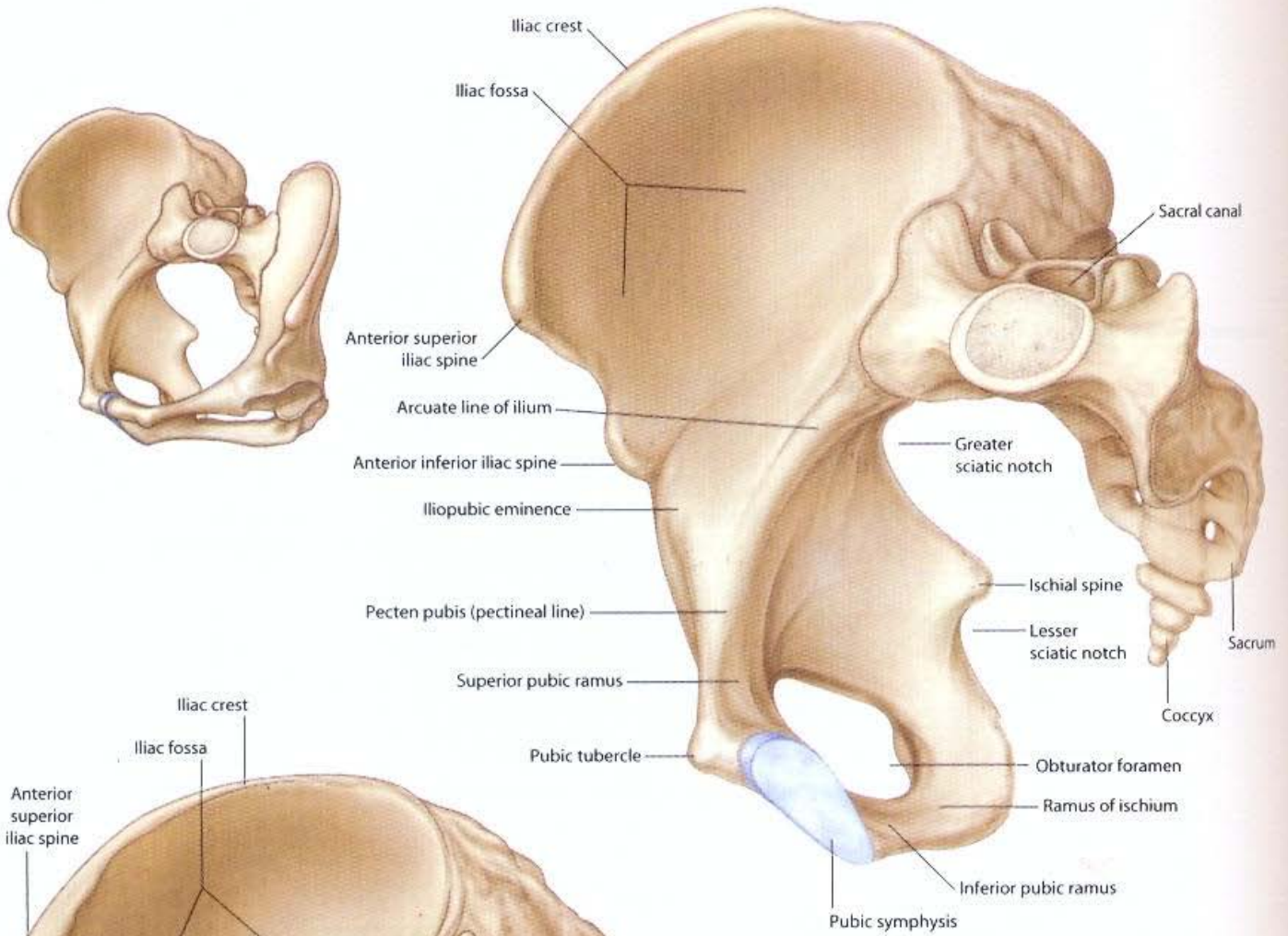


Surface anatomy with bones (posterior view)

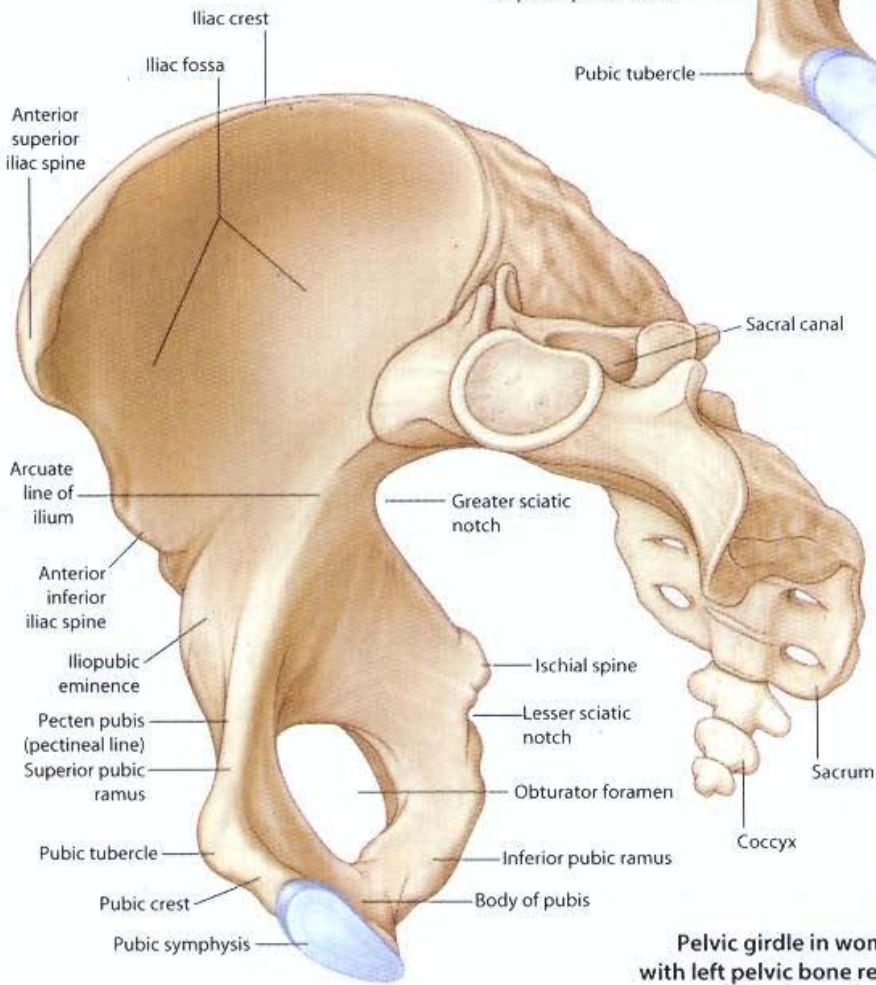


Articulated pelvis (posterior view)

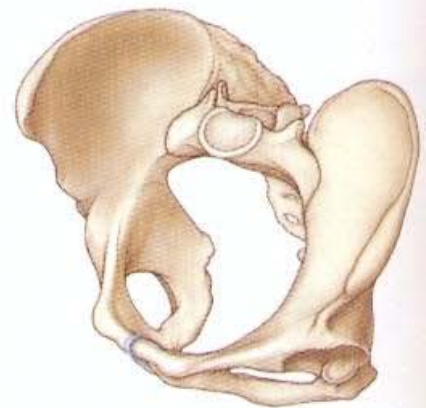
# PELVIS AND PERINEUM • Pelvic girdle

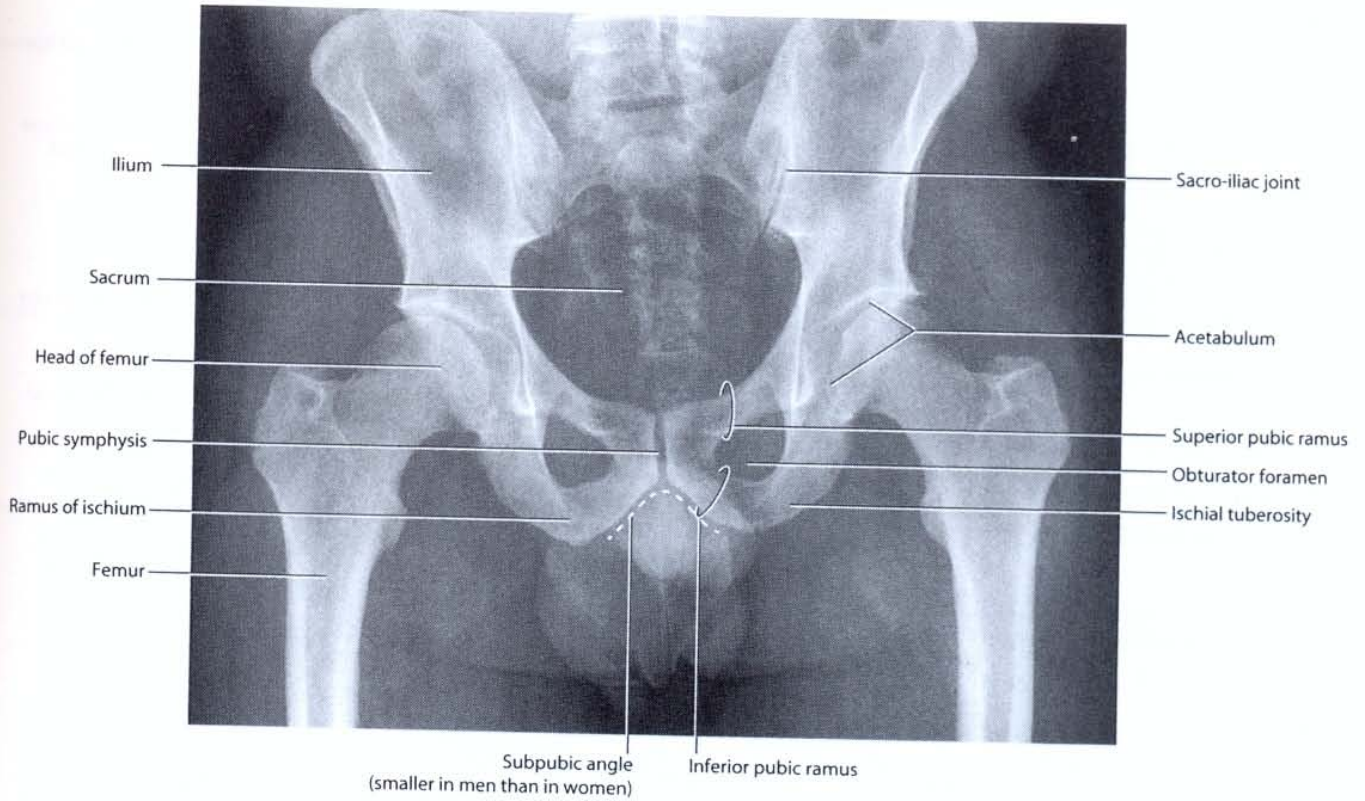


**Pelvic girdle in men  
with left pelvic bone removed  
(anterolateral superior view)**

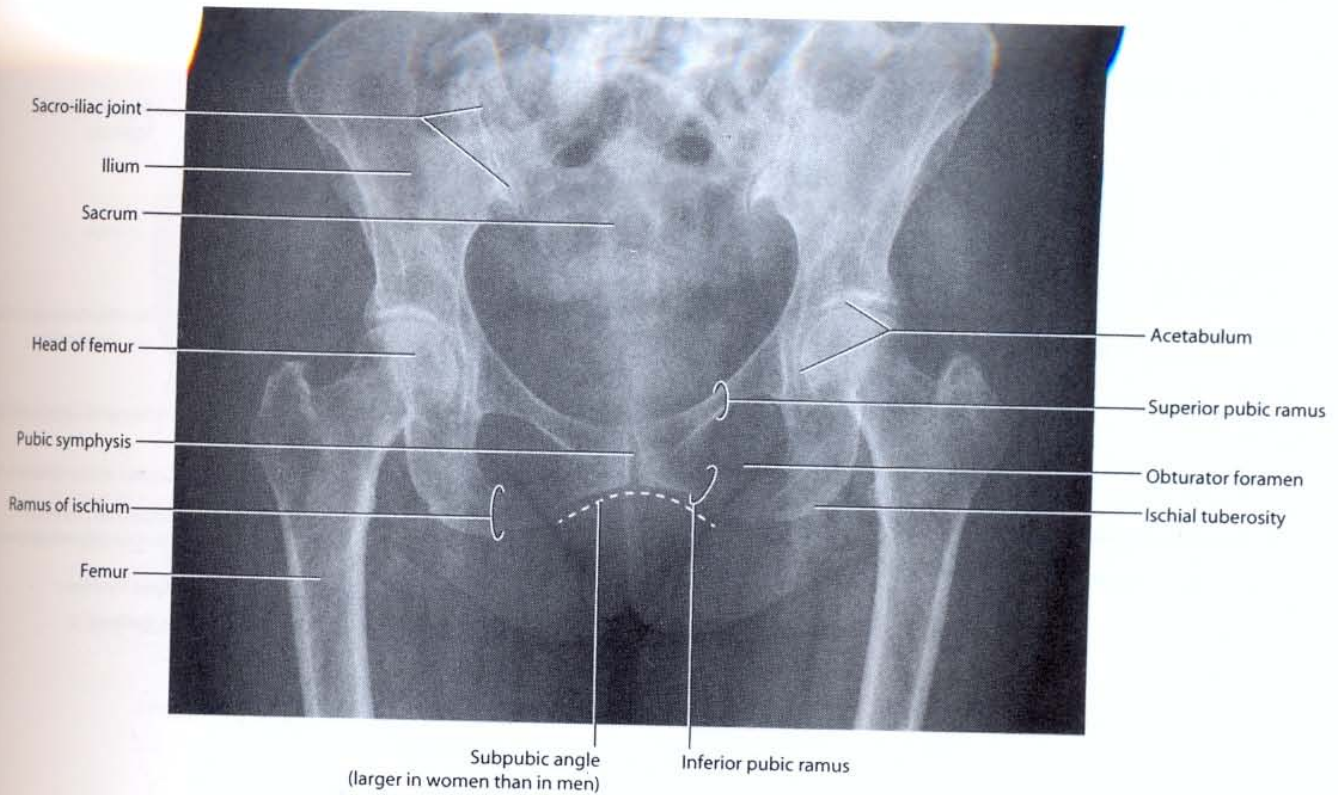


**Pelvic girdle in women  
with left pelvic bone removed  
(anterolateral superior view)**

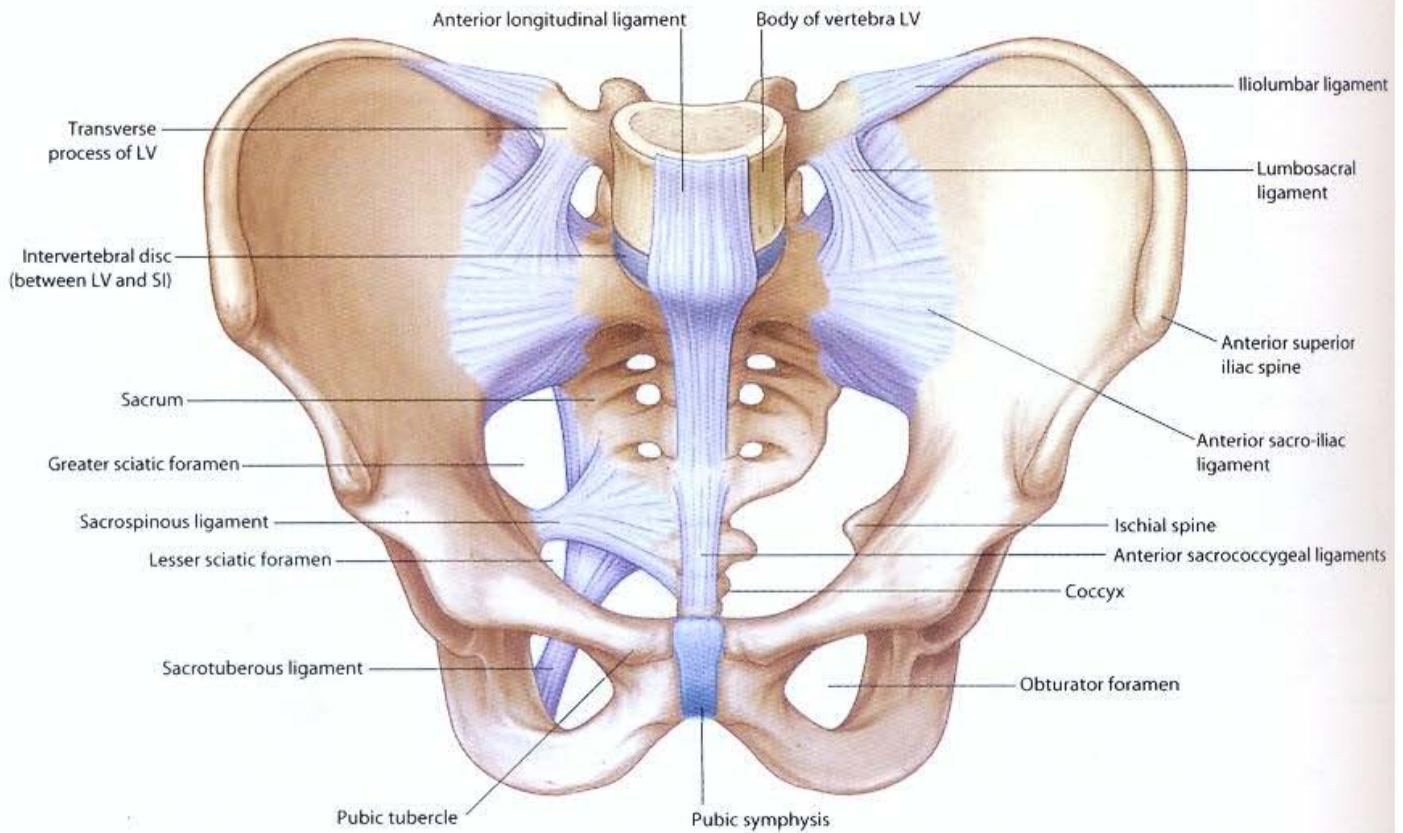




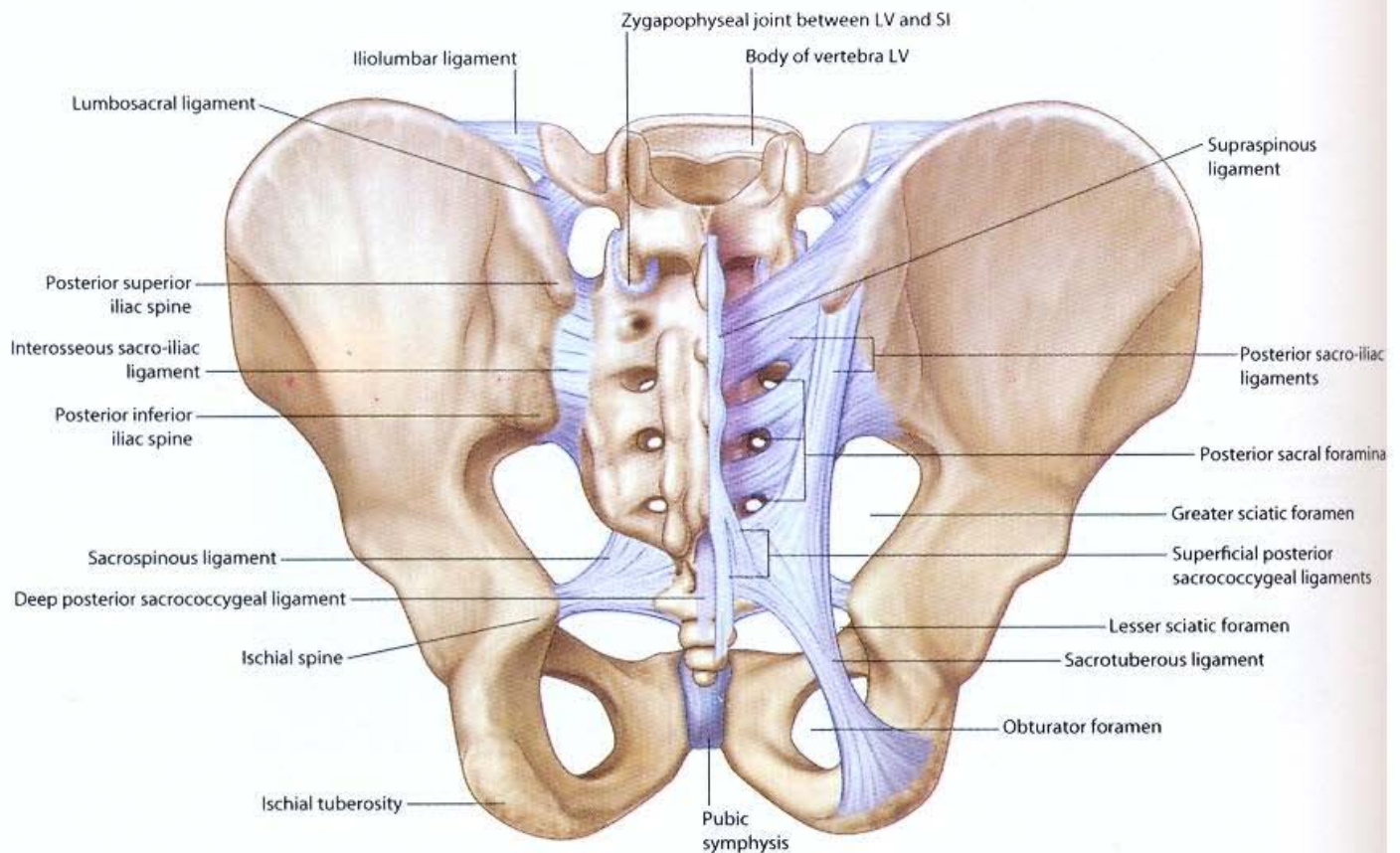
**Male bony pelvis.**  
Radiograph, anterior-posterior view



**Female bony pelvis.**  
Radiograph, anterior-posterior view

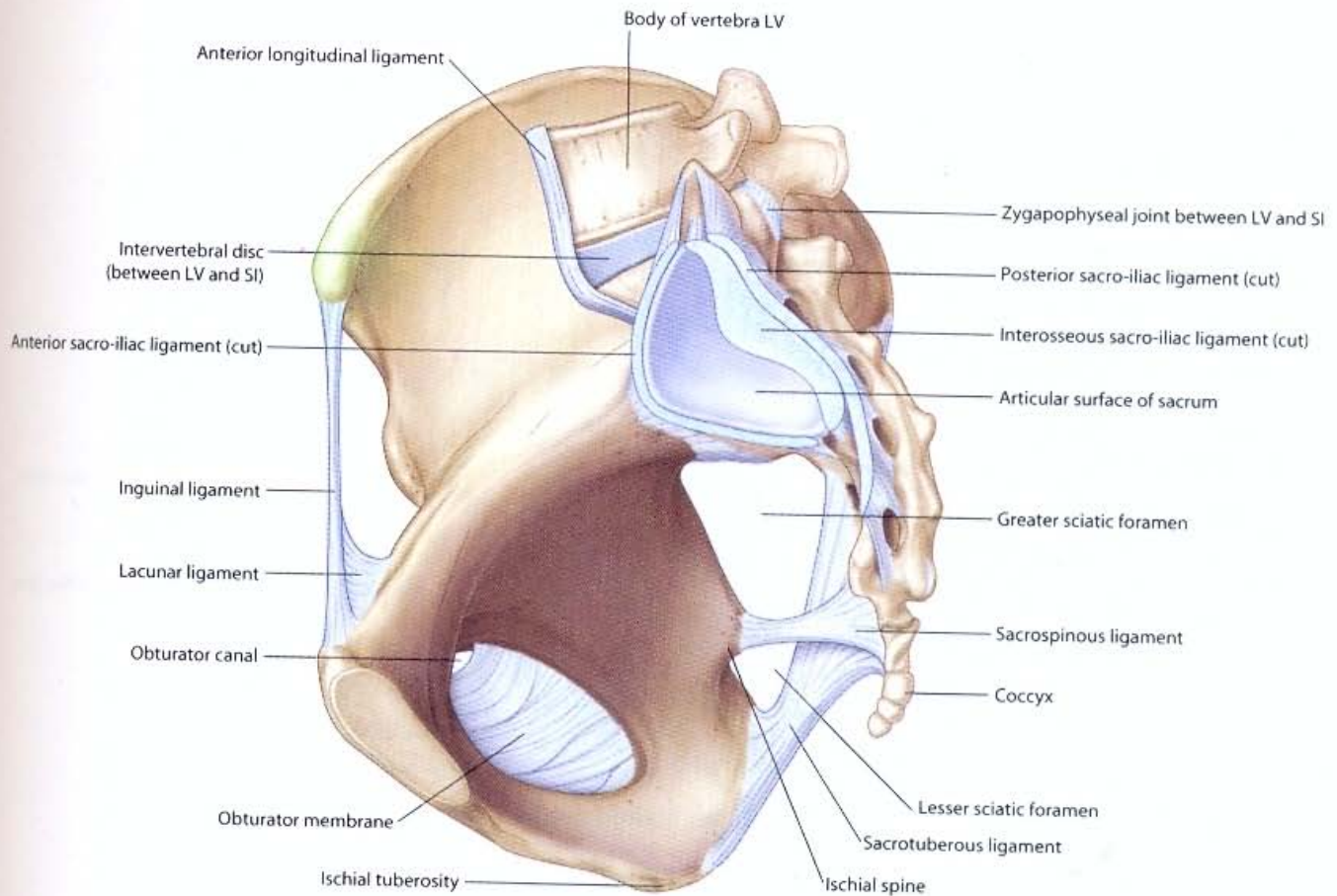


**Lumbosacral joints and associated ligaments (anterior view)**

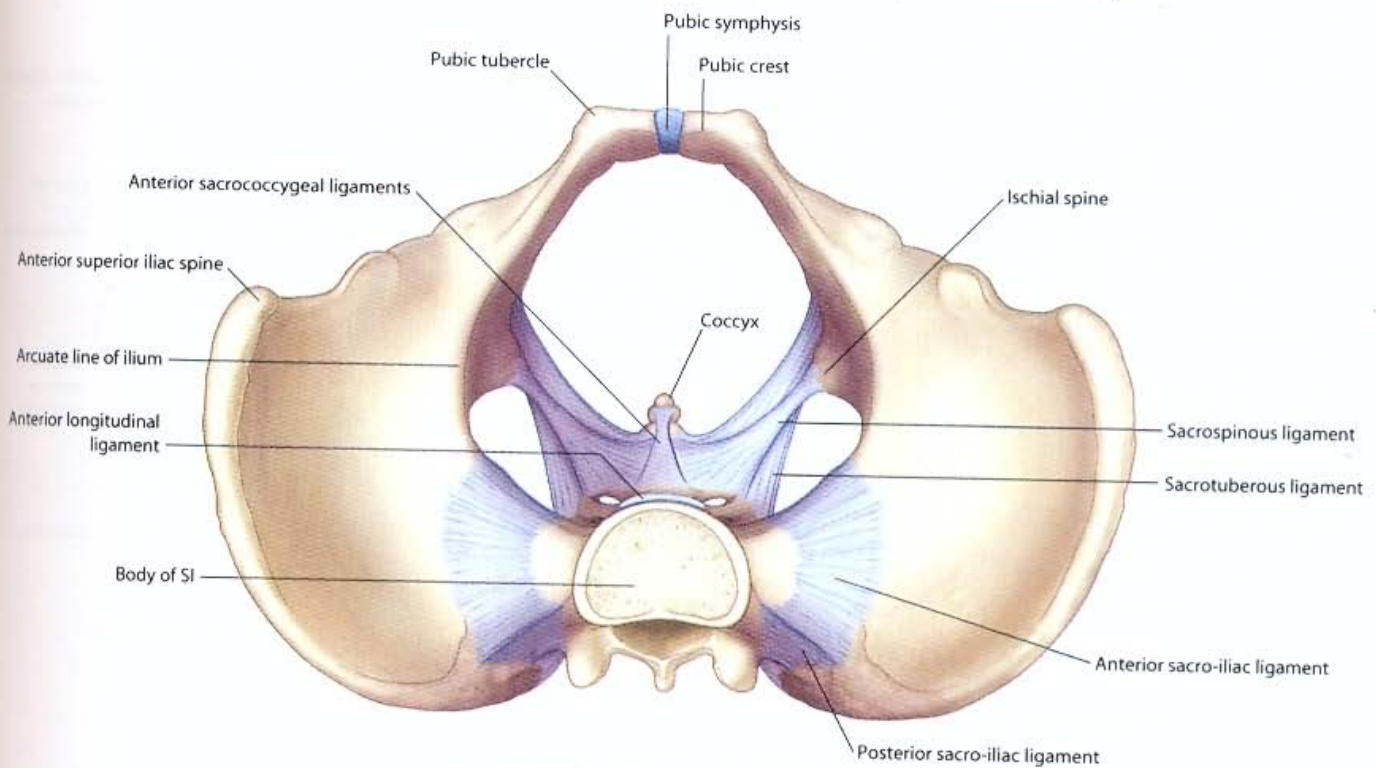


**Lumbosacral joints and associated ligaments (posterior view)**



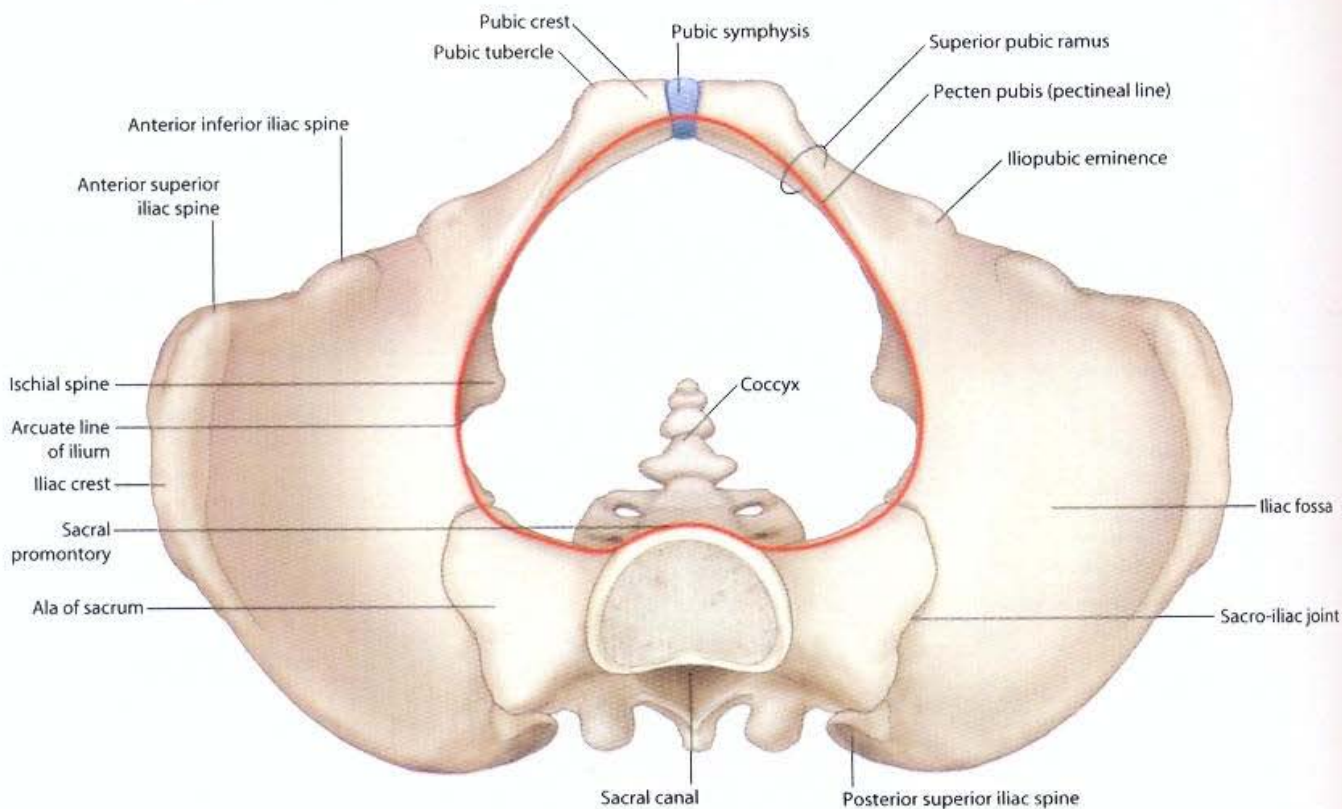


Sacro-iliac joints and associated ligaments (lateral view with left pelvic bone removed)

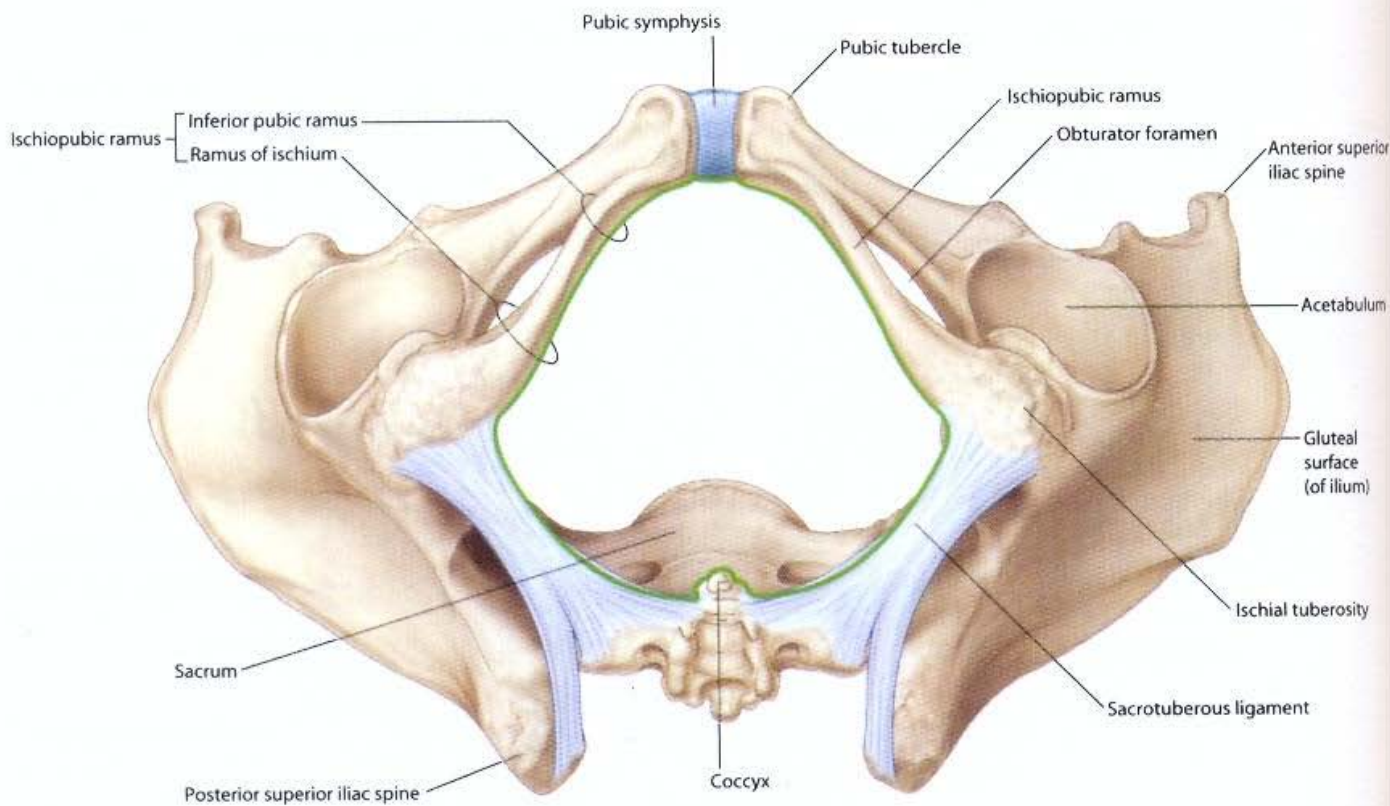


Sacro-iliac joints (anterosuperior view)

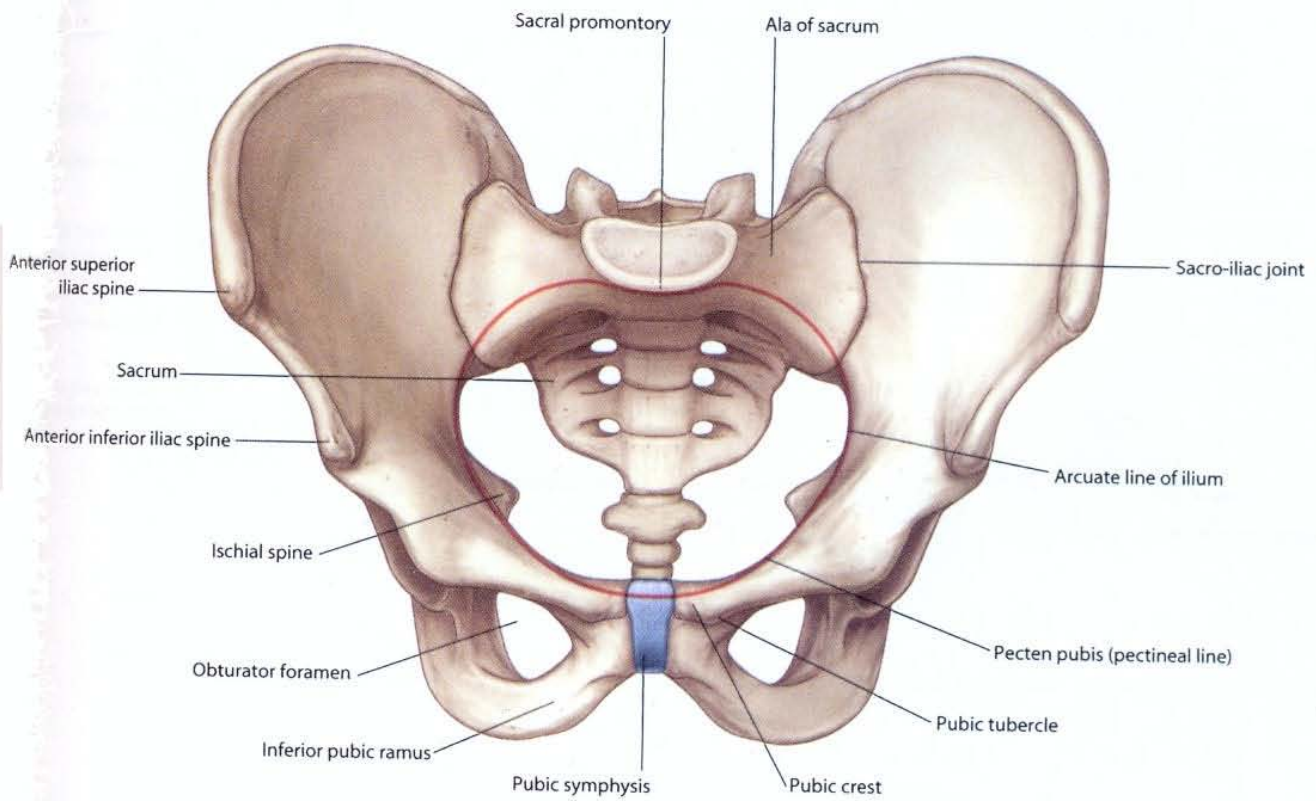
# PELVIS AND PERINEUM • Pelvic inlet and outlet



Pelvic inlet (shown in red; anterosuperior view)

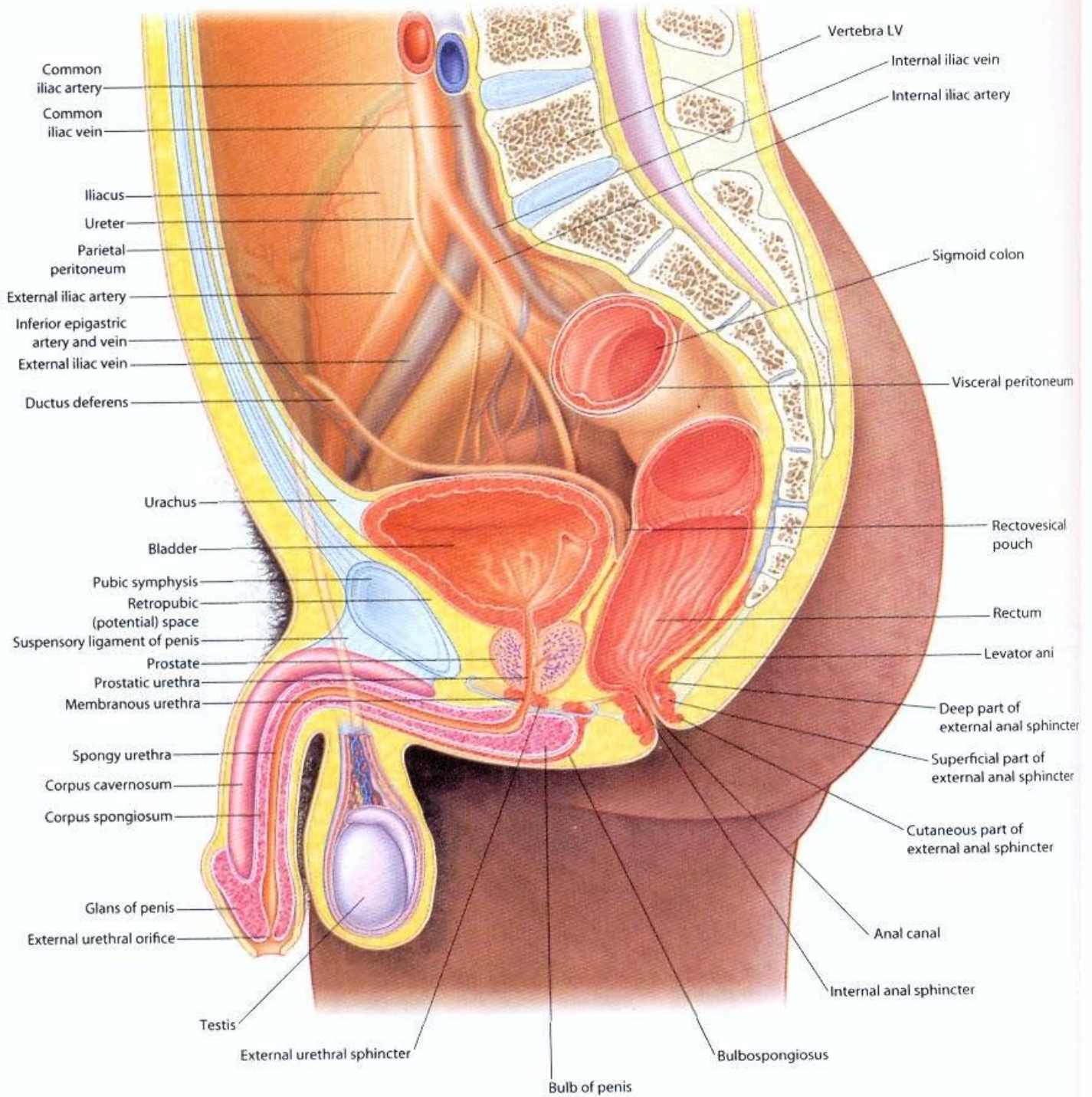


Pelvic outlet (shown in green; anteroinferior view)

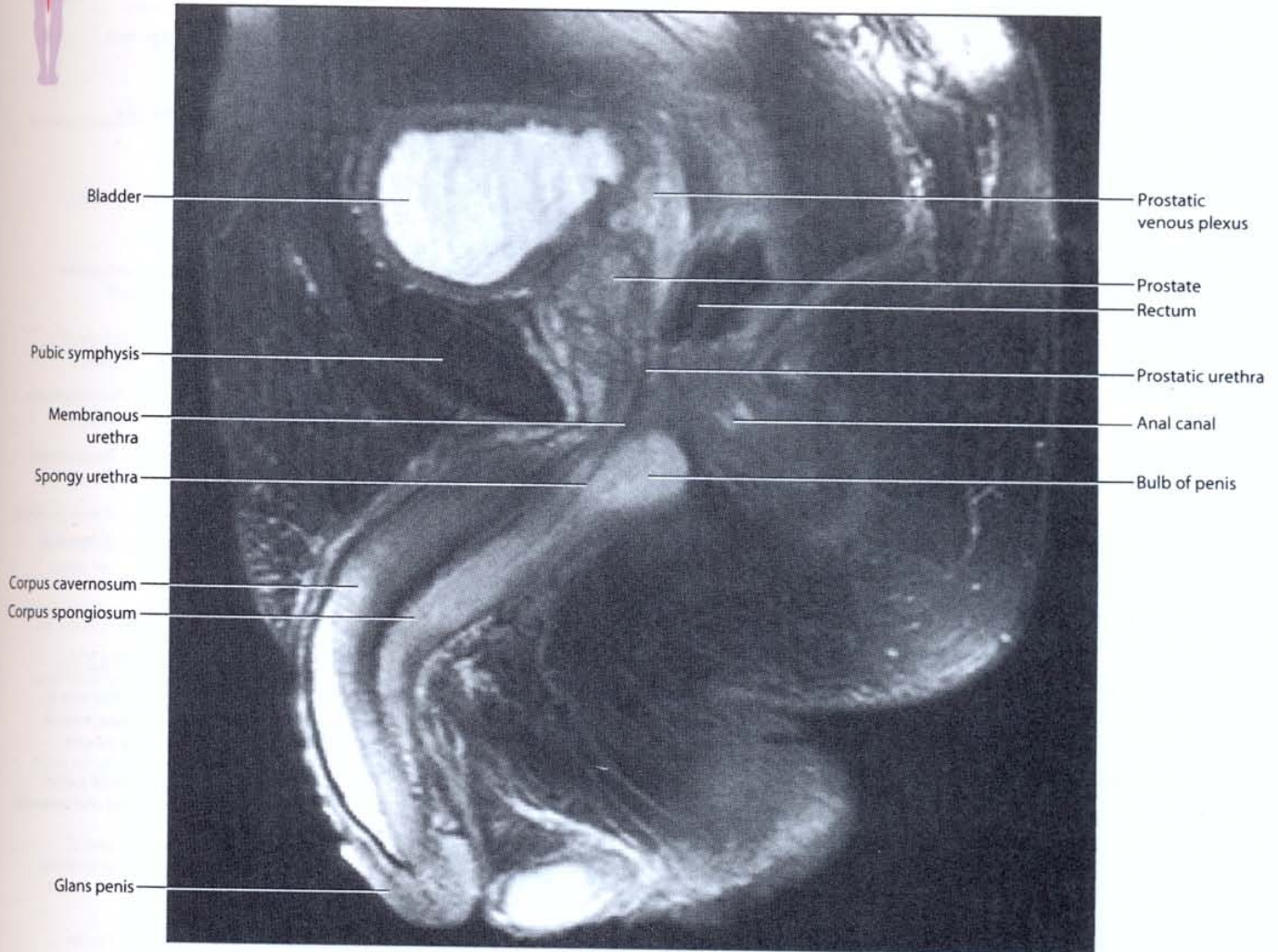
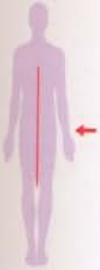

Pelvic brim (shown in red; anterior view)

# PELVIS AND PERINEUM • Pelvic viscera and perineum in men

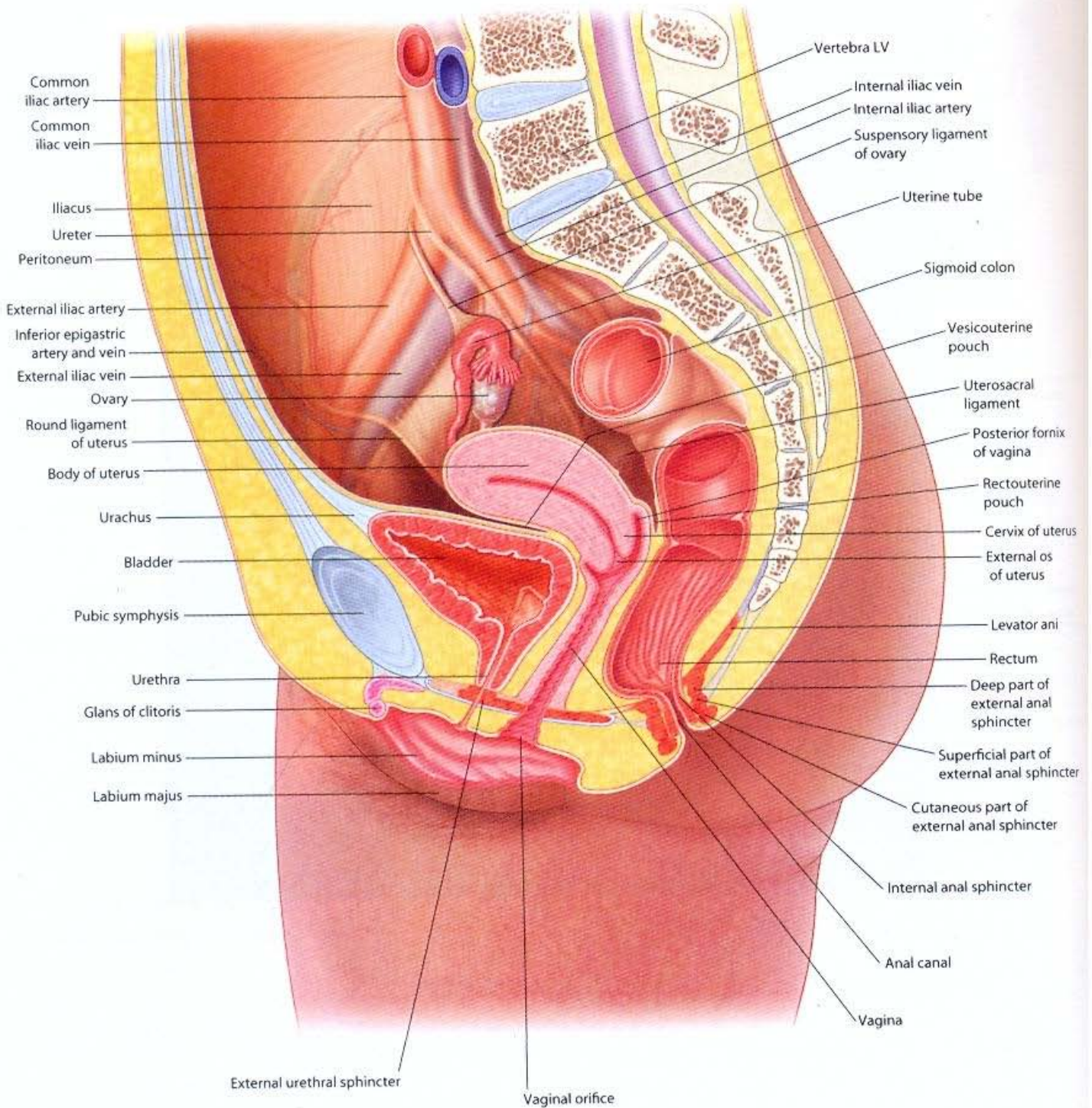


Pelvic viscera and perineum in men *in situ* (sagittal section)

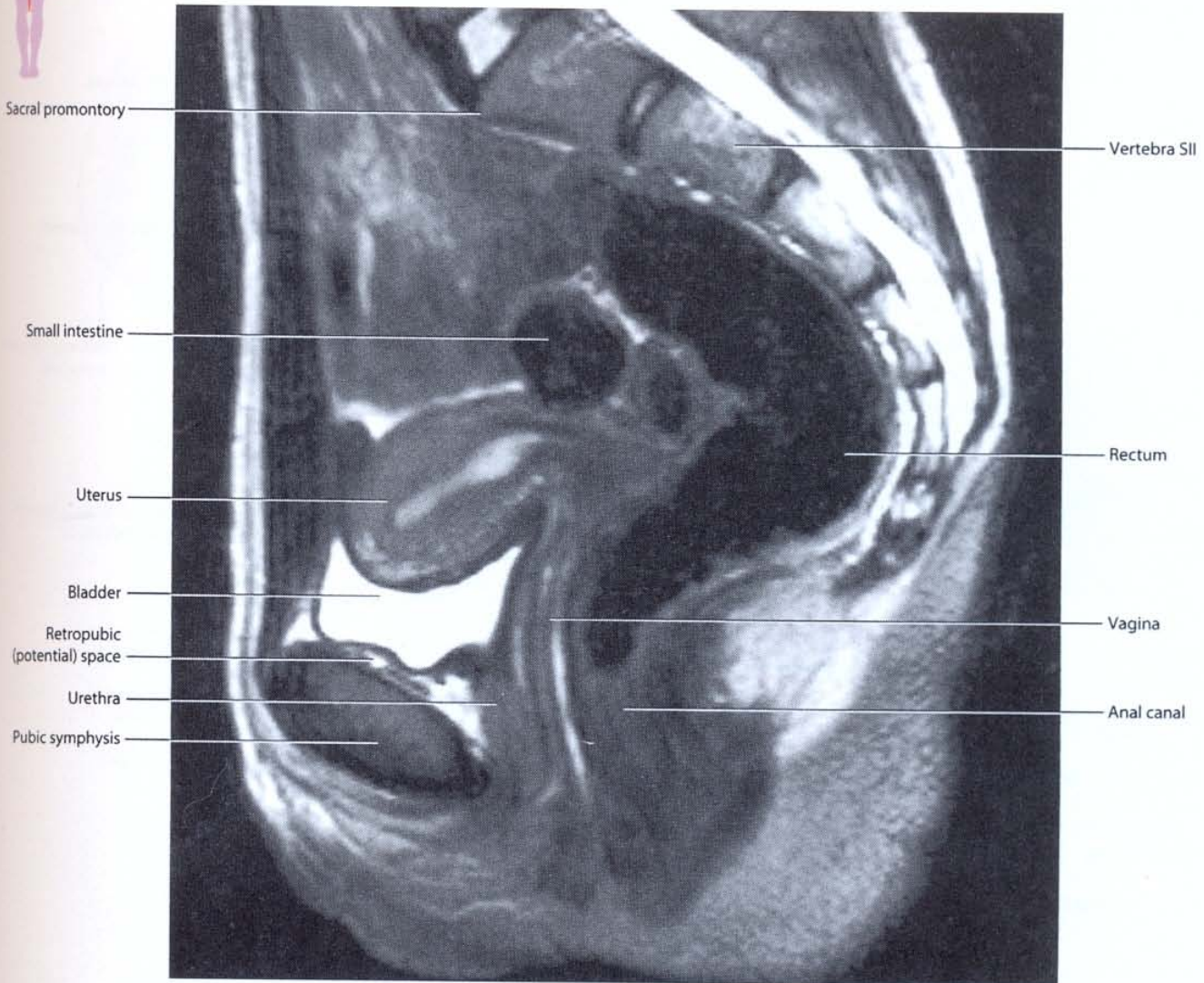
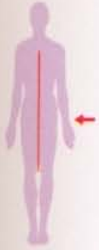

**Pelvic viscera in men.**  
T2-weighted MR image in sagittal plane

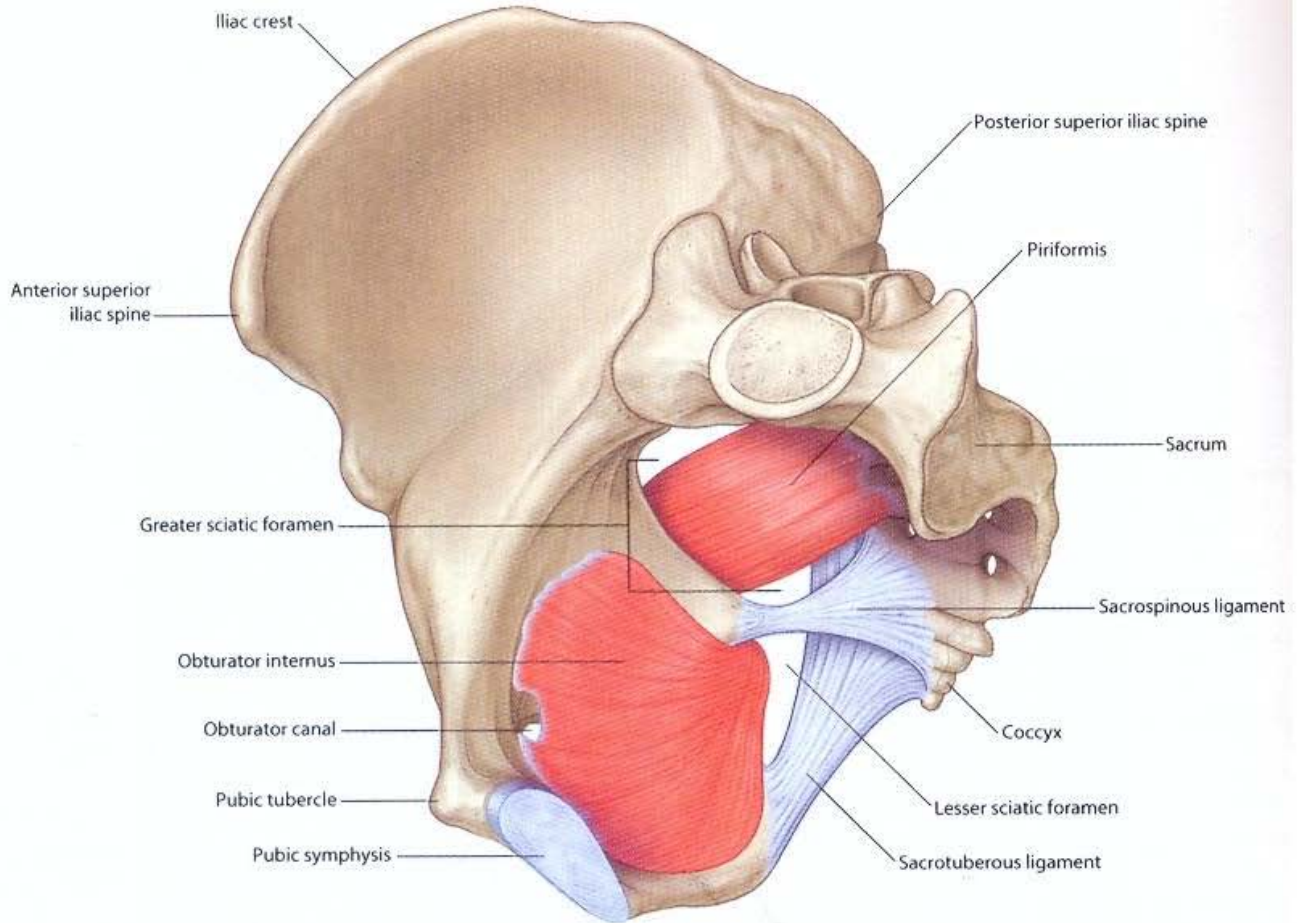
**PELVIS AND PERINEUM** • *Pelvic viscera and perineum in women*



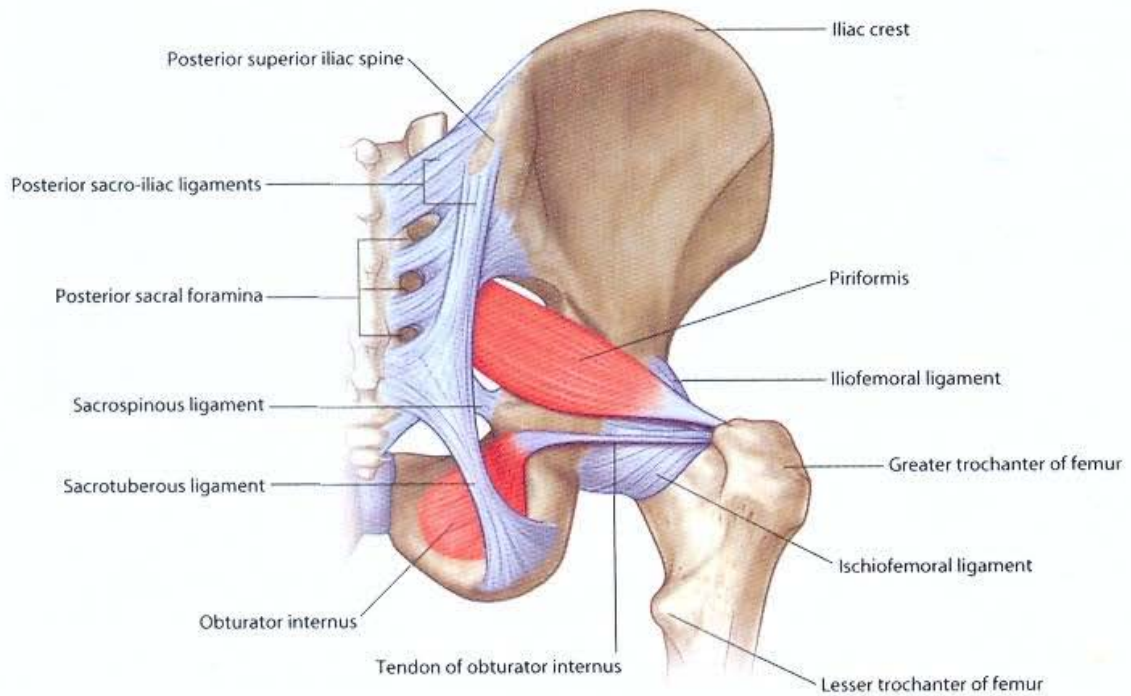
Pelvic viscera and perineum in women *in situ* (sagittal section)



**Pelvic viscera in women.**  
T2-weighted MR image in sagittal plane

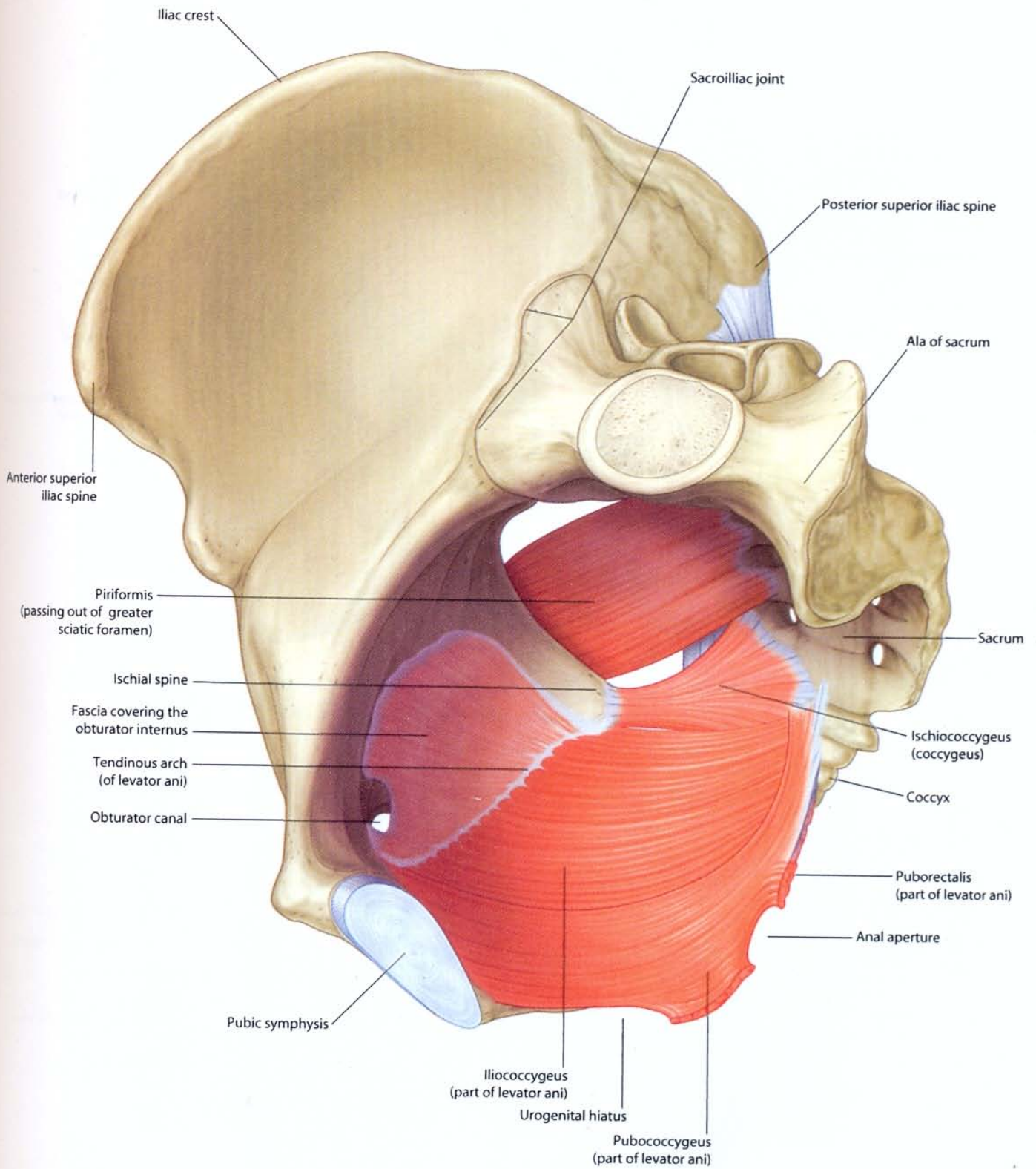


**Obturator internus and piriformis muscles (oblique medial view)**



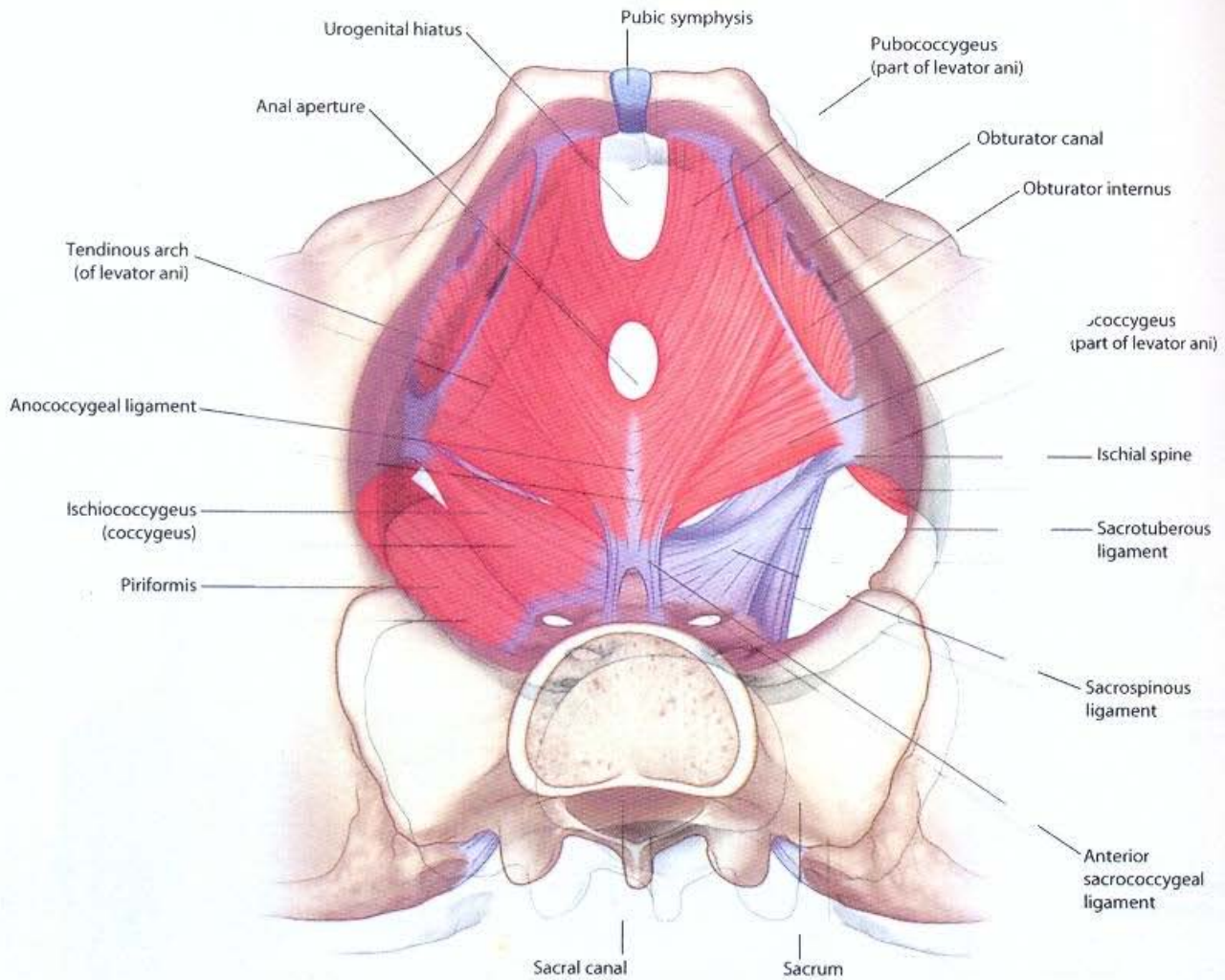
**Obturator internus and piriformis muscles (posterior view)**



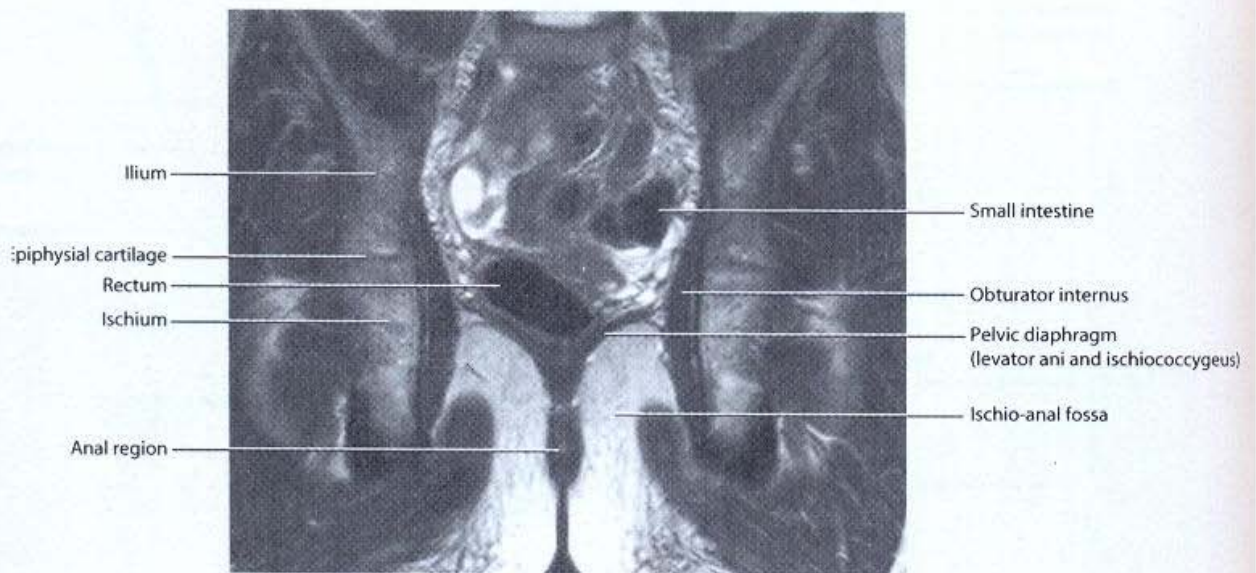


Levator ani and ischiococcygeus (coccygeus) muscles (oblique sagittal view)

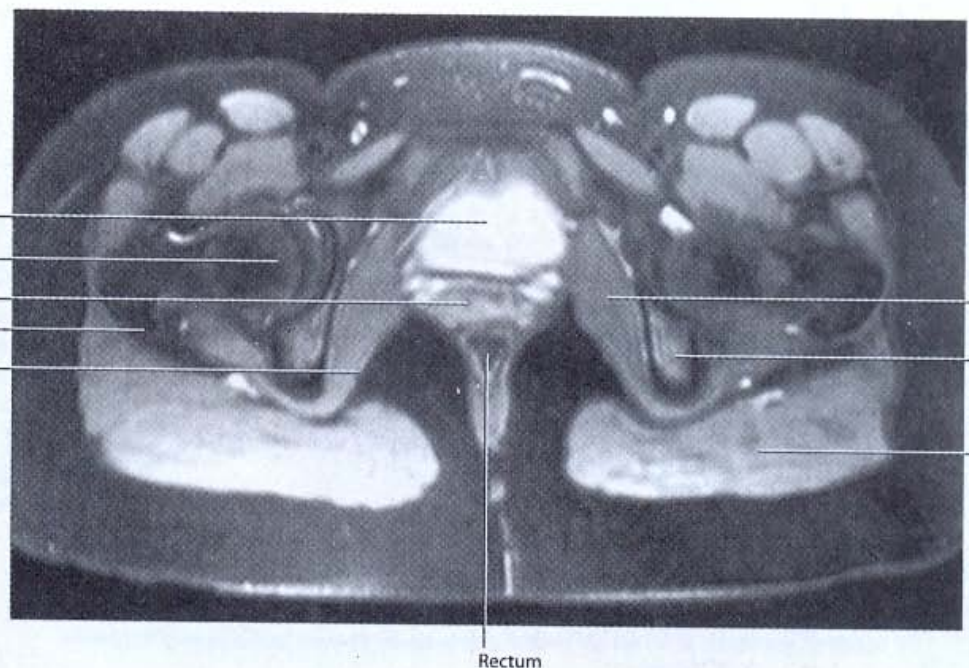
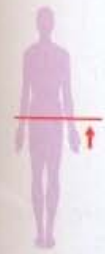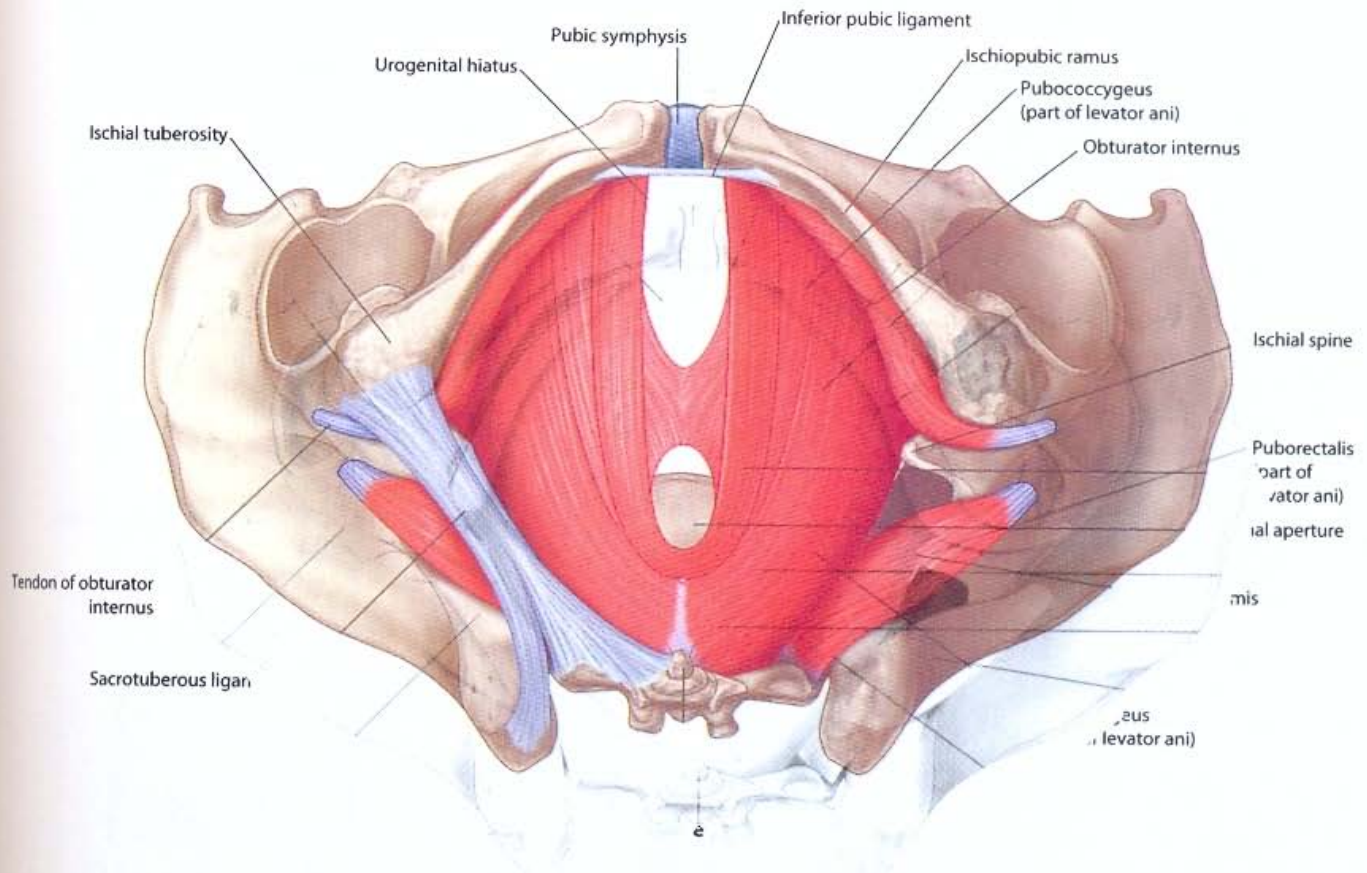
# PELVIS AND PERINEUM • Floor of pelvic cavity: pelvic diaphragm



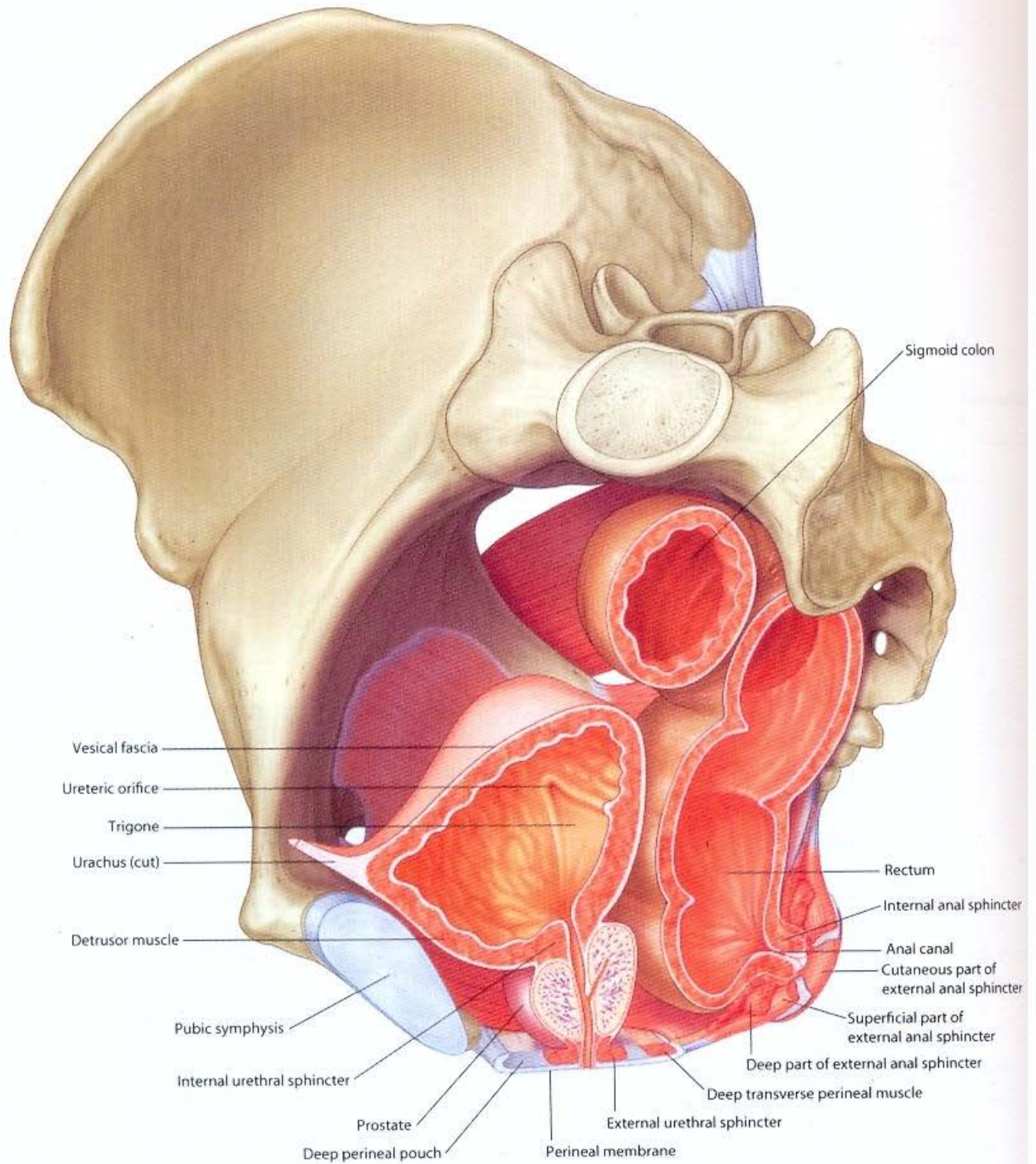
Levator ani and ischiococcygeus (coccygeus) muscles (anterosuperior view)



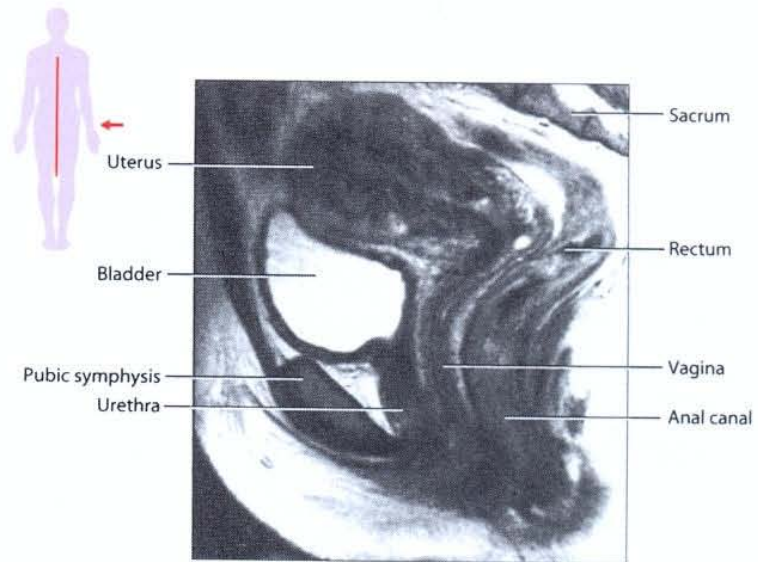
Pelvic diaphragm in relation to other structures in the pelvic cavity and perineum. T2-weighted MR image in coronal plane



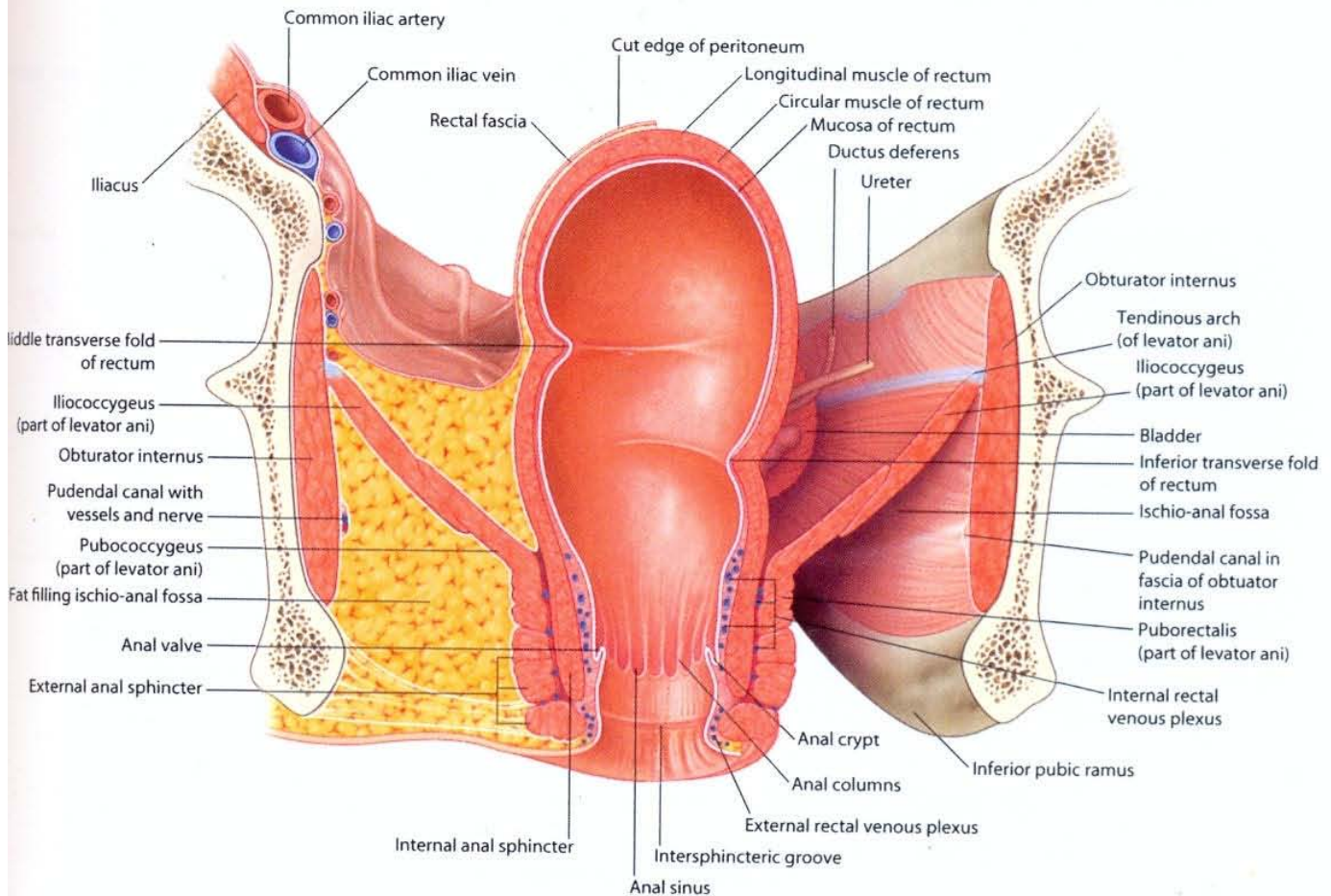
**Obturator internus muscle and its relationship to other pelvic structures.**  
T2-weighted MR image in axial plane



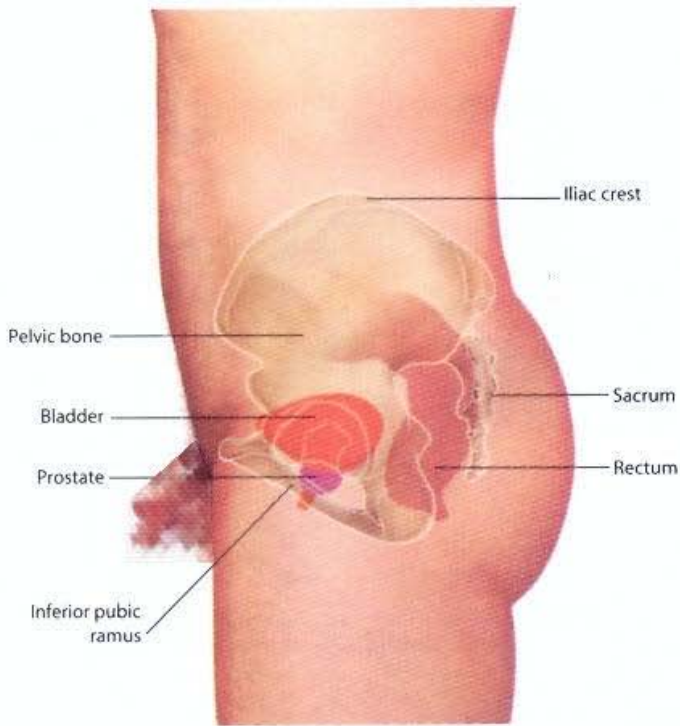
**Bladder, prostate, and rectum within pelvic cavity in men (oblique sagittal view)**



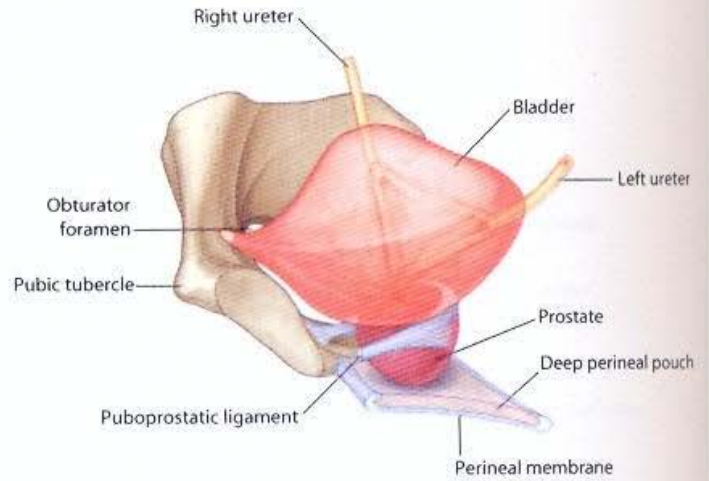
Positioning of the rectum and anal canal in relation to the other female pelvic viscera. T2-weighted MR image in sagittal plane



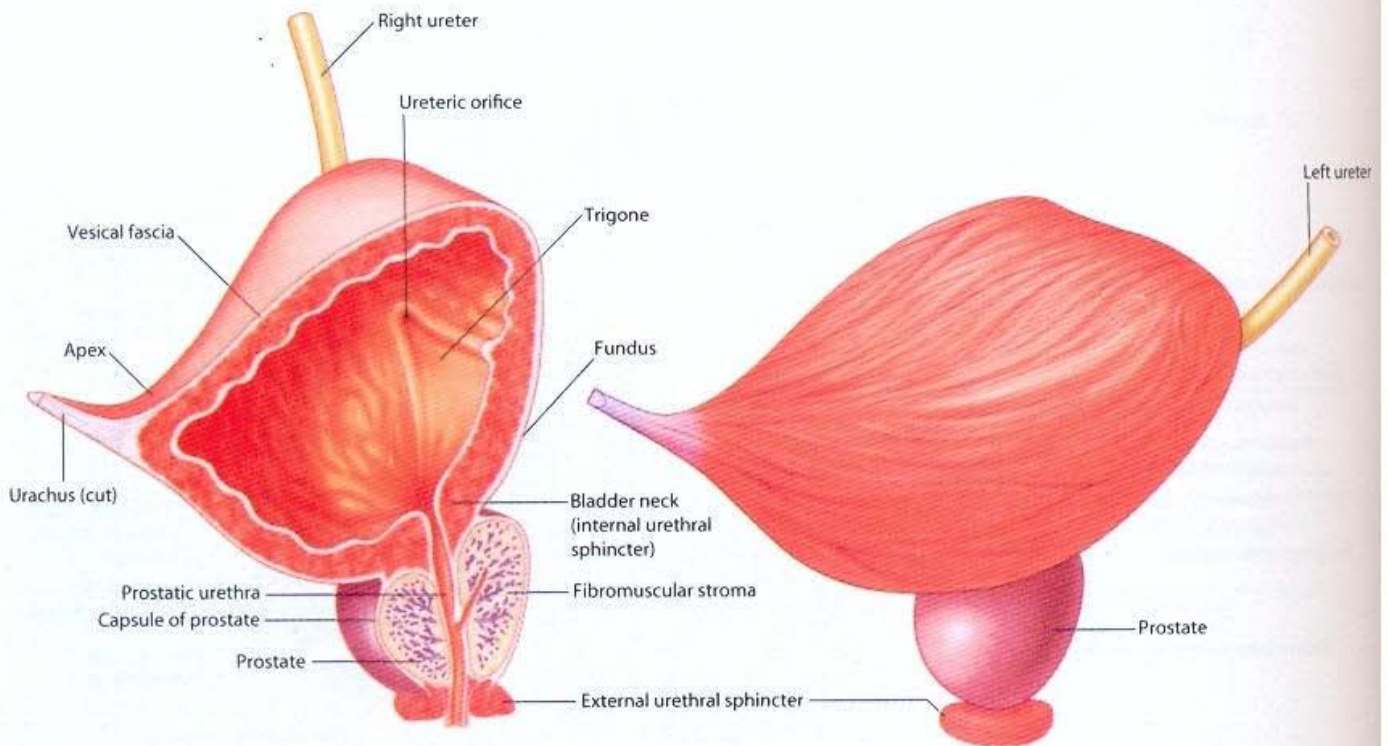
Coronal section through rectum and anal canal (posterior view)



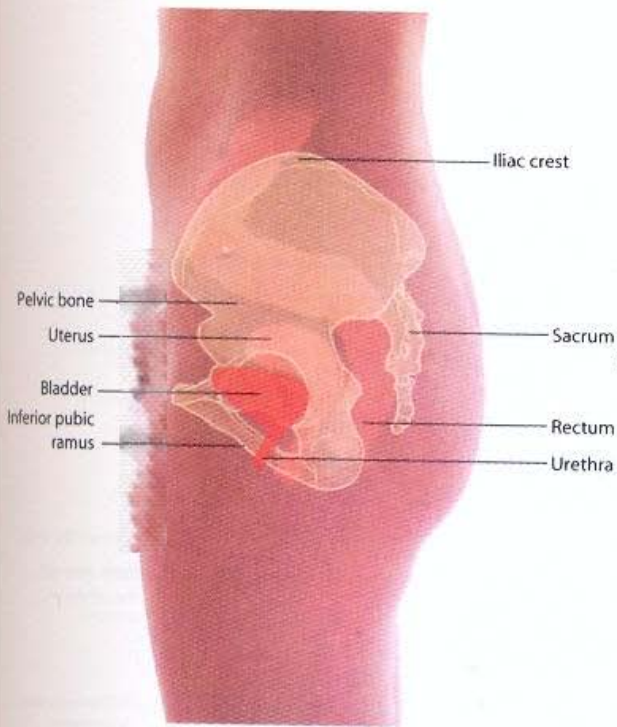
**Surface projection of the bladder in men (lateral view)**



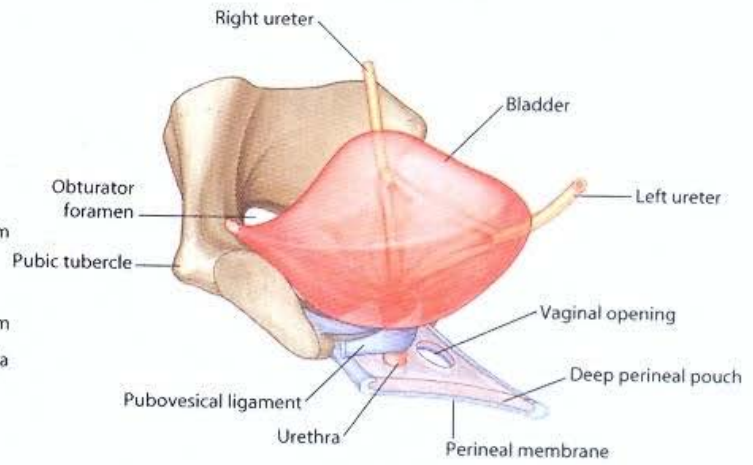
**Puboprostatic ligament**



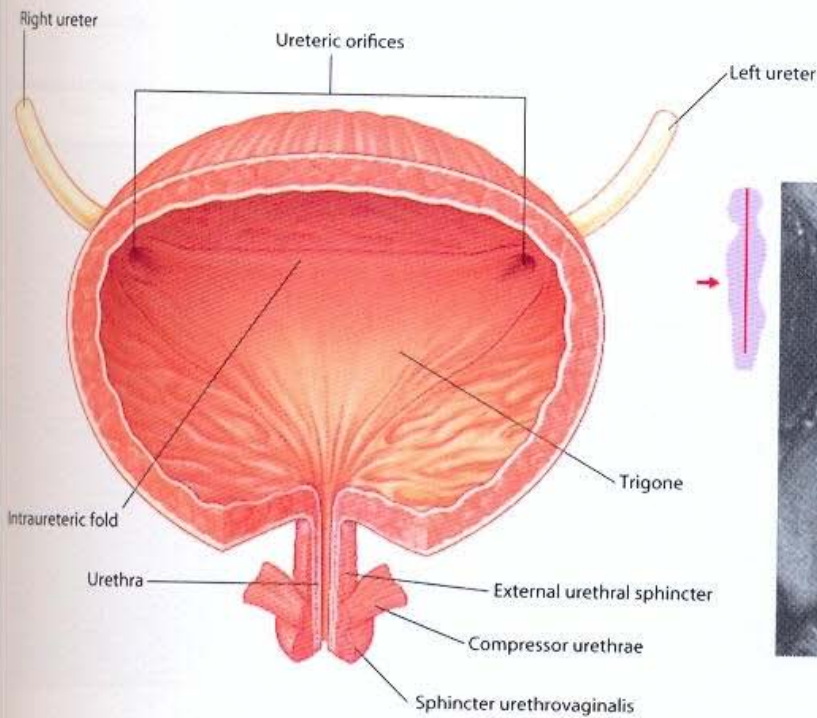
**Urinary bladder in men**



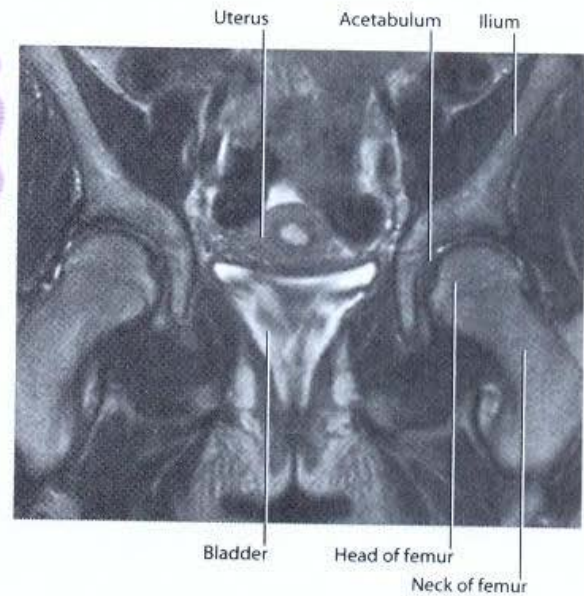
Surface projection of the bladder in women (lateral view)



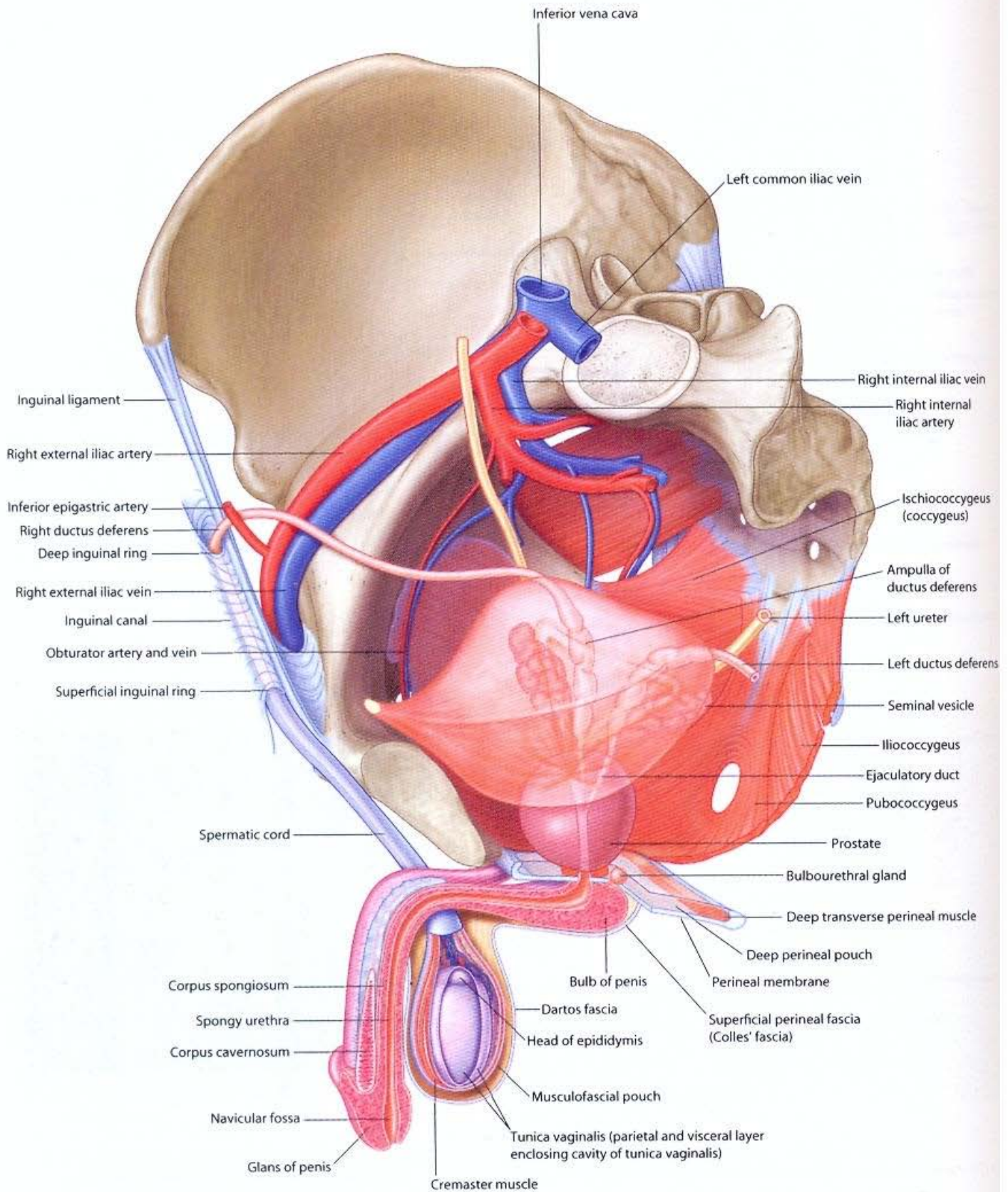
Pubovesical ligament



Urinary bladder and urethral sphincter muscles in women (anterior view of posterior wall)

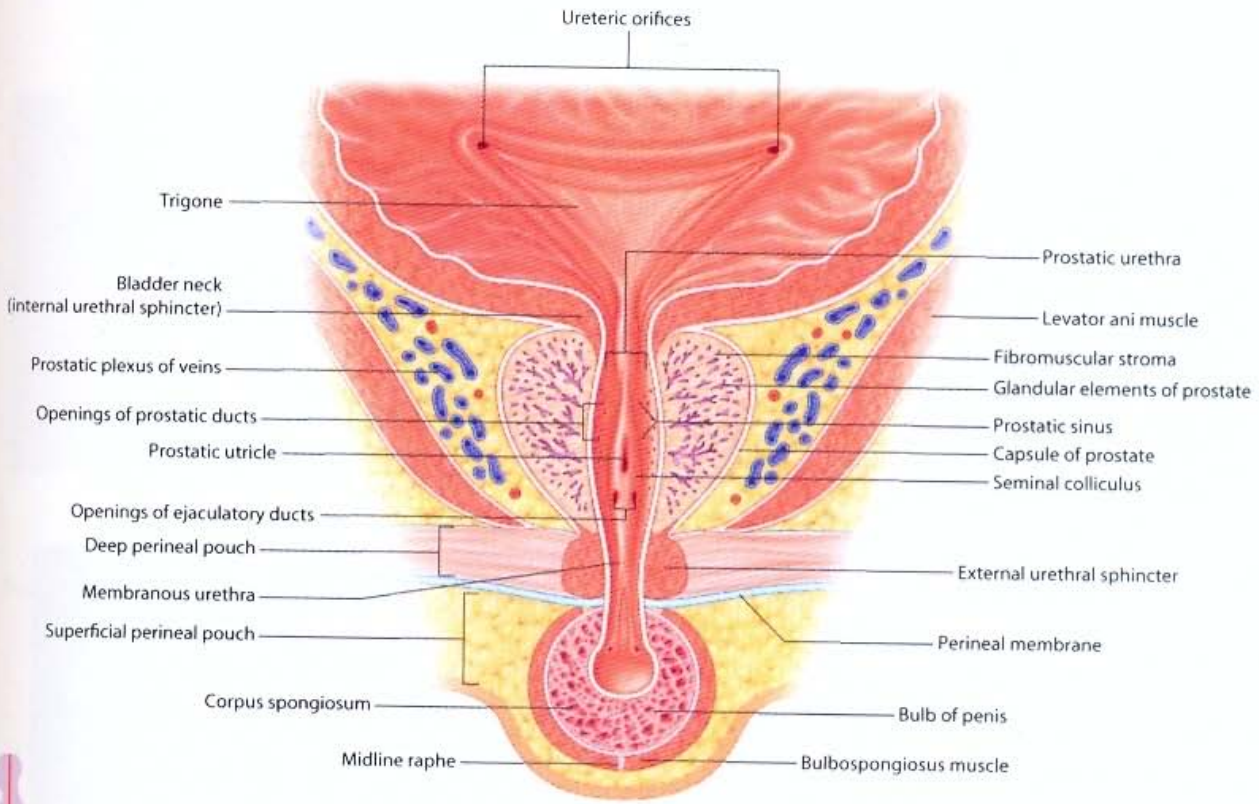


Appearance and positioning of the bladder in relation to other structures in the female pelvic cavity. T2-weighted MR image in coronal plane

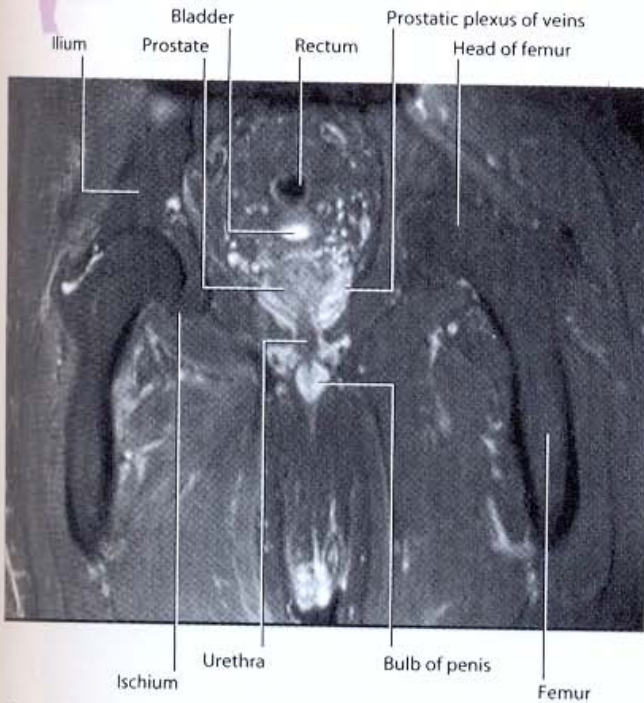


**Reproductive system in men (oblique sagittal view)**

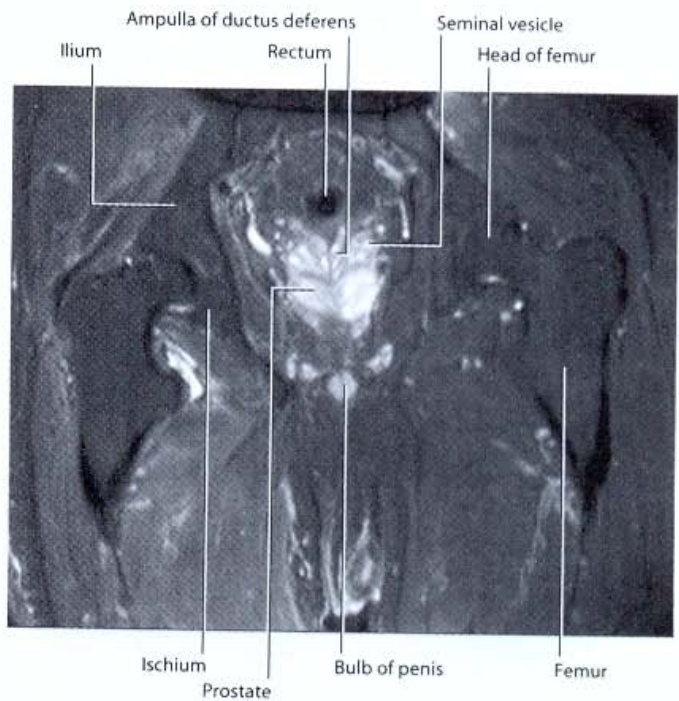




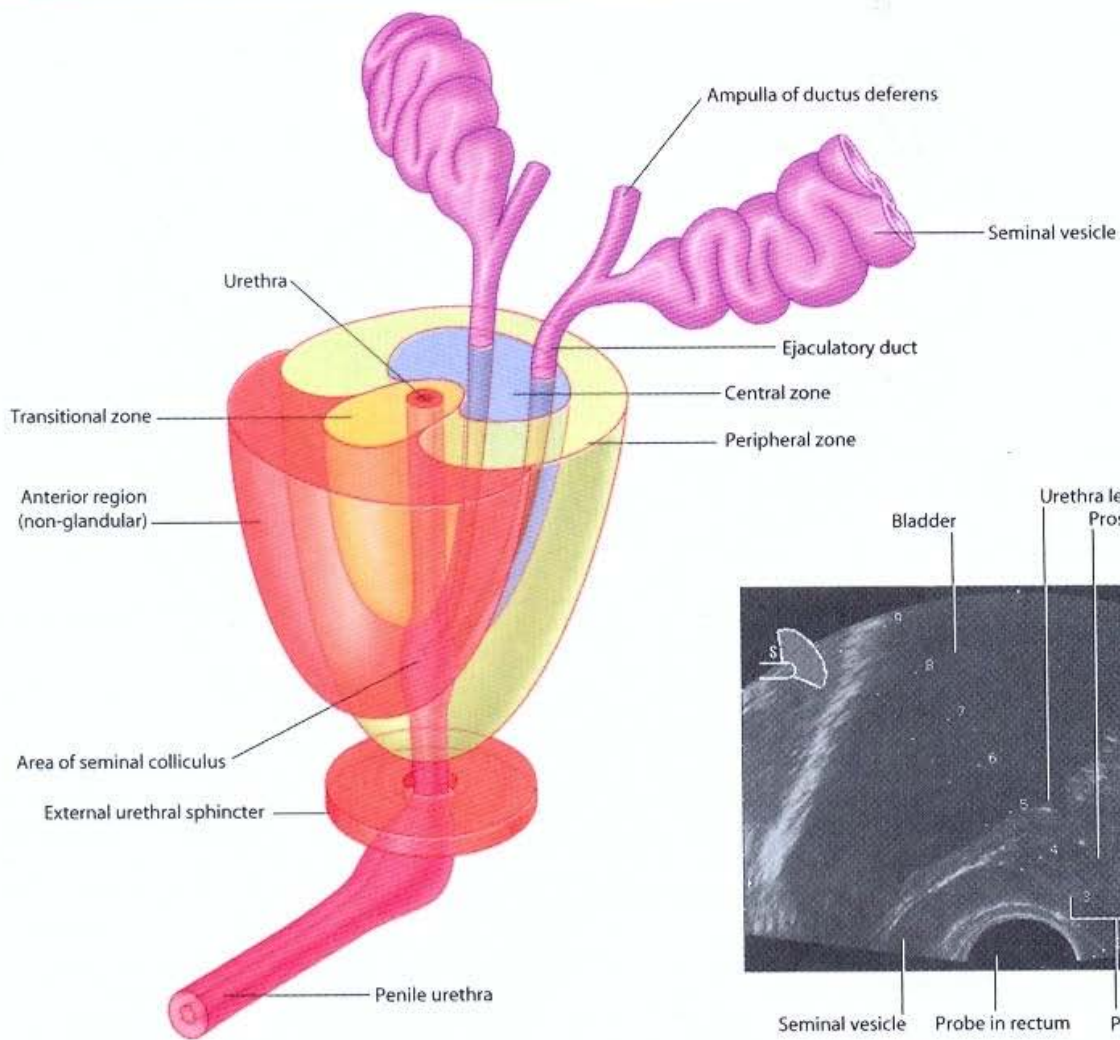
Coronal section through bladder and prostate (anterior view)



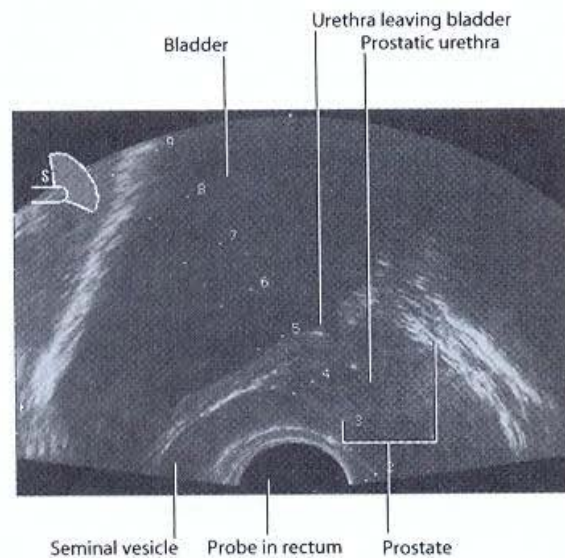
Appearance and positioning of bladder and prostate in relation to other structures in the male pelvis and perineum.  
T2-weighted MR image in coronal plane



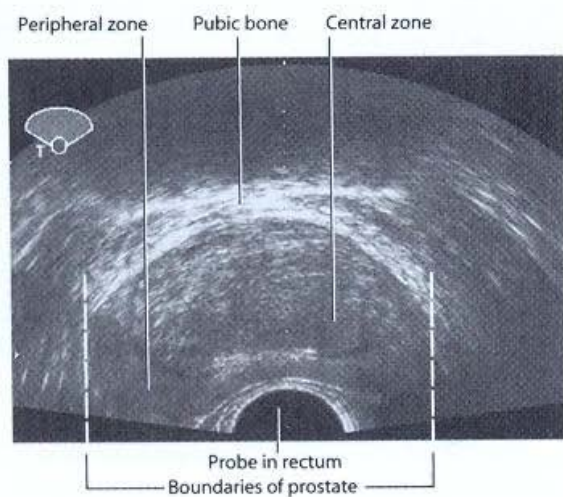
Appearance and positioning of ductus deferens, and seminal vesicles in relation to other structures in the male pelvis and perineum.  
T2-weighted MR image in coronal plane



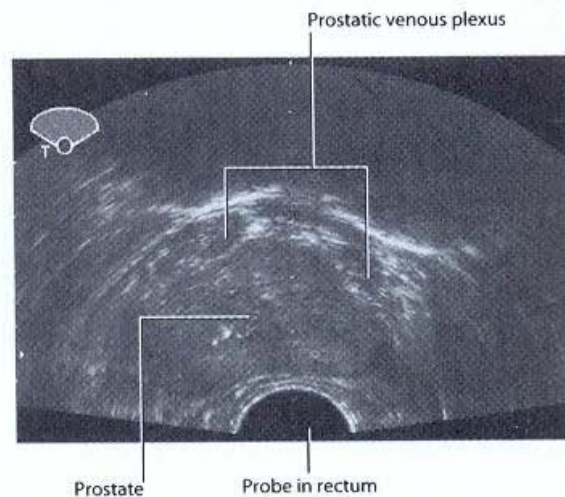
**Zonal anatomy of the prostate gland.**  
 Most carcinomas originate in the peripheral zone.  
 Benign prostatic hypertrophy (BPH) affects mainly the transitional zone



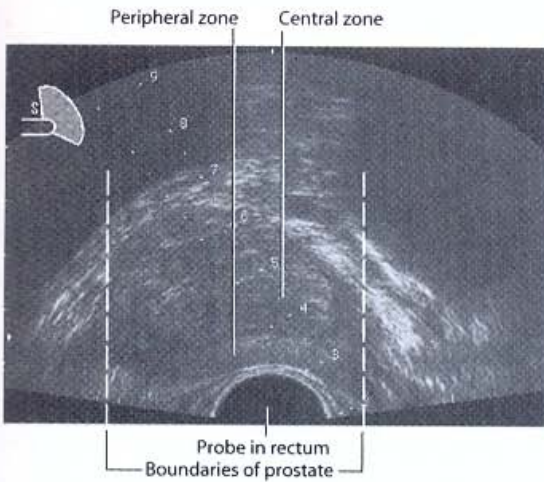
**Rectal ultrasound imaging of the prostate, bladder, and seminal vesicle. Sagittal view also showing the urethra**



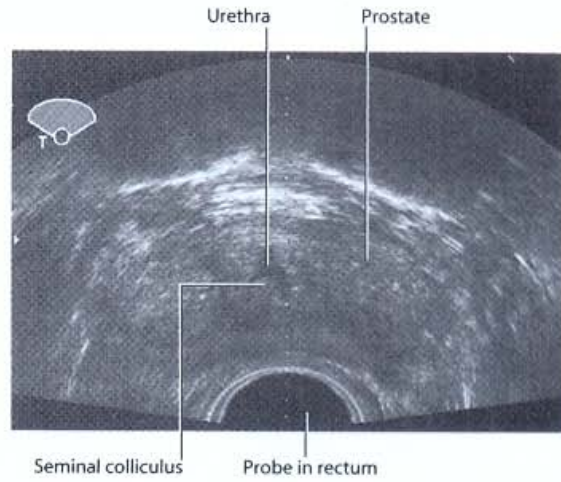
**Rectal ultrasound imaging of the prostate. Axial view showing the central and peripheral zones**



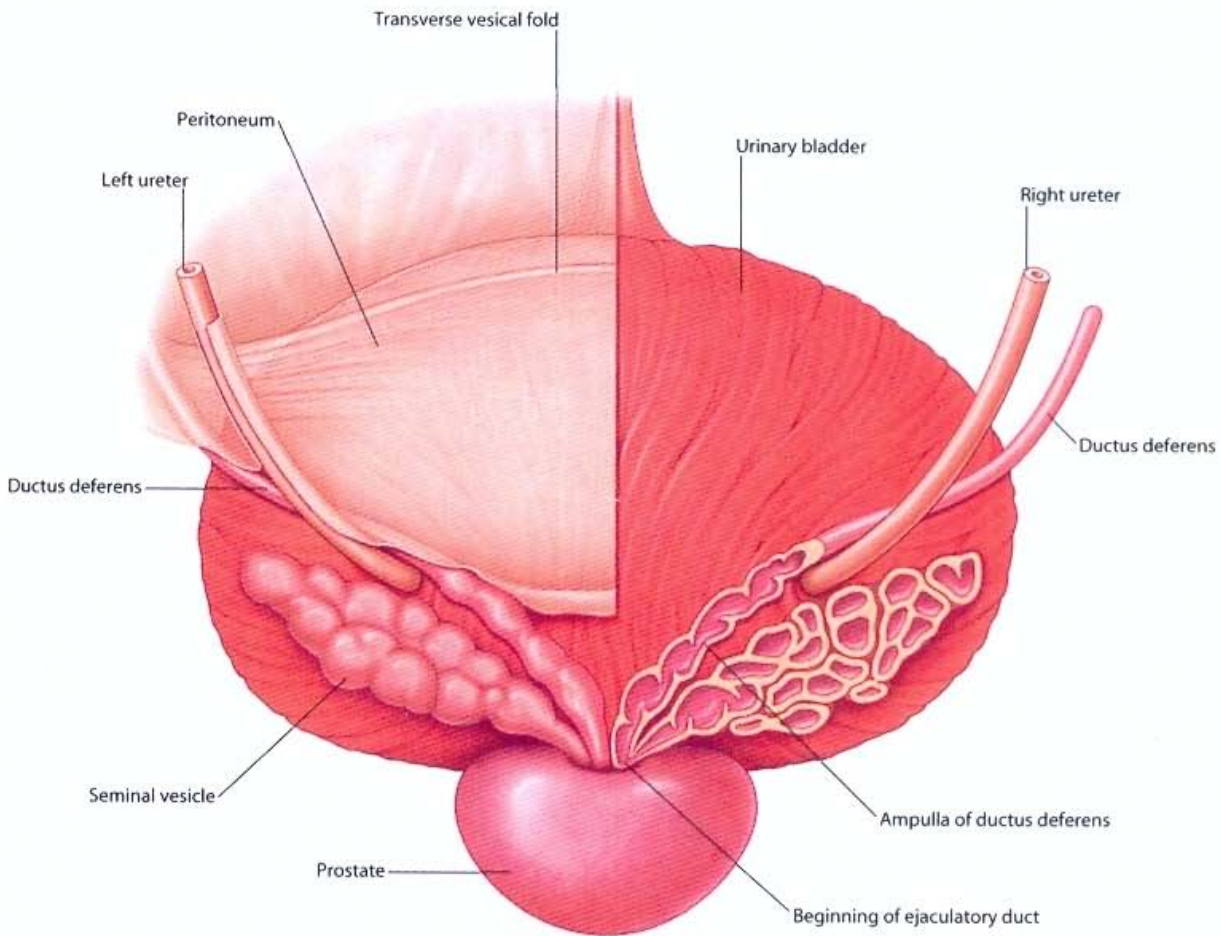
**Rectal ultrasound imaging of the prostate. Axial view showing the surrounding plexus of veins**



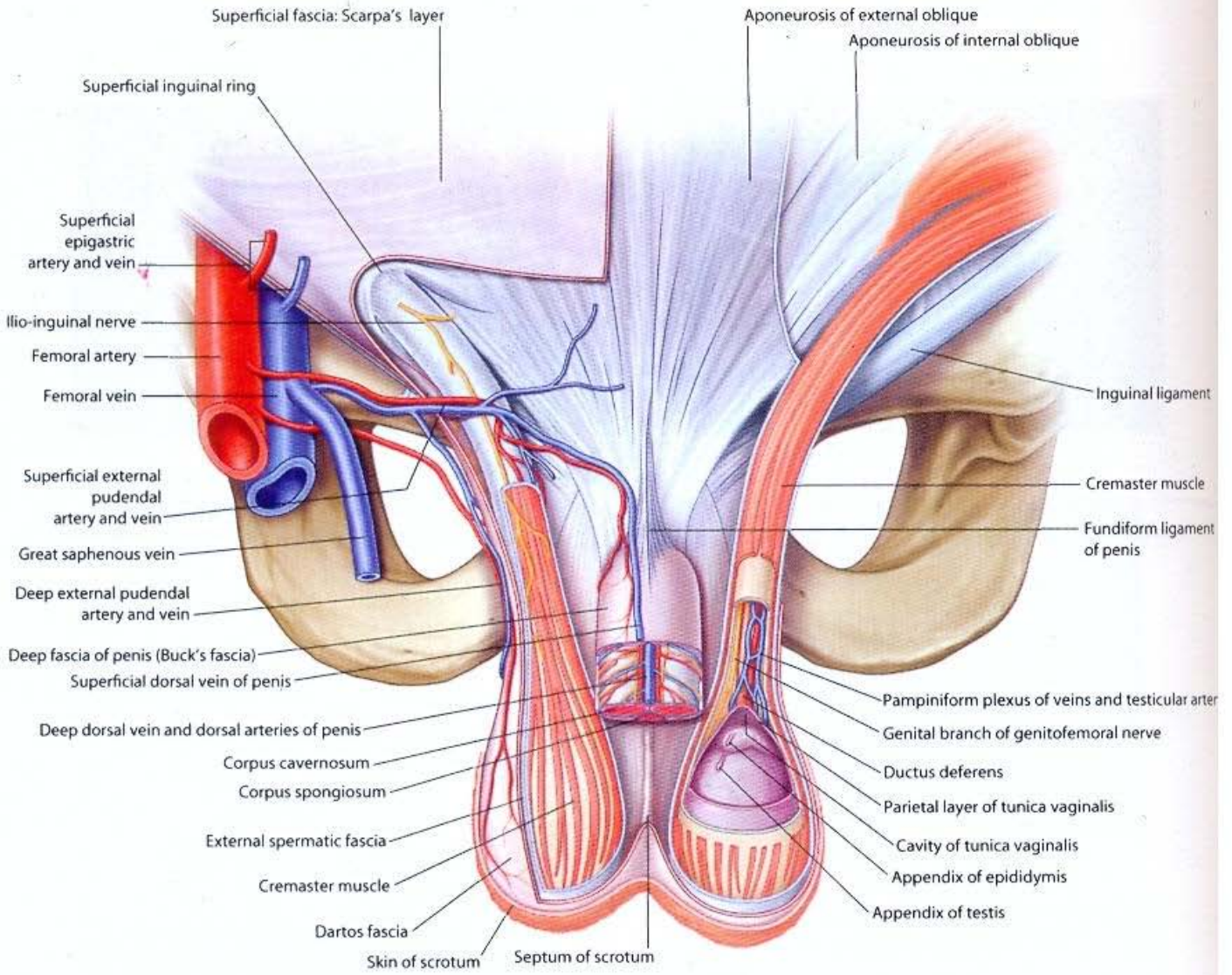
Rectal ultrasound imaging of the prostate. Sagittal view showing the central and peripheral zones



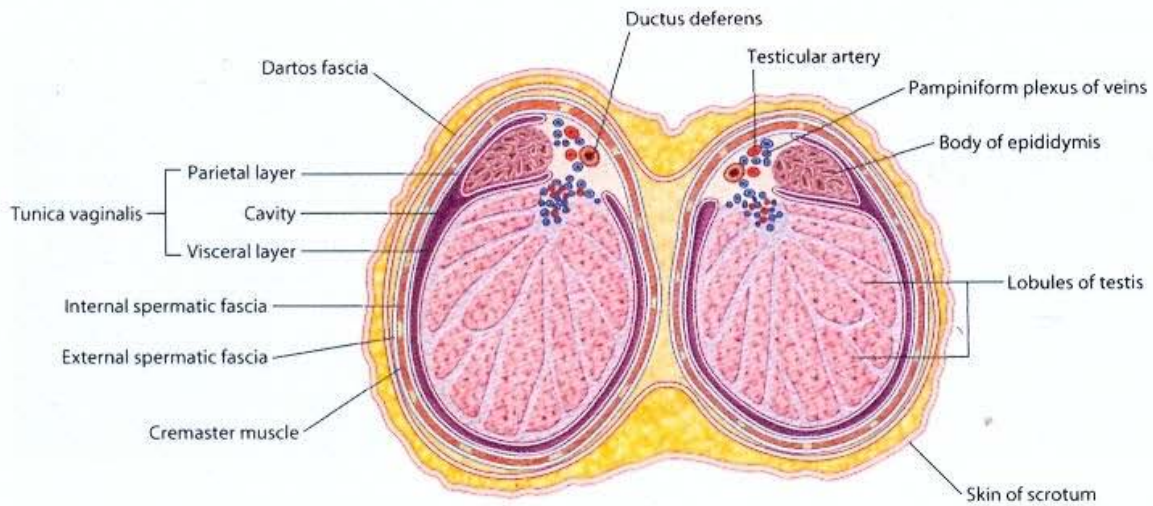
Rectal ultrasound imaging of the prostate. Axial view showing the urethra and seminal colliculus



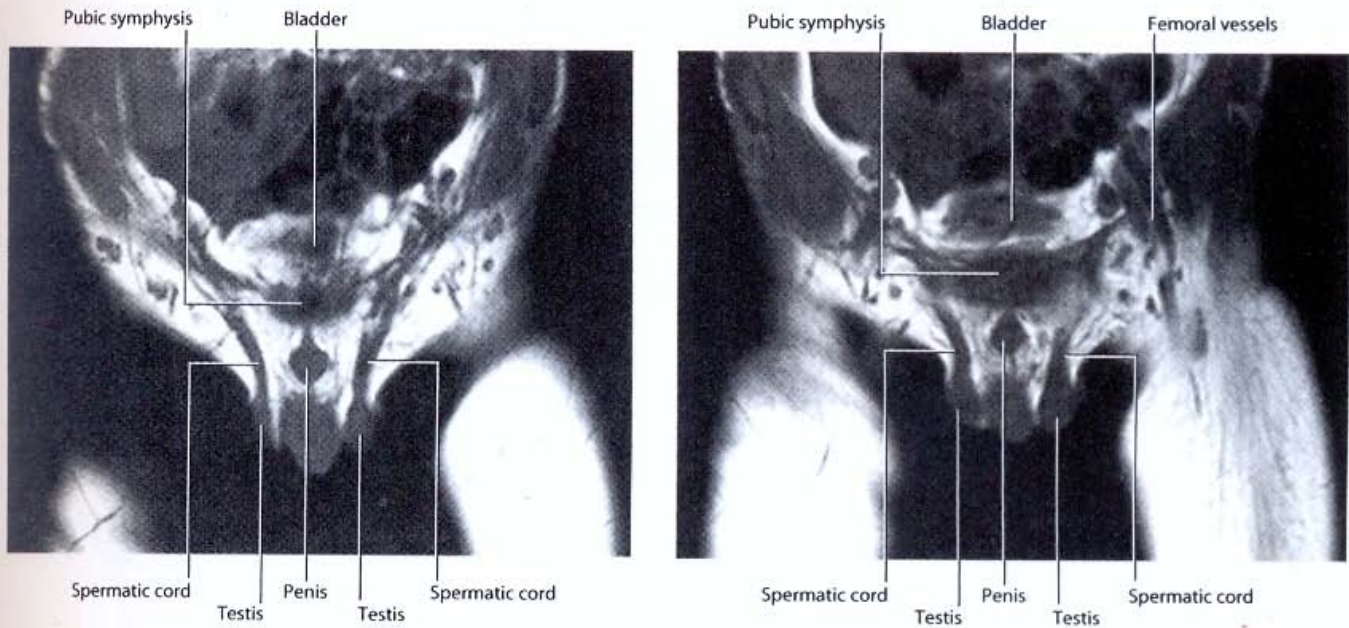
Bladder and prostate (posterior view)



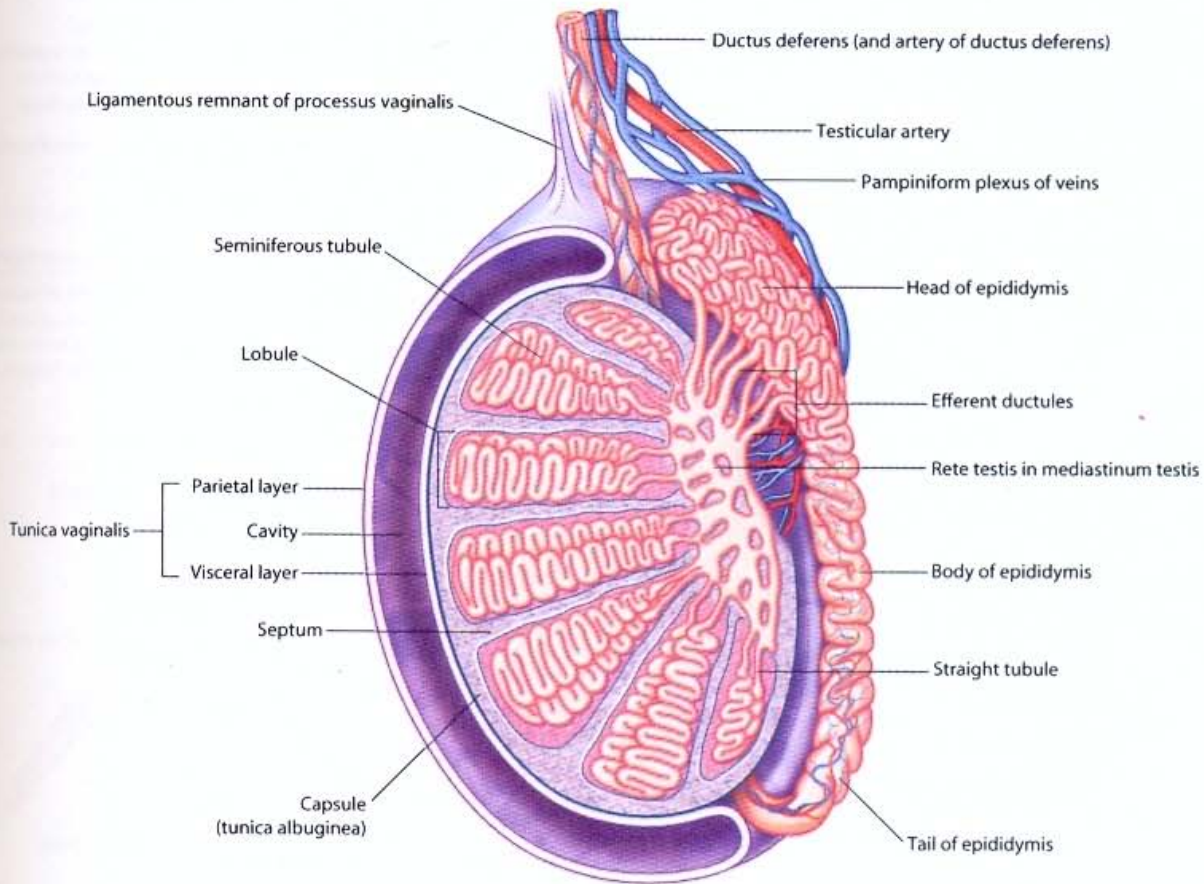
**Contents of the scrotum (anterior view)**



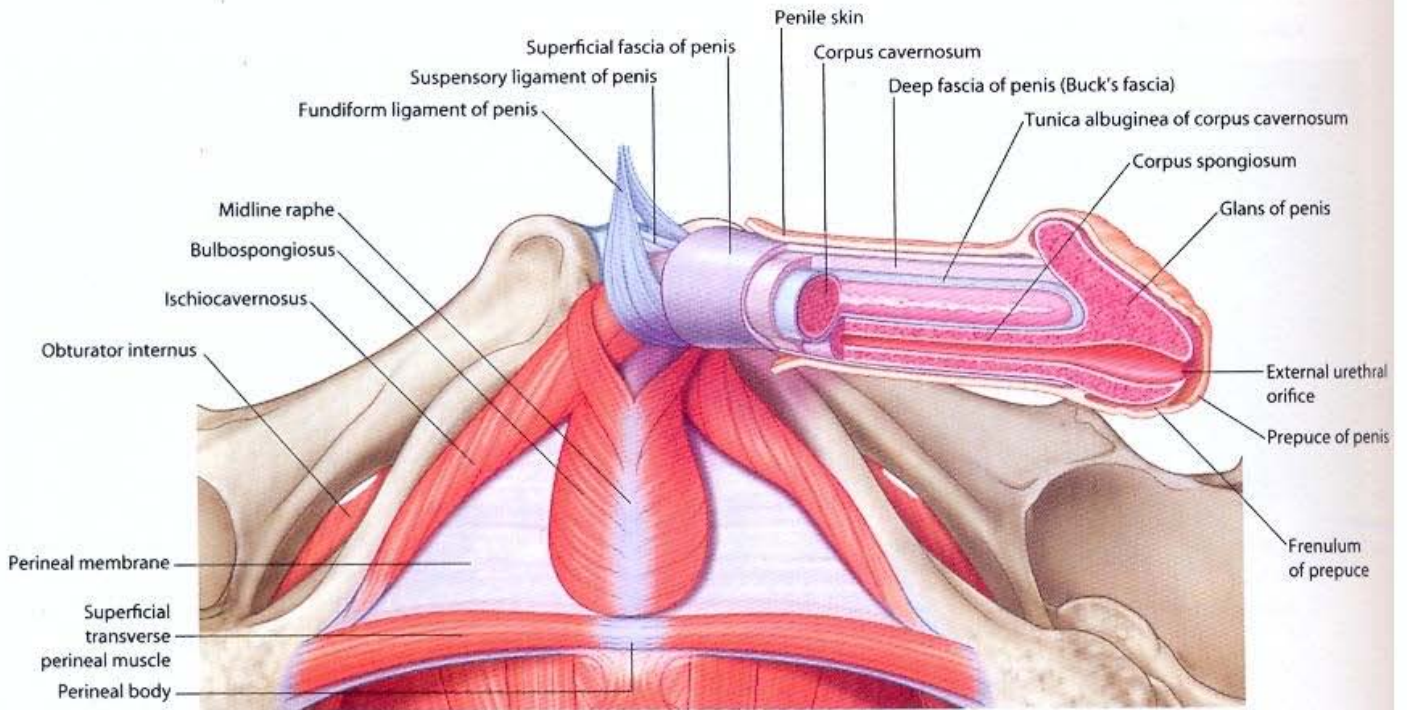
**Transverse section through the scrotum and testes**



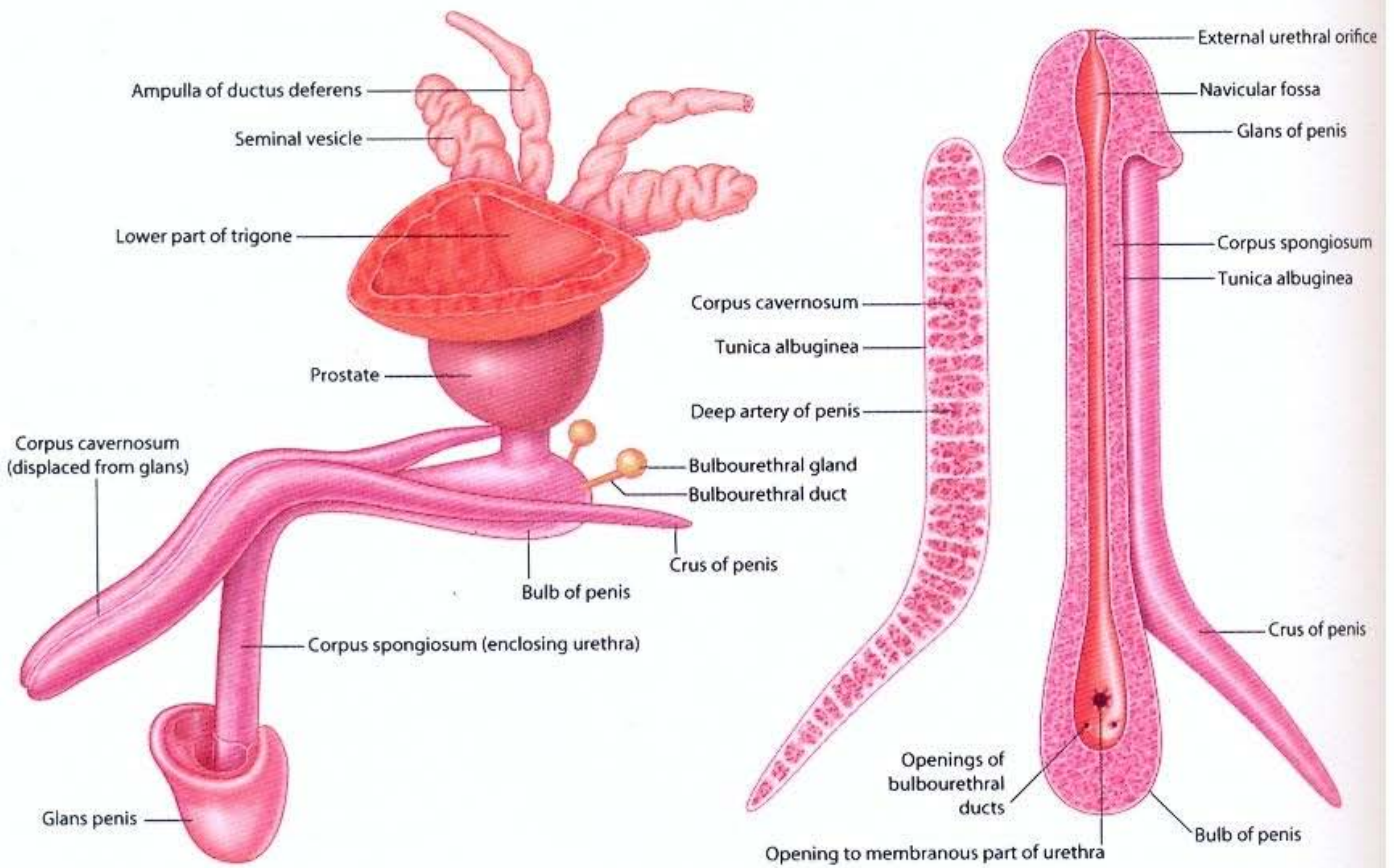
**Spermatic cord appearance and positioning in a young male.**  
T1-weighted MR images in coronal plane



**Testis and surrounding structures**

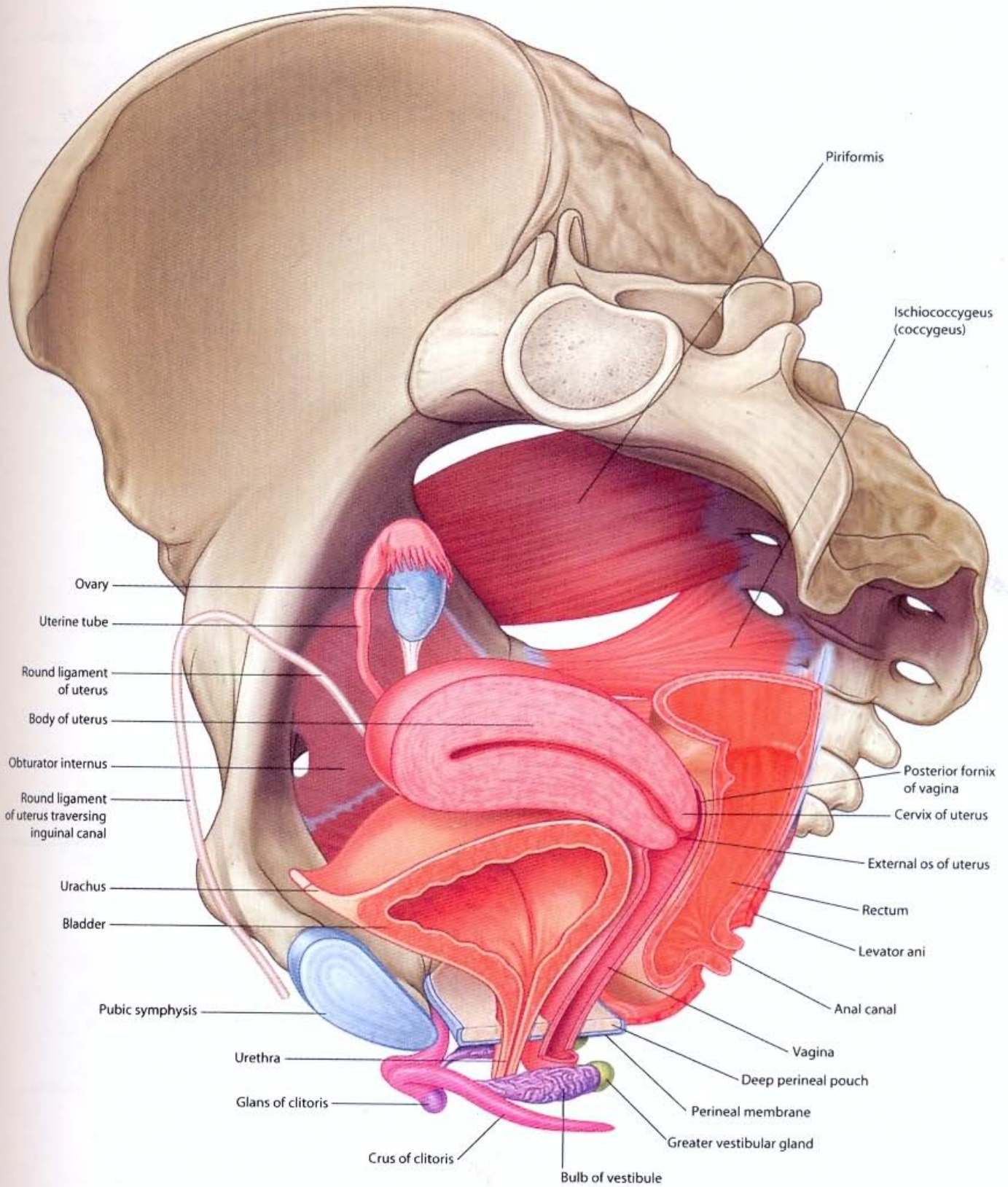


**Structure of the penis**

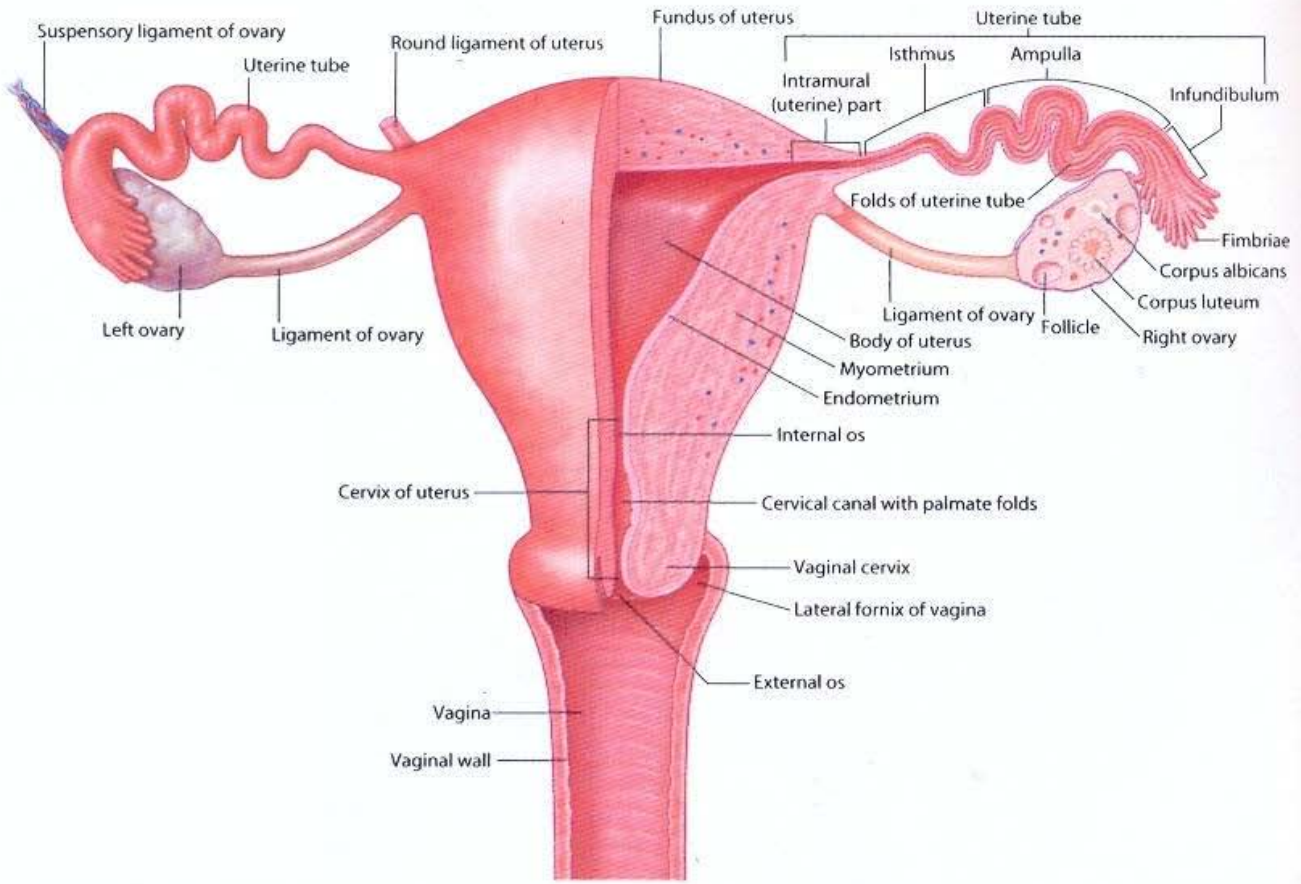


**Structure of the penis**

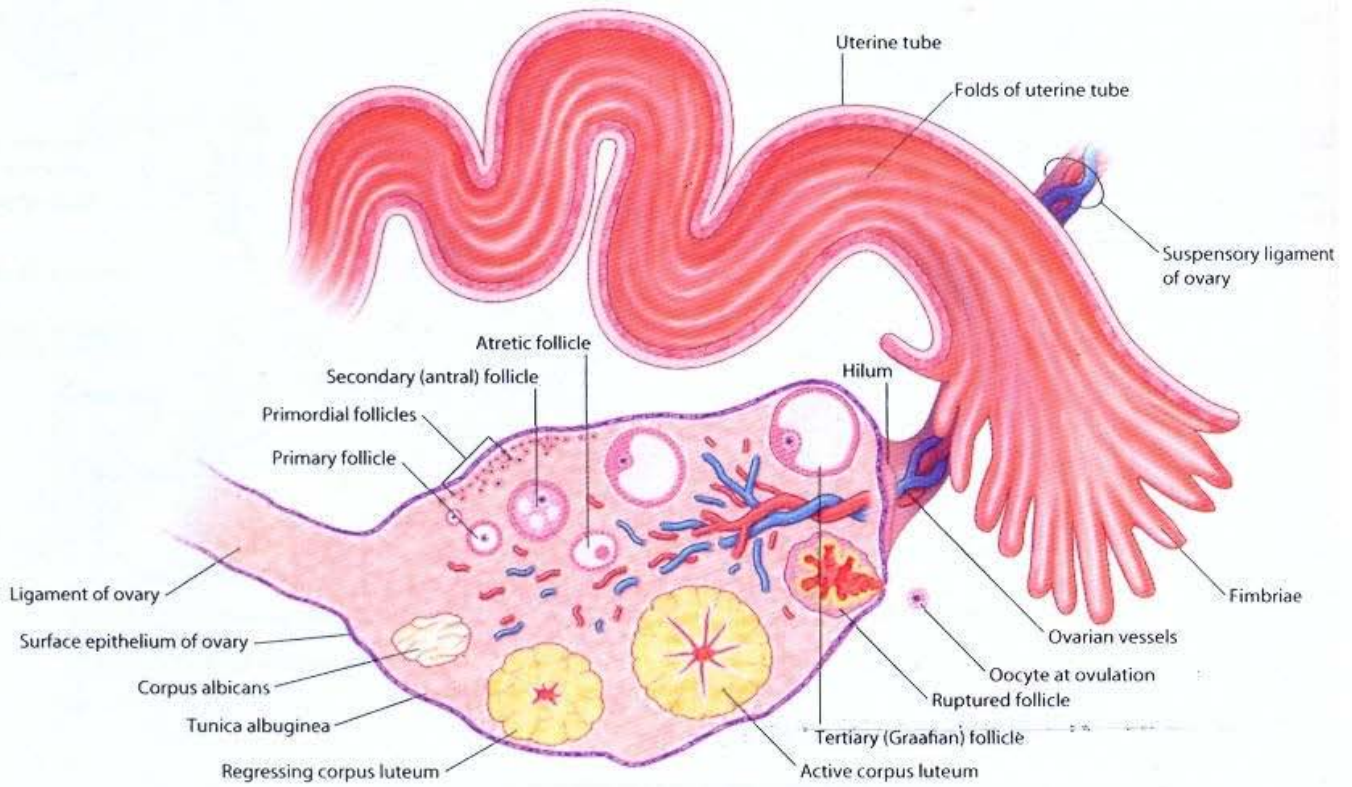
**Roof of spongy urethra (inferior view)**



Reproductive system in women (oblique sagittal view)

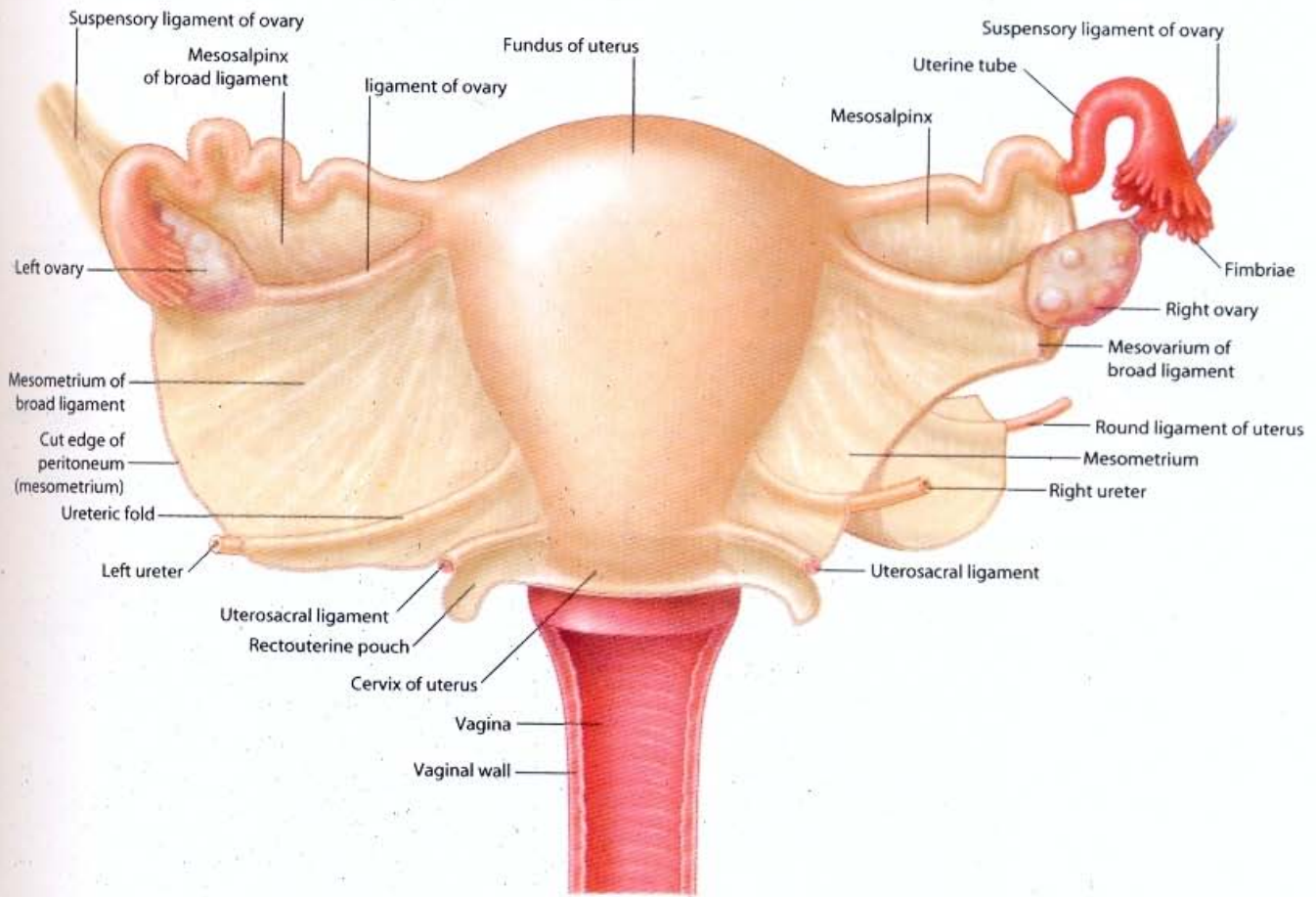


**Structure of the uterus and ovaries (posterior view)**

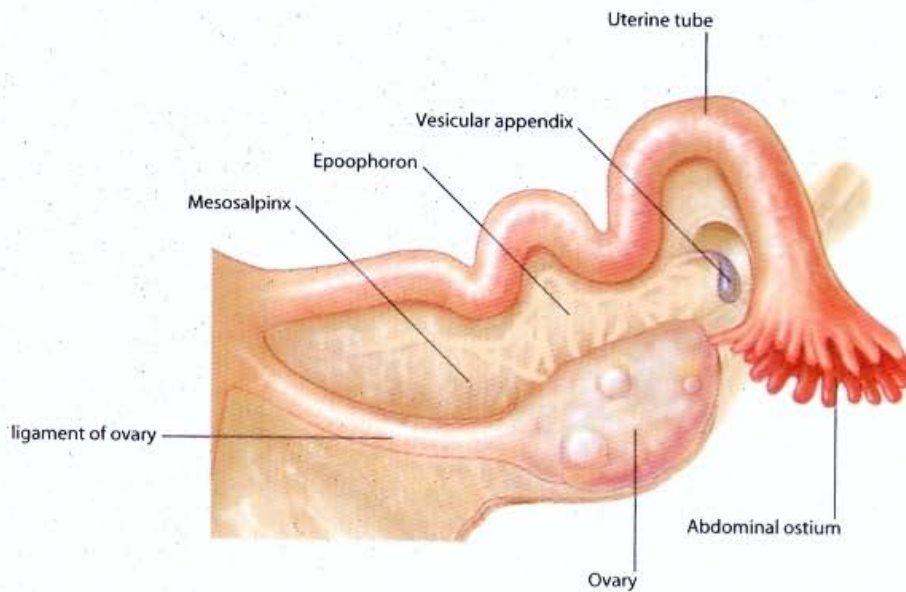


**Structure of the uterine tube and ovary (posterior view)**

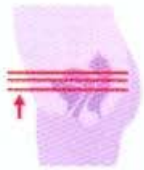



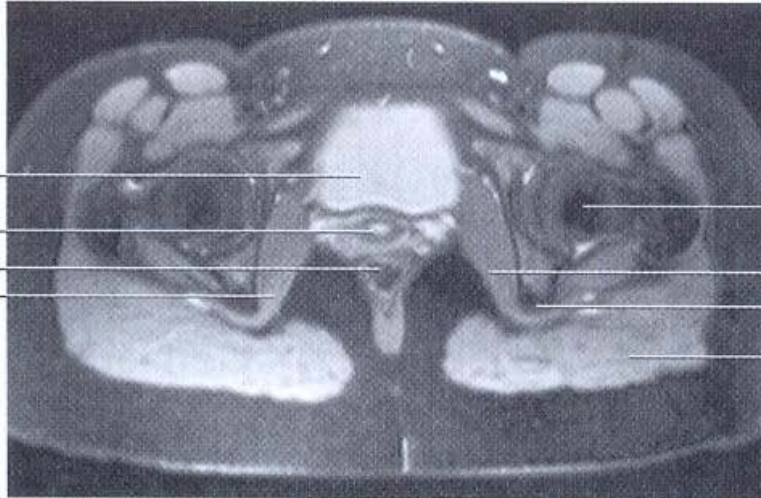
Uterus and broad ligament (posterior view)



Uterine tube and ovary (posterior view)

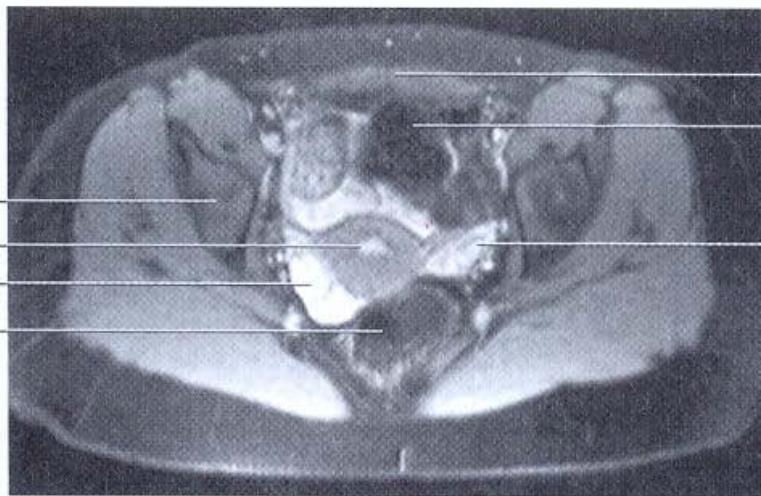


**A**



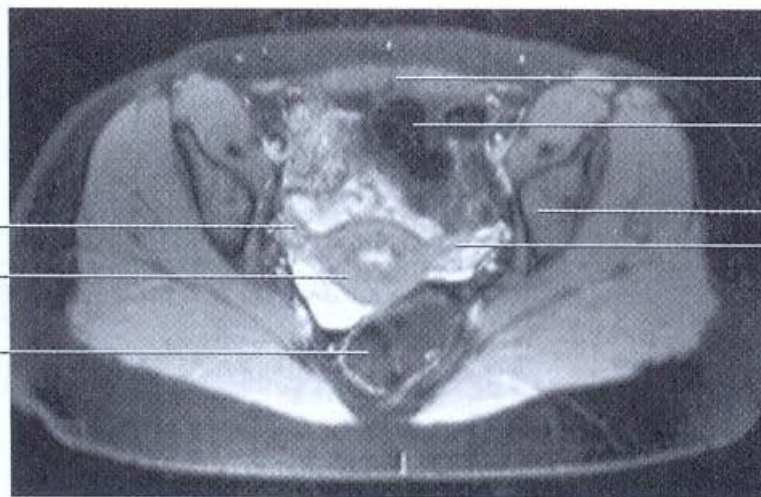
- Bladder
- Cervix of uterus
- Rectum
- Obturator internus
- Head of femur
- Obturator internus
- Ischial tuberosity
- Gluteus maximus

**B**



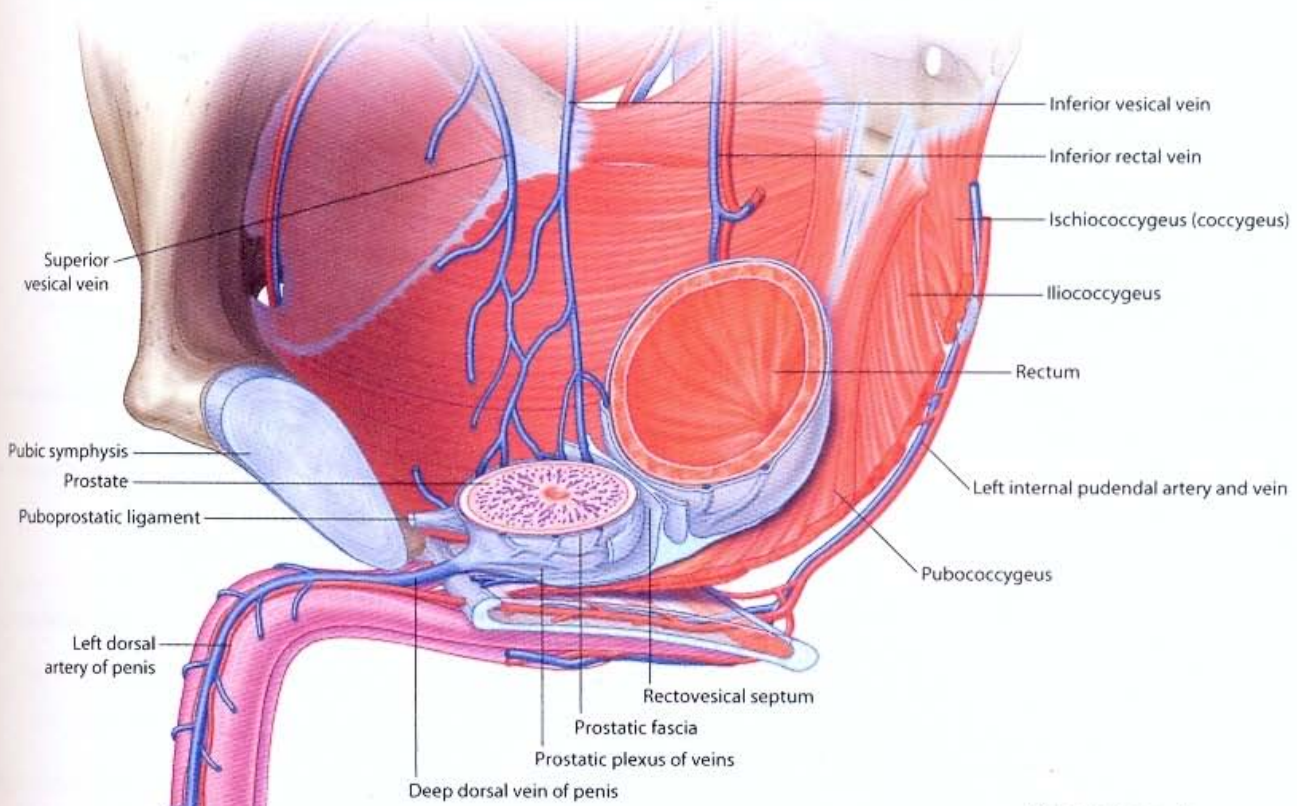
- Head of femur
- Uterus
- Right ovary
- Rectum
- Pubic symphysis
- Small intestine
- Left ovary

**C**

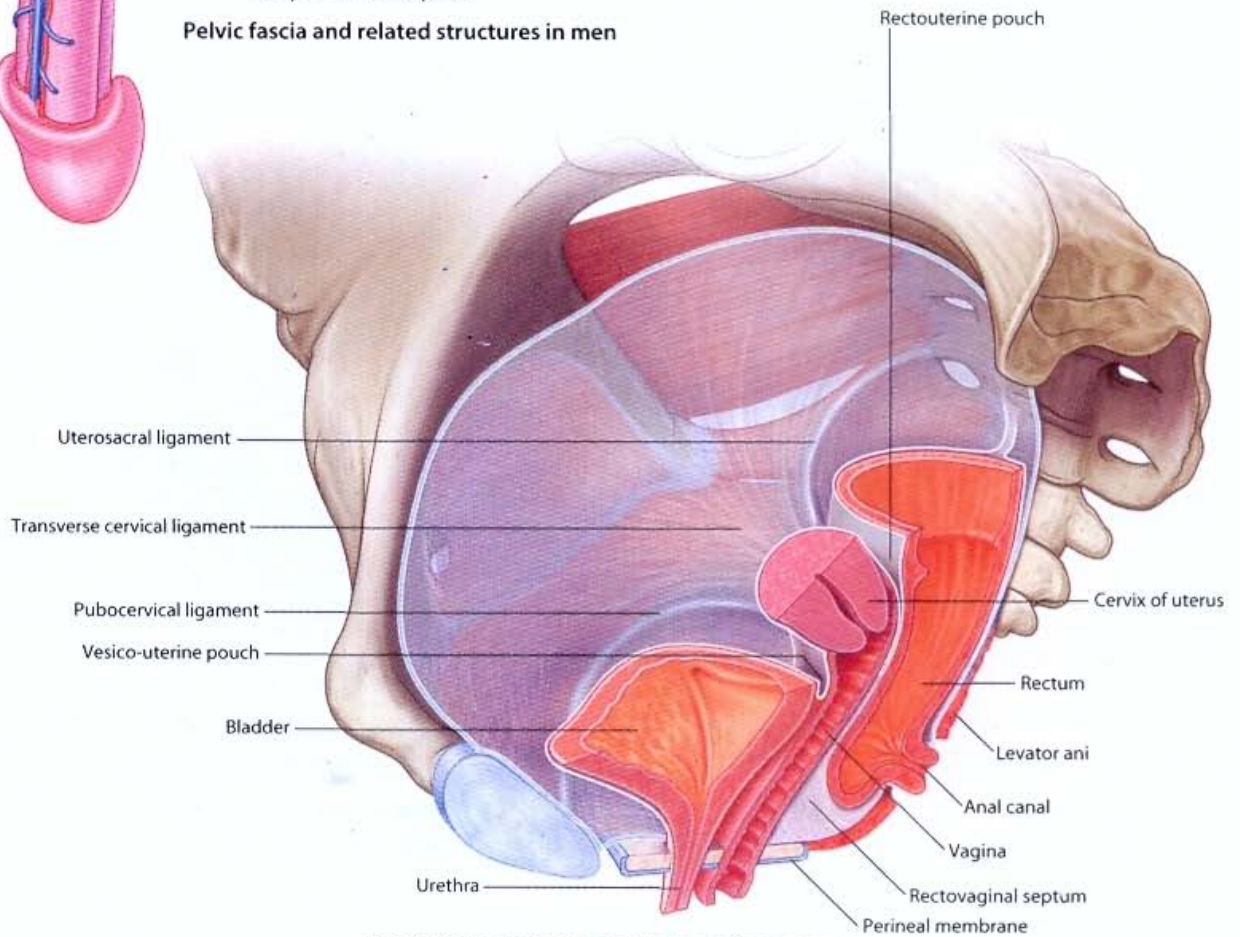


- Right uterine tube
- Uterus
- Rectum
- Pubic symphysis
- Small intestine
- Ilium
- Left uterine tube

**Appearance of cervix of uterus, uterus, ovaries, and uterine tubes in relation to other pelvic structures. T2-weighted MR images in axial plane**

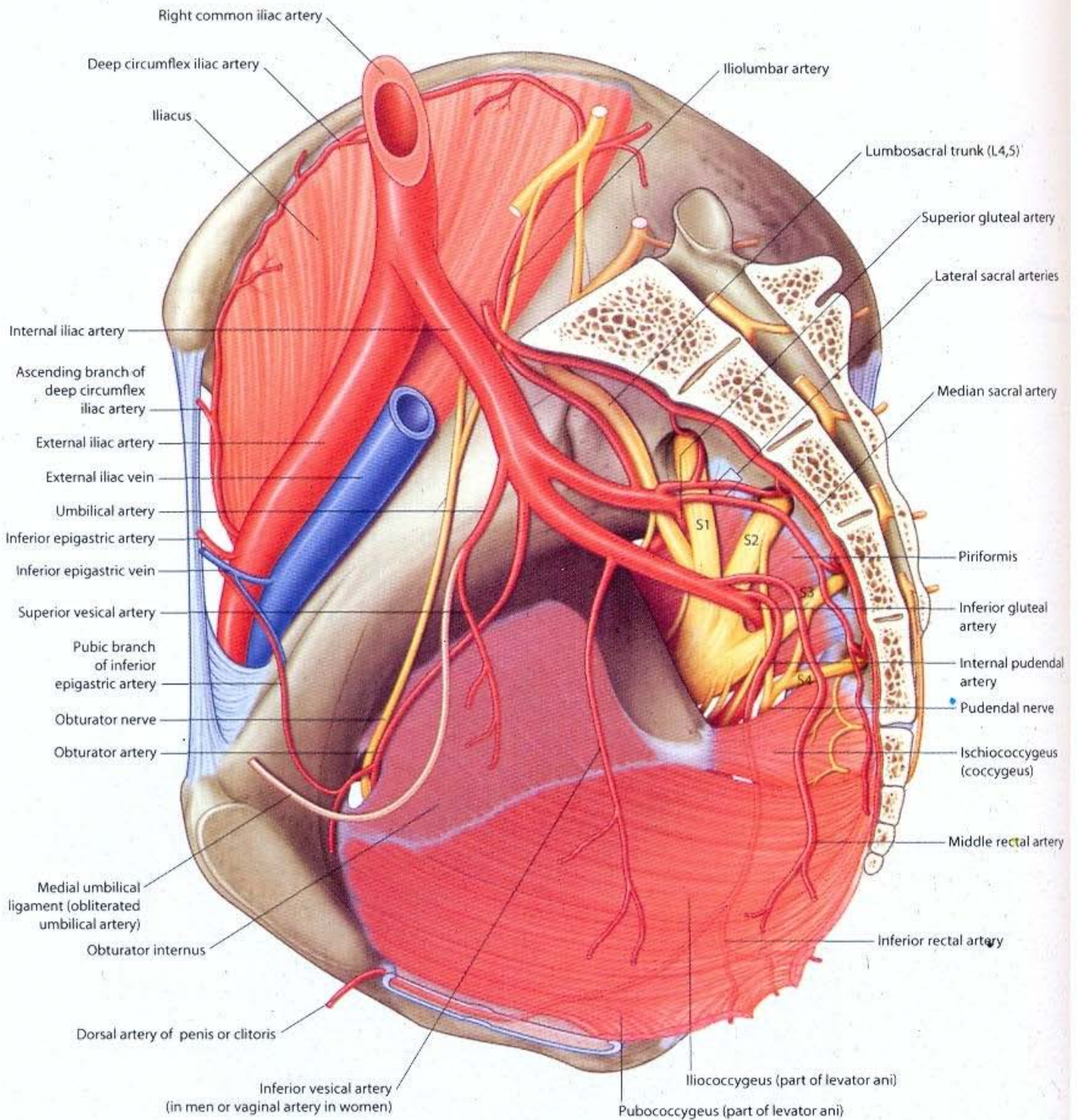


**Pelvic fascia and related structures in men**

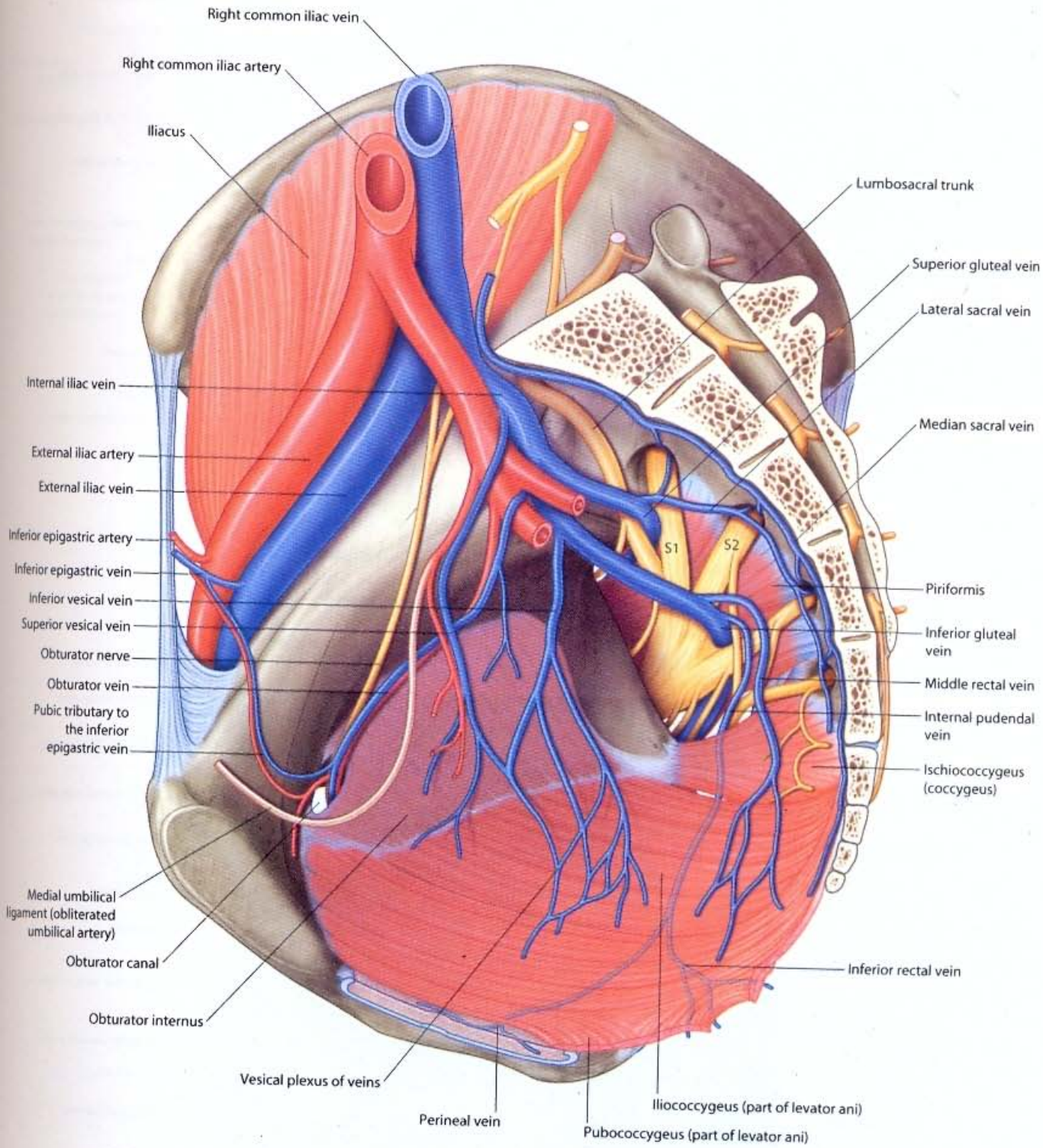


**Pelvic fascia and related structures in women**

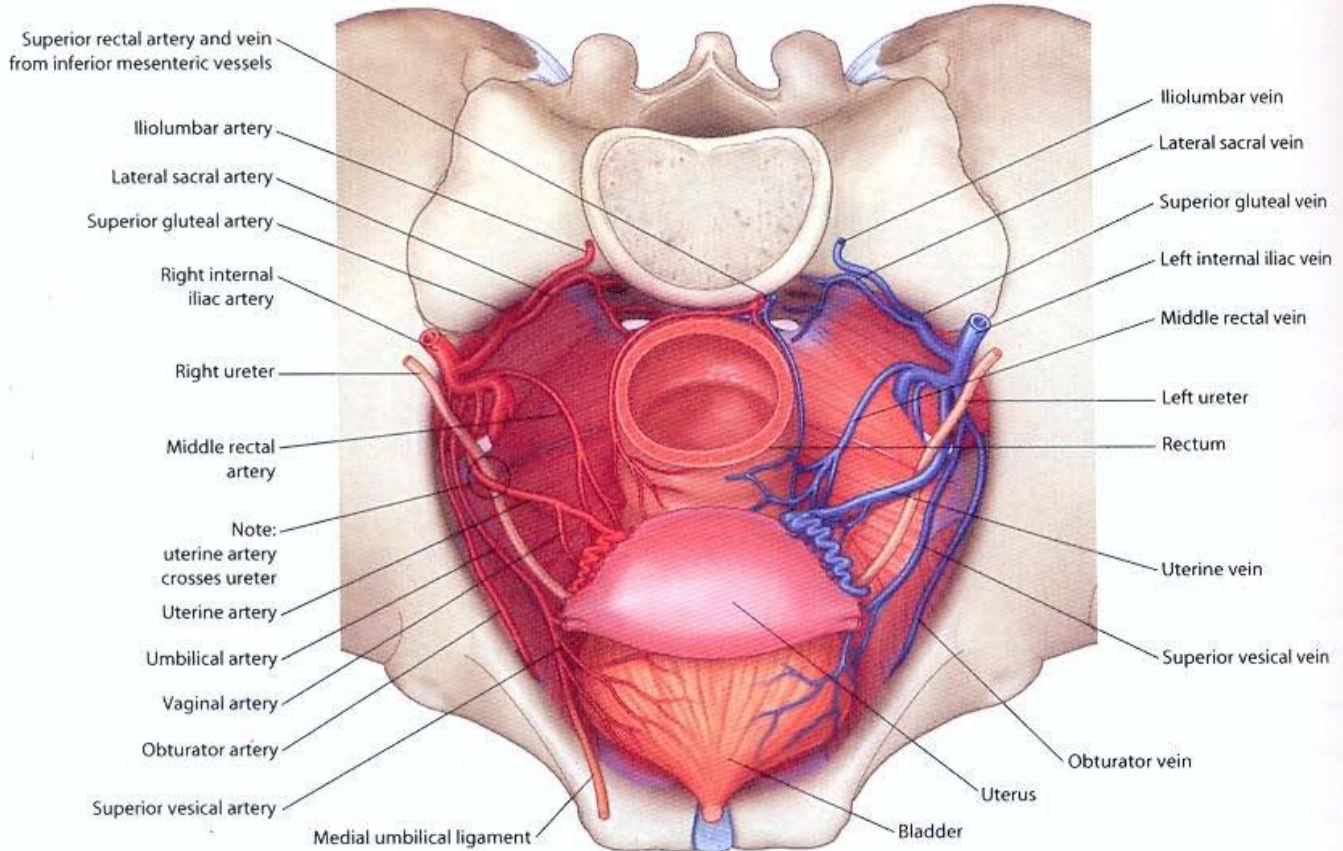
# PELVIS AND PERINEUM • Arterial supply of pelvis



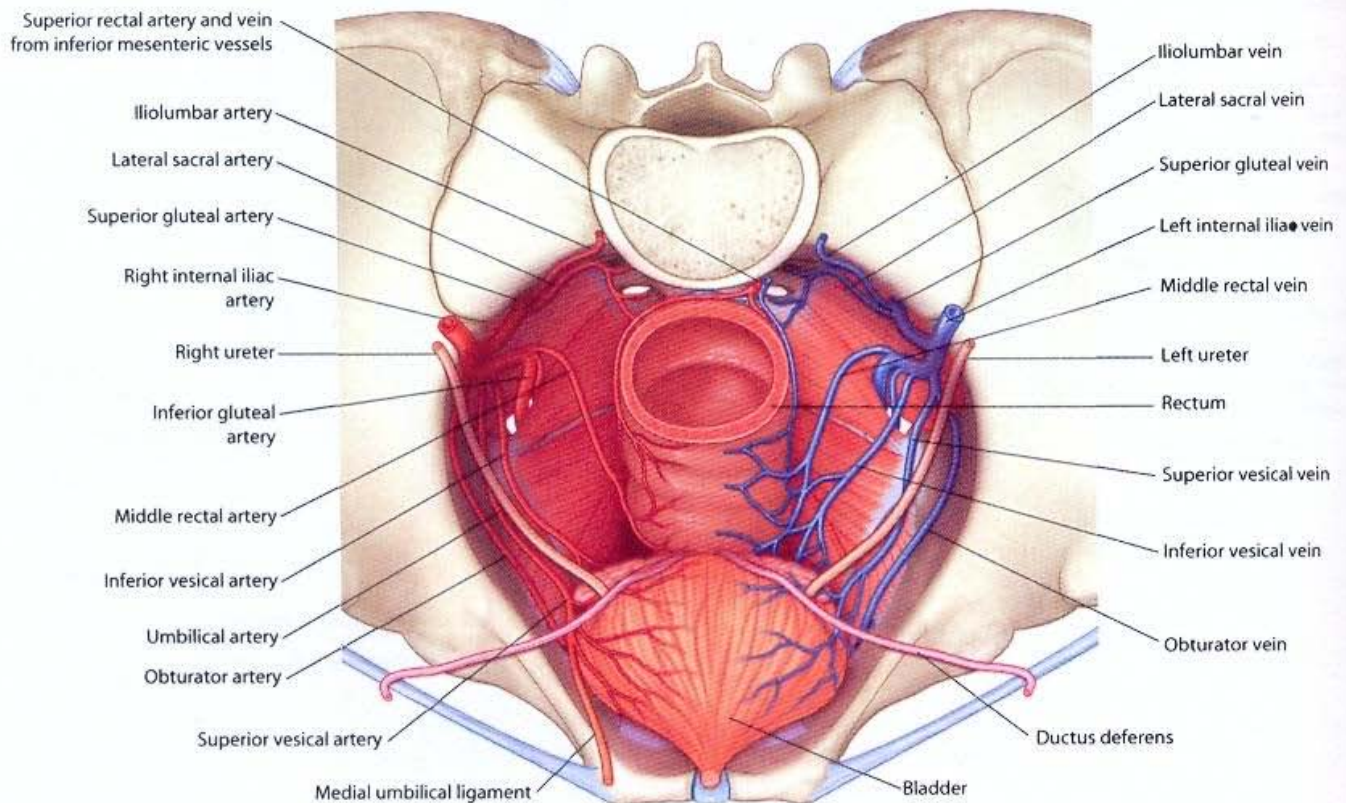
Arterial supply to the pelvis (right side sagittal view)



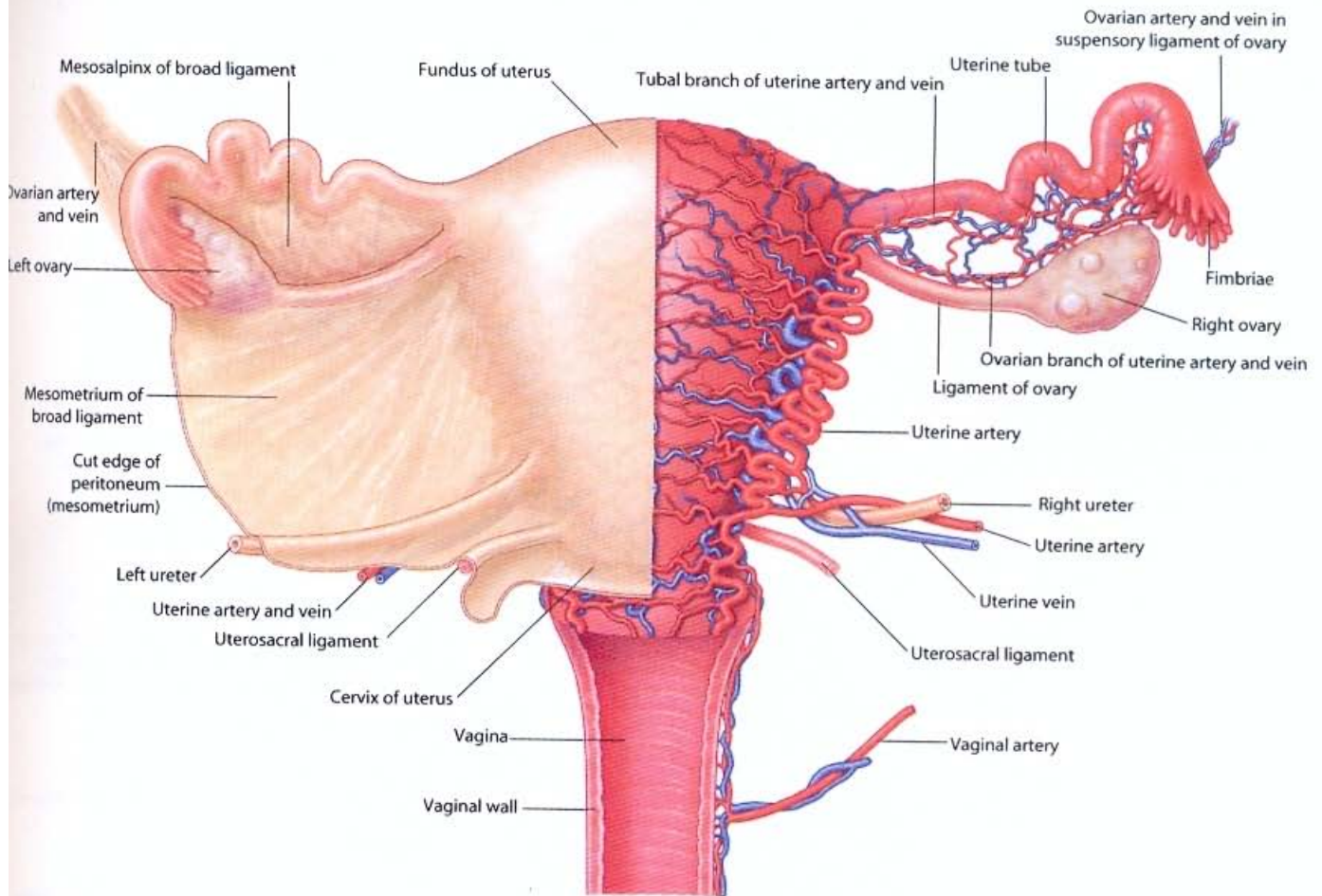
Veins of the pelvis (right side sagittal view)



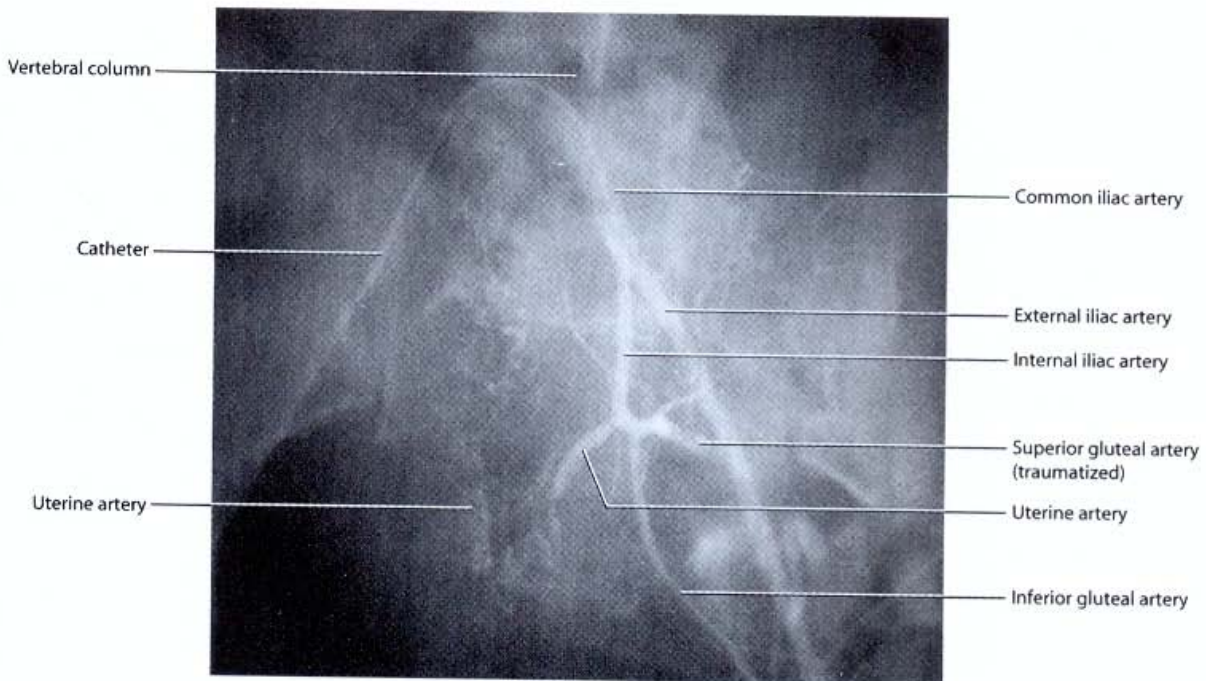
**Vasculature of the pelvic viscera in women (superior view)**



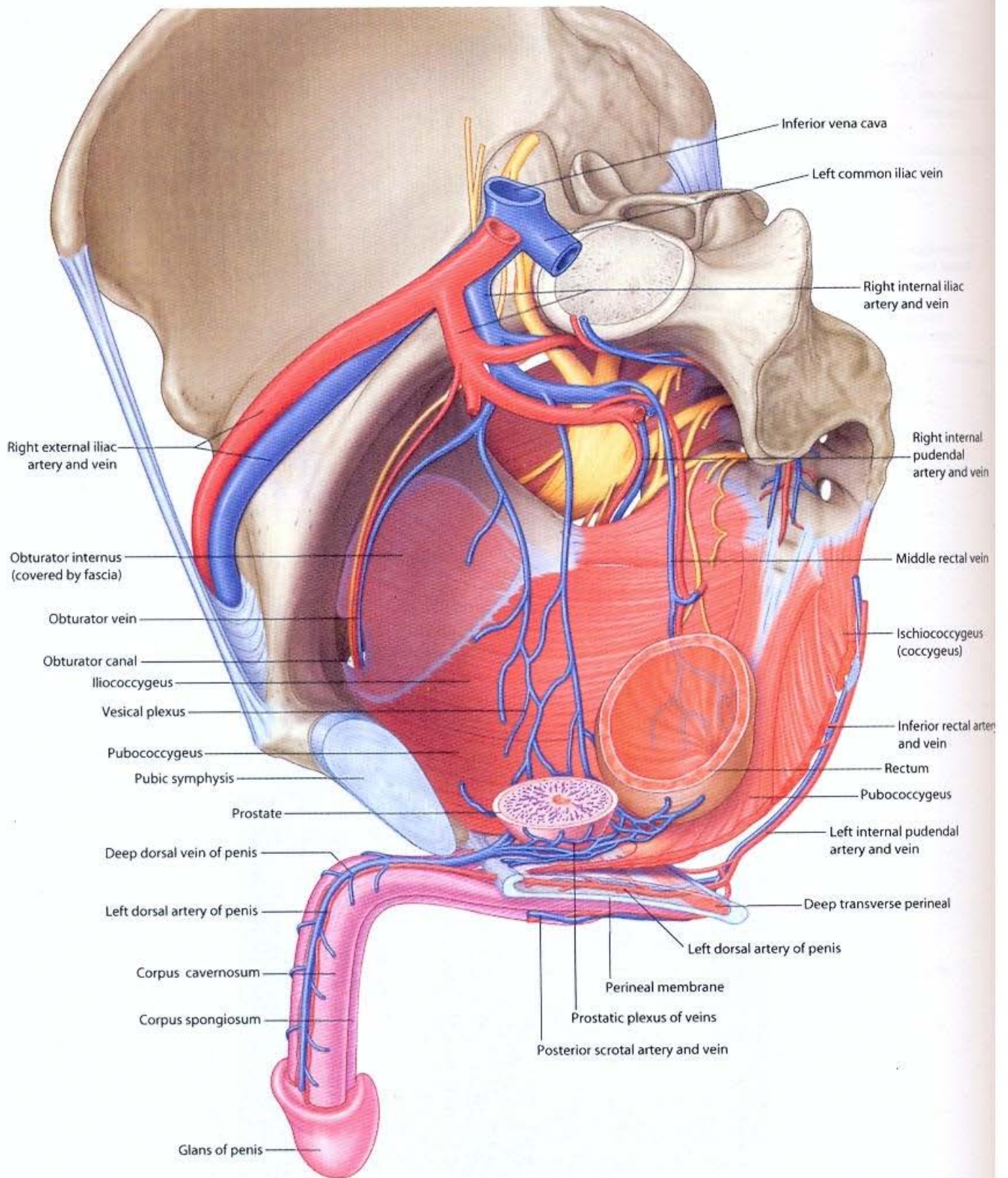
**Vasculature of the pelvic viscera in men (superior view)**



Vascular supply to uterus (posterior view)

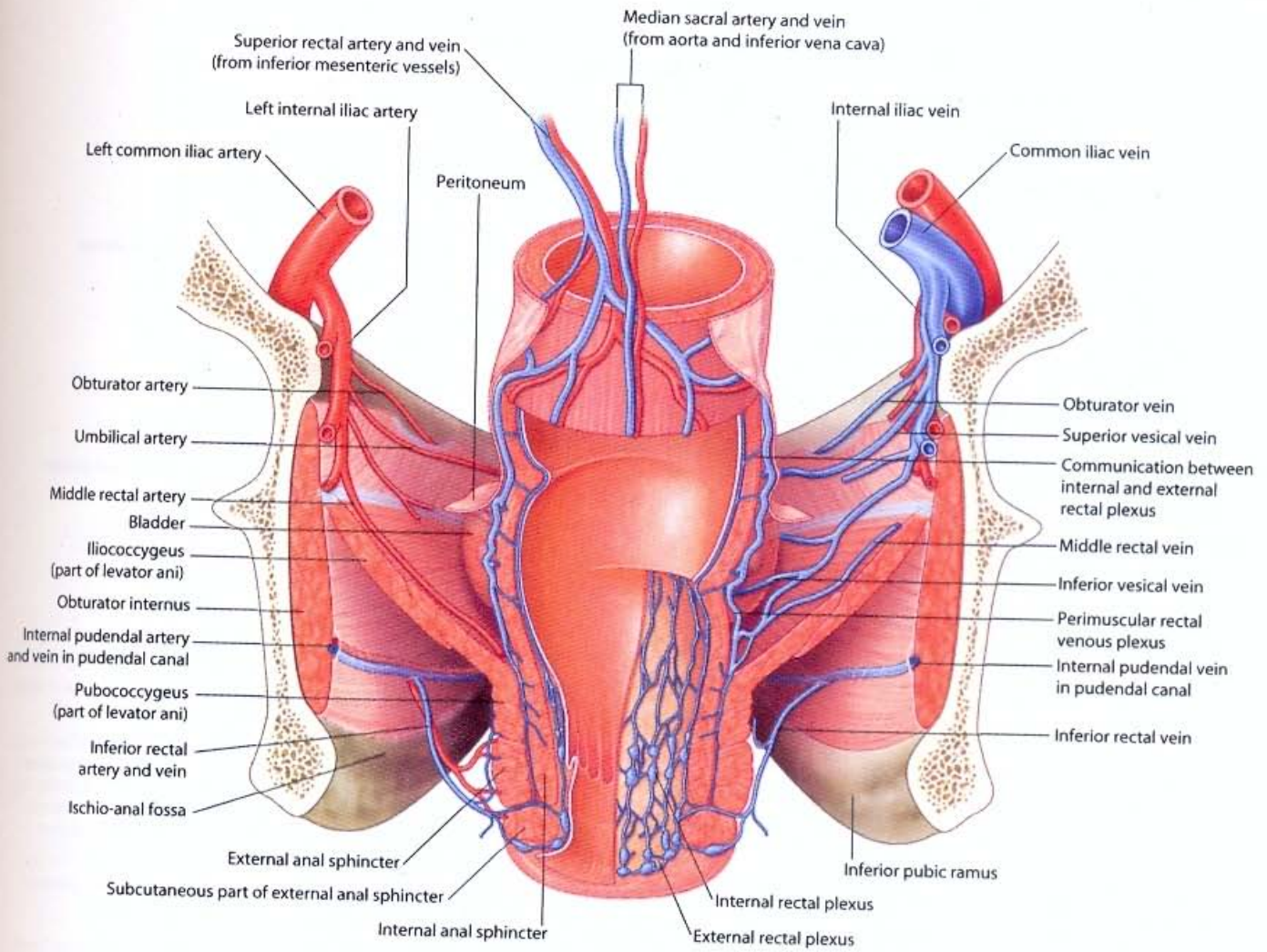


Vascular supply to uterus. Angiogram

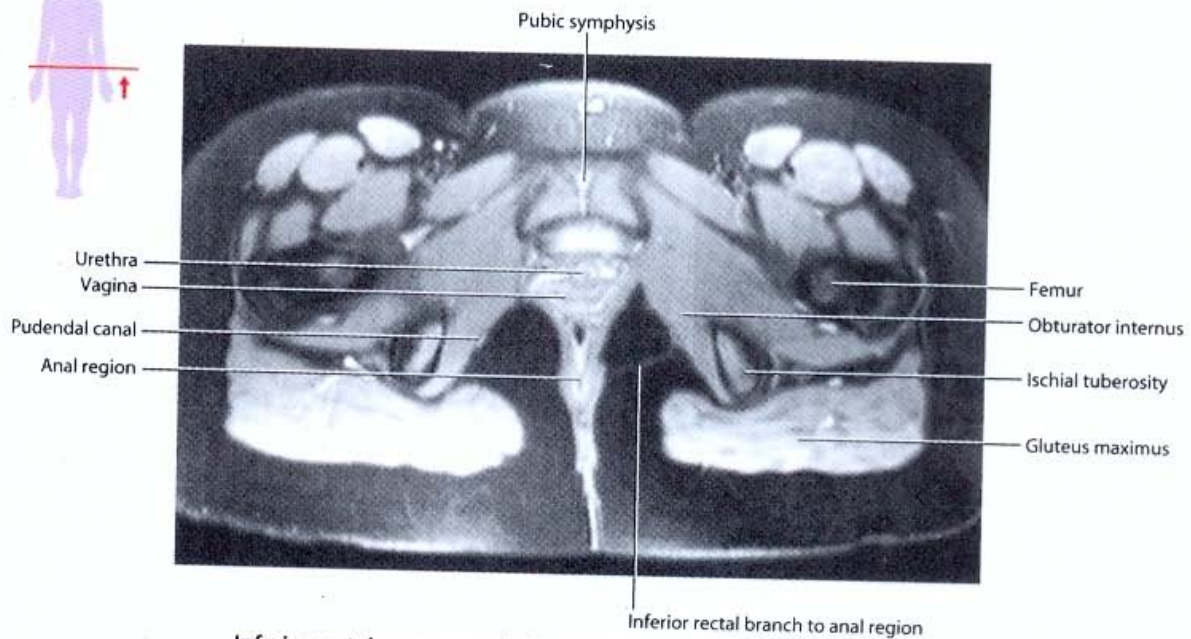
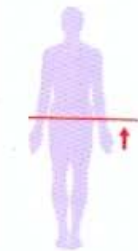


**Venous drainage of pelvic viscera in men (oblique sagittal view)**



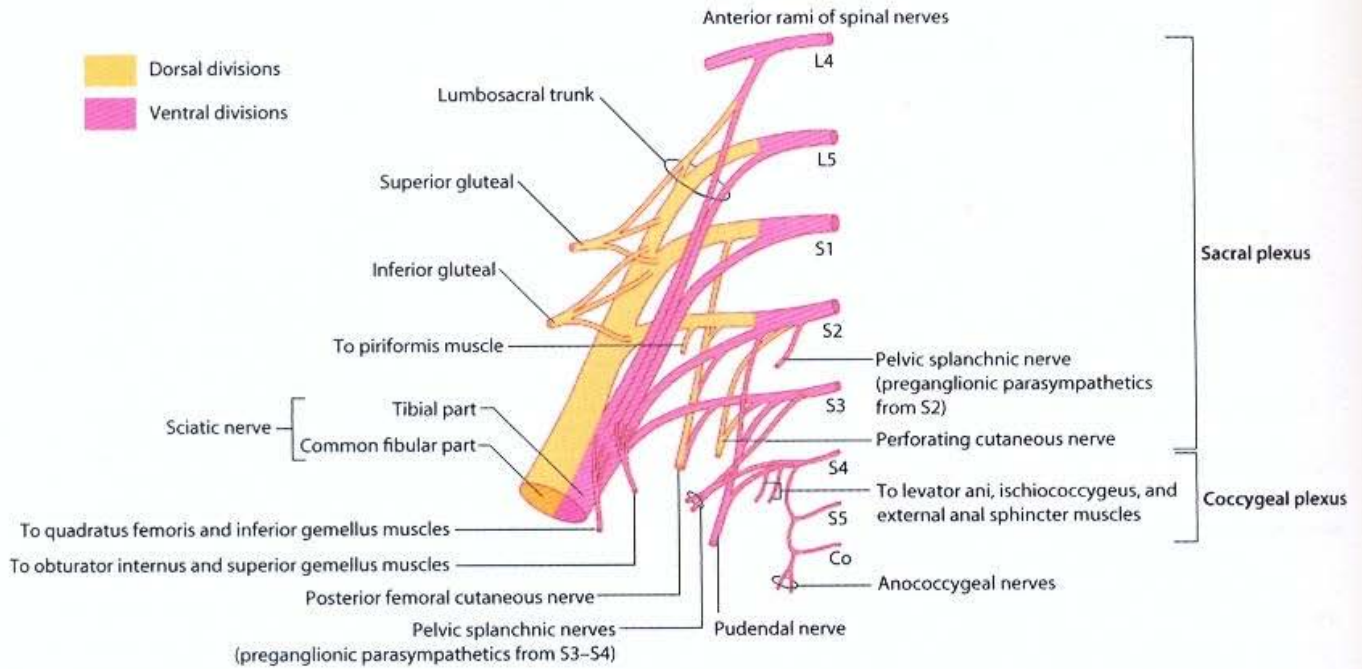


Vasculature of the rectum (posterior view)

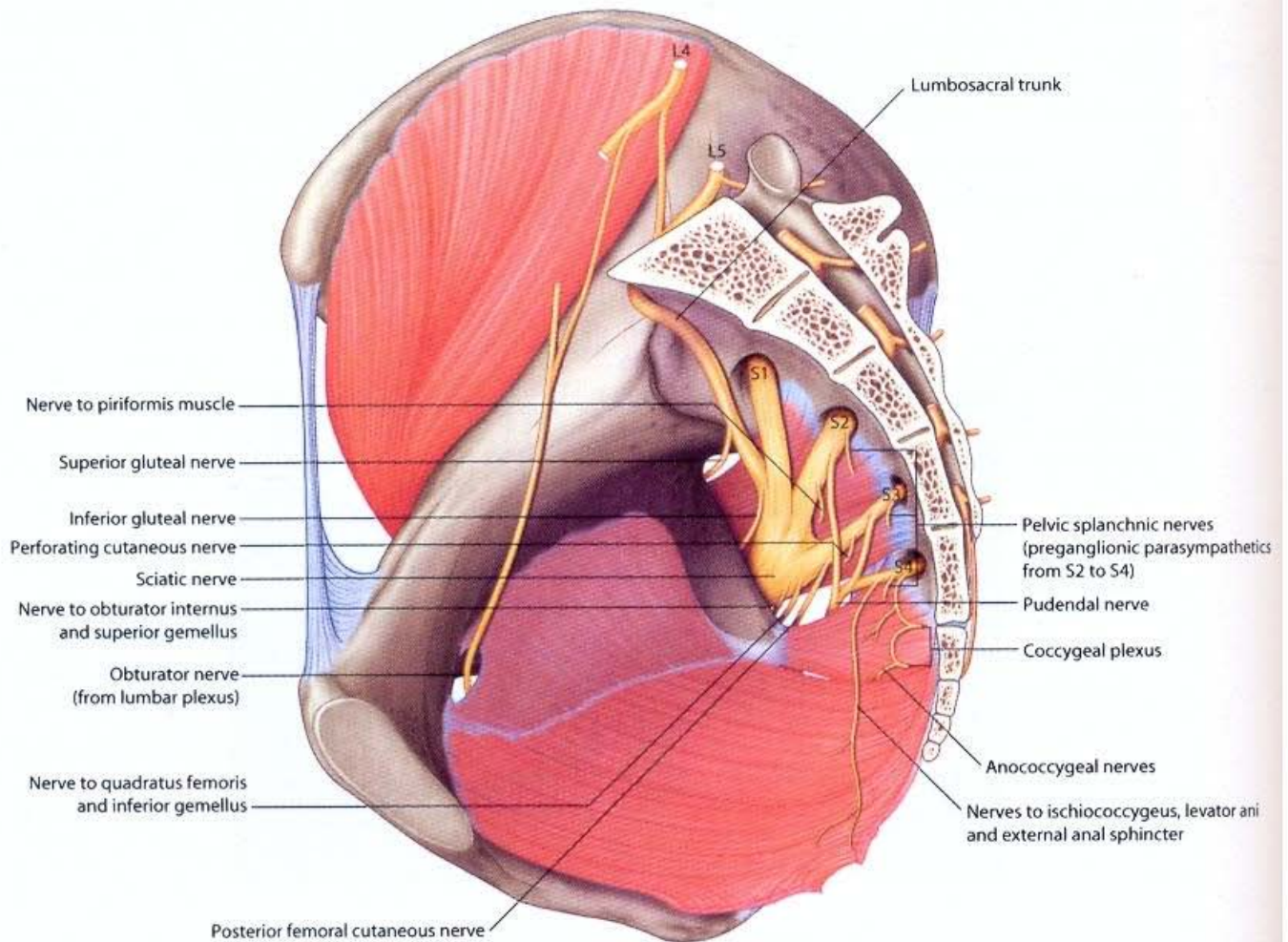


Inferior rectal neurovascular bundle crossing the ischio-anal fossa. T2-weighted MR image in axial plane

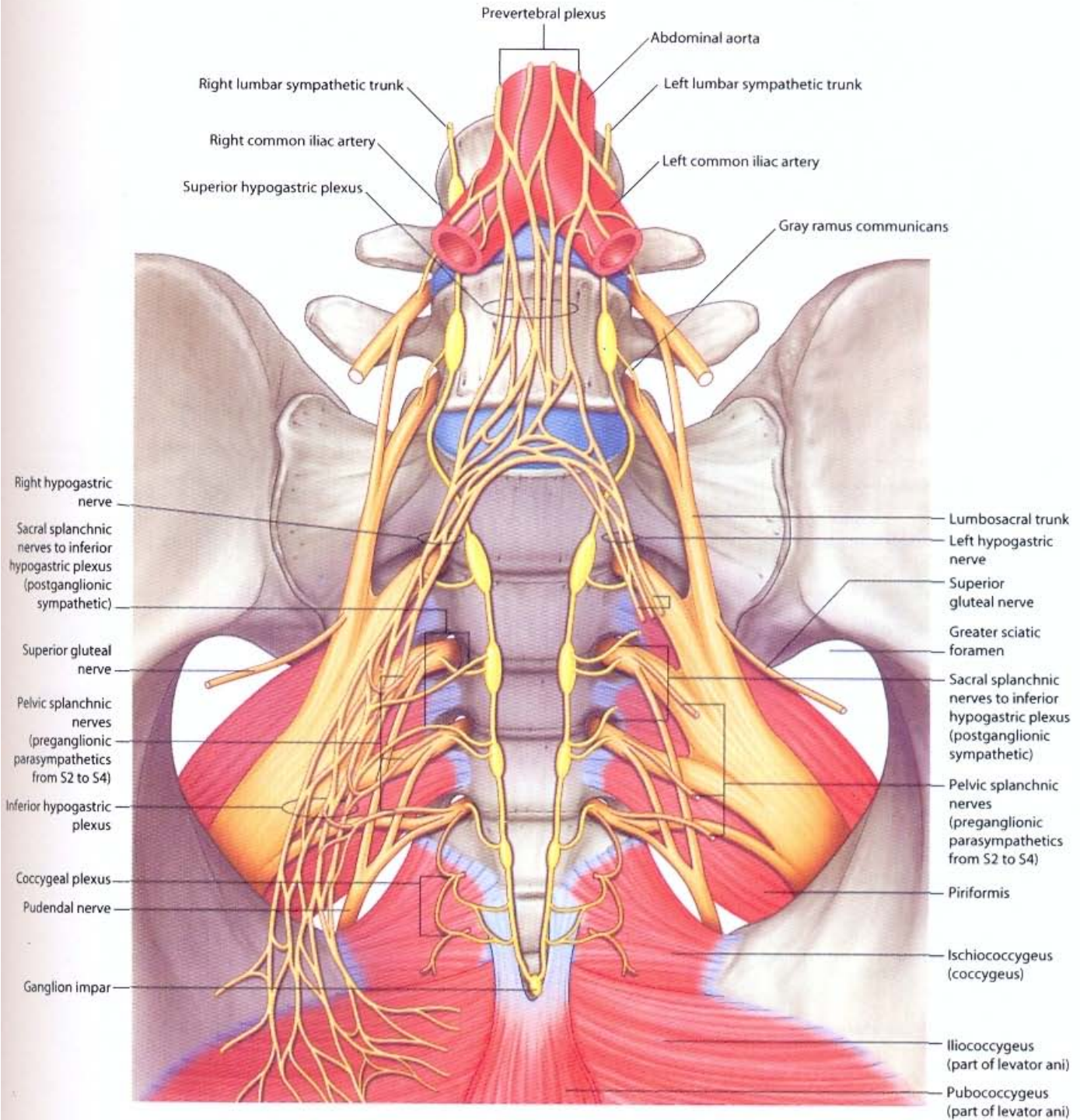
# PELVIS AND PERINEUM • Sacral and coccygeal nerve plexuses



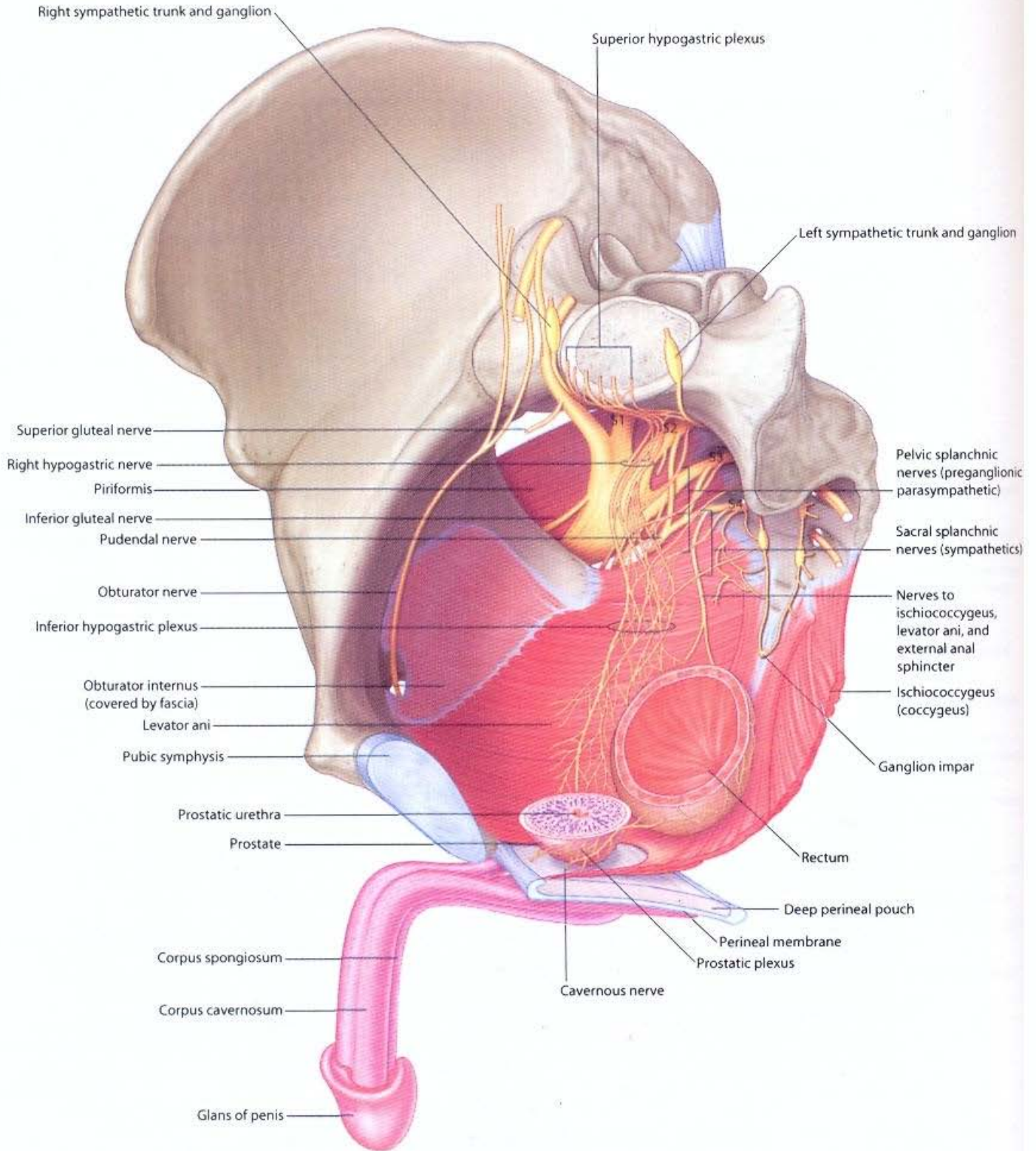
Components and branches of the sacral and coccygeal nerve plexuses



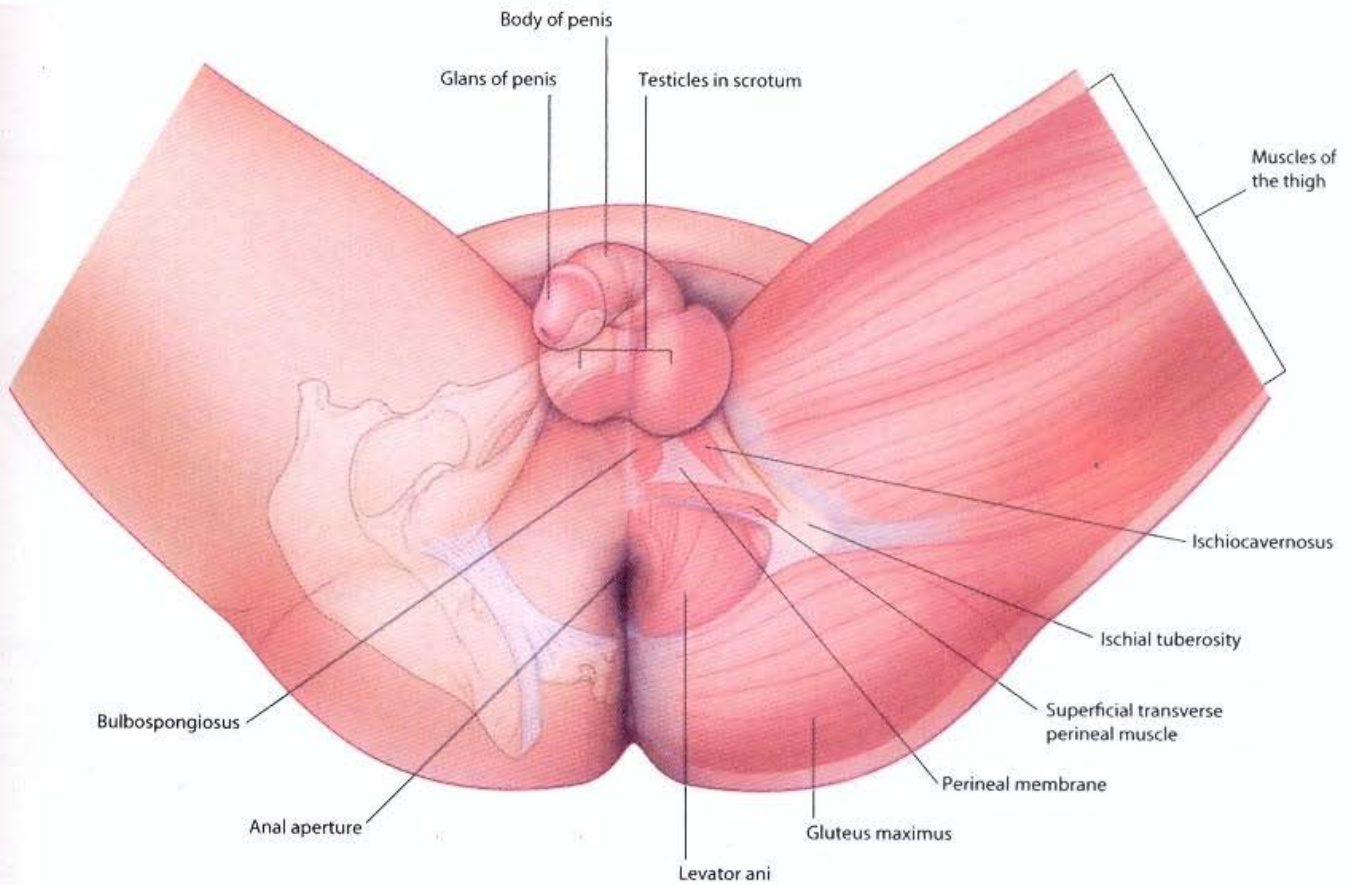
Sacral and coccygeal nerve plexuses within the pelvic cavity (sagittal view)



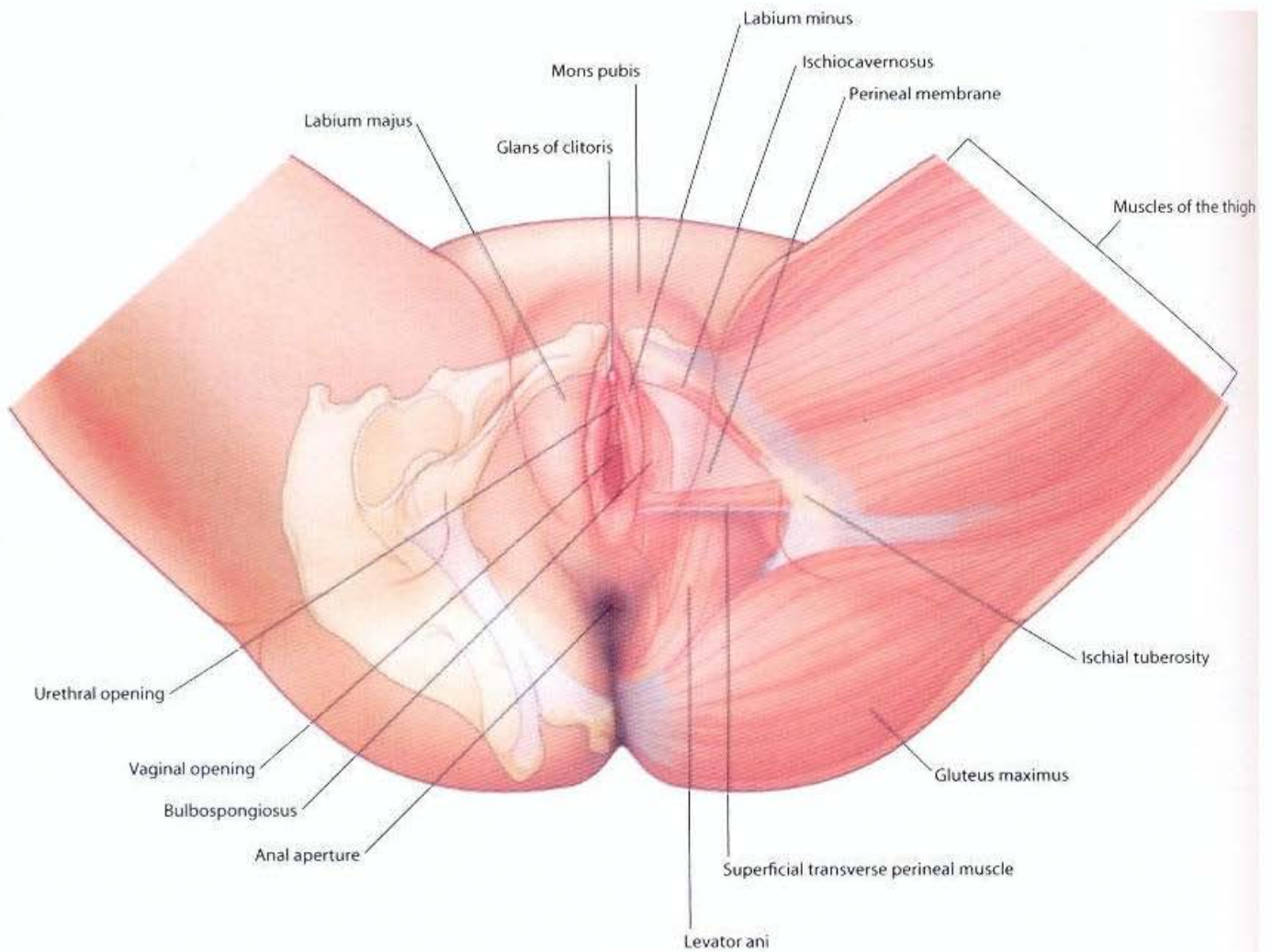
Pelvic extensions of the prevertebral nerve plexus (anterior view)



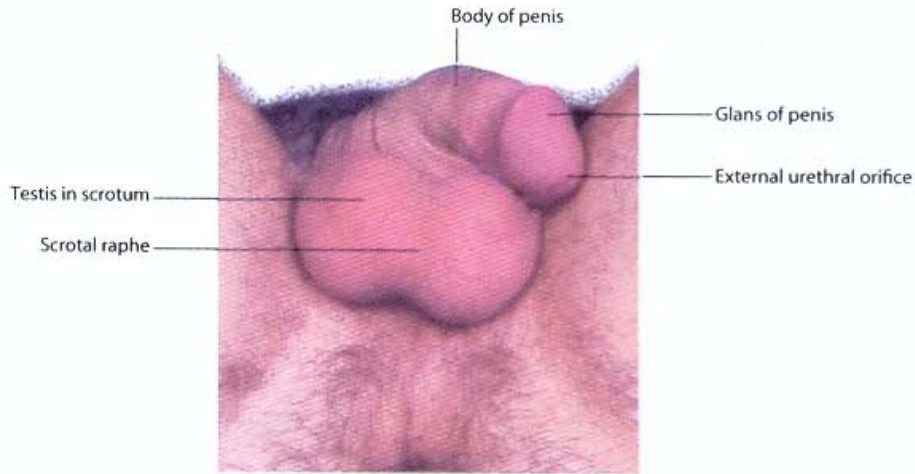
**Hypogastric nerve plexuses (oblique sagittal view)**



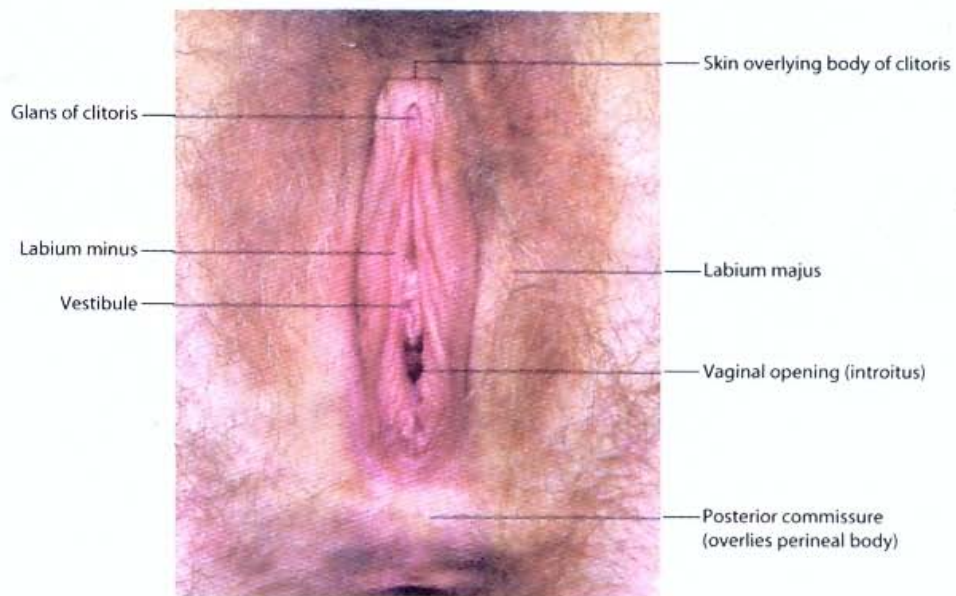
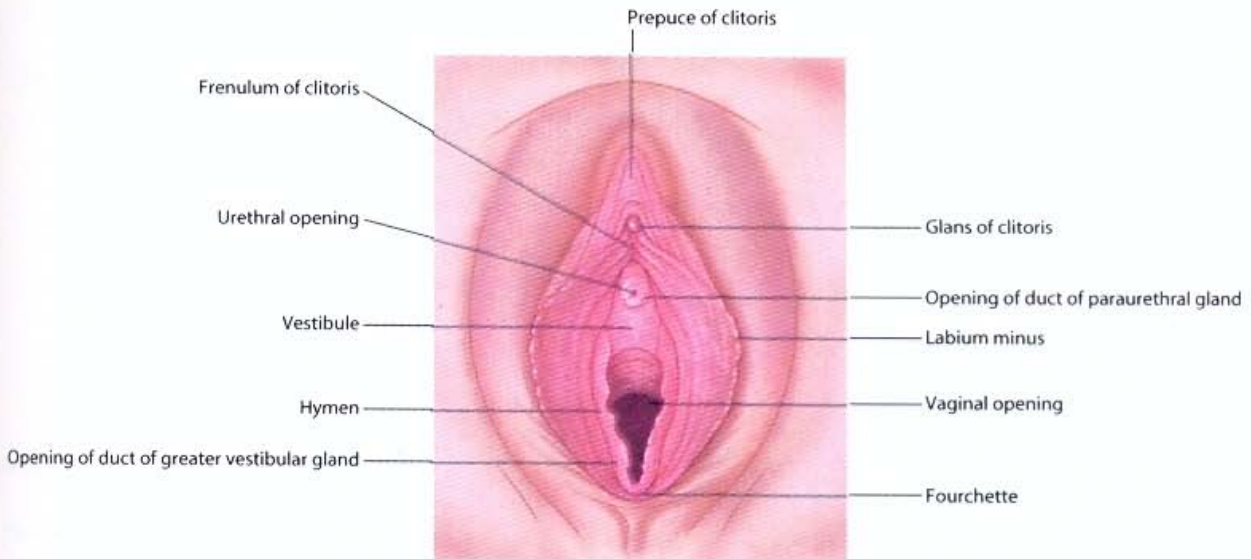
Structures of the perineum in men



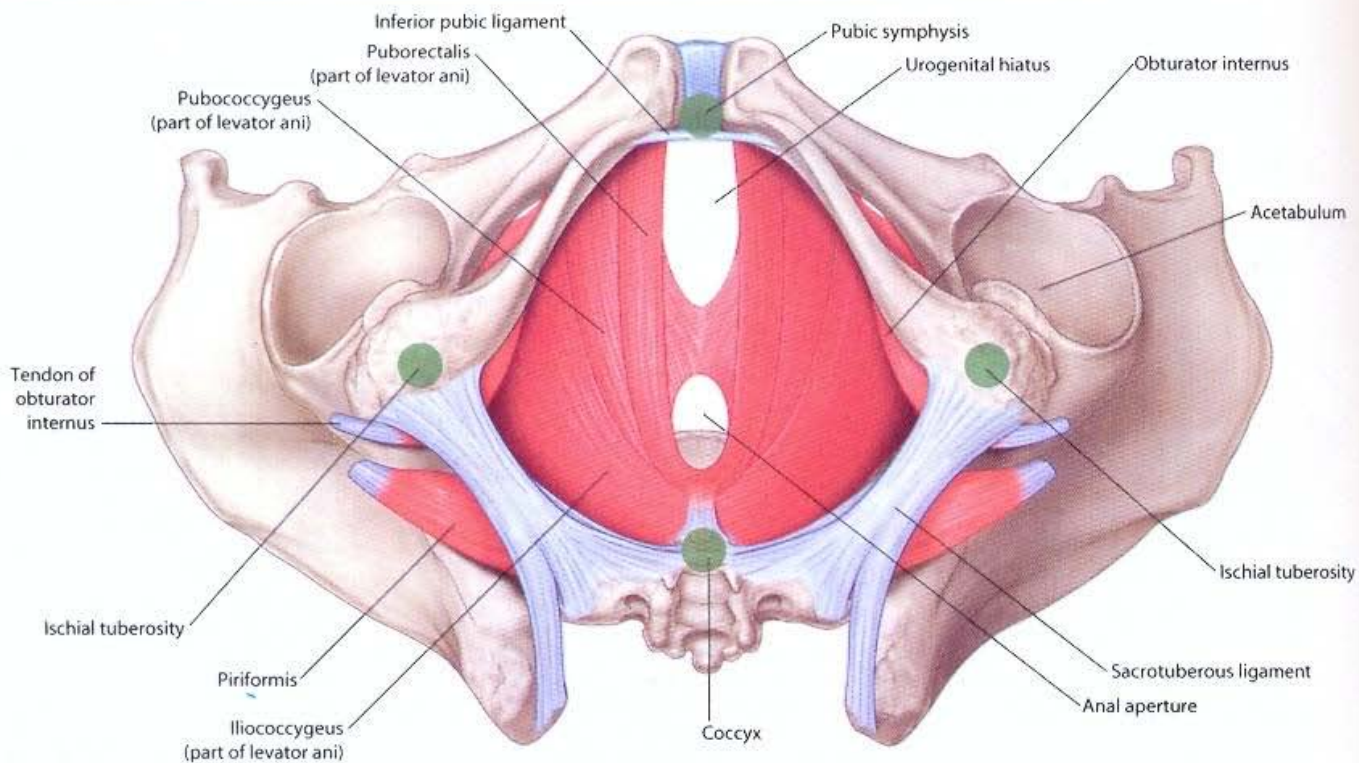
**Structures of the perineum in women**



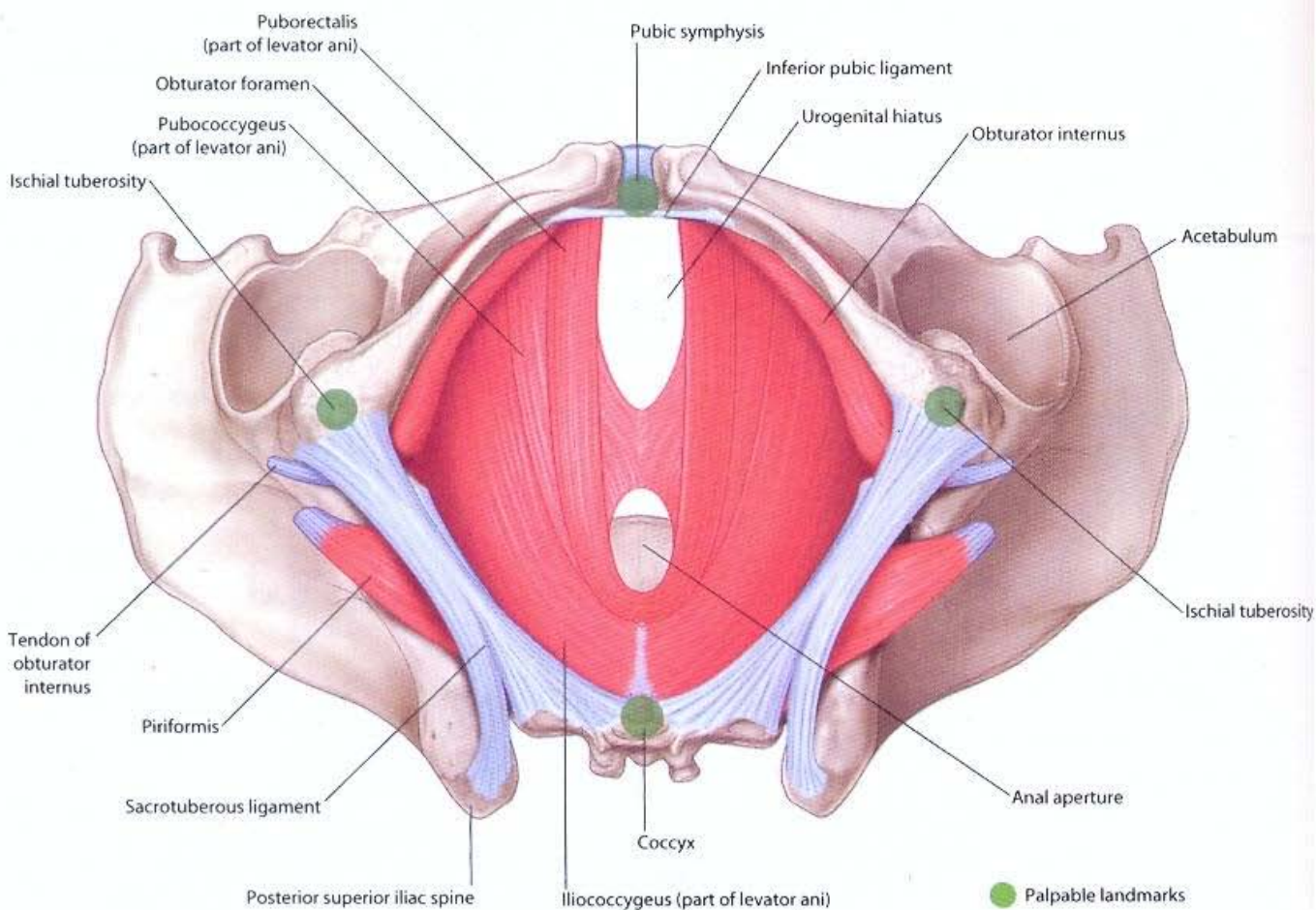
Superficial features of the perineum in men



Superficial features of the perineum in women

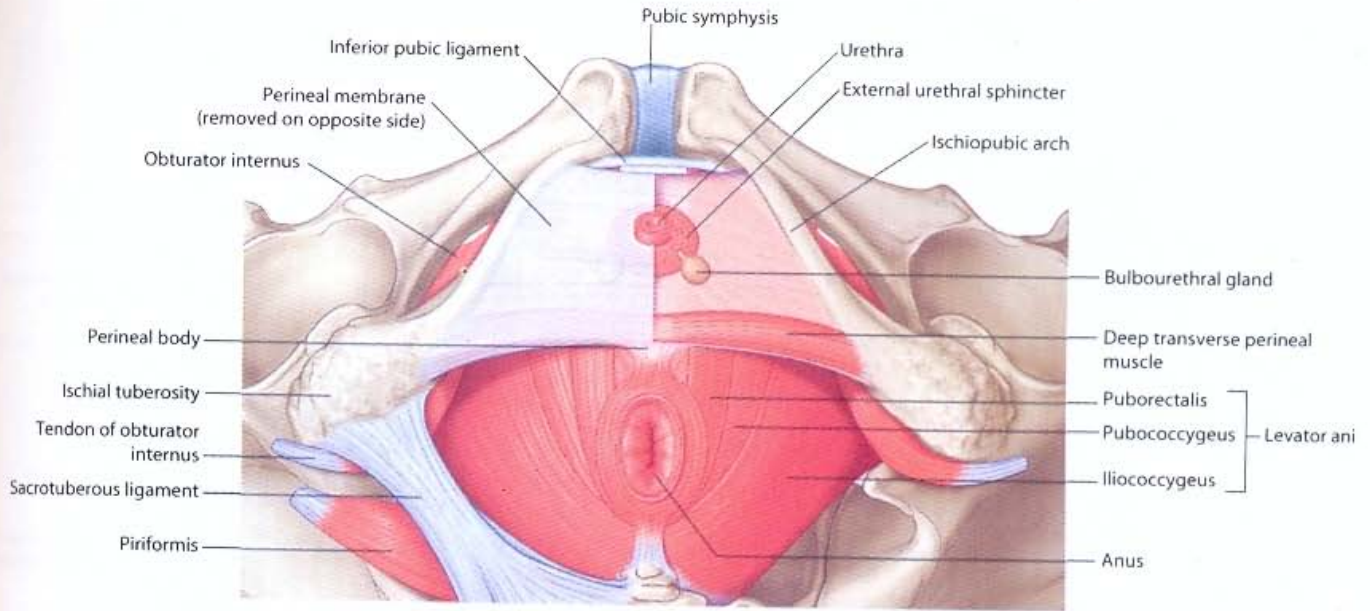


**Borders and ceiling of the perineum in men**

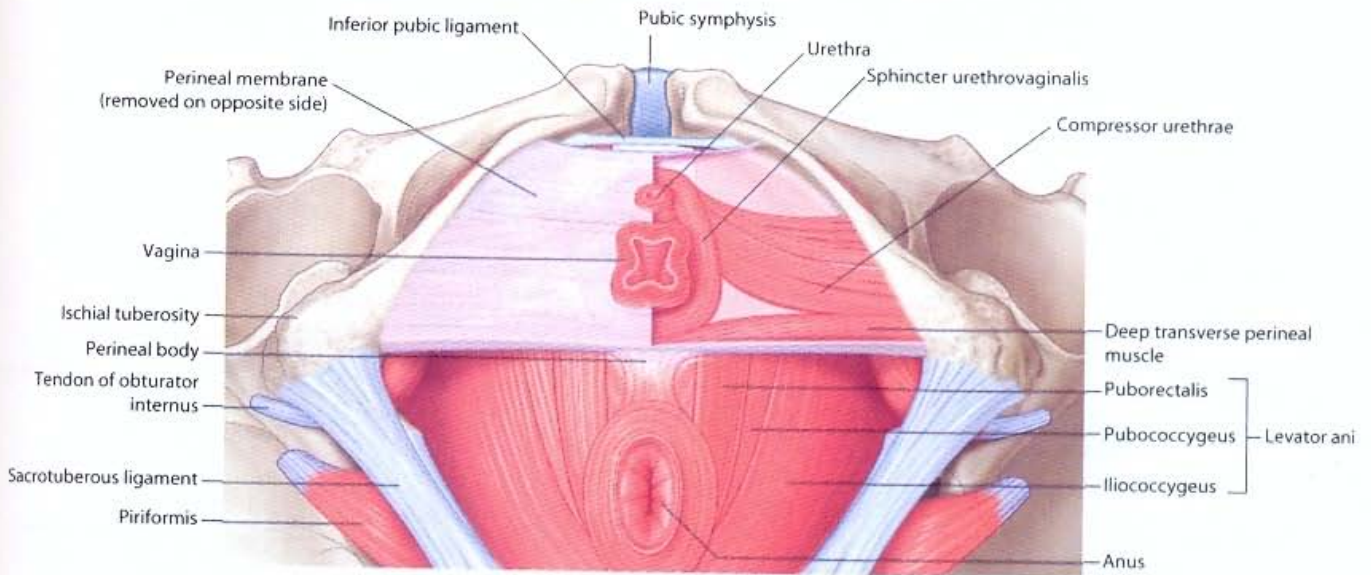


**Borders and ceiling of the perineum in women**

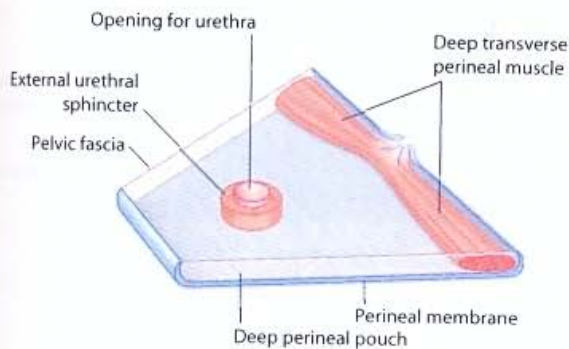




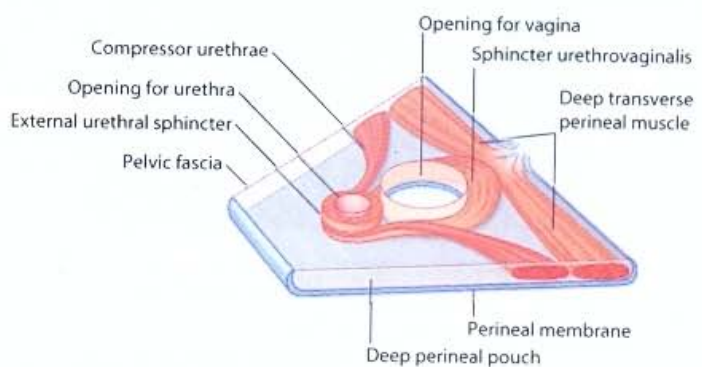
**Muscles of deep perineal pouch in men**  
(perineal membrane removed on left side to expose deep perineal pouch)



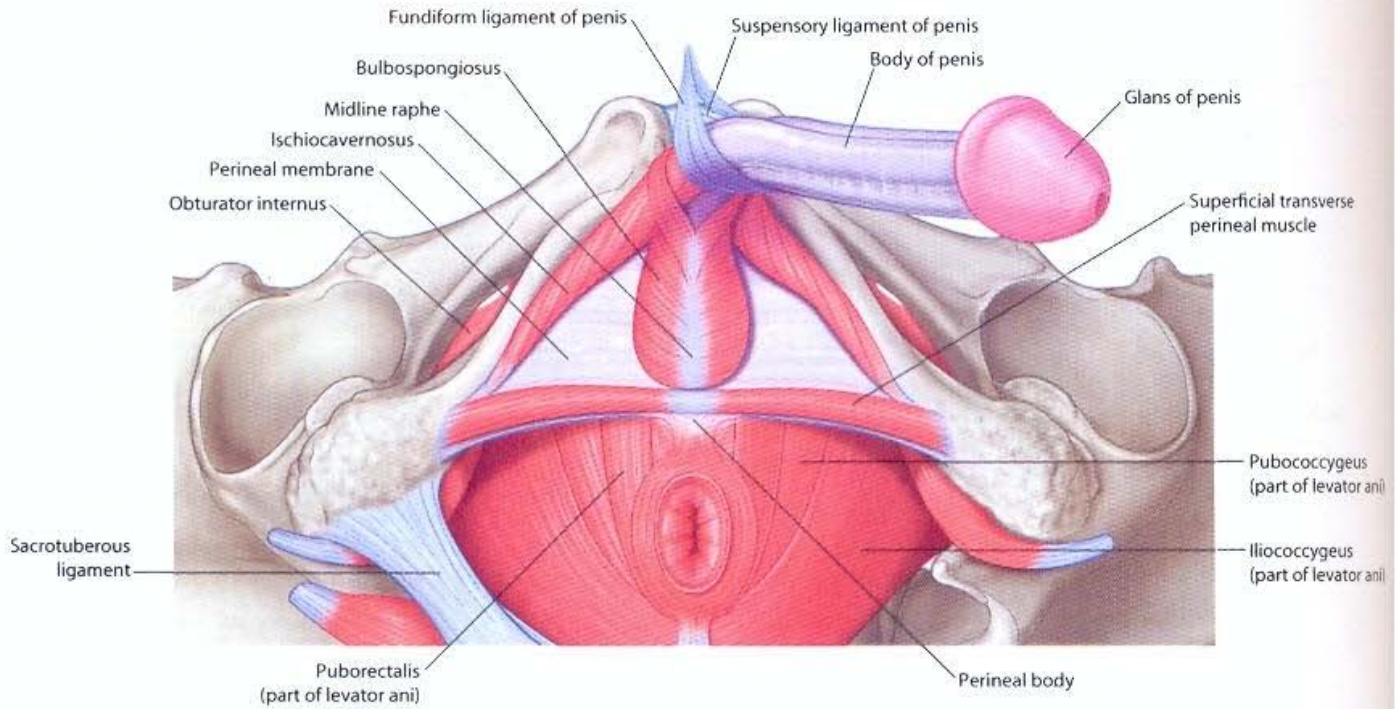
**Muscles of deep perineal pouch in women**  
(perineal membrane removed on left side to expose deep perineal pouch)



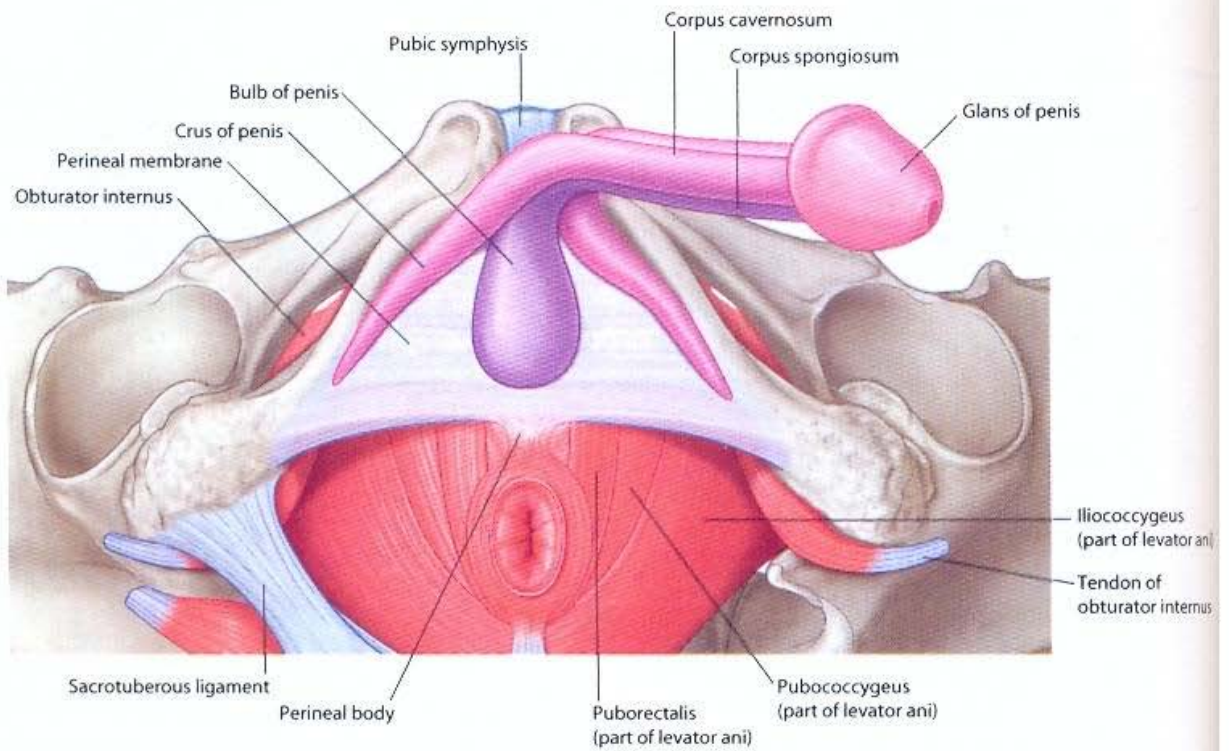
**Muscles of deep perineal pouch in men**



**Muscles of deep perineal pouch in women**



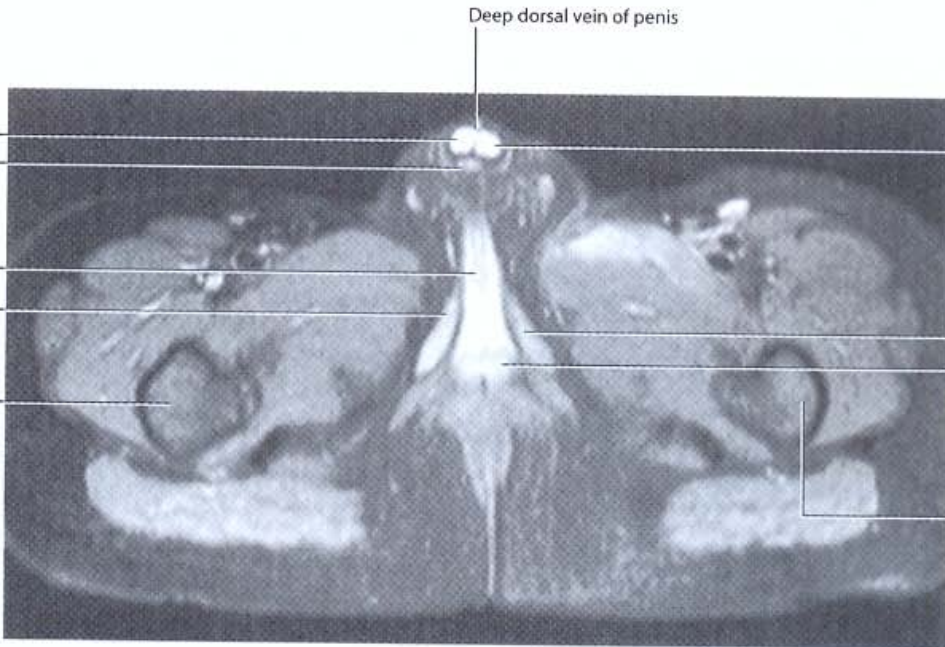
**Muscles of the superficial perineal pouch in men**



**Erectile tissues of the superficial perineal pouch in men**



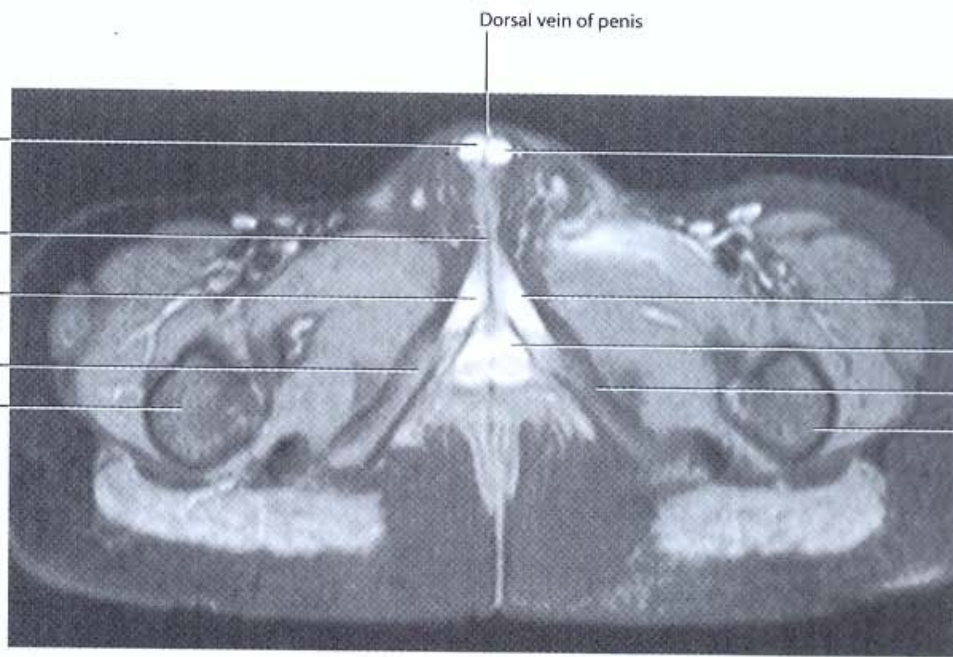
Corpus cavernosum  
 Corpus spongiosum  
 Corpus spongiosum  
 Crus of penis  
 Head of femur



Deep dorsal vein of penis  
 Corpus cavernosum  
 Crus of penis  
 Bulb of penis  
 Head of femur

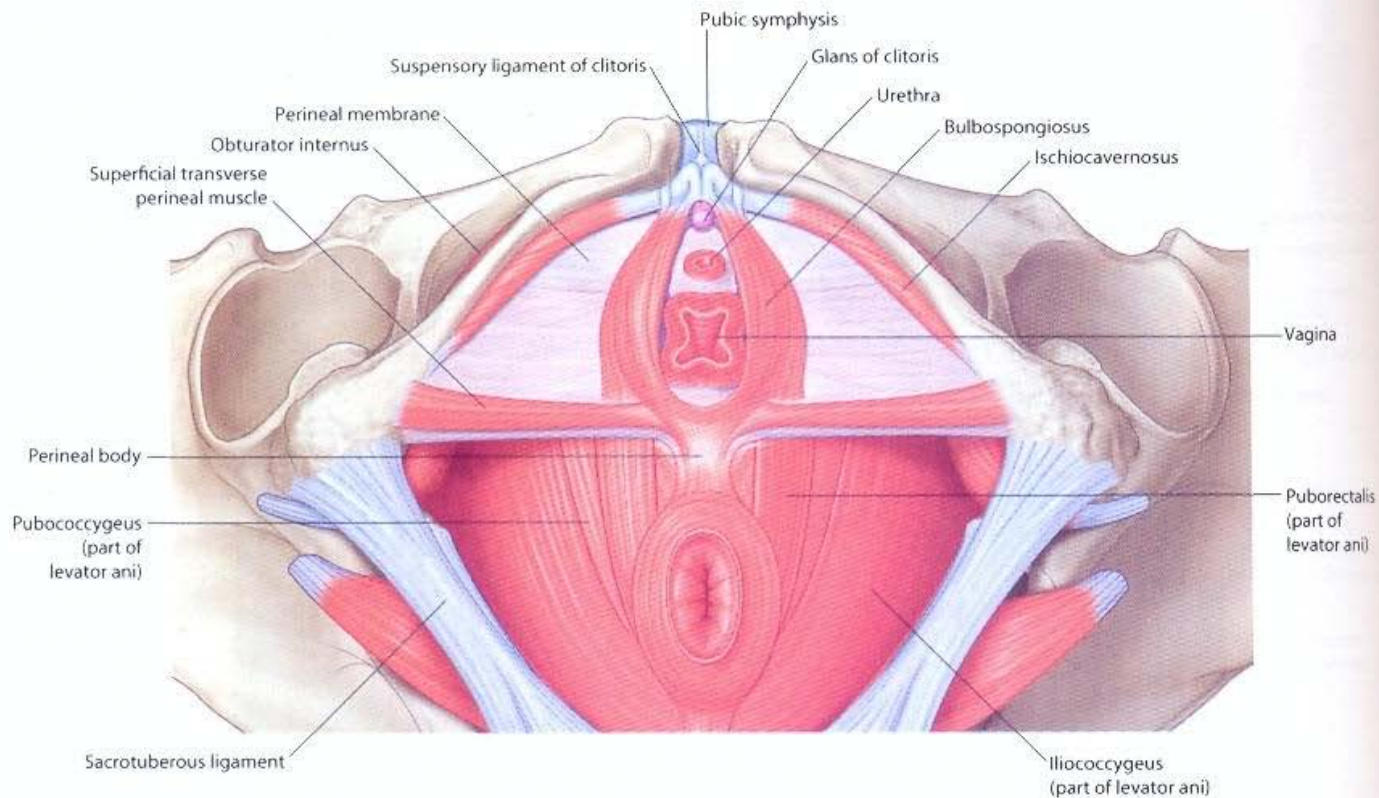
Erectile tissues in relation to other structures in the male perineum.  
 T2-weighted MR image in axial plane

Corpus cavernosum  
 Urethra  
 Crus of penis  
 Ischiopubic ramus  
 Head of femur

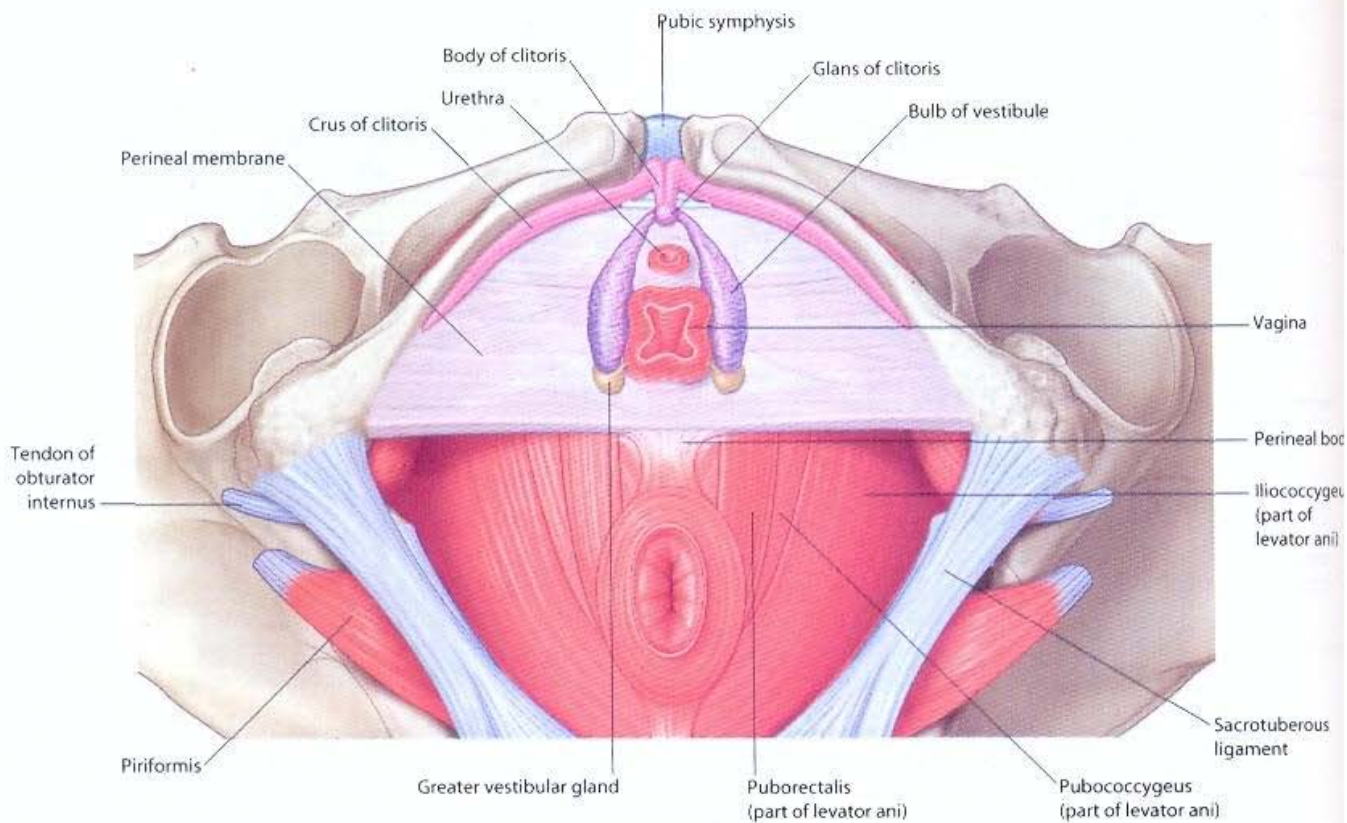


Dorsal vein of penis  
 Corpus cavernosum  
 Crus of penis  
 Bulb of penis  
 Ischiopubic ramus  
 Head of femur

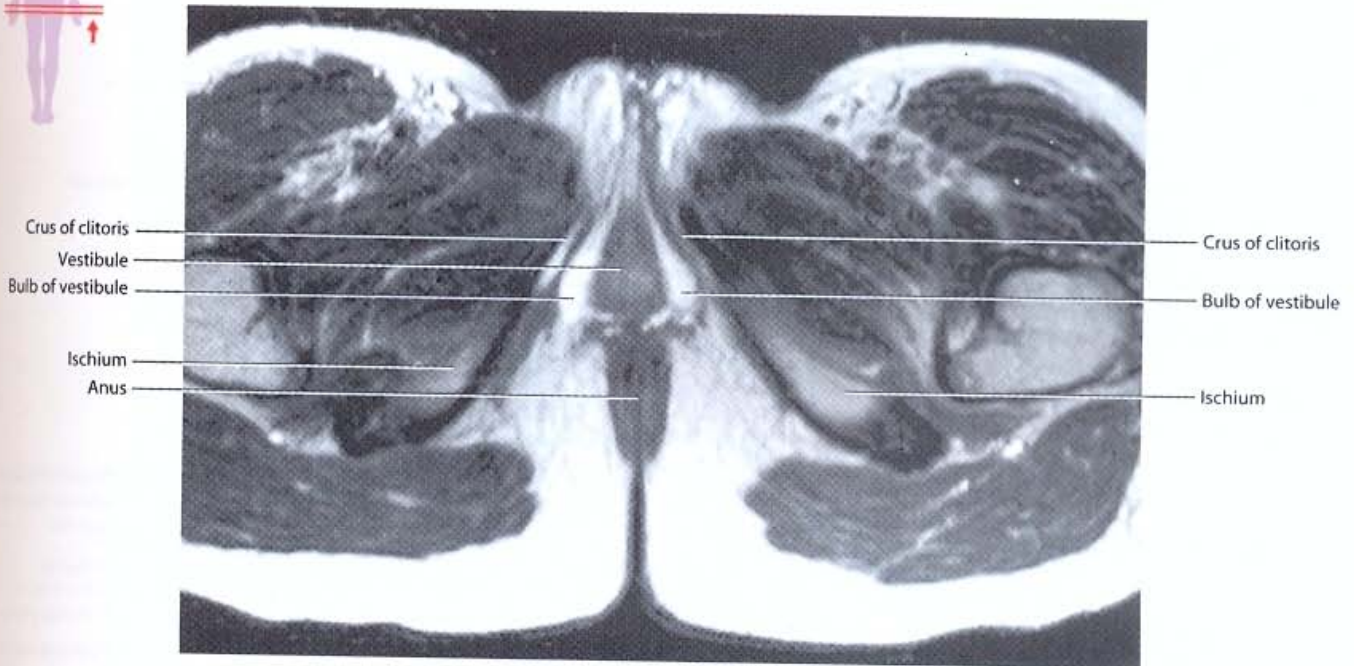
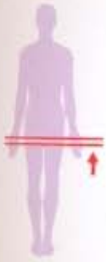Erectile tissues in relation to other structures in the male perineum.  
 T2-weighted MR image in axial plane



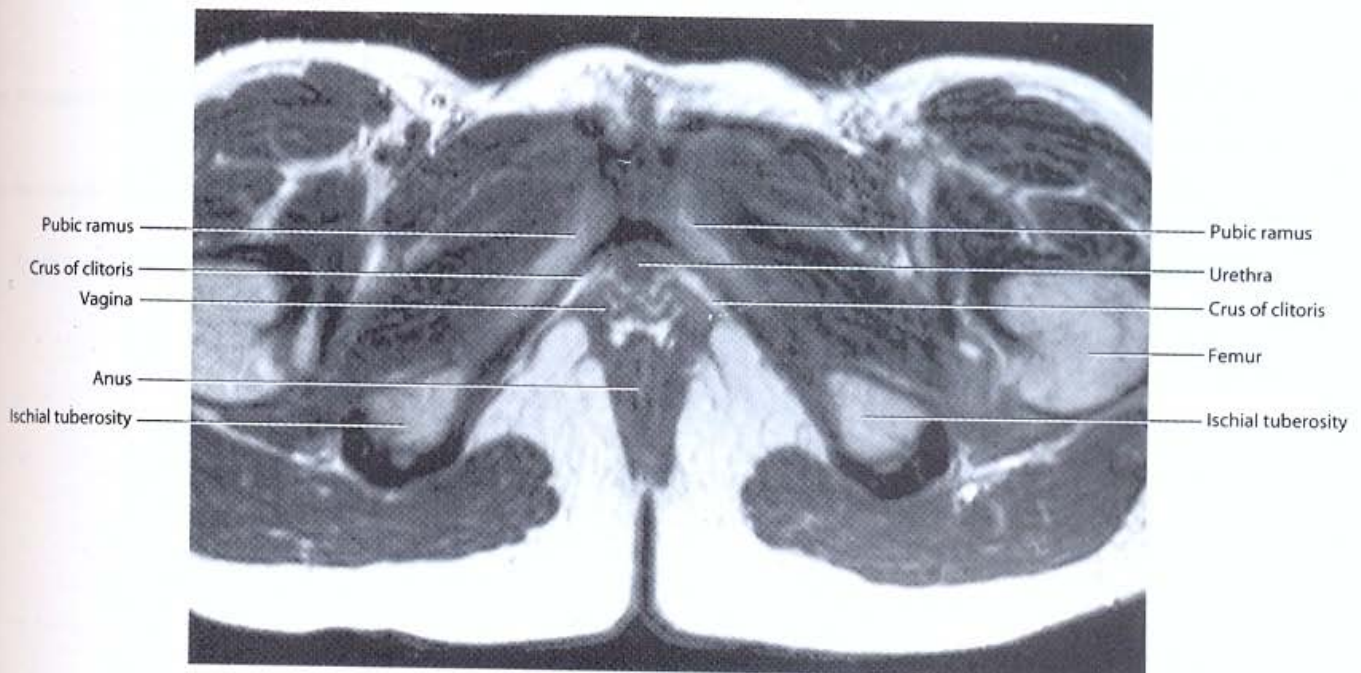**Muscles of the superficial perineal pouch in women**



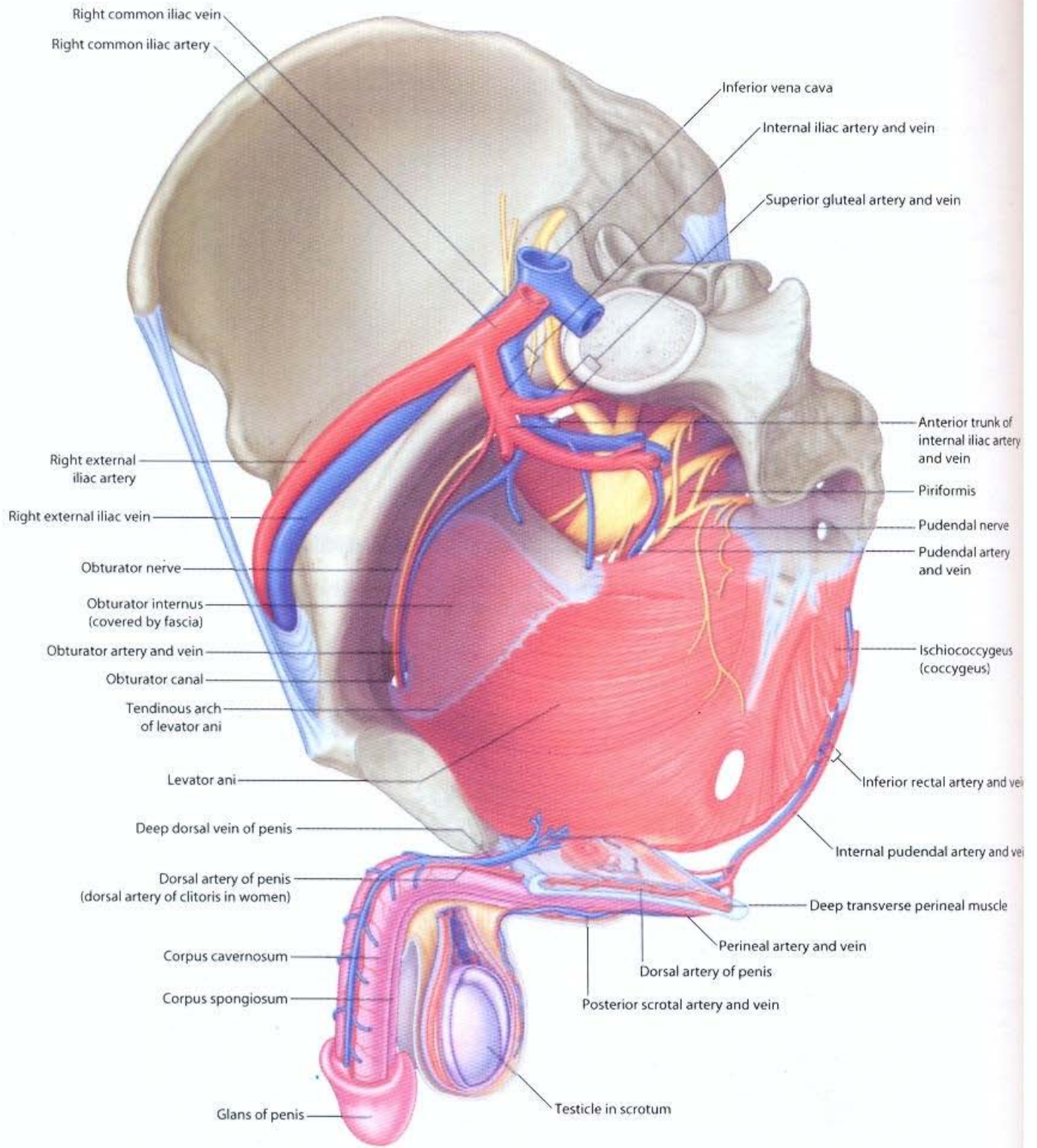
**Erectile tissues of the superficial perineal pouch in women**



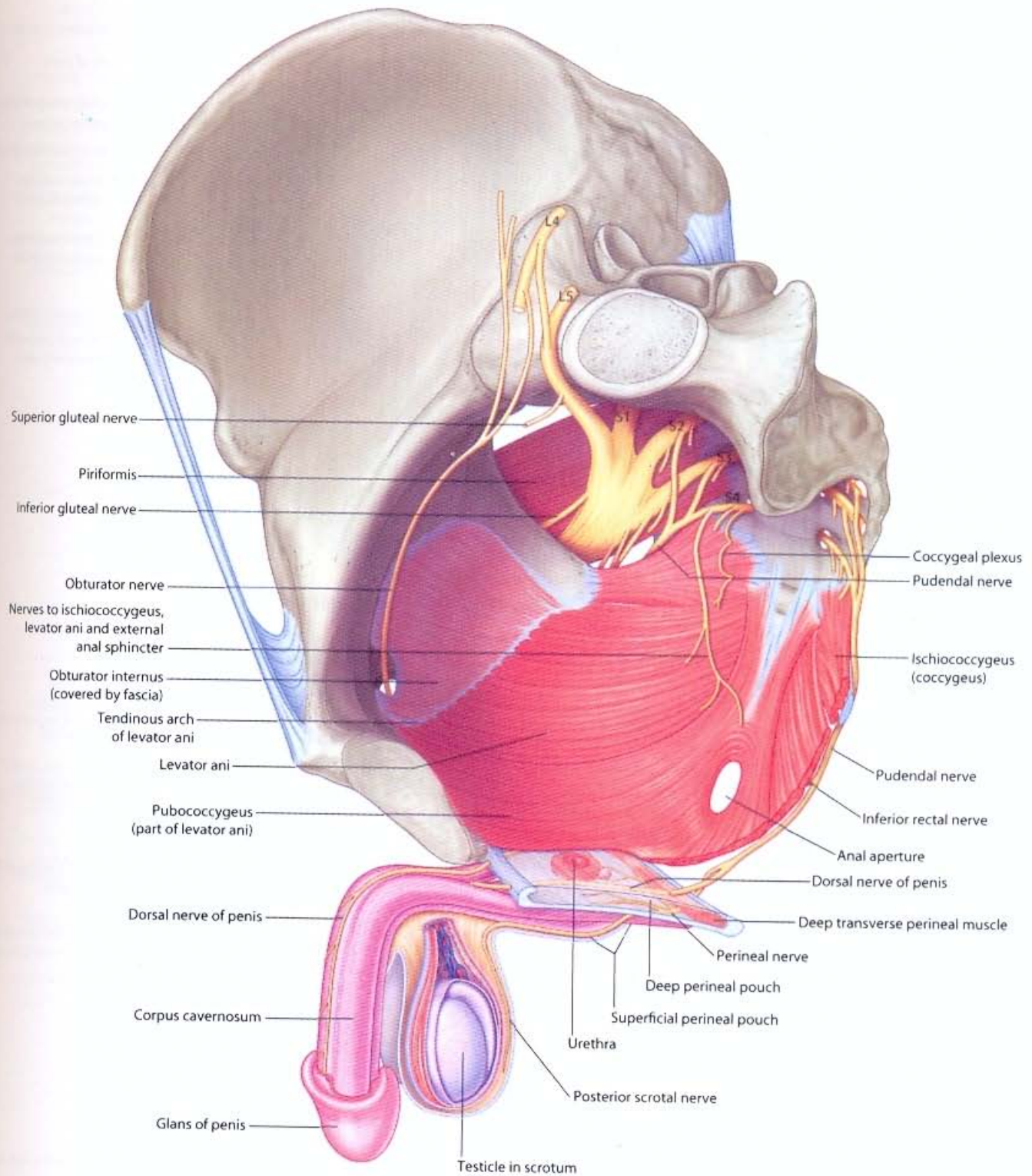
Erectile tissues in relation to other structures in the female perineum.  
T2-weighted MR image in axial plane



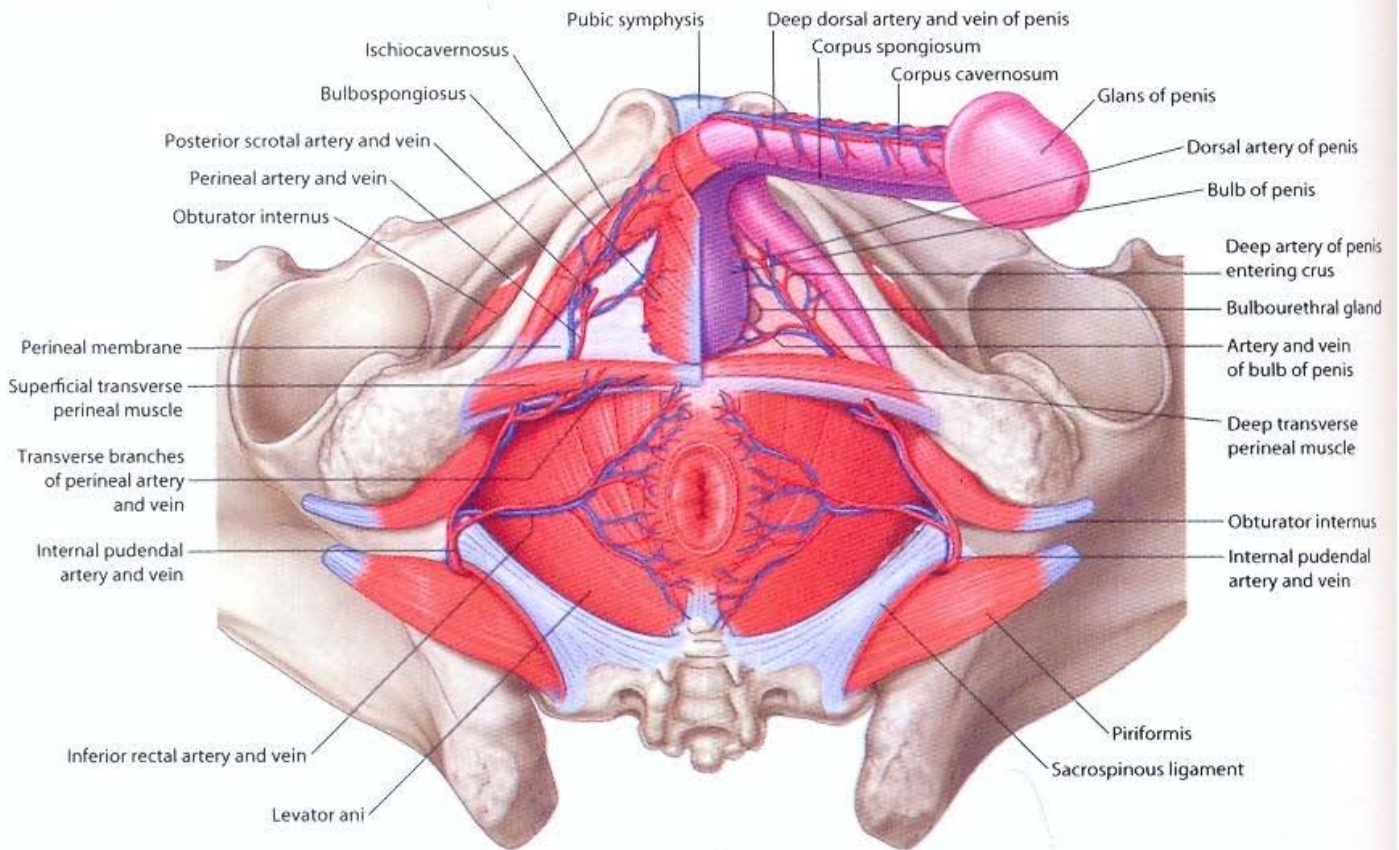
Erectile tissues in relation to other structures in the female perineum.  
T2-weighted MR image in axial plane



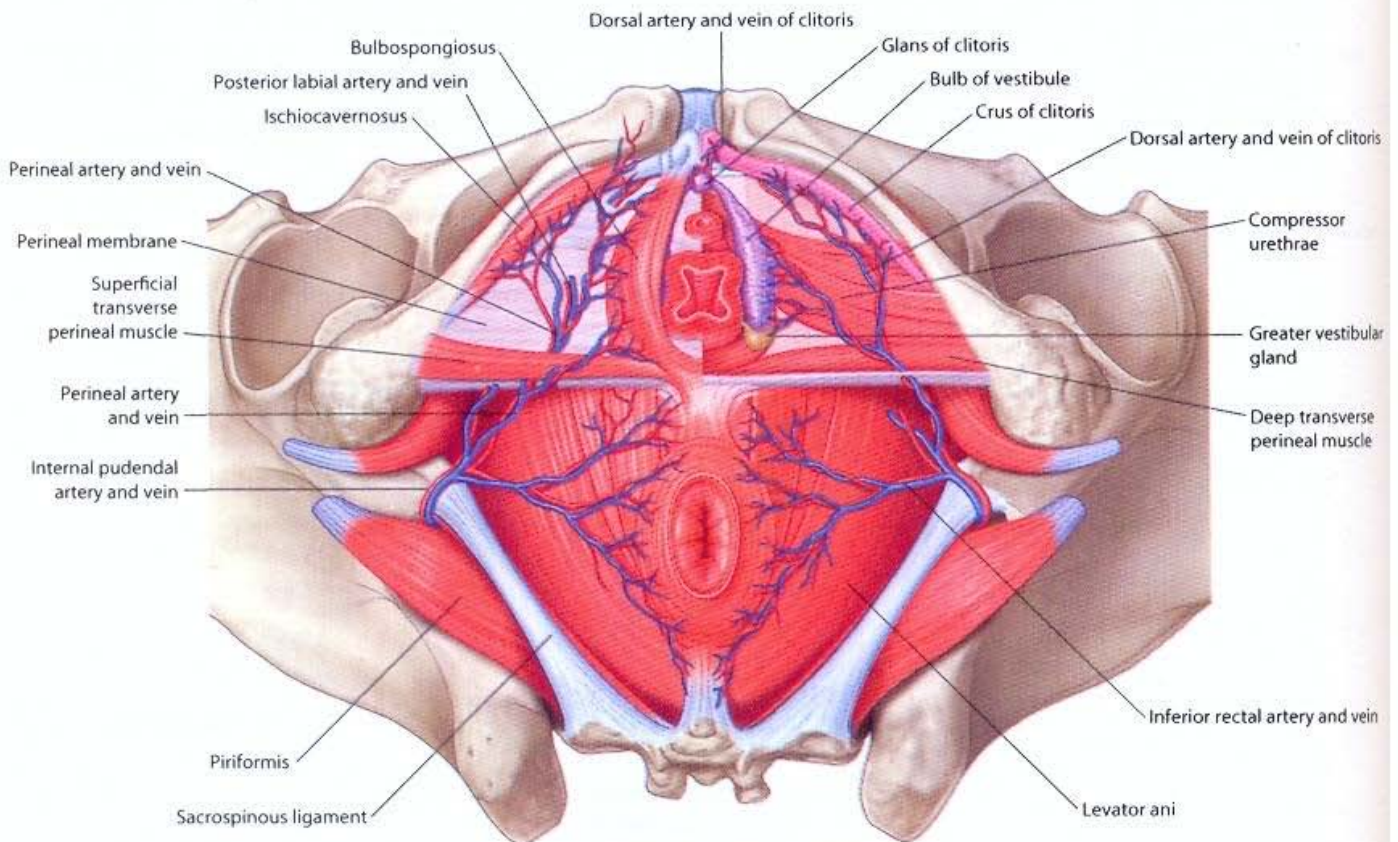
**Course of internal pudendal artery and vein in men (oblique sagittal view)**



Course of pudendal nerve in men (oblique sagittal view)

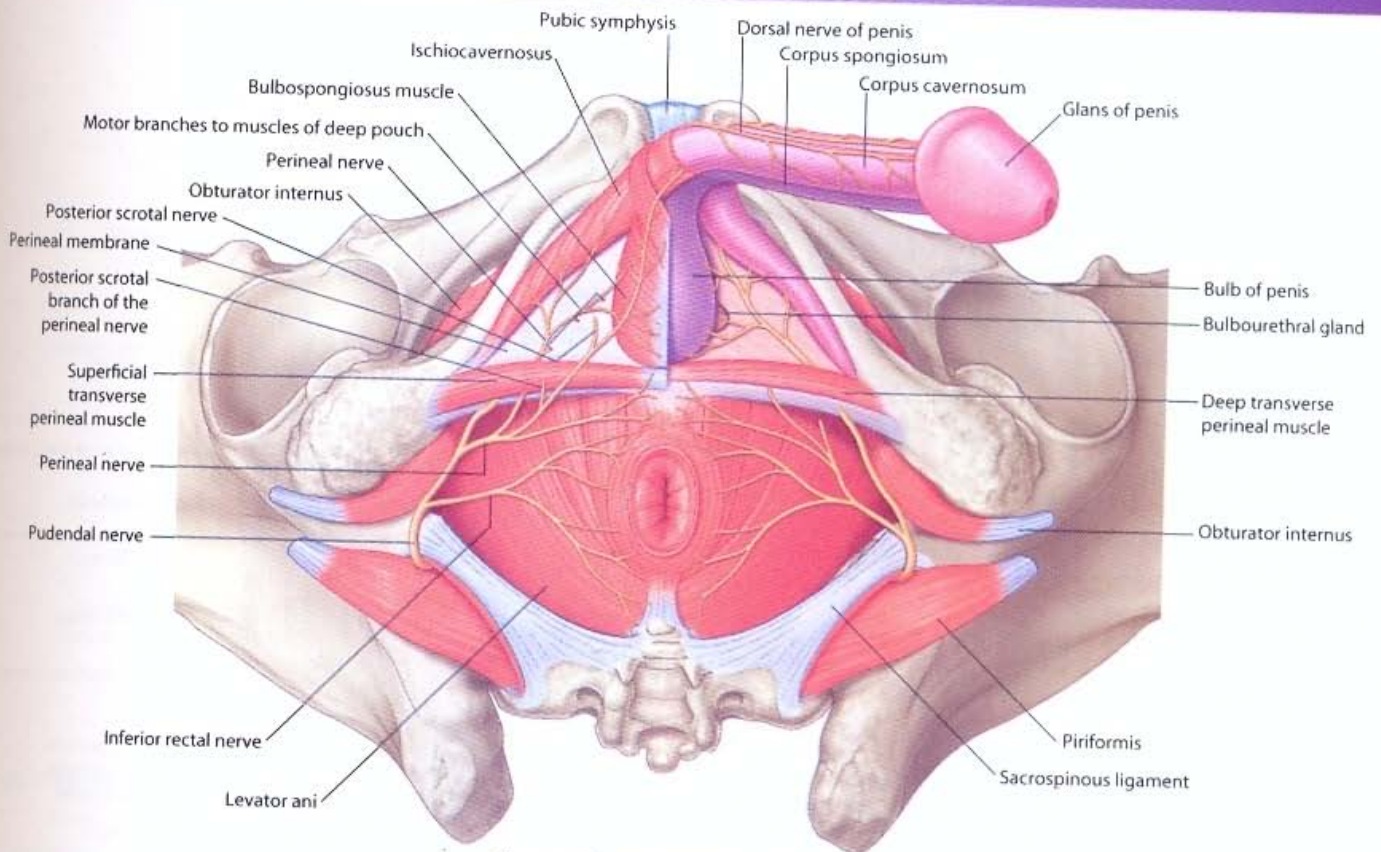


**Arteries and veins of perineum in men**  
(perineal membrane removed on left side to expose deep perineal pouch, inferior view)

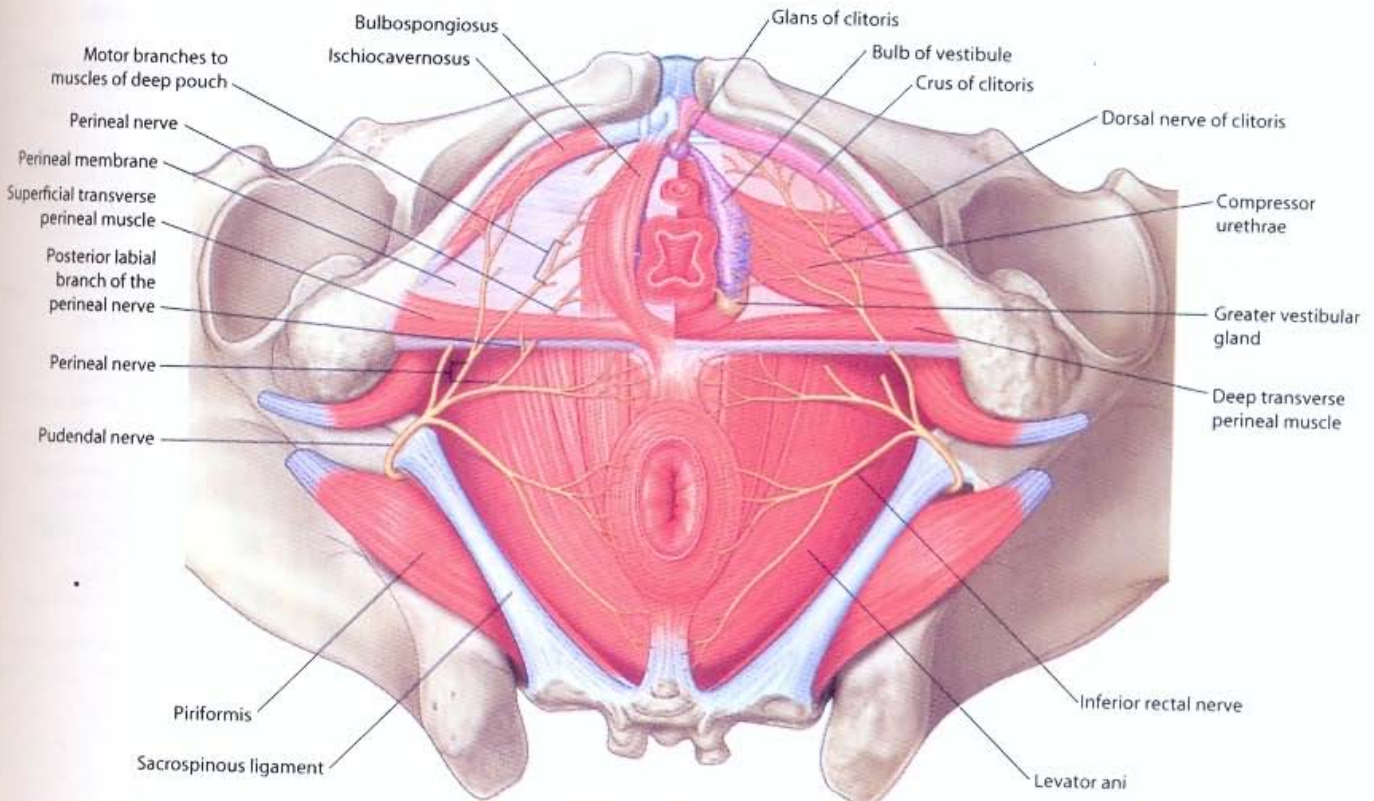


**Arteries and veins of perineum in women**  
(perineal membrane removed on left side to expose deep perineal pouch, inferior view)



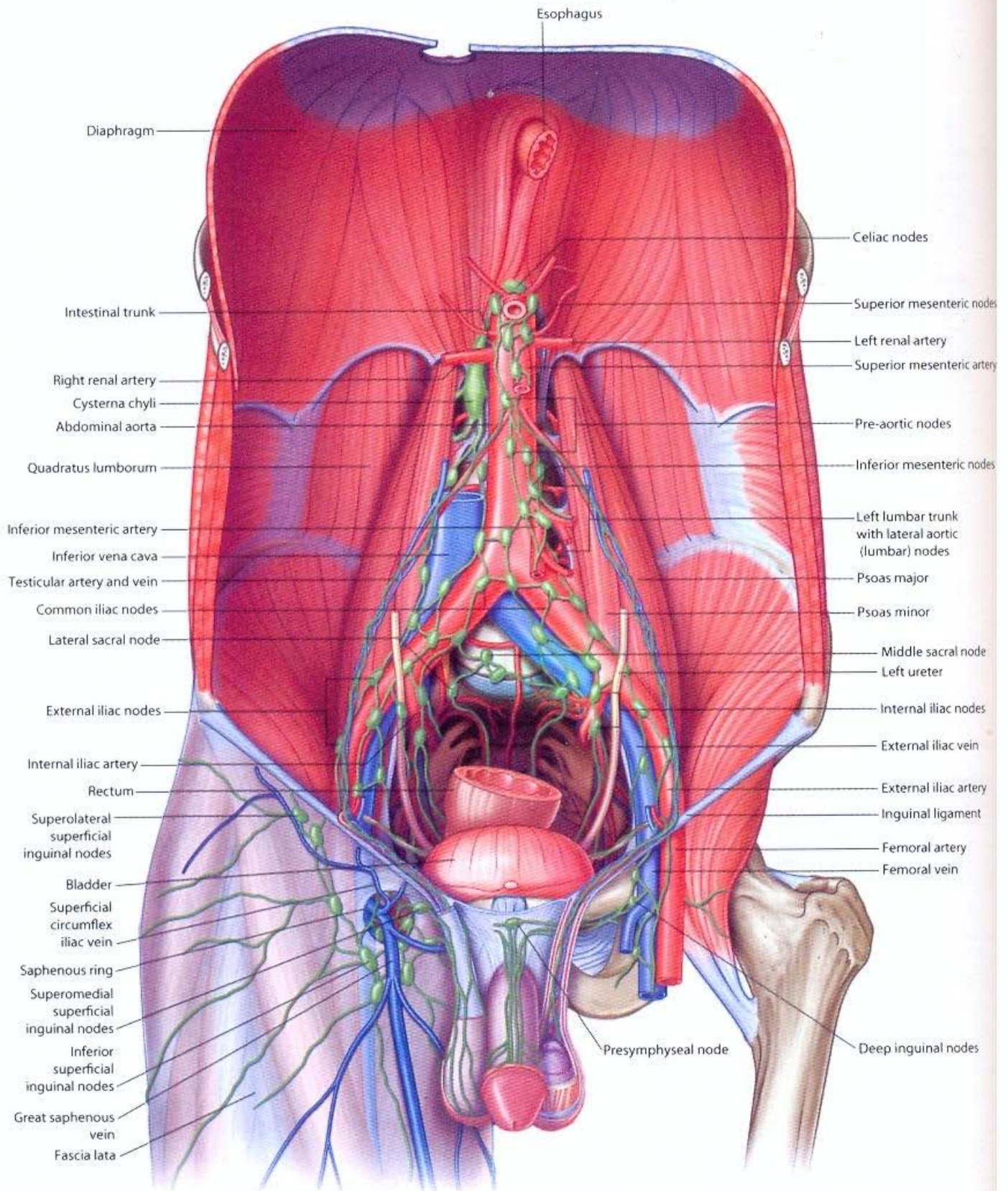


**Nerves of the perineum in men**  
(perineal membrane removed on left side to expose deep perineal pouch, inferior view)

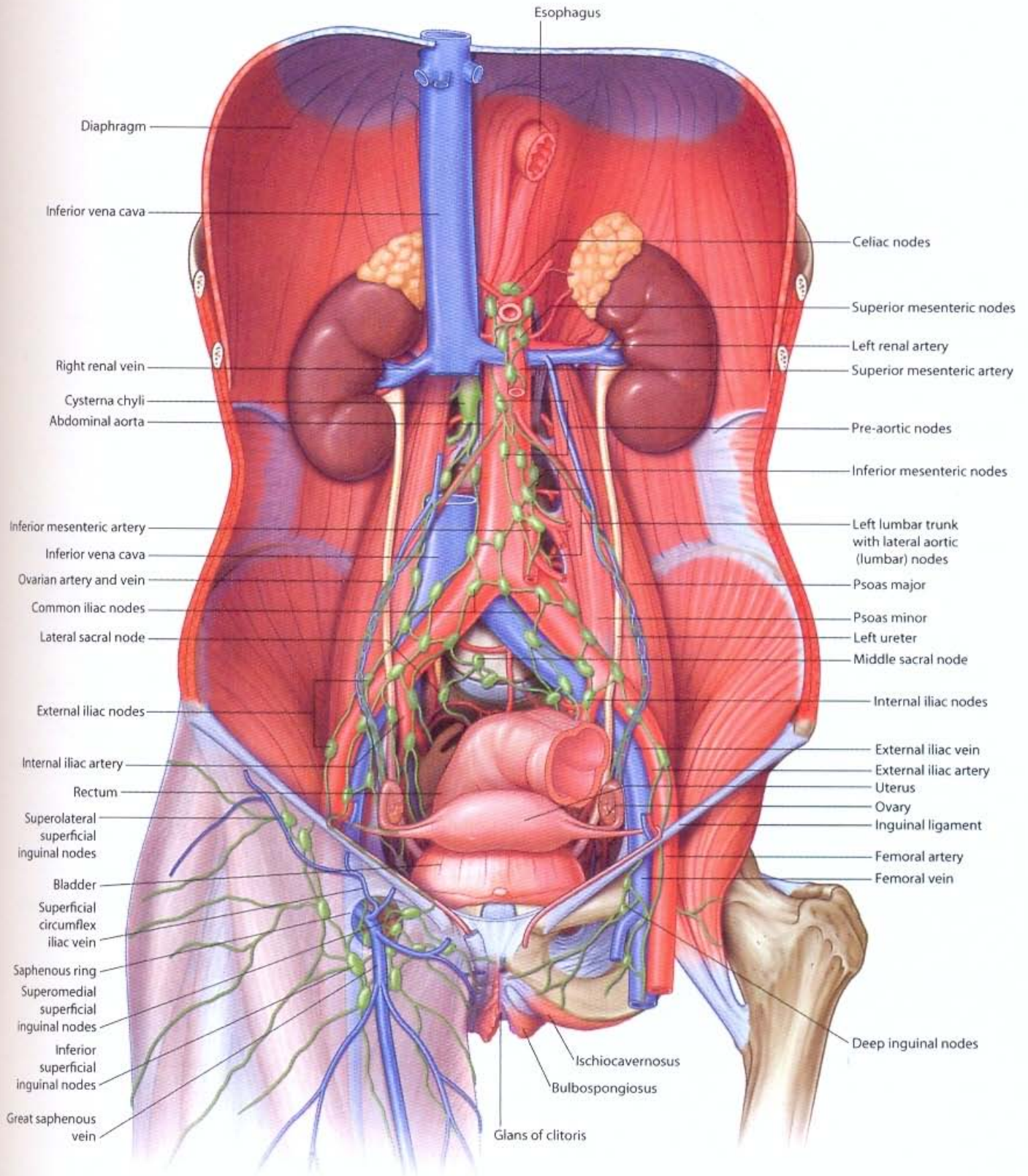


**Nerves of the perineum in women**  
(perineal membrane removed on left side to expose deep perineal pouch, inferior view)

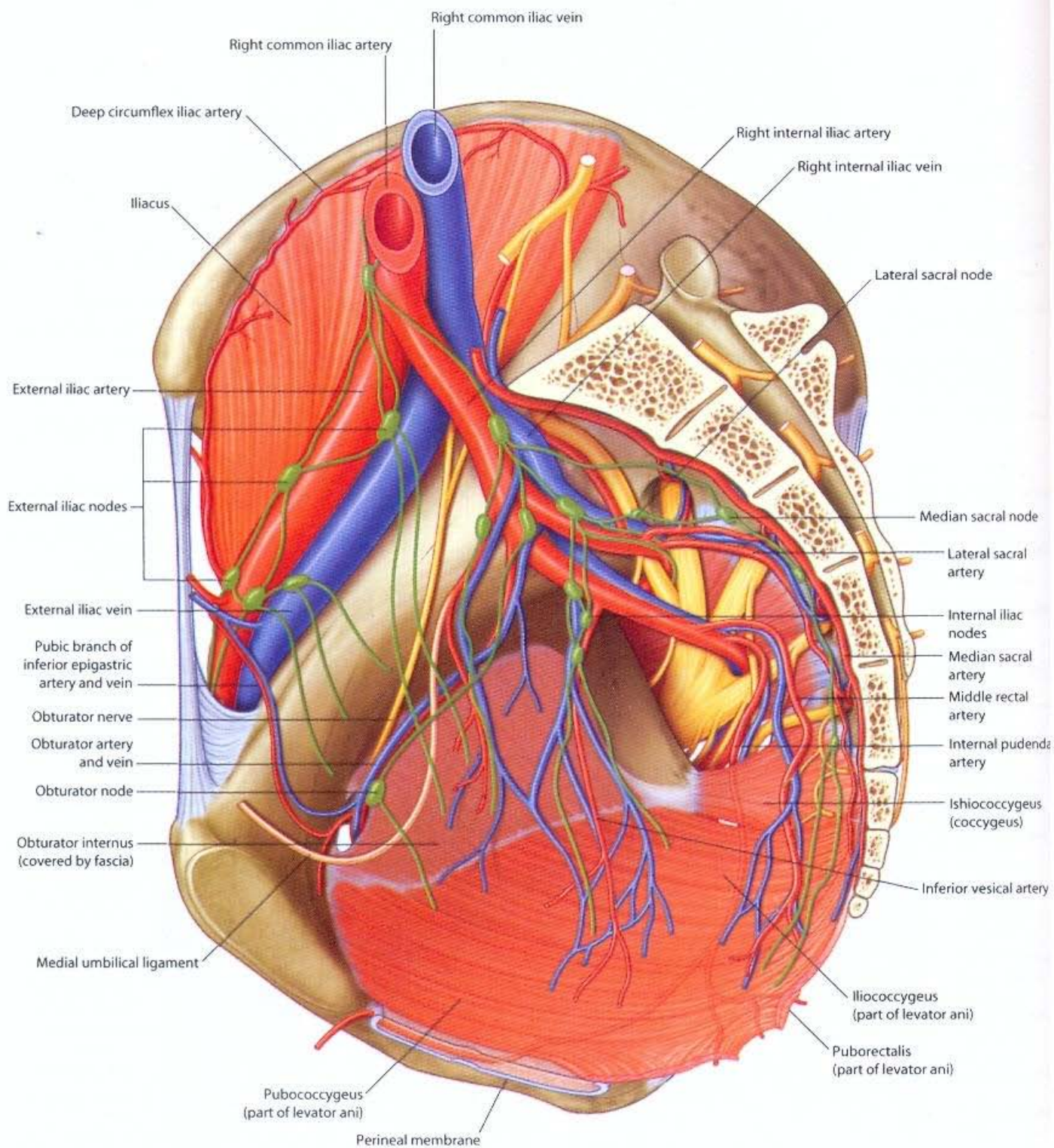
# PELVIS AND PERINEUM • *Lymphatics of pelvis and perineum in men*



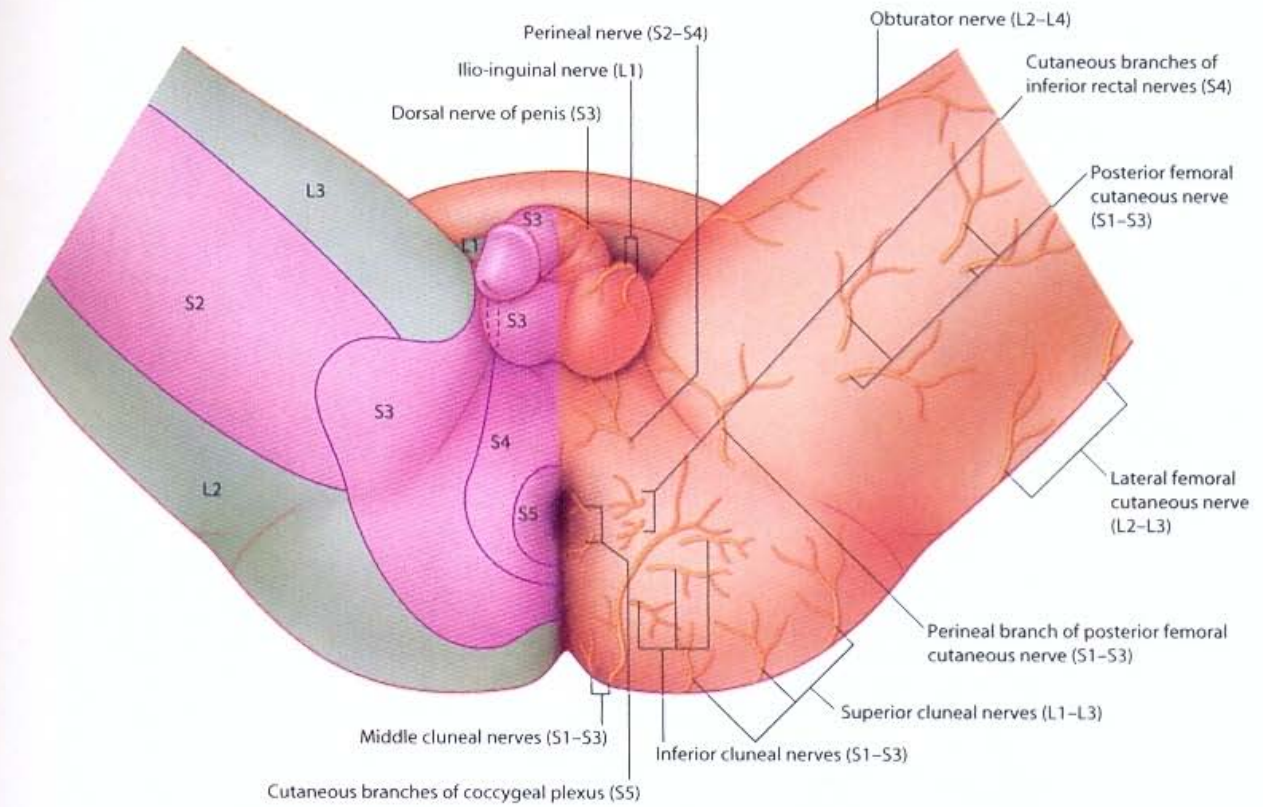
Lymphatics of pelvis and perineum in men



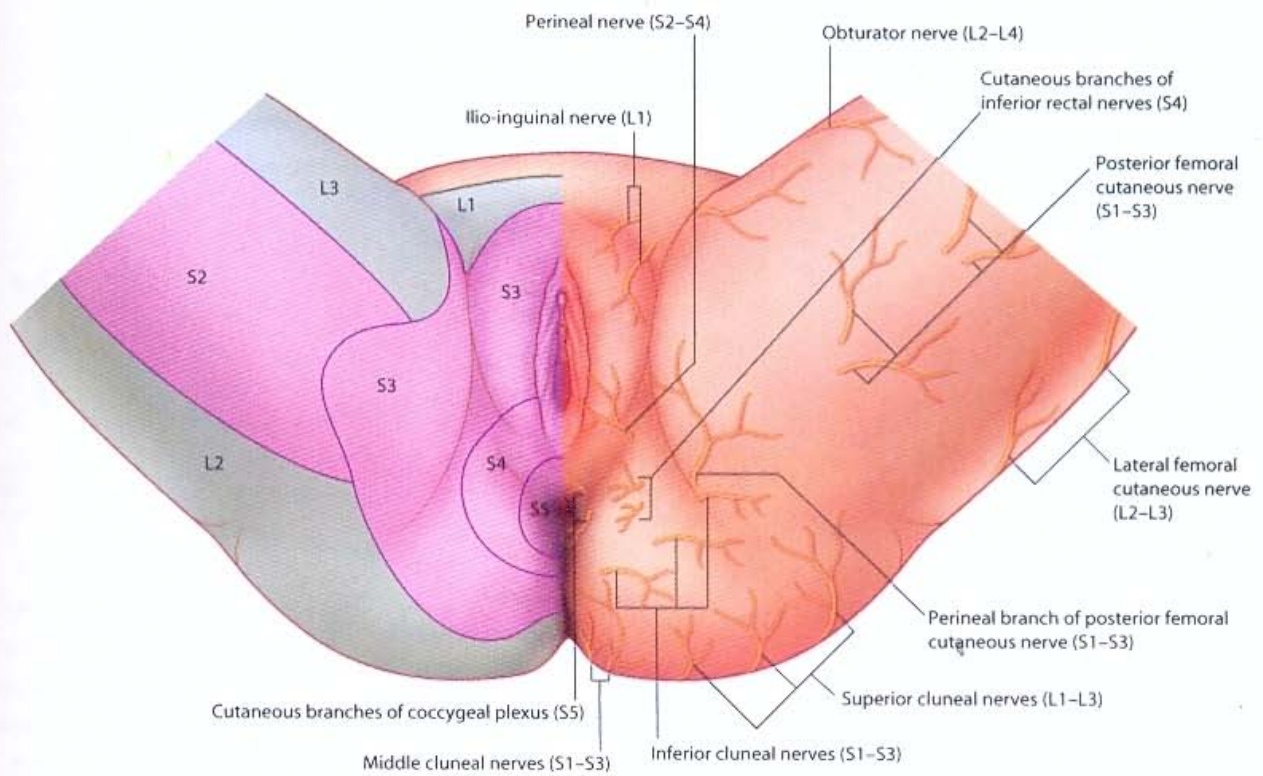
Lymphatics of pelvis and perineum in women



**Lymphatics of pelvic cavity (sagittal view)**

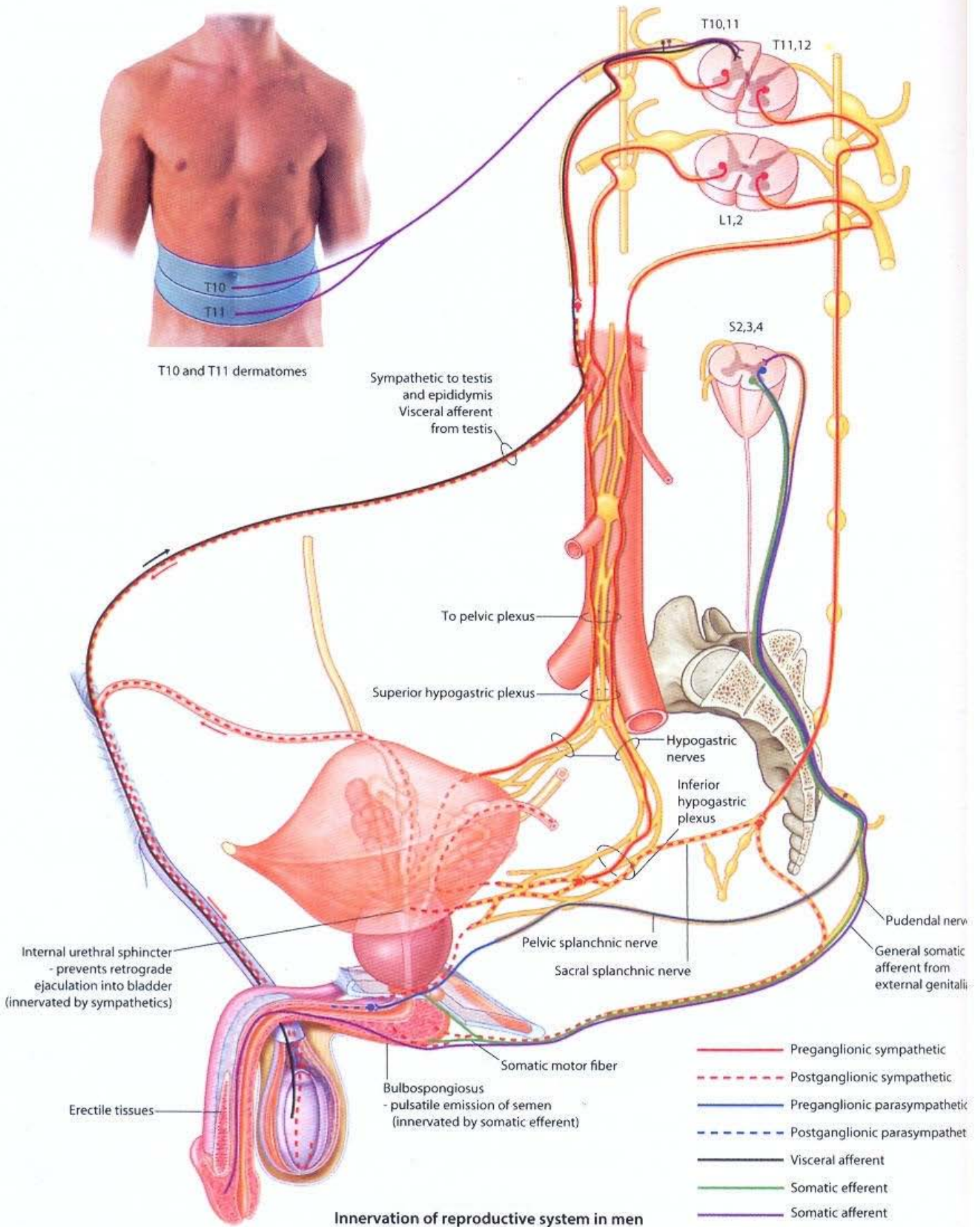


**Dermatomes and cutaneous nerves of perineum in men**

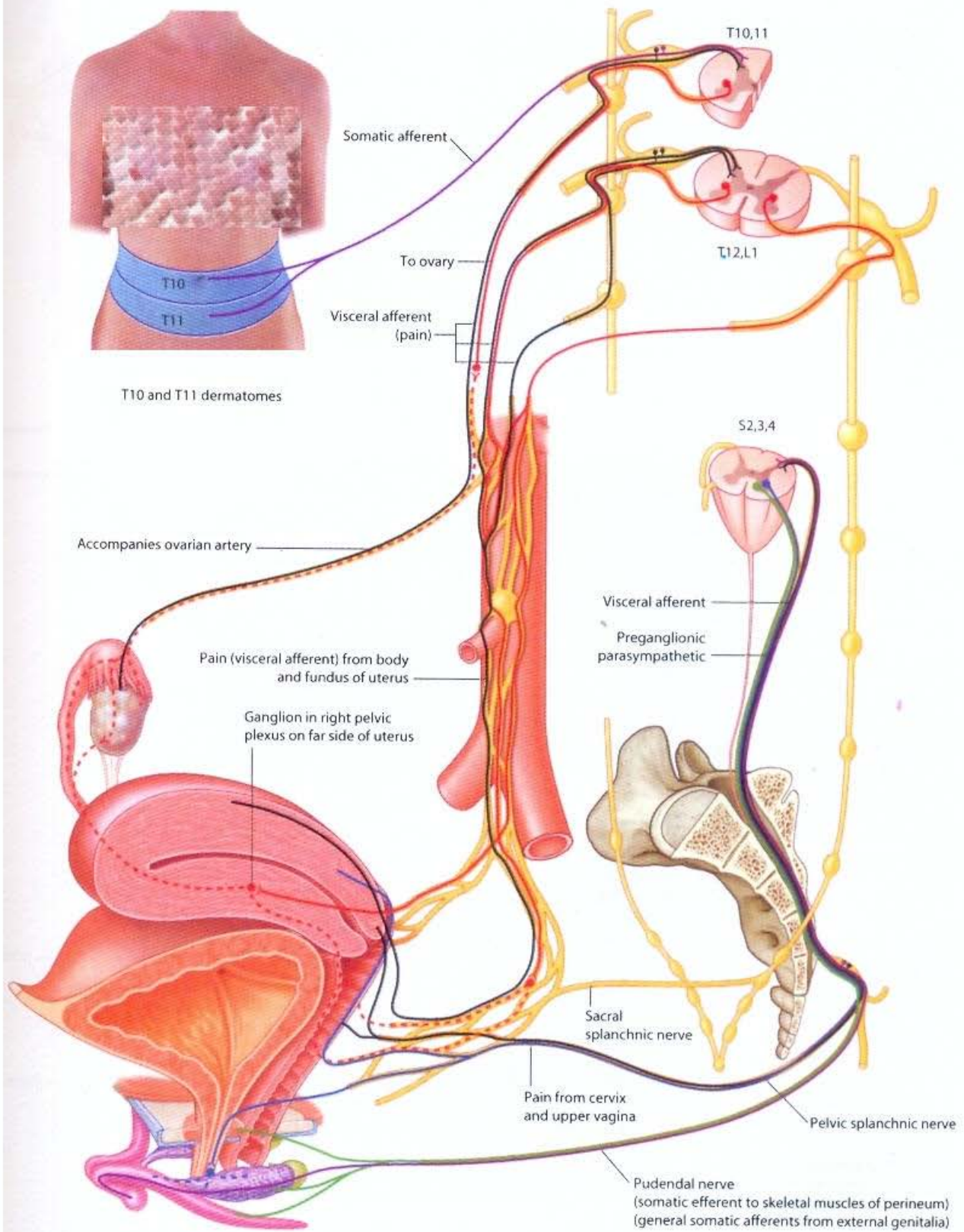


**Dermatomes and cutaneous nerves of perineum in women**

**PELVIS AND PERINEUM • Innervation of reproductive system in men**

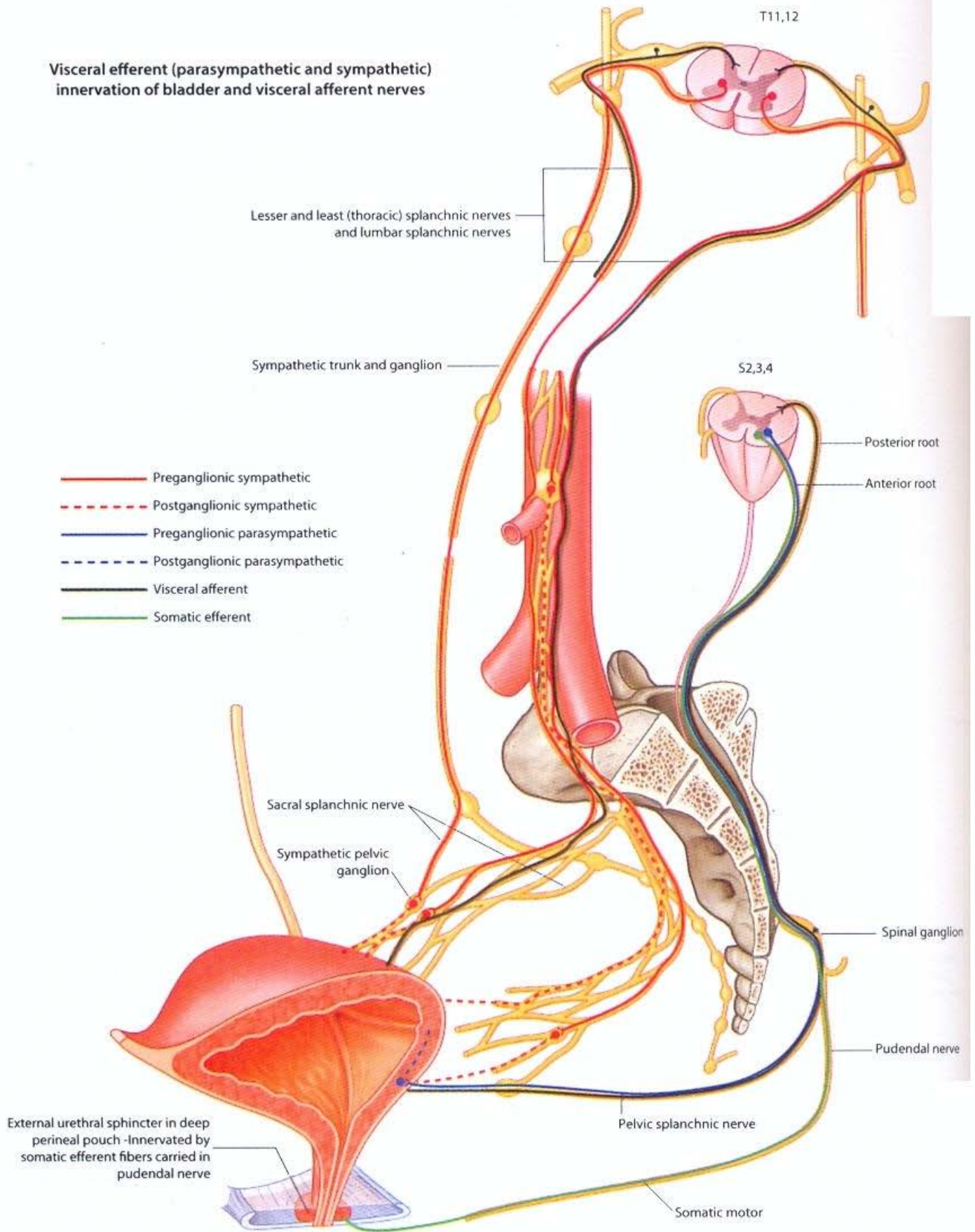


**Innervation of reproductive system in men**



Innervation of reproductive system in women

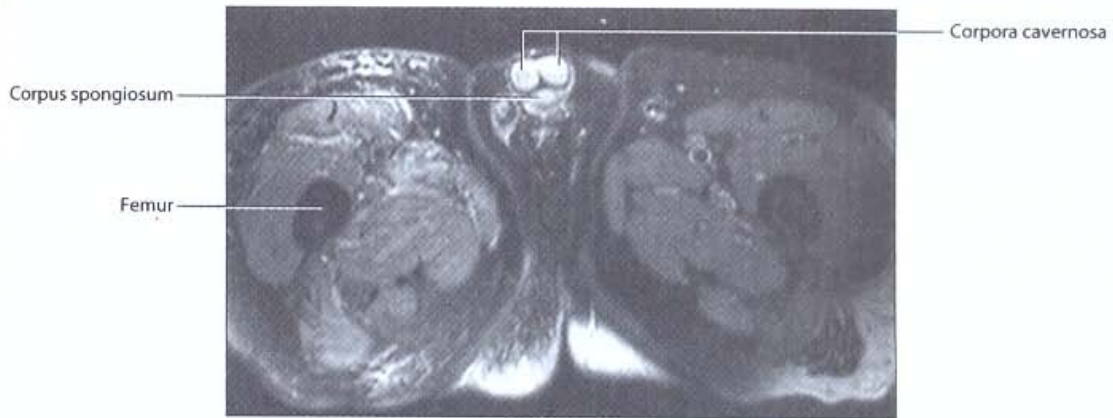
**Visceral efferent (parasympathetic and sympathetic) innervation of bladder and visceral afferent nerves**



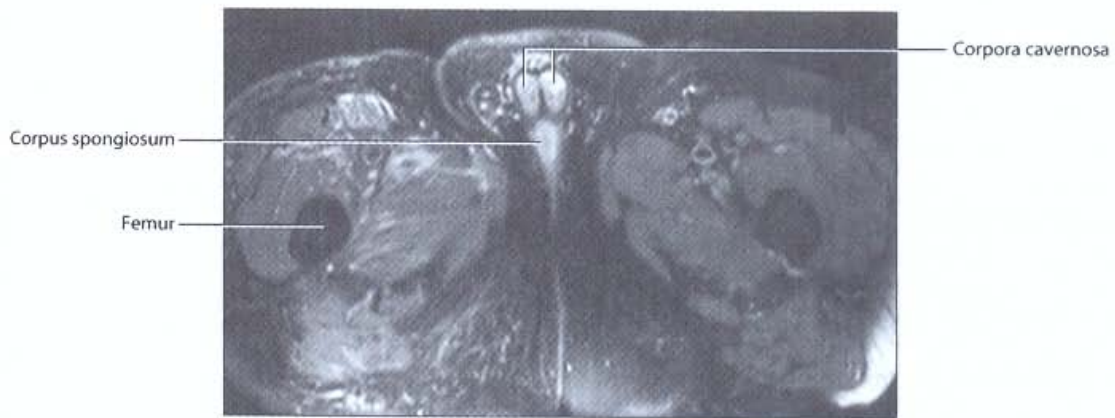



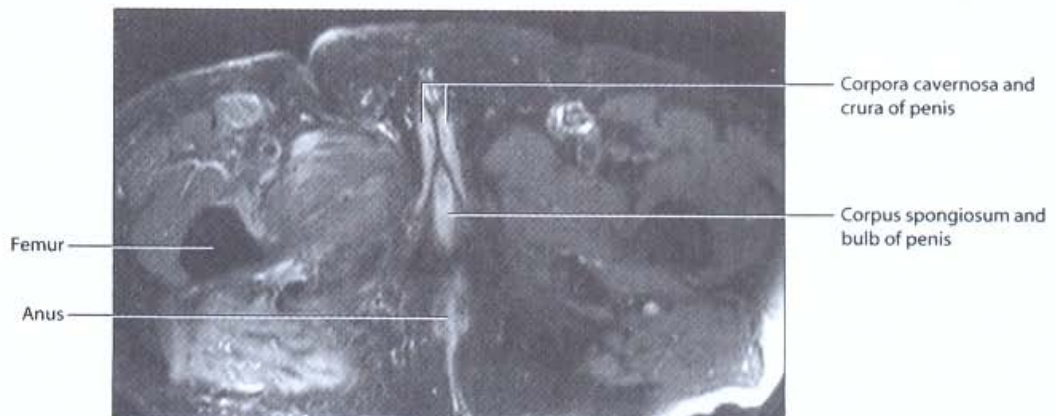
A



B



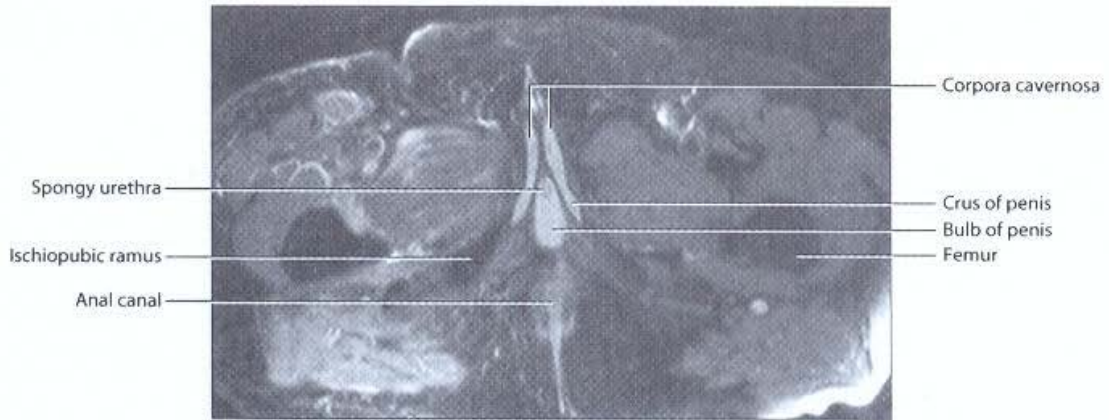
C



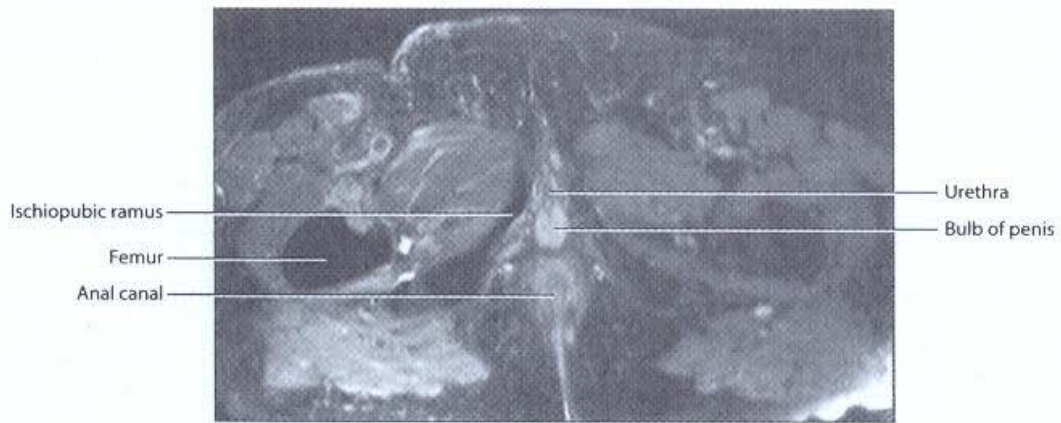
A through C – Series of axial images that pass through the pelvic cavity and perineum from inferior to superior showing the various structures and their relationships with each other.  
T2-weighted MR images in axial plane



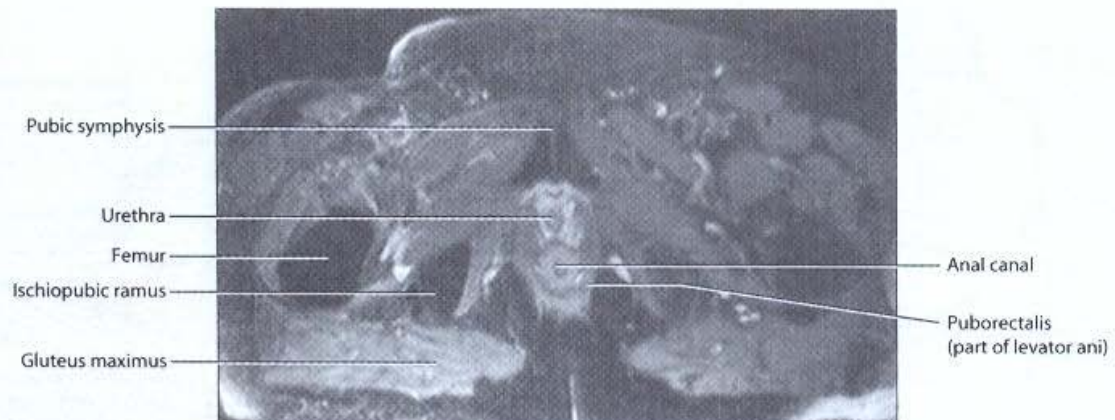
D



E

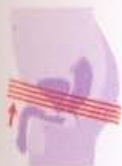

F

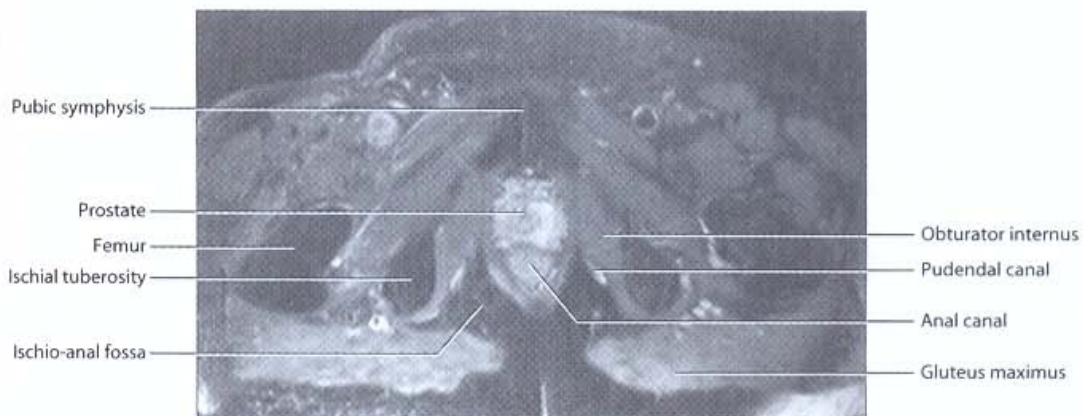


**D through J** – Series of axial images that pass through the pelvic cavity and perineum from inferior to superior showing the various structures and their relationships with each other.

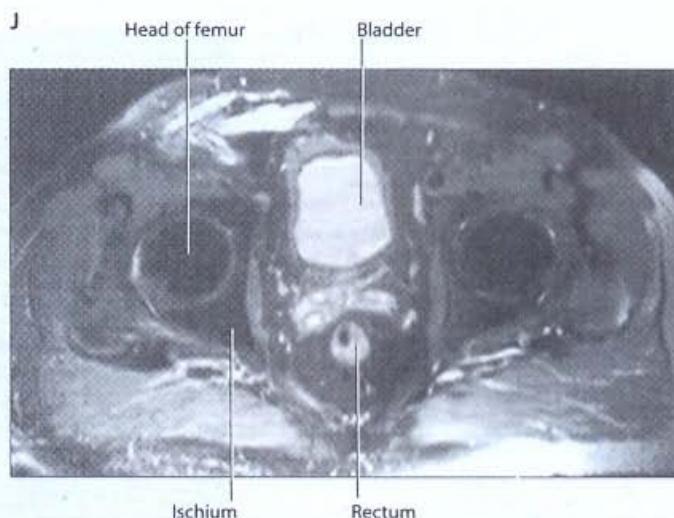
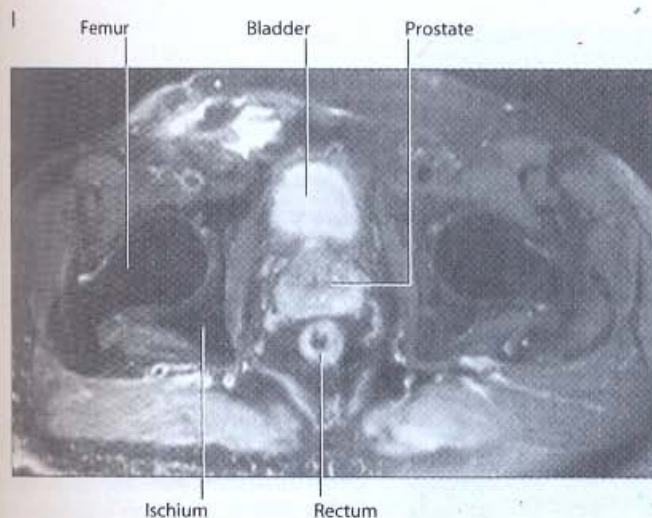
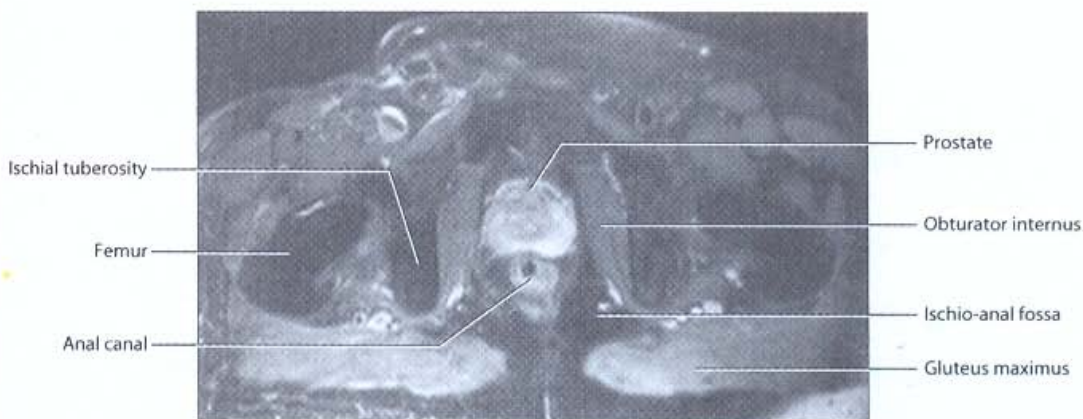
T2-weighted MR images in axial plane

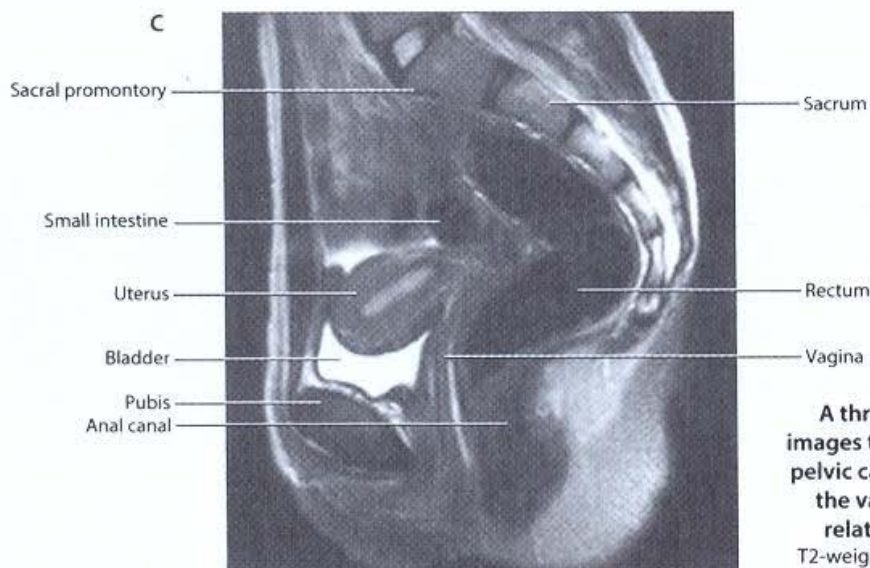
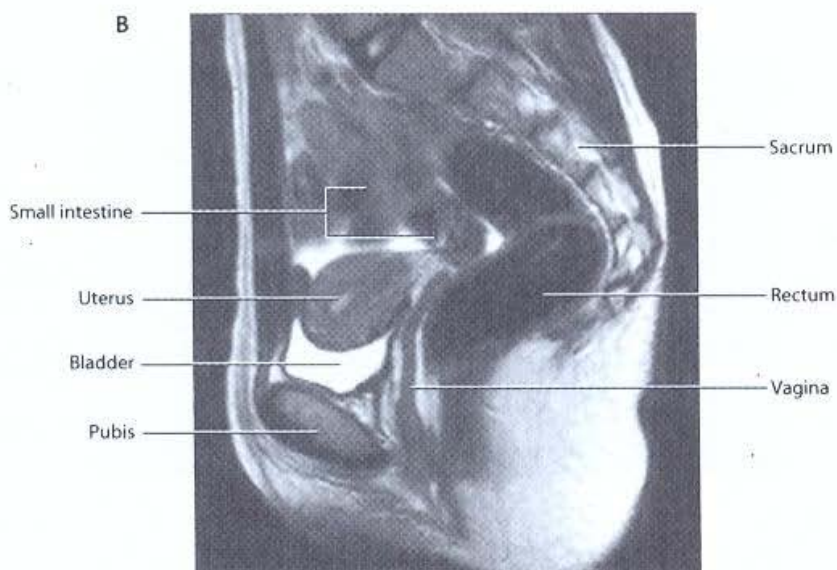
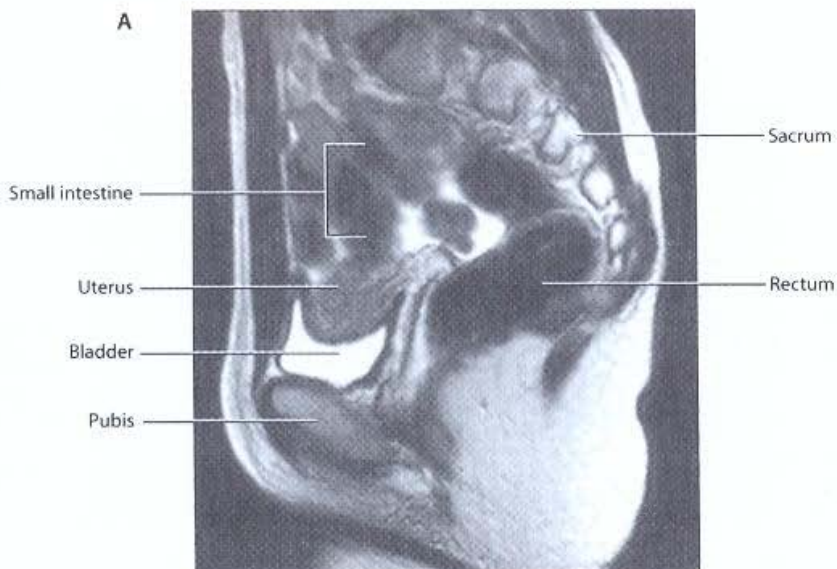
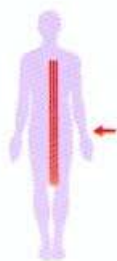


G

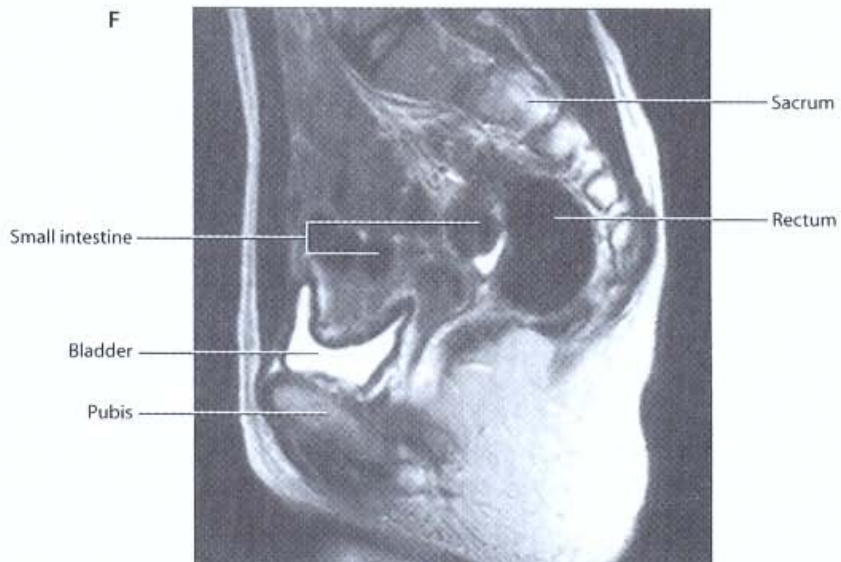
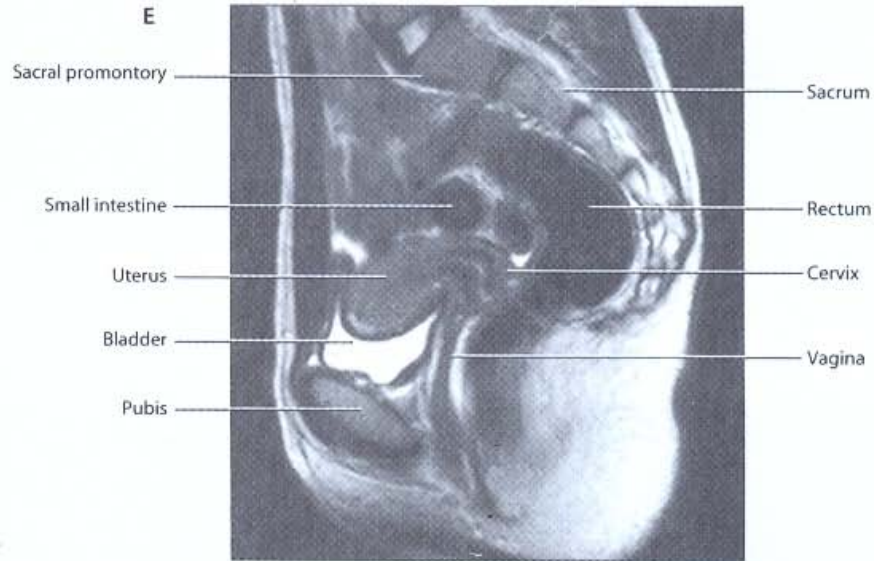
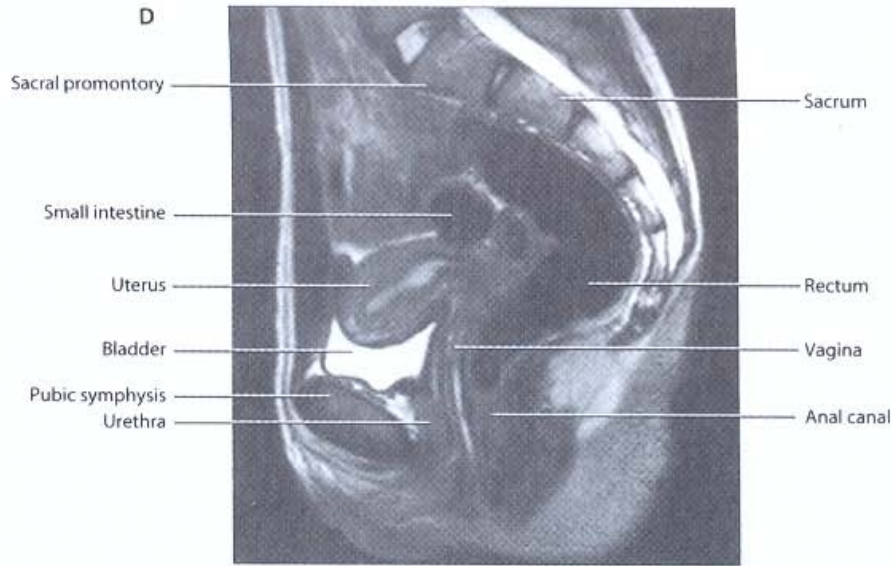
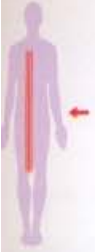


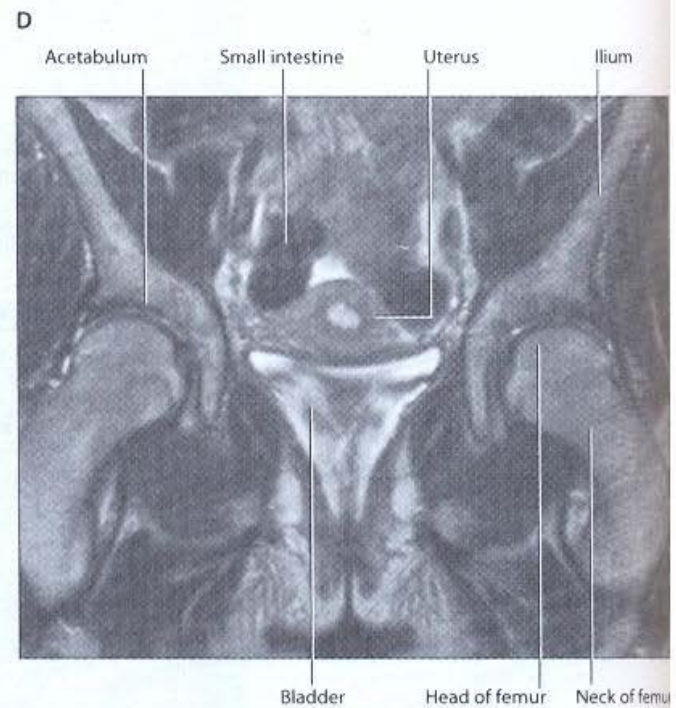
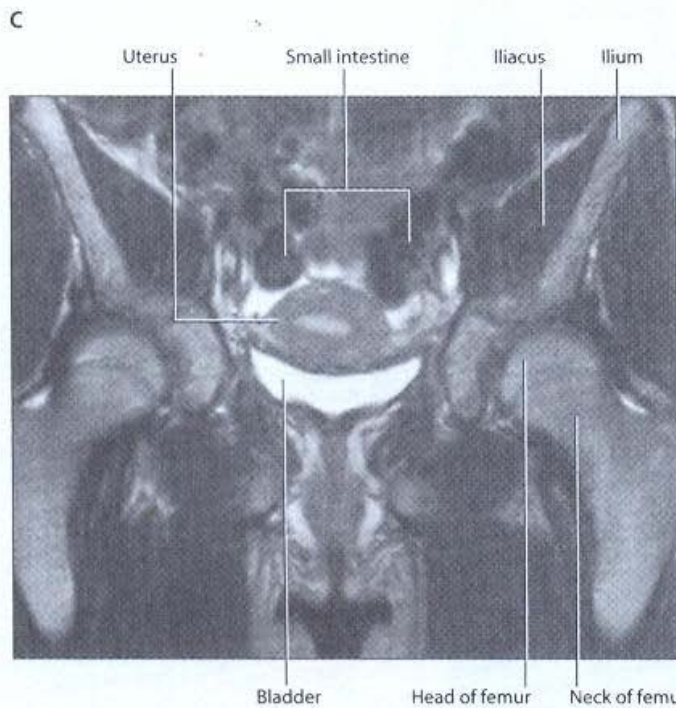
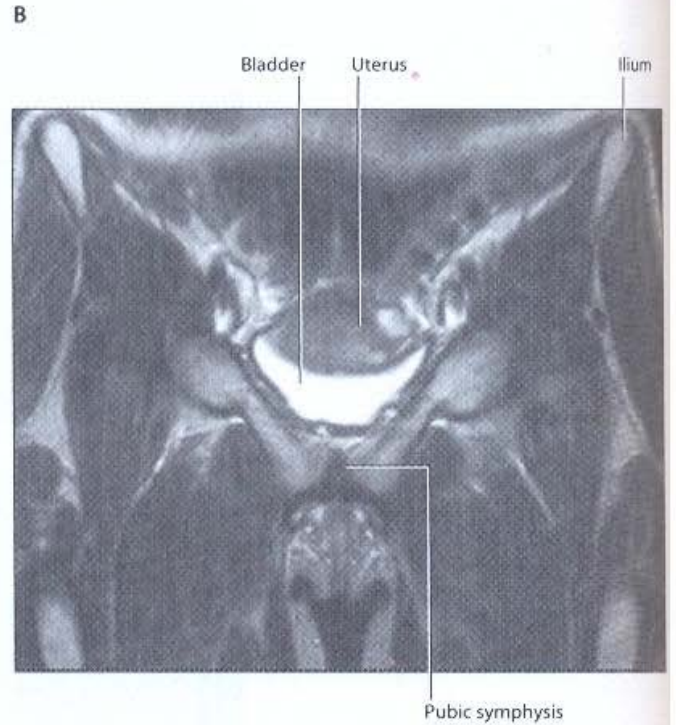
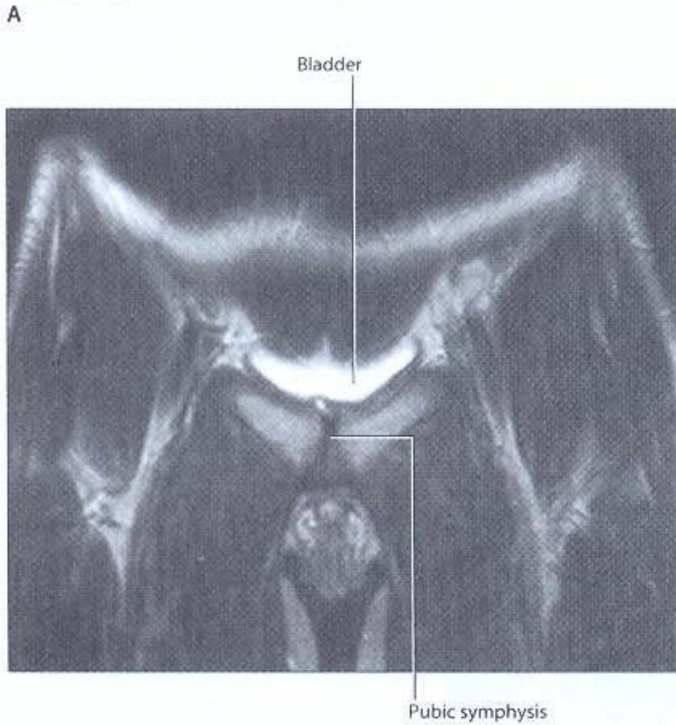
H



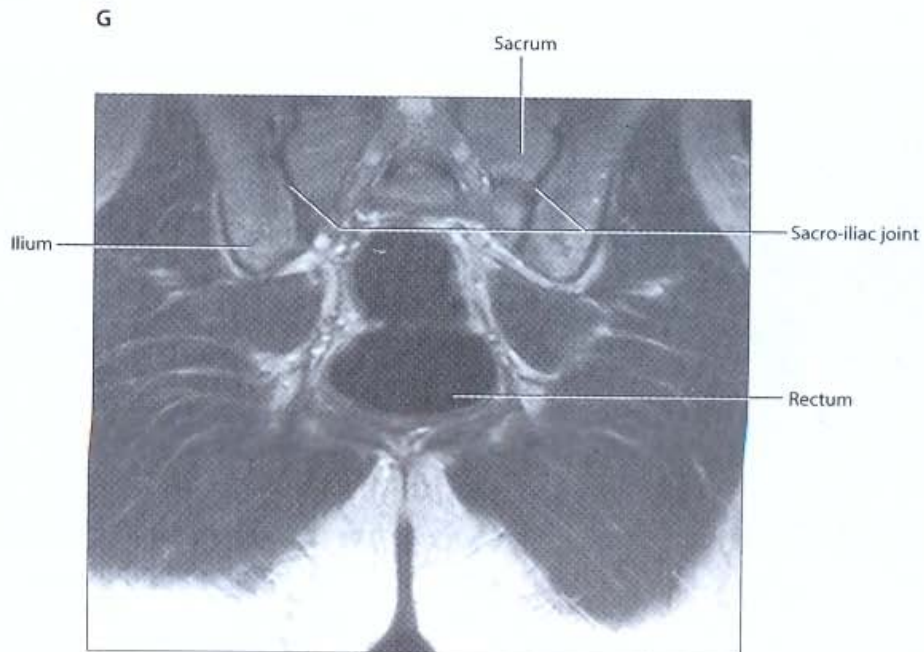
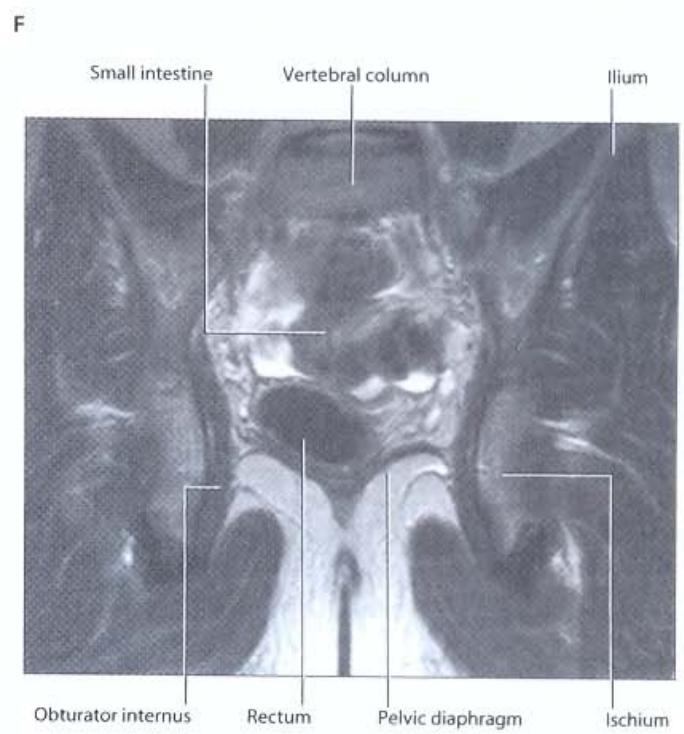
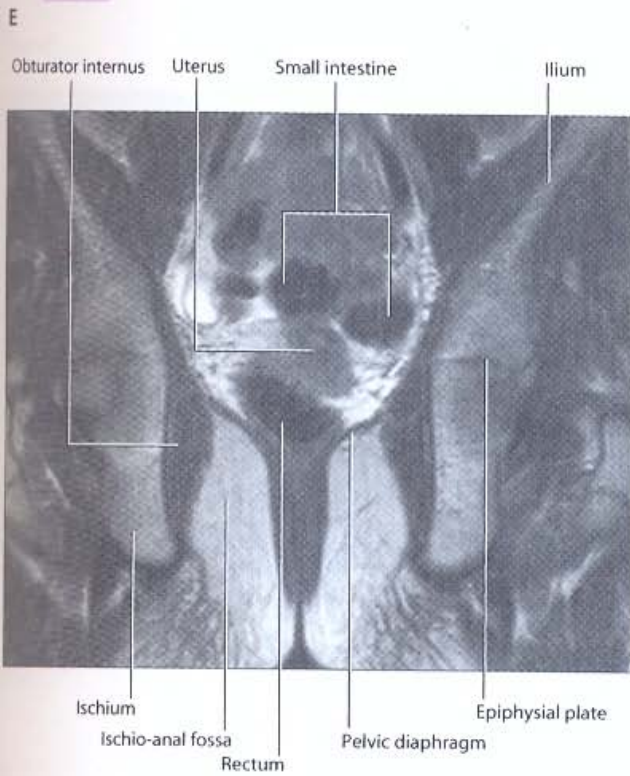
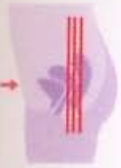


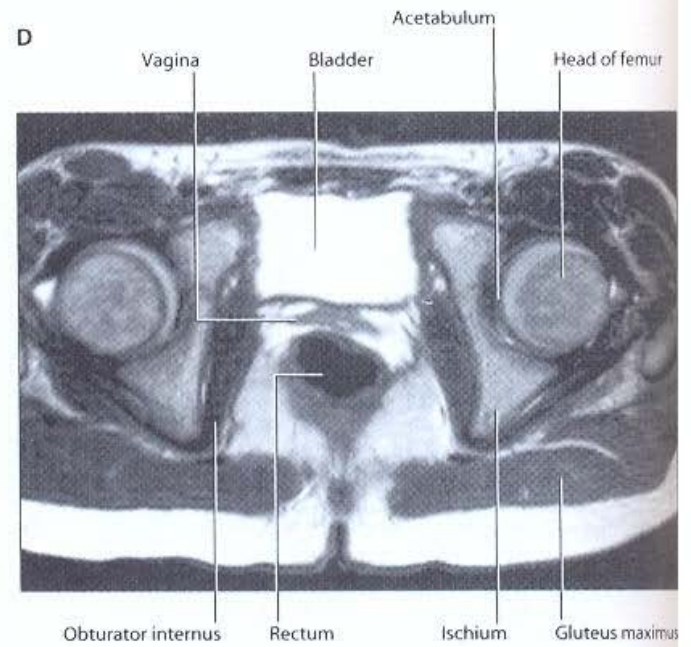
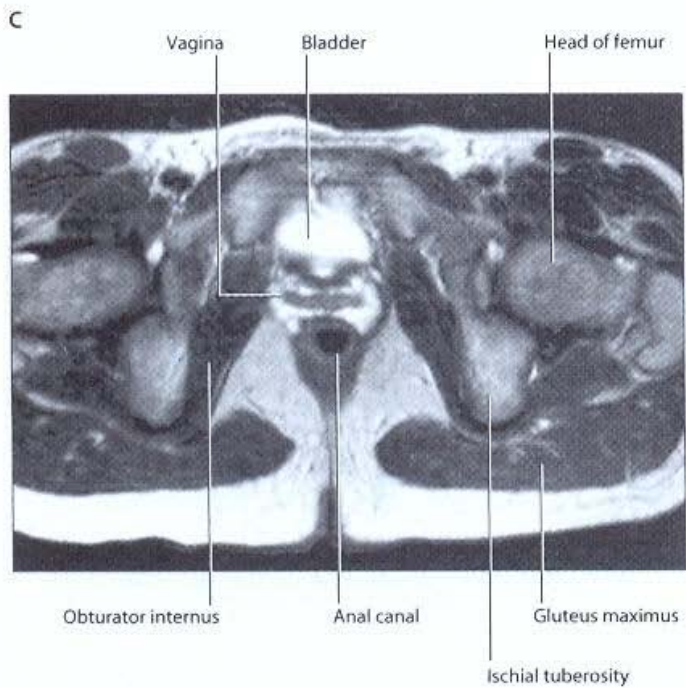
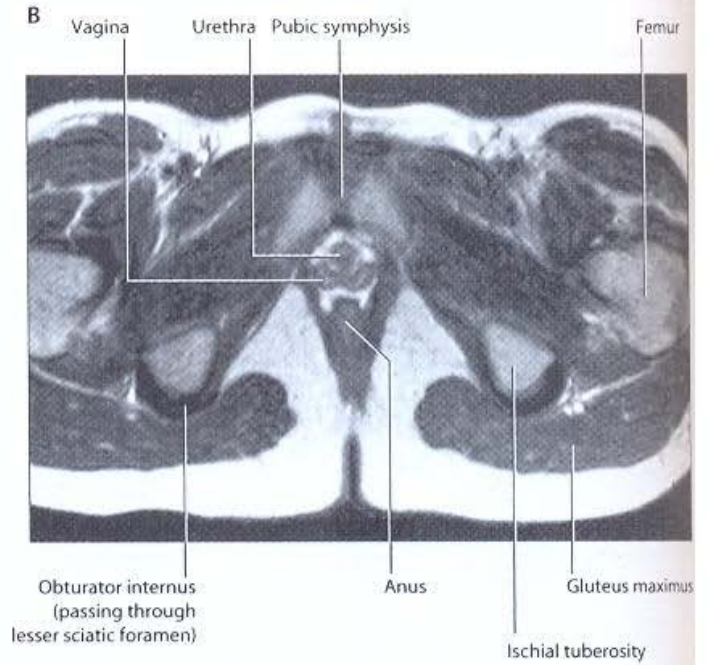
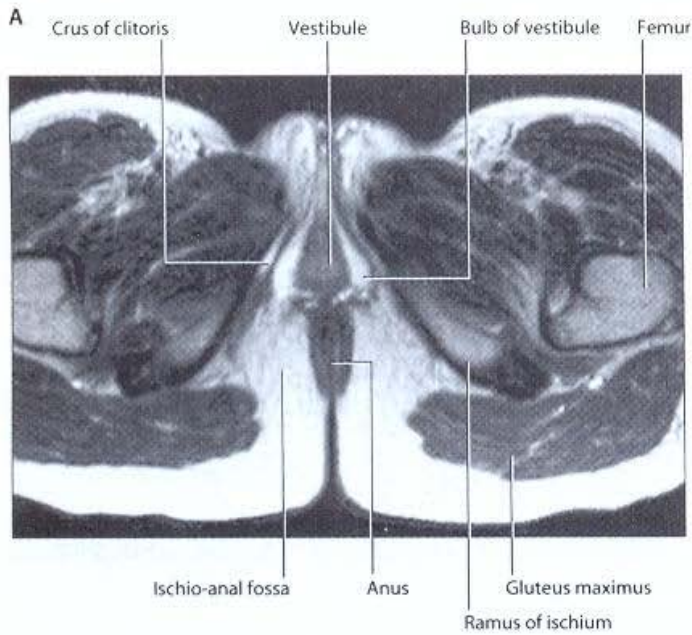
**A through F** – Series of sagittal images that pass through the female pelvic cavity and perineum showing the various structures and their relationships with each other. T2-weighted MR images in sagittal plane





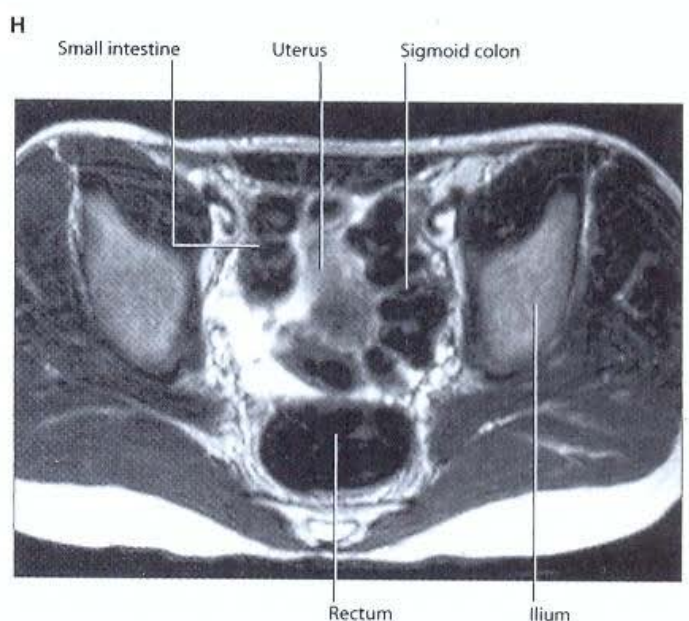
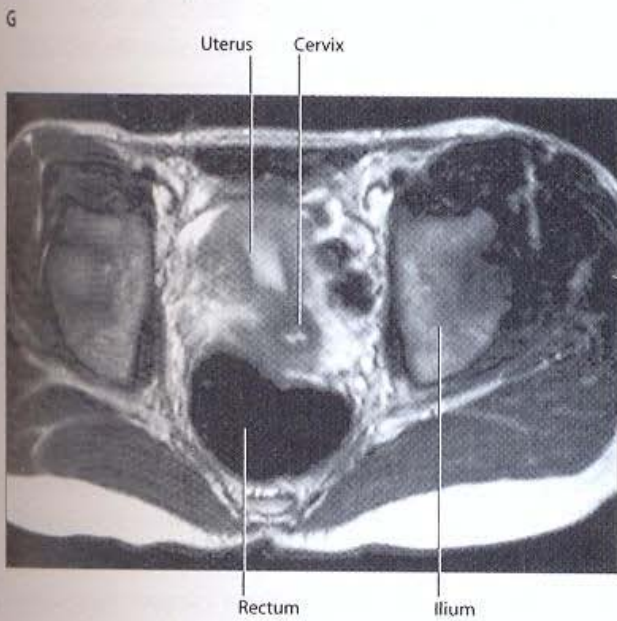
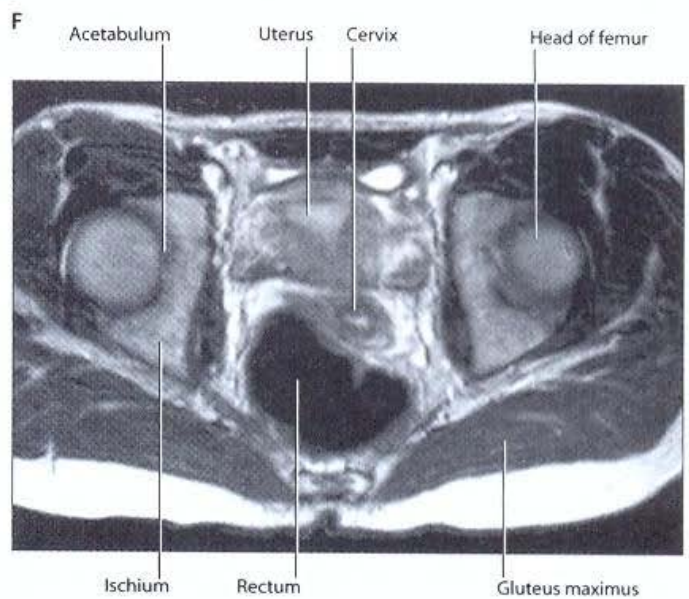
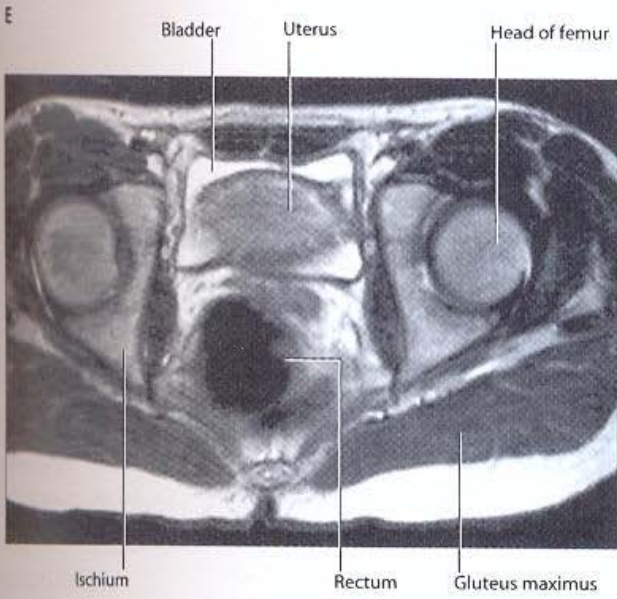
**A through G** – Series of coronal images that pass through the pelvic cavity and perineum from anterior to posterior showing the various structures and their relationships with each other.  
T2-weighted MR images in coronal plane





**A through H** – Series of axial images that pass through the pelvic cavity and perineum from inferior to superior showing the various structures and their relationships with each other.  
T2-weighted MR images in axial plane



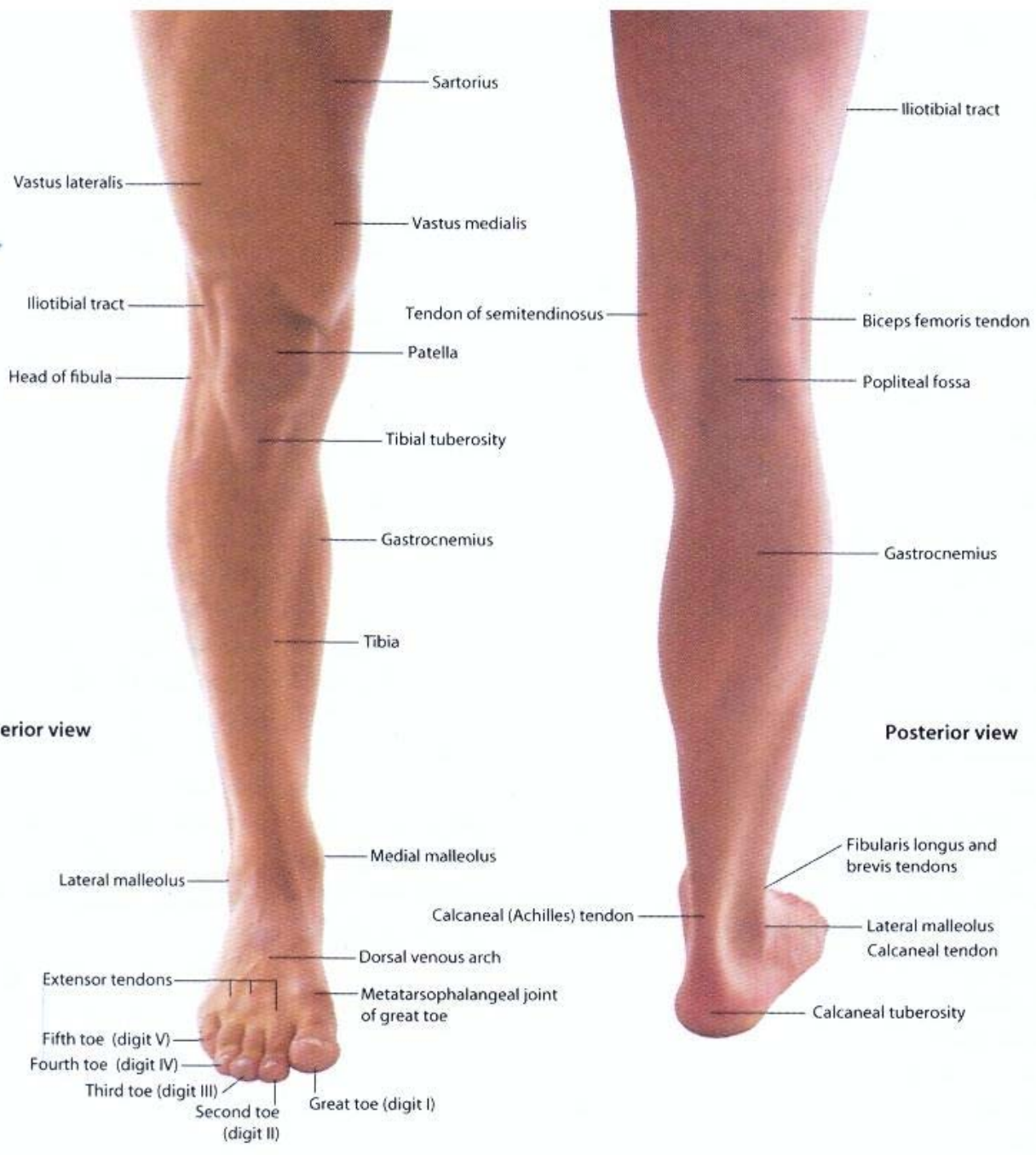

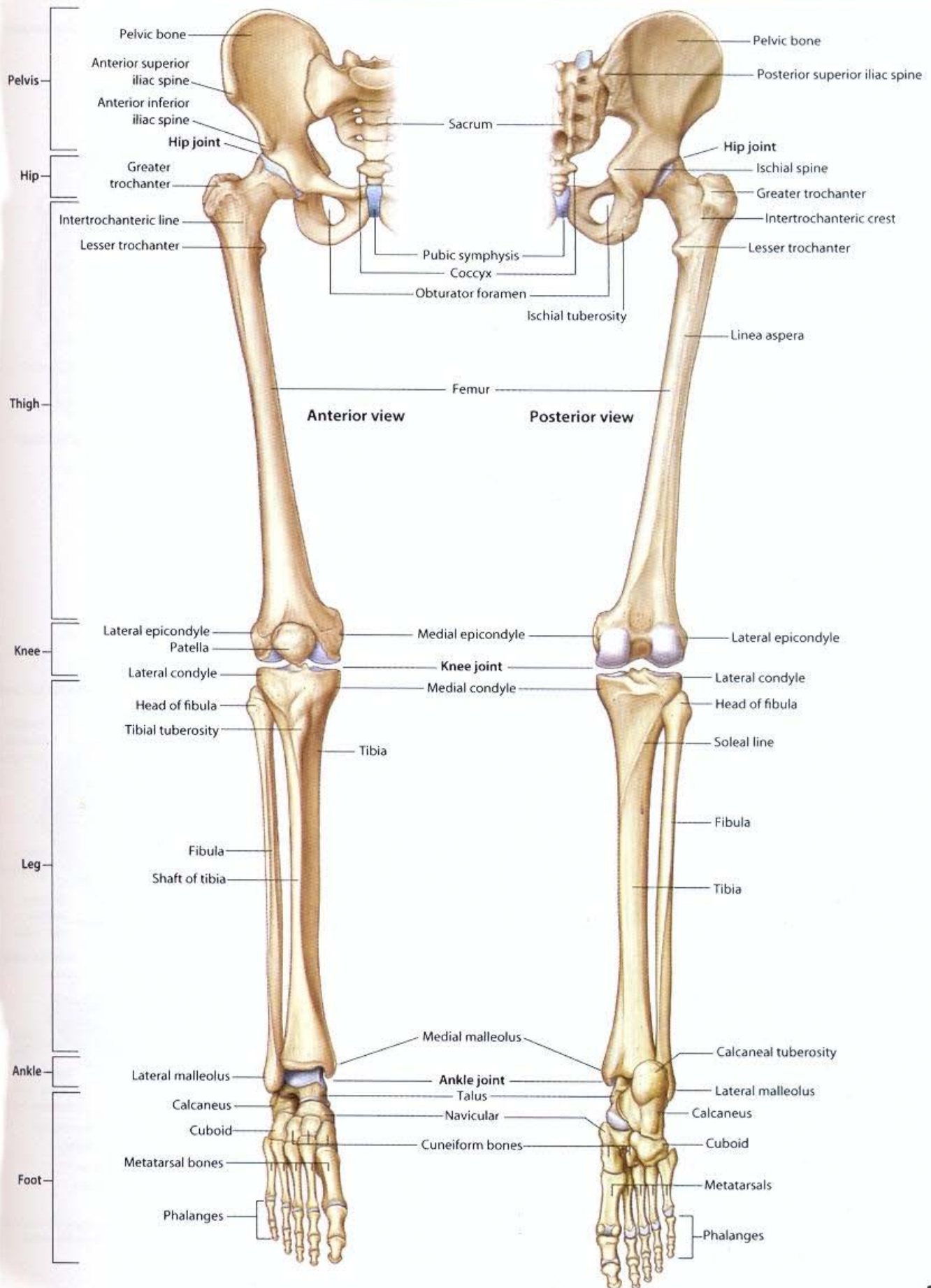
# 6

## LOWER LIMB

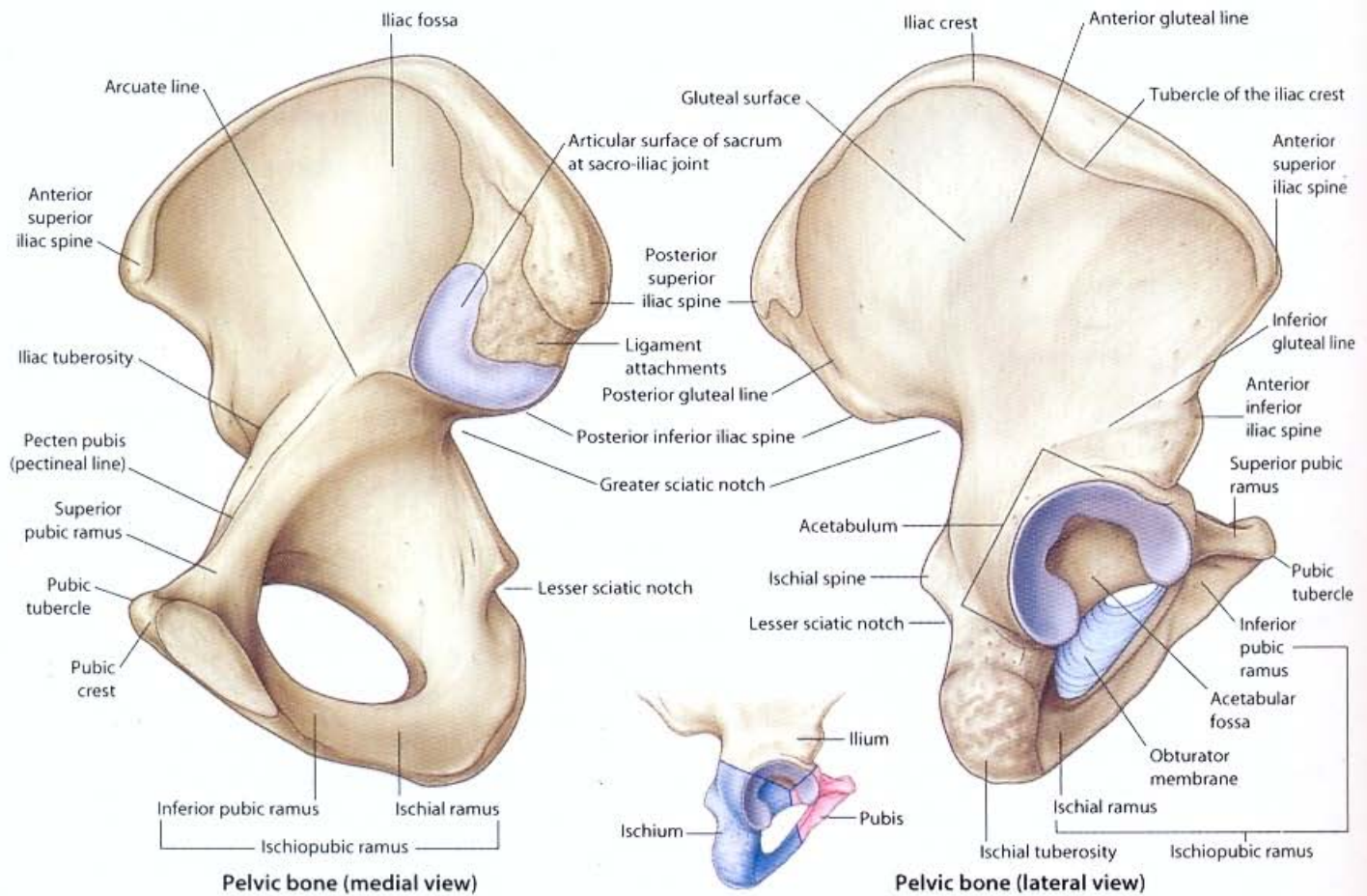
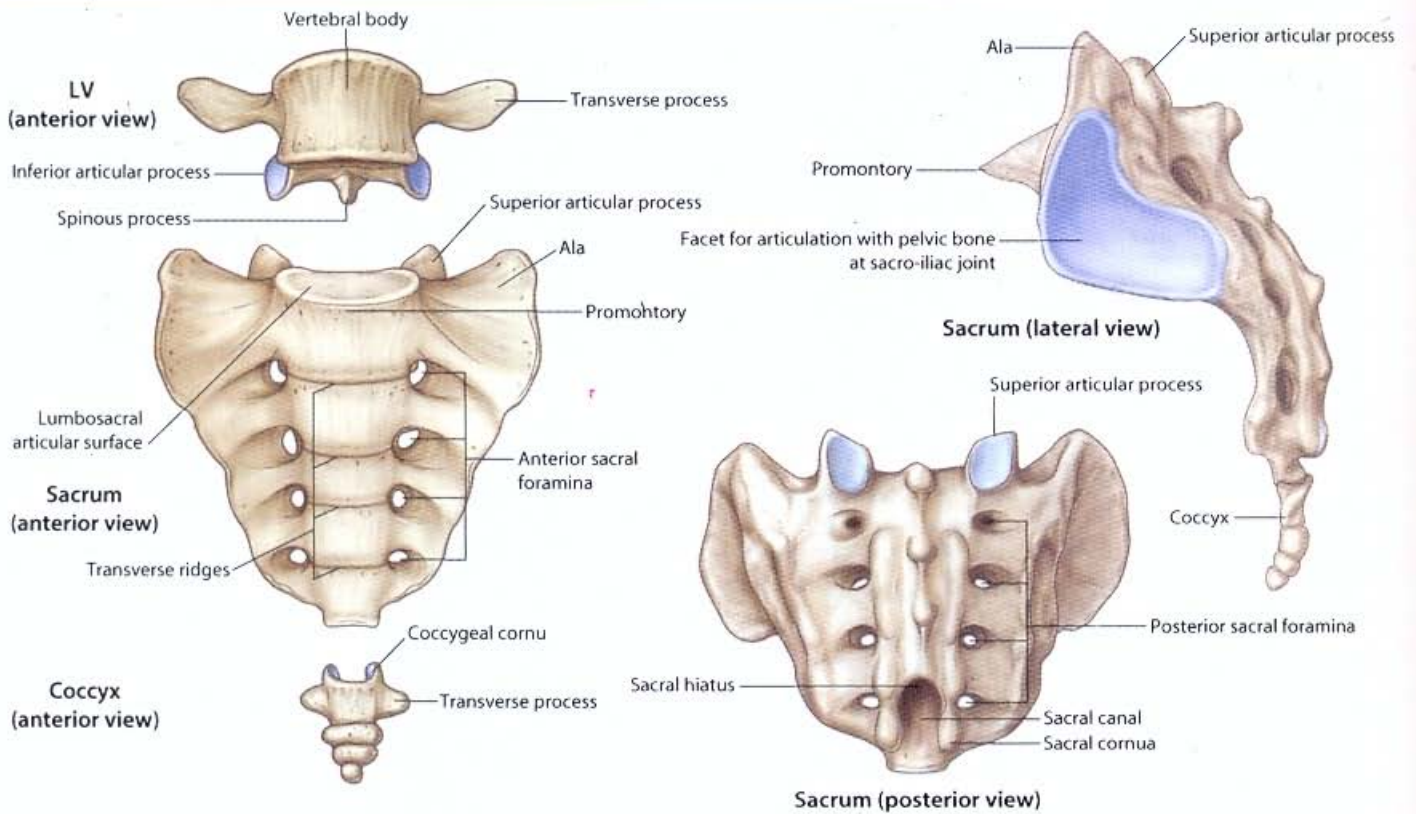
### CONTENTS

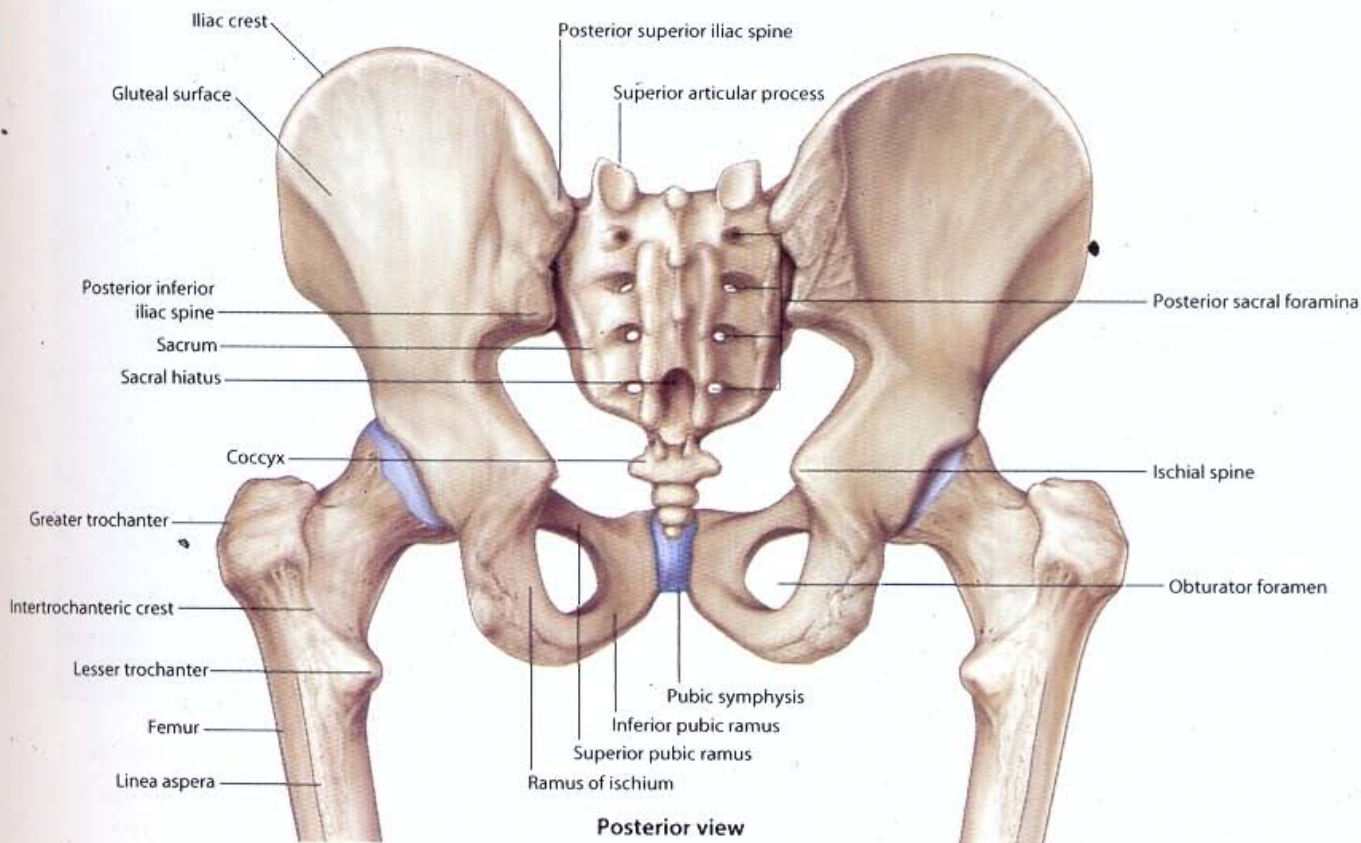
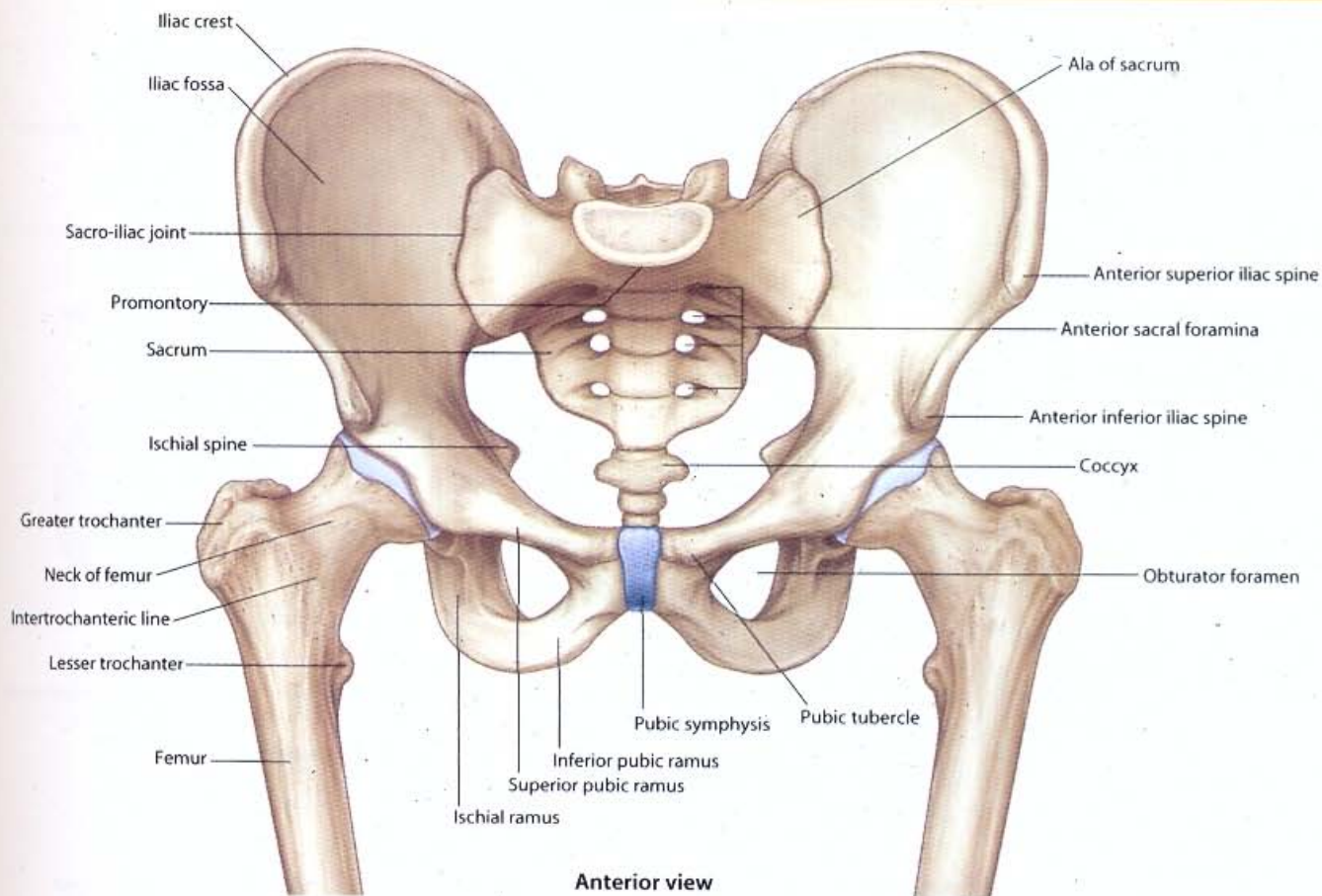
<i>Surface anatomy</i>	272	<i>Ligaments of the ankle joint</i>	316
<i>Bones of the lower limb</i>	273	<i>Leg: muscle attachments</i>	319
<i>Pelvic bones and sacrum</i>	274	<i>Posterior leg: superficial muscles</i>	320
<i>Articulated pelvis</i>	275	<i>Posterior compartment: deep muscles</i>	321
<i>Proximal femur</i>	276	<i>Posterior leg: arteries and nerves</i>	322
<i>Hip joint</i>	277	<i>Lateral compartment: muscles</i>	323
<i>Hip joint: structure and arterial supply</i>	279	<i>Anterior leg: superficial muscles</i>	324
<i>Gluteal region: attachments and superficial musculature</i>	280	<i>Anterior compartment: muscles</i>	325
<i>Gluteal region: superficial and deep muscles</i>	281	<i>Anterior leg: arteries and nerves</i>	326
<i>Gluteal region: arteries and nerves</i>	282	<i>Leg: cutaneous nerves</i>	327
<i>Distal femur and proximal tibia and fibula</i>	284	<i>Transverse sections: leg</i>	328
<i>Thigh: muscle attachments</i>	285	<i>Foot: muscle attachments</i>	330
<i>Thigh: anterior superficial musculature</i>	286	<i>Foot: ligaments</i>	331
<i>Thigh: posterior superficial musculature</i>	287	<i>Dorsum of foot</i>	333
<i>Thigh: anterior compartment muscles</i>	288	<i>Dorsum of foot: arteries and nerves</i>	334
<i>Thigh: medial compartment muscles</i>	289	<i>Plantar aponeurosis</i>	336
<i>Femoral triangle</i>	290	<i>Plantar region (sole) musculature: first layer</i>	337
<i>Anterior thigh: arteries and nerves</i>	291	<i>Plantar region (sole) musculature: second layer</i>	338
<i>Anterior thigh: arteries</i>	292	<i>Plantar region (sole) musculature: third layer</i>	339
<i>Thigh: posterior compartment muscles</i>	293	<i>Plantar region (sole) musculature: fourth layer</i>	340
<i>Posterior thigh: arteries and nerves</i>	294	<i>Plantar region (sole): arteries and nerves</i>	341
<i>Transverse sections: thigh</i>	296	<i>Dorsal hood and tarsal tunnel</i>	343
<i>Knee joint</i>	298	<i>Superficial veins of the lower limb</i>	344
<i>Ligaments of the knee</i>	300	<i>Lymphatics of the lower limb</i>	345
<i>Menisci and cruciate ligaments</i>	302	<i>Anterior cutaneous nerves and dermatomes of the lower limb</i>	346
<i>Knee: bursa and capsule</i>	306	<i>Posterior cutaneous nerves and dermatomes of the lower limb</i>	347
<i>Knee surface: muscles, capsule, and arteries</i>	307		
<i>Popliteal fossa</i>	308		
<i>Tibia and fibula</i>	309		
<i>Bones of the foot</i>	310		
<i>Bones and joints of the foot</i>	313		
<i>Talus and calcaneus</i>	314		
<i>Ankle joint</i>	315		

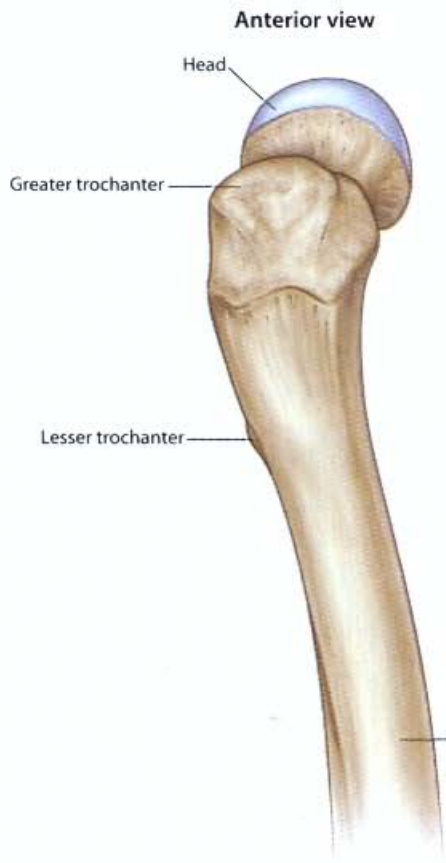
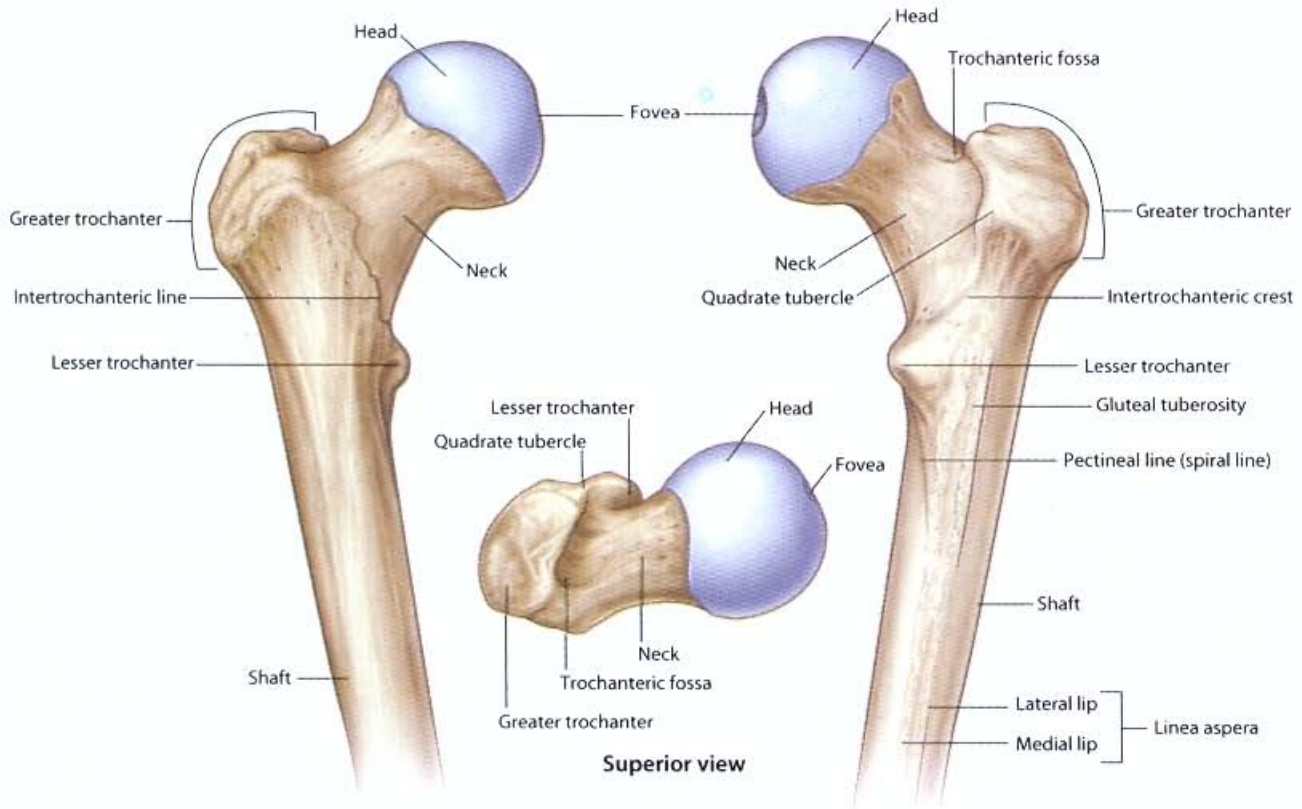




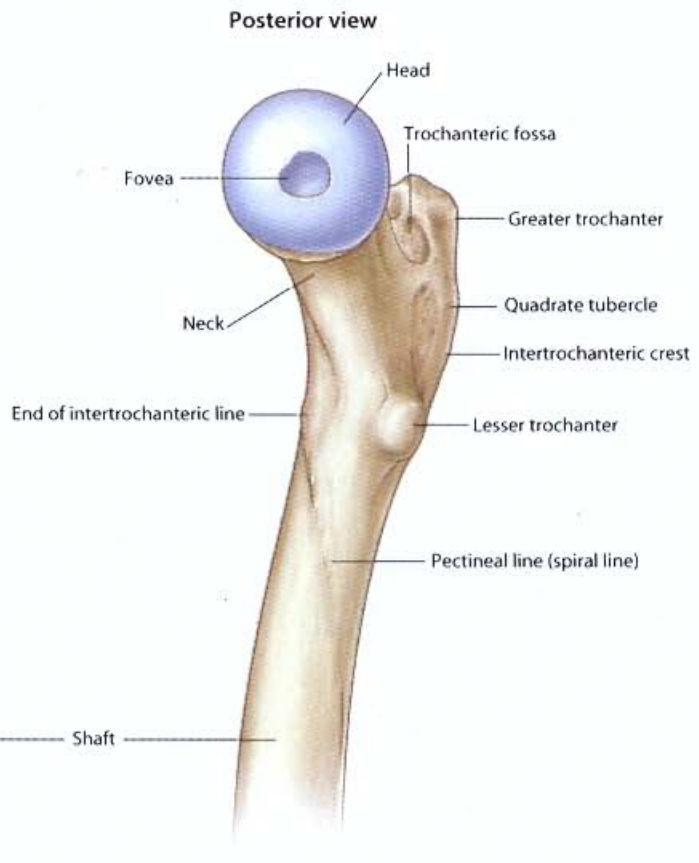
# LOWER LIMB • Pelvic bones and sacrum



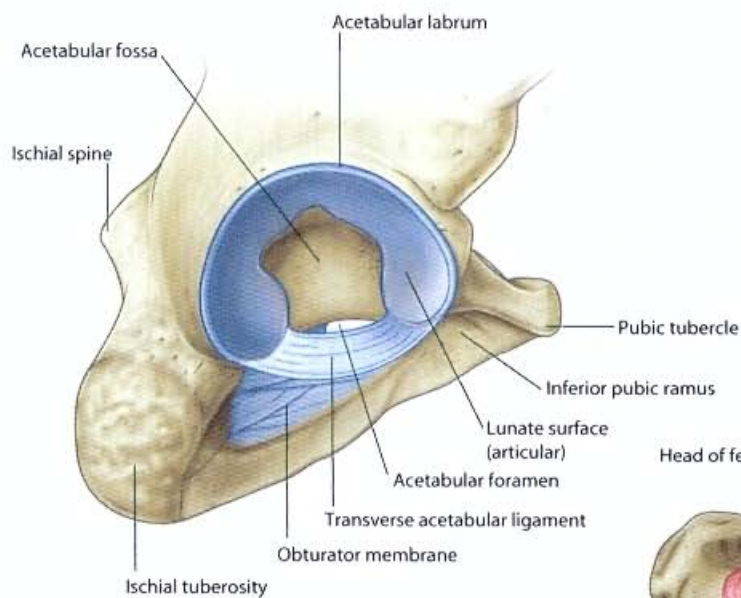




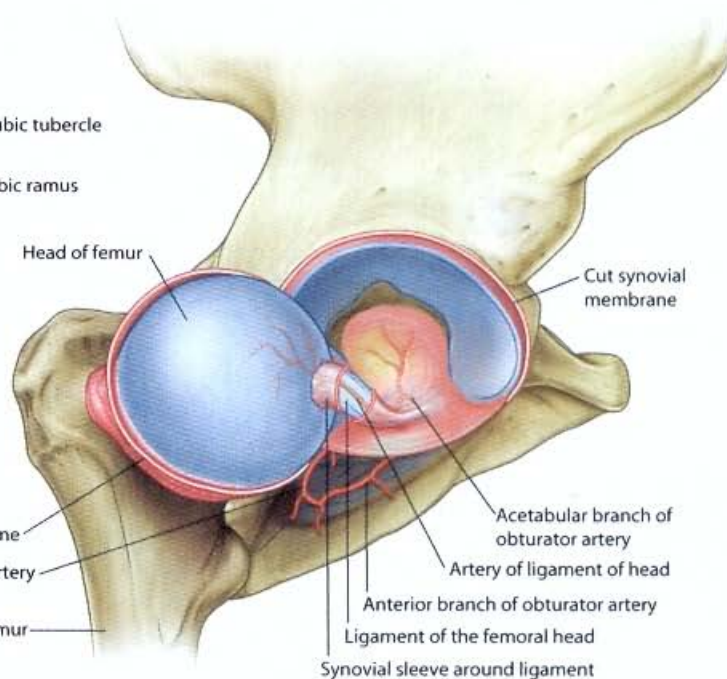
**Lateral view**



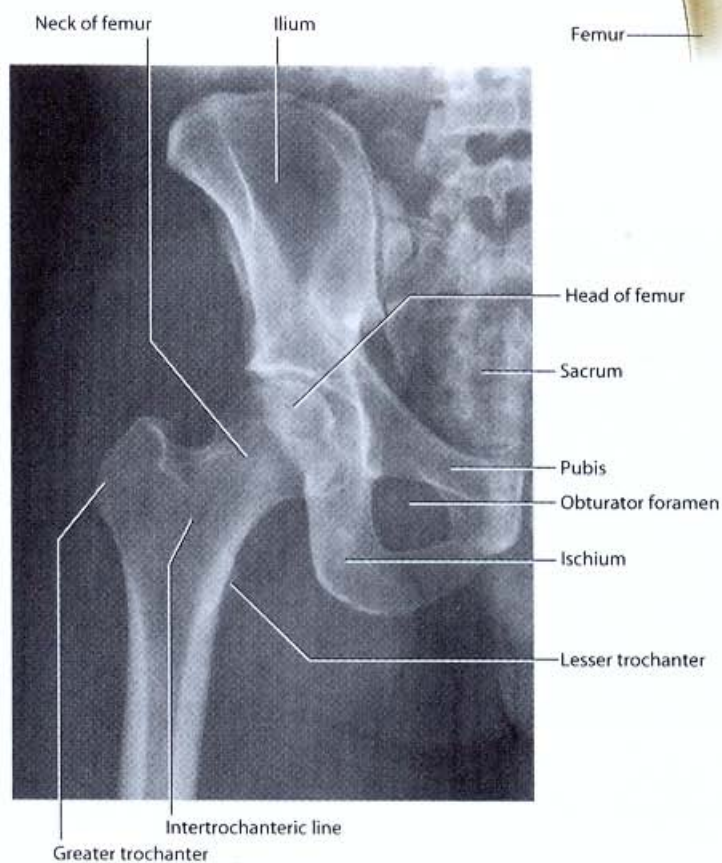
**Medial view**



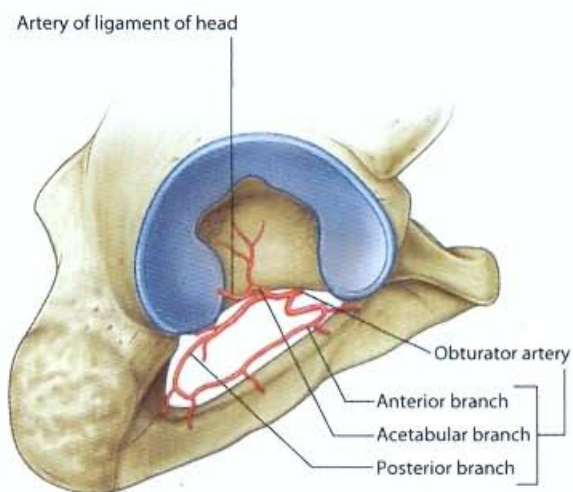
**Acetabular fossa and transverse acetabular ligament**



**Ligament of head of femur.**  
The head of the femur has been laterally rotated

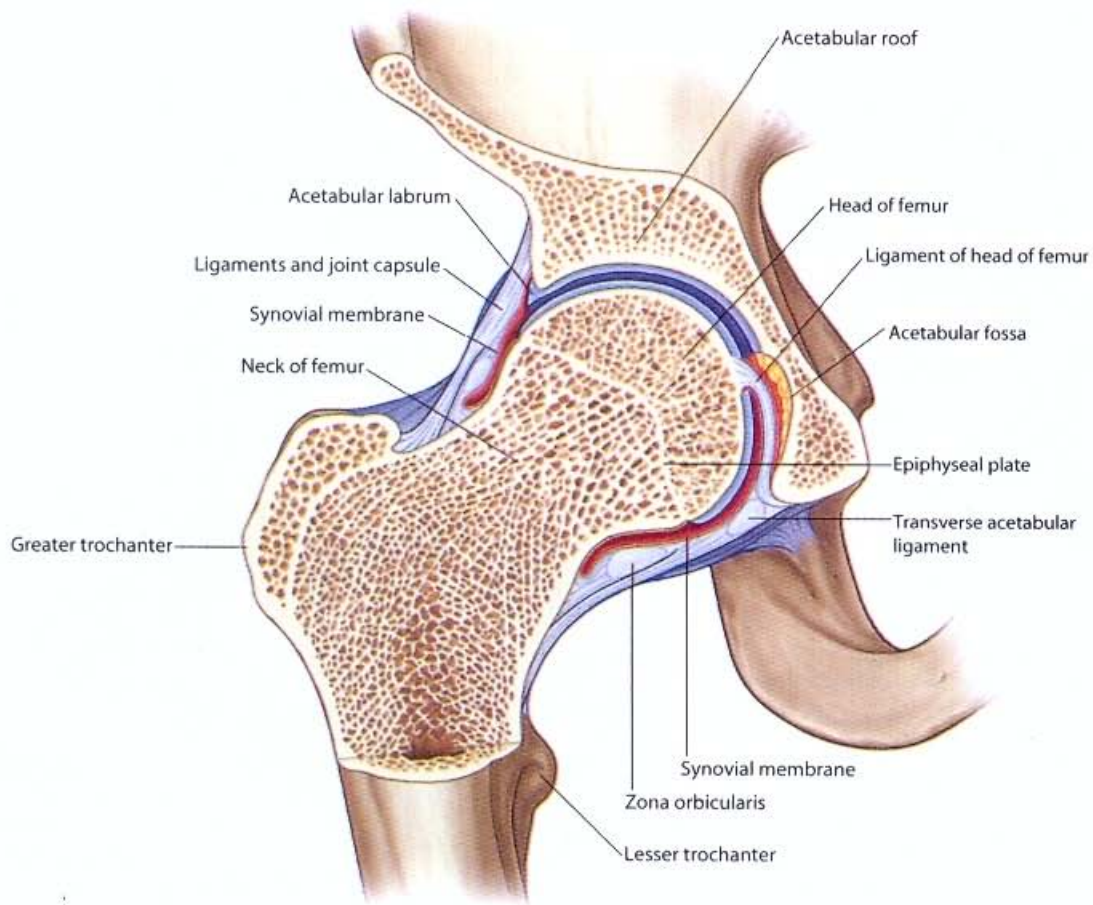


**Normal hip joint.**  
Radiograph, AP view

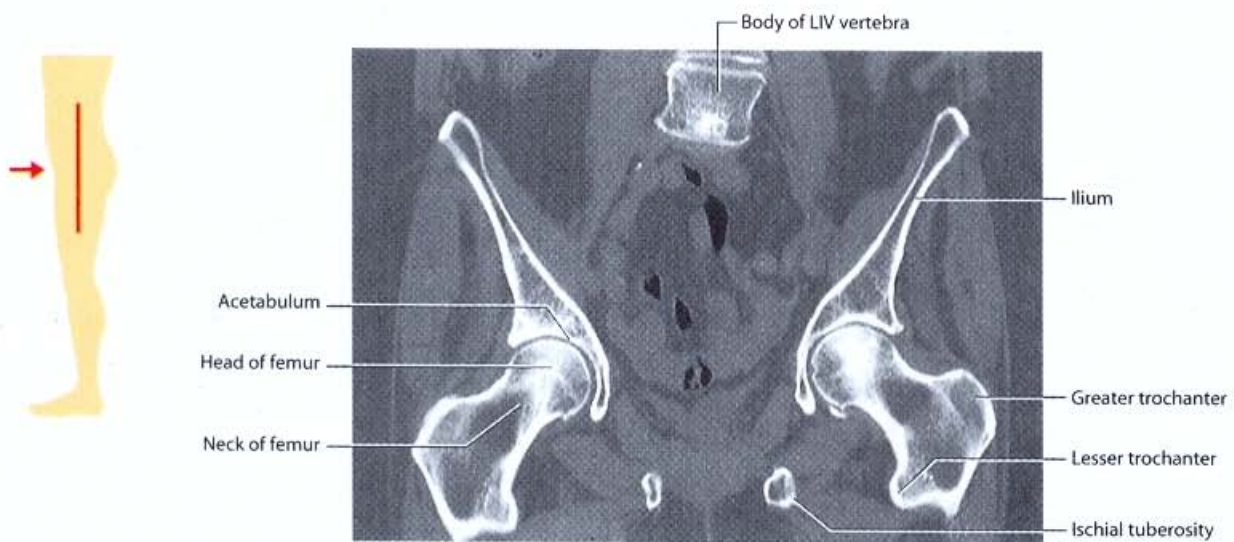


**Obturator artery and branches**

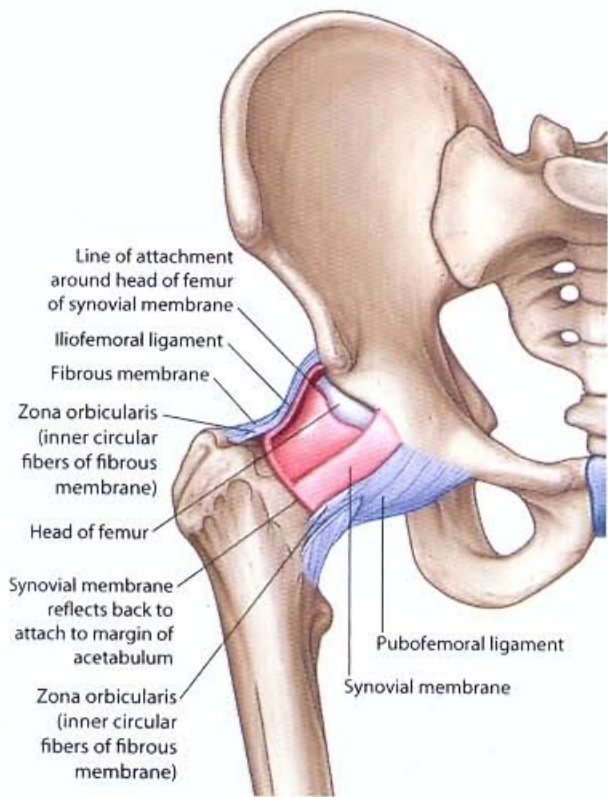




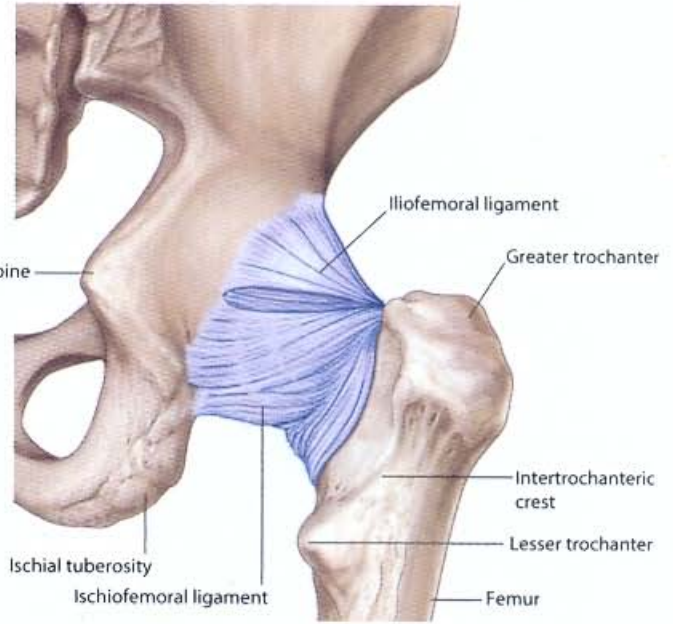
Coronal section through hip joint



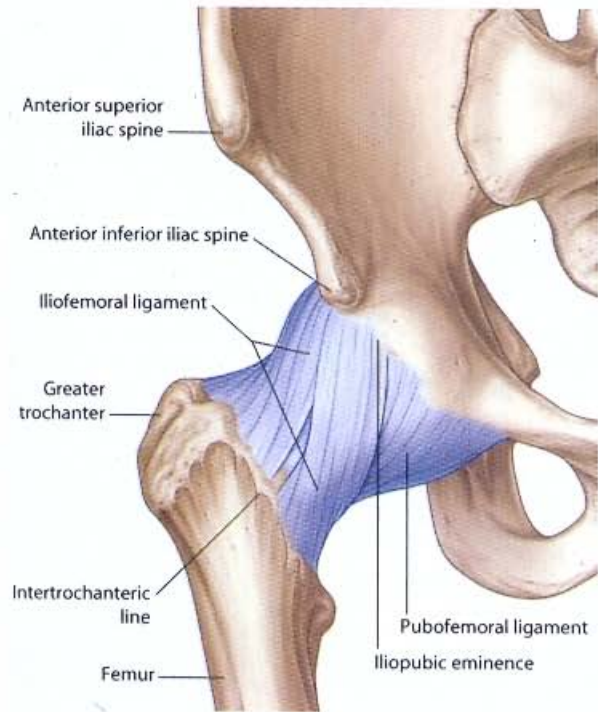
Hip joints.  
CT image in coronal plane



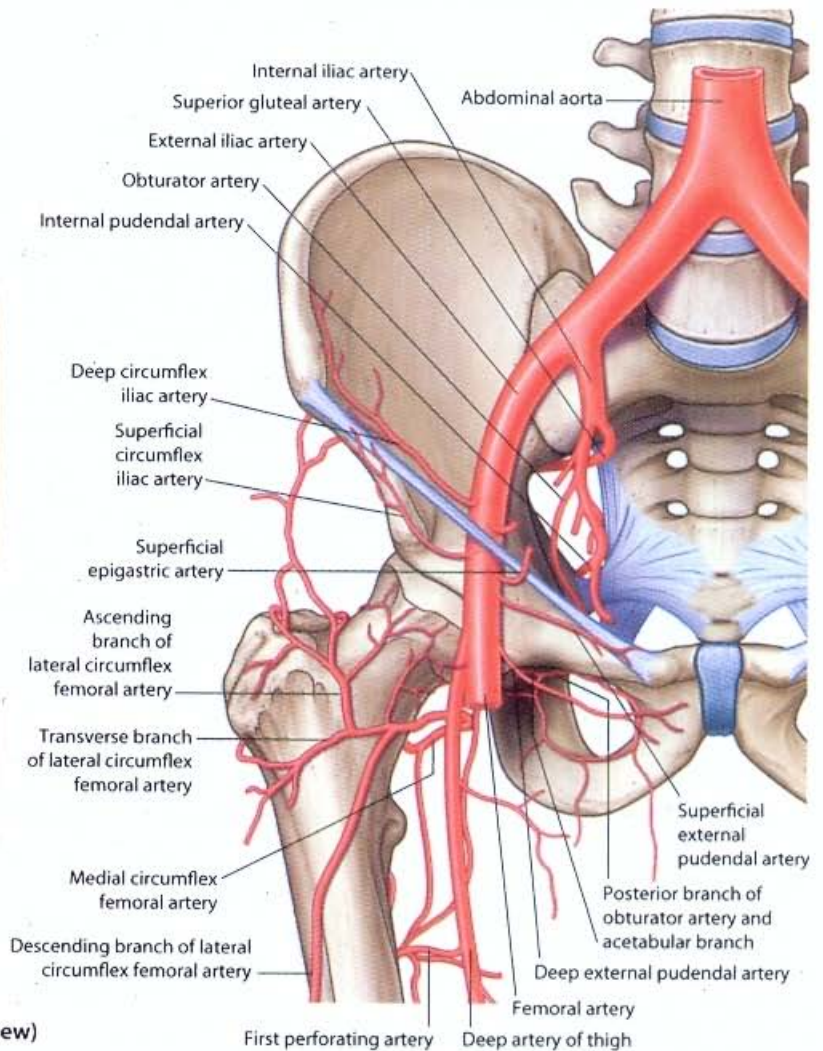
Joint capsule and synovial membrane



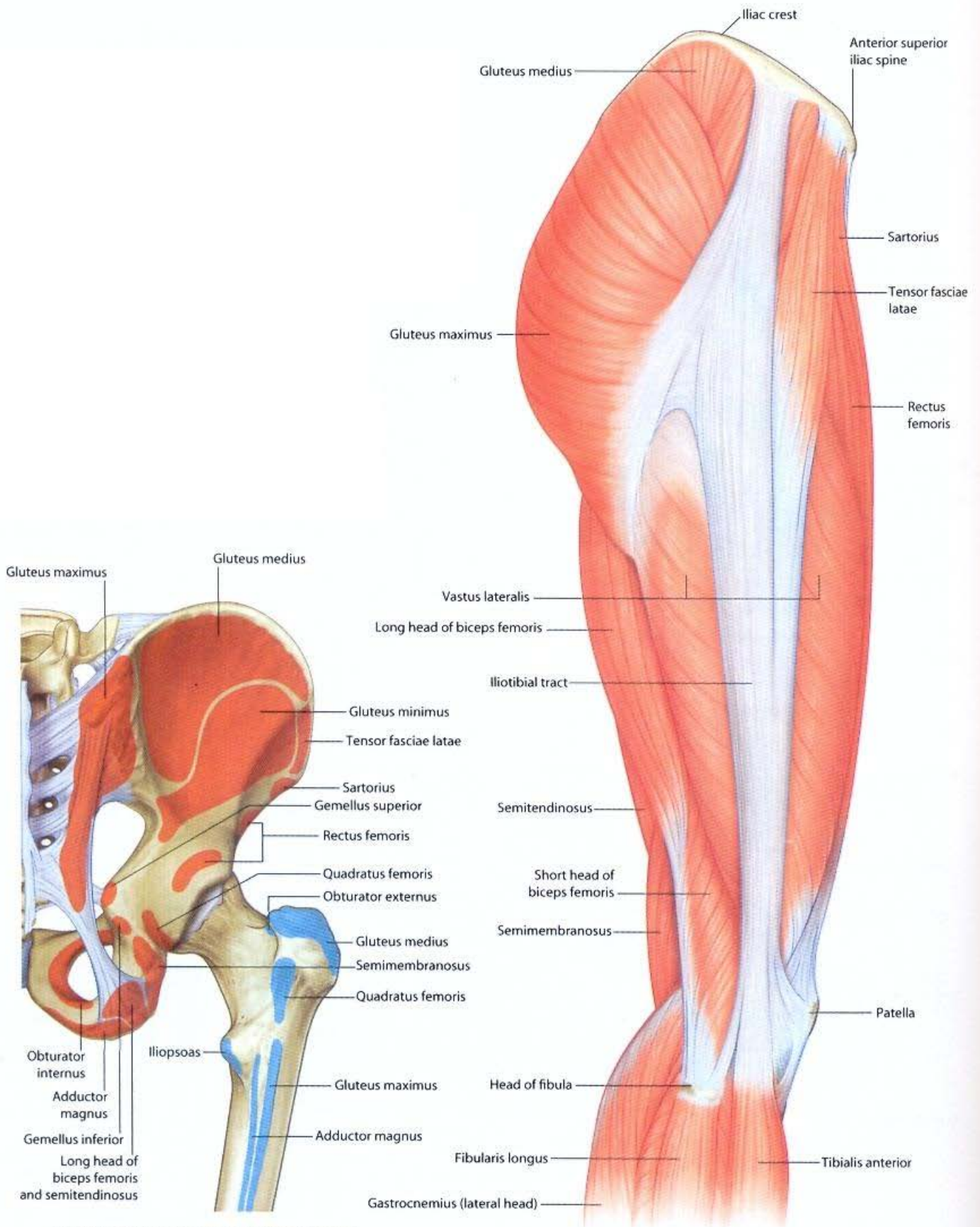
Ischiofemoral ligament (posterior view)



Iliofemoral and pubofemoral ligaments (anterior view)

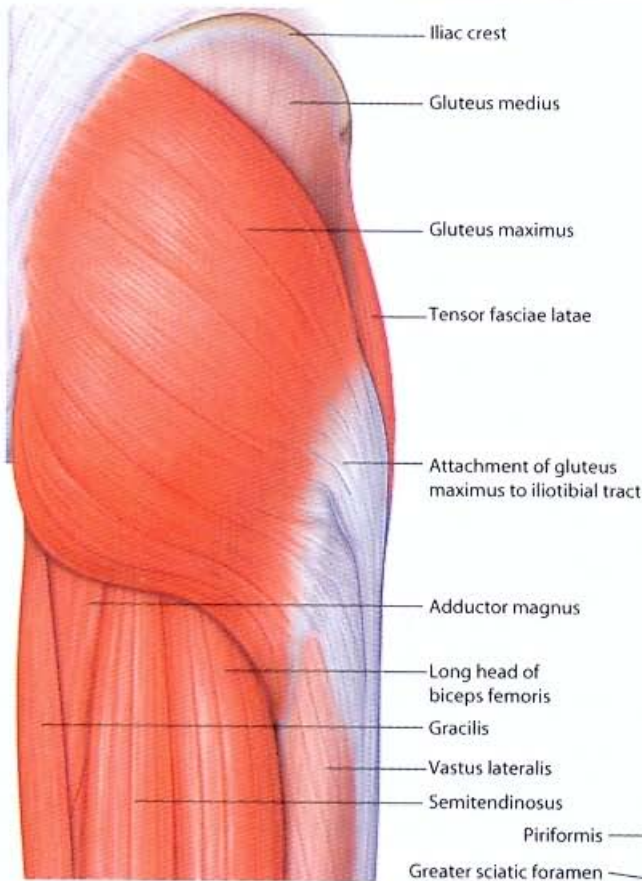


Arterial supply of the hip joint

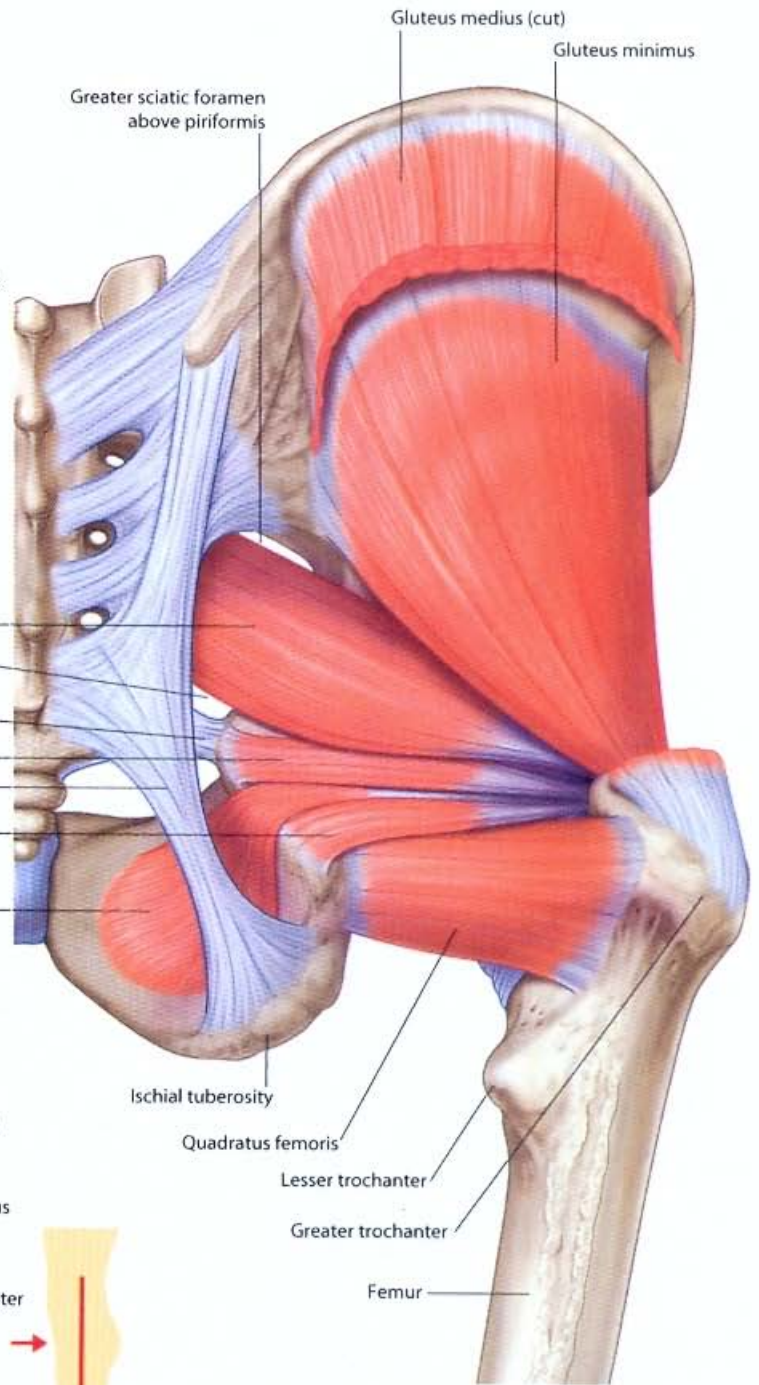


**Muscle attachments of the gluteal region**

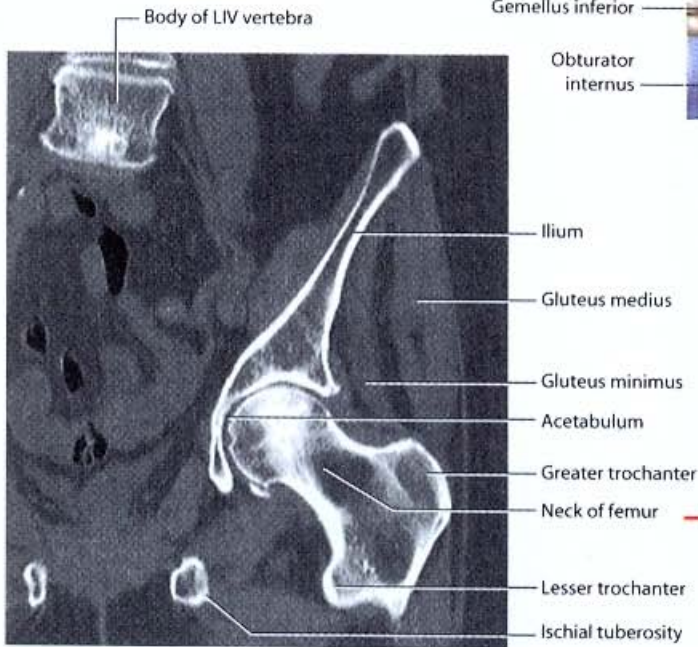
**Muscles of the hip and thigh (lateral view)**



Superficial muscles of the gluteal region (posterior view)

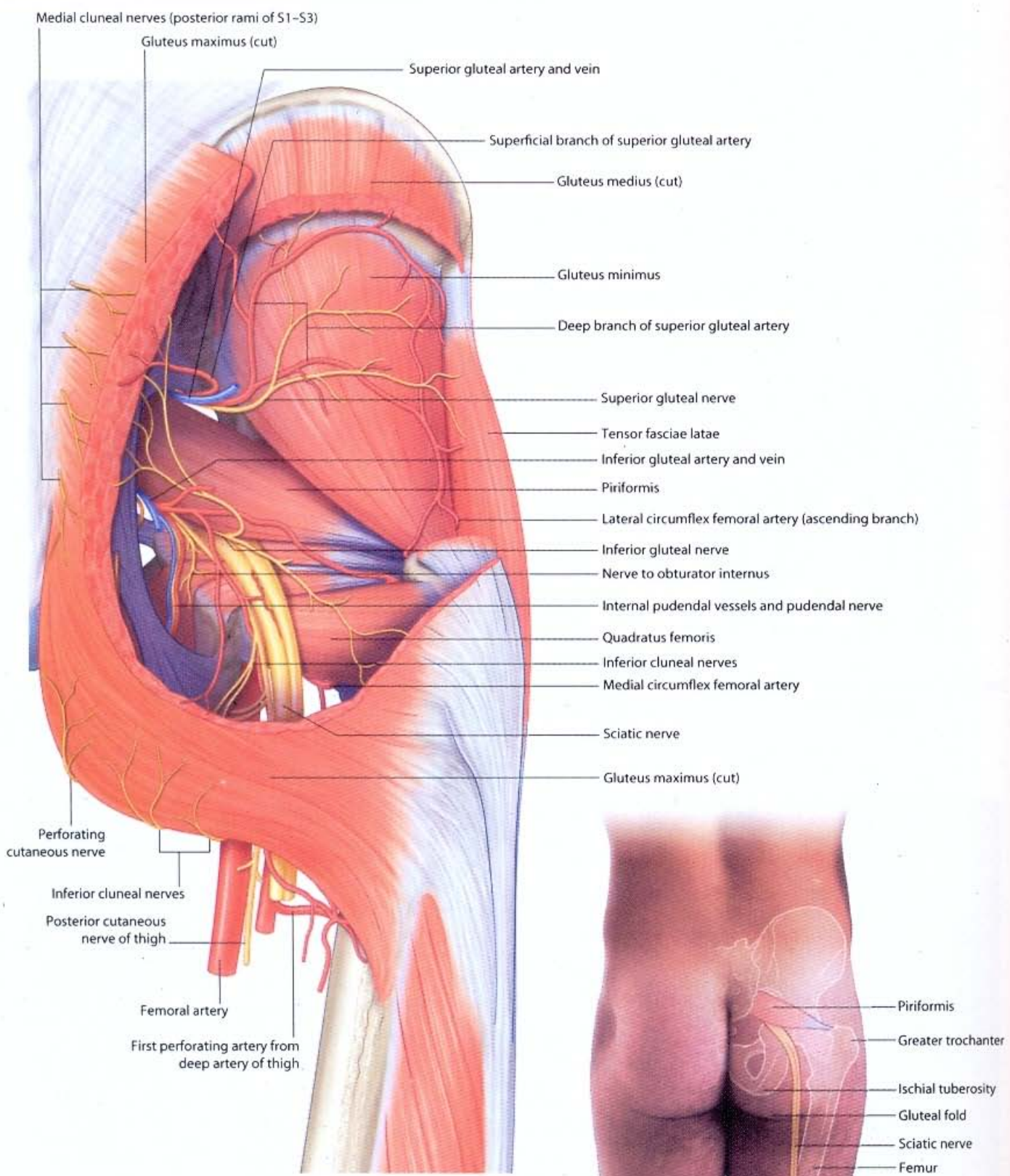


Deep muscles of the gluteal region (posterior view)



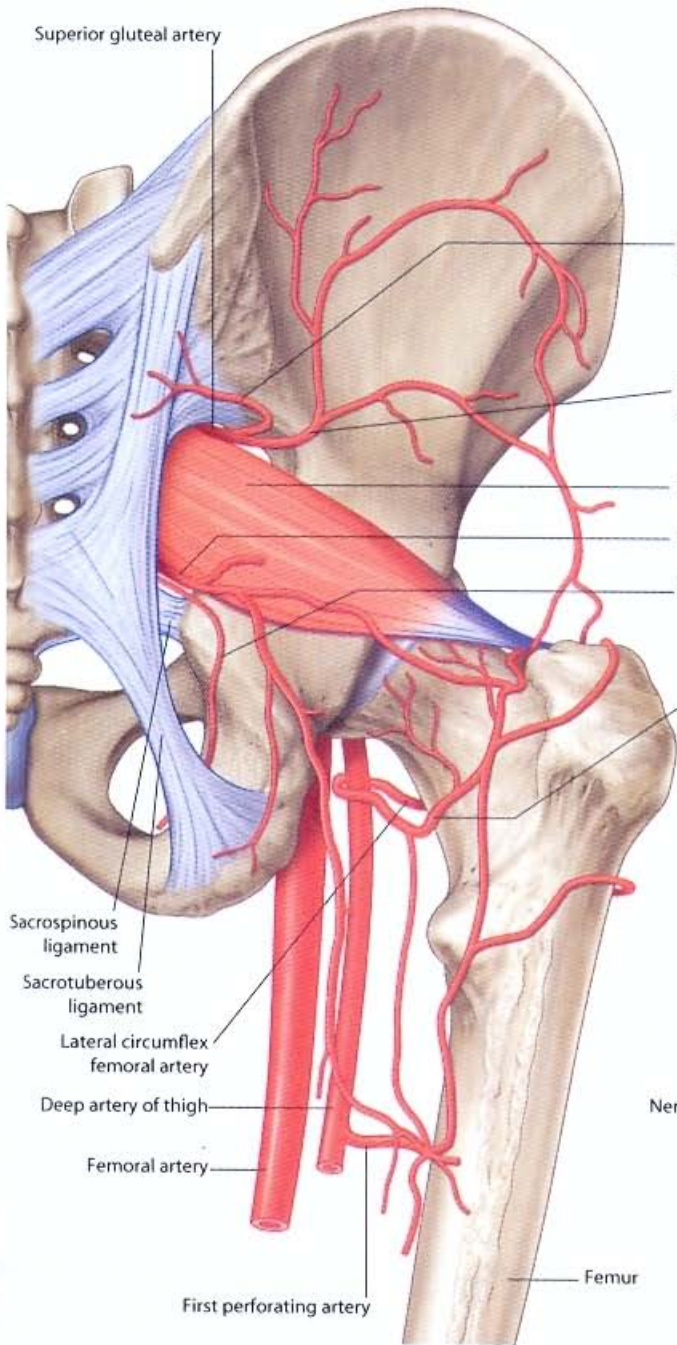
Positioning of gluteus medius and minimus muscles in relation to the hip joint.  
CT image in coronal plane

**LOWER LIMB • Gluteal region: arteries and nerves**

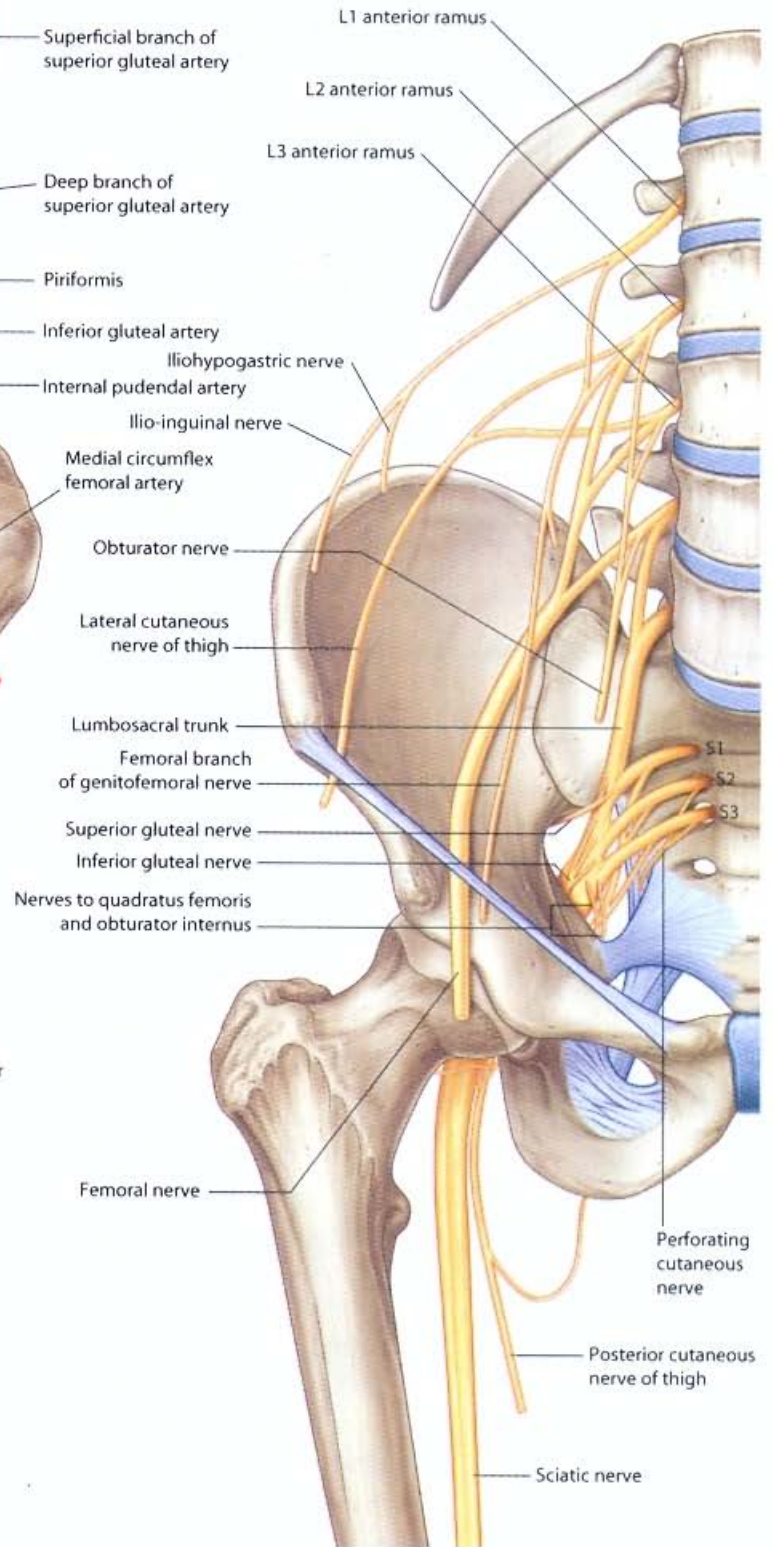


Arteries and nerves of the gluteal region

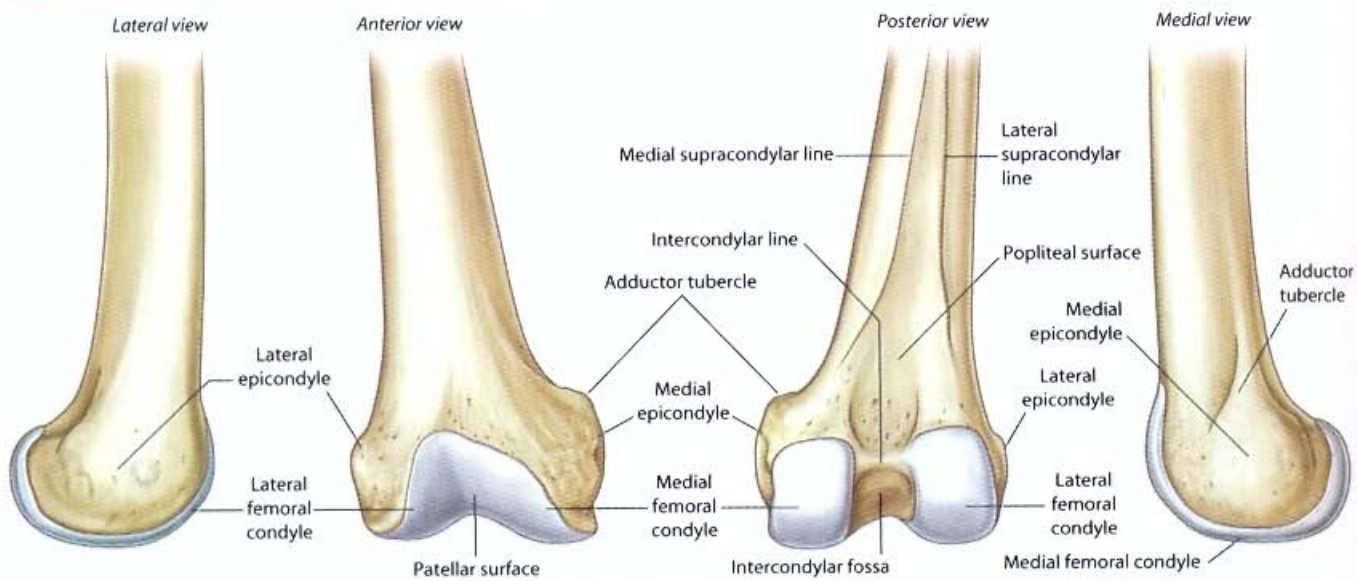
Sciatic nerve in the gluteal region as it relates to the surface (posterior view)



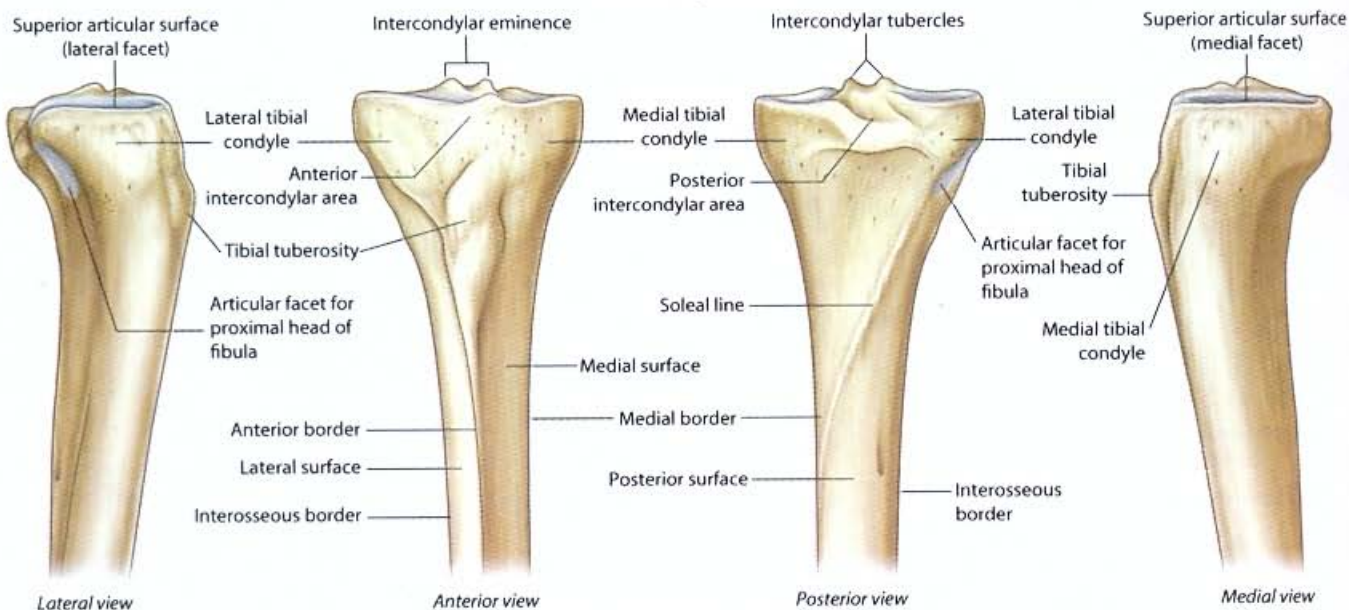
Arteries of the gluteal region



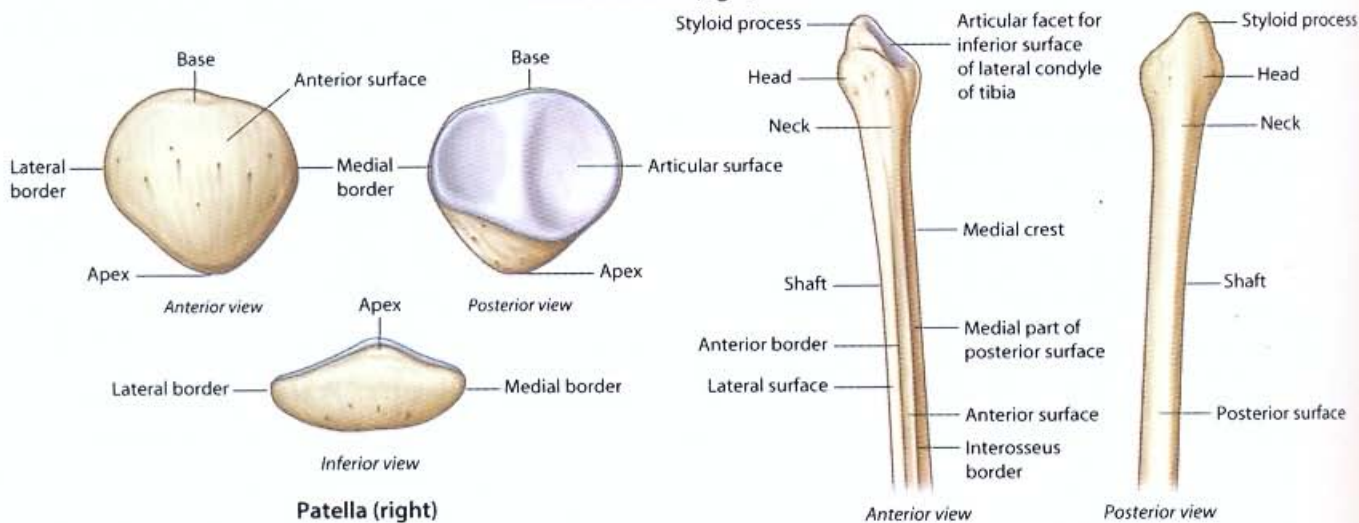
Branches of the lumbosacral plexus related to lower limb



**Distal end of (right) femur**

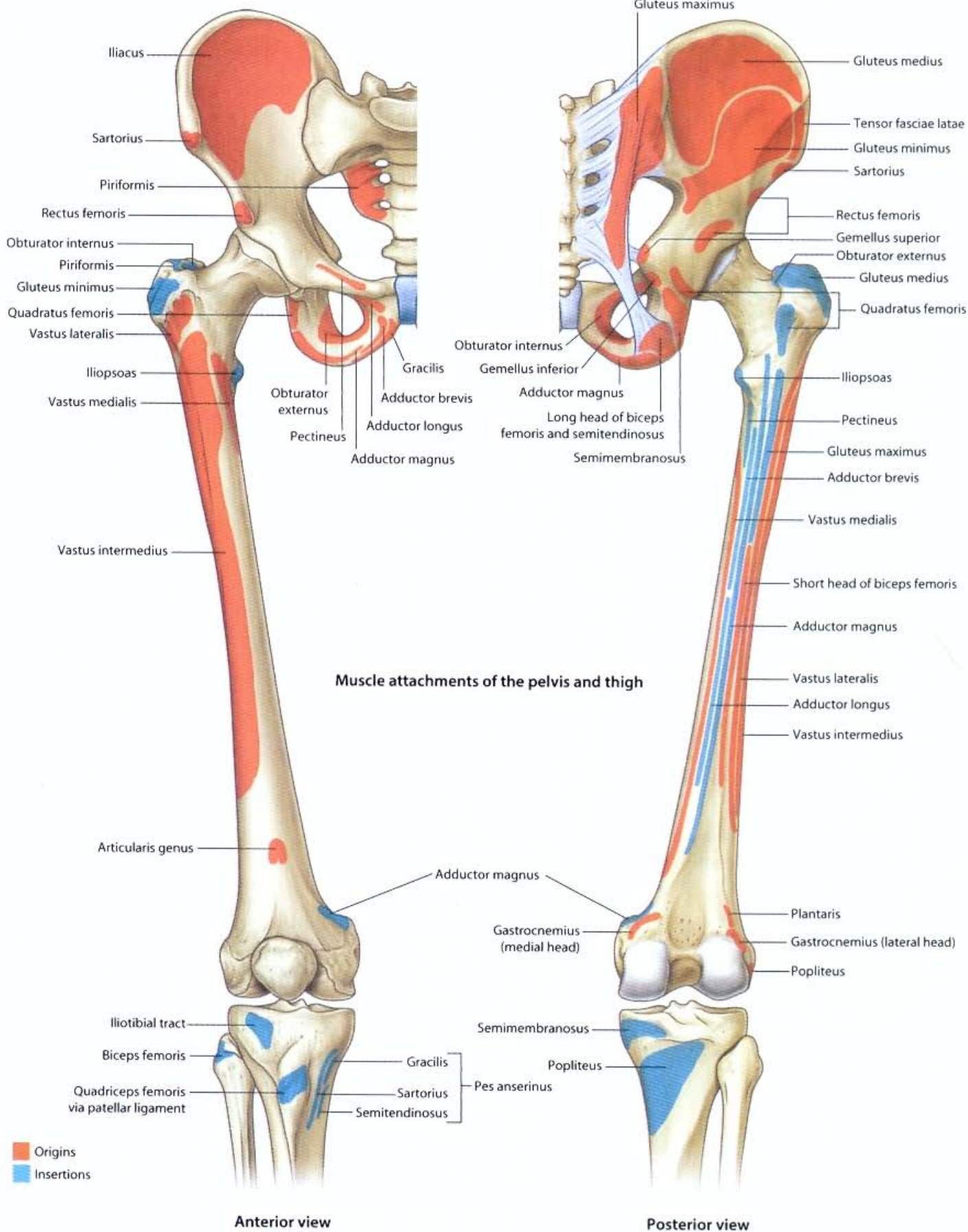


**Proximal end of (right) tibia**

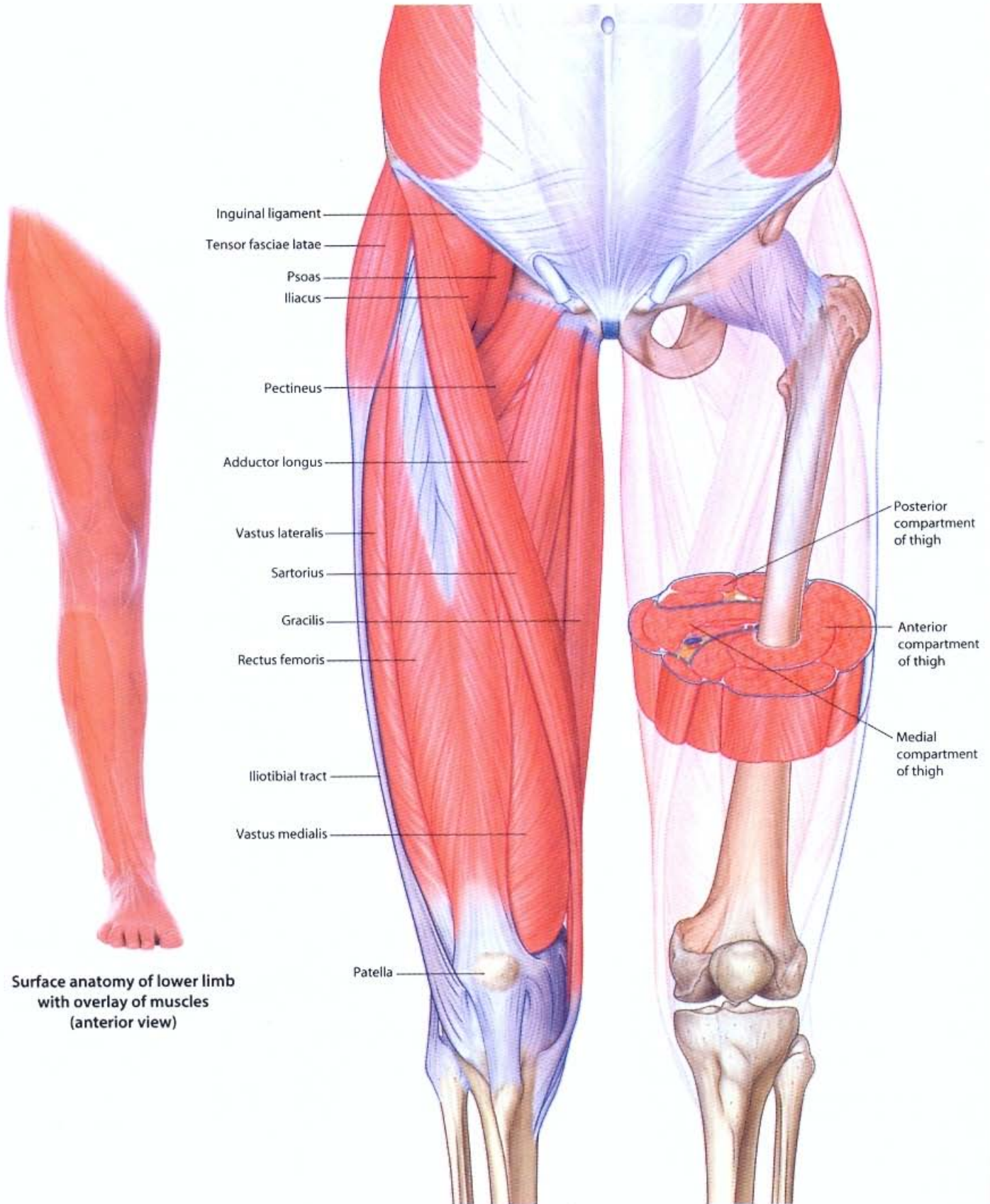


**Patella (right)**

**Proximal end of (right) fibula**

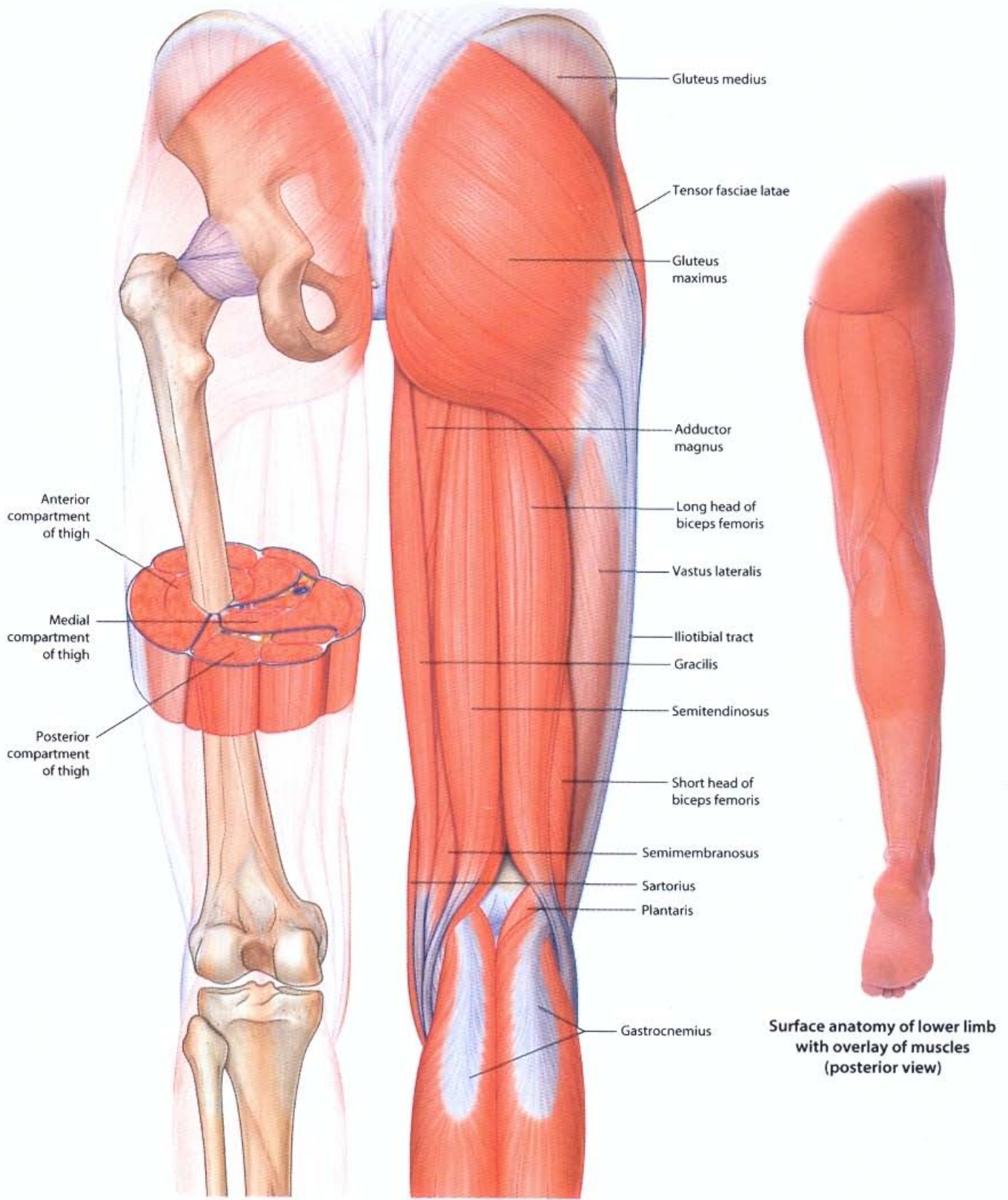




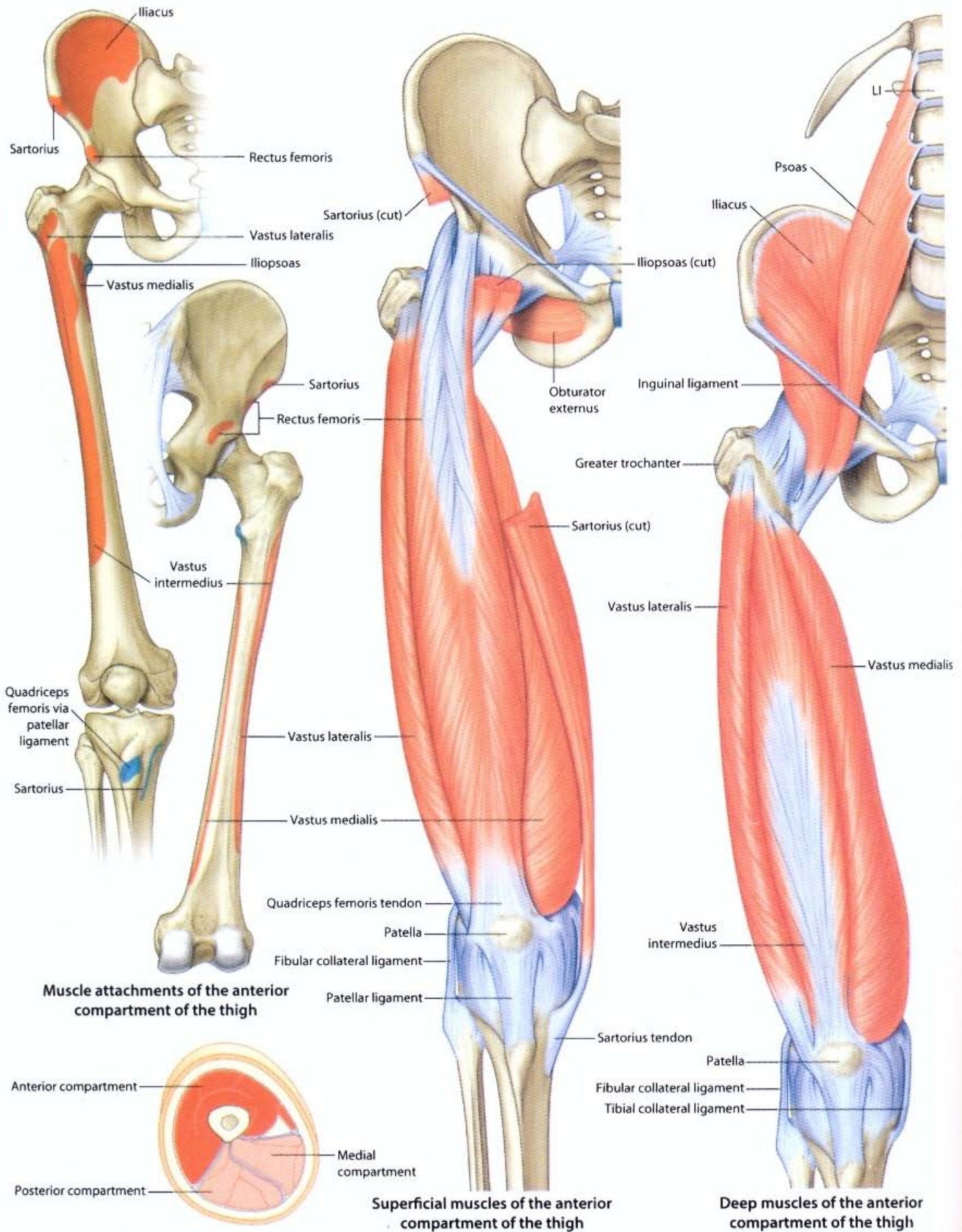


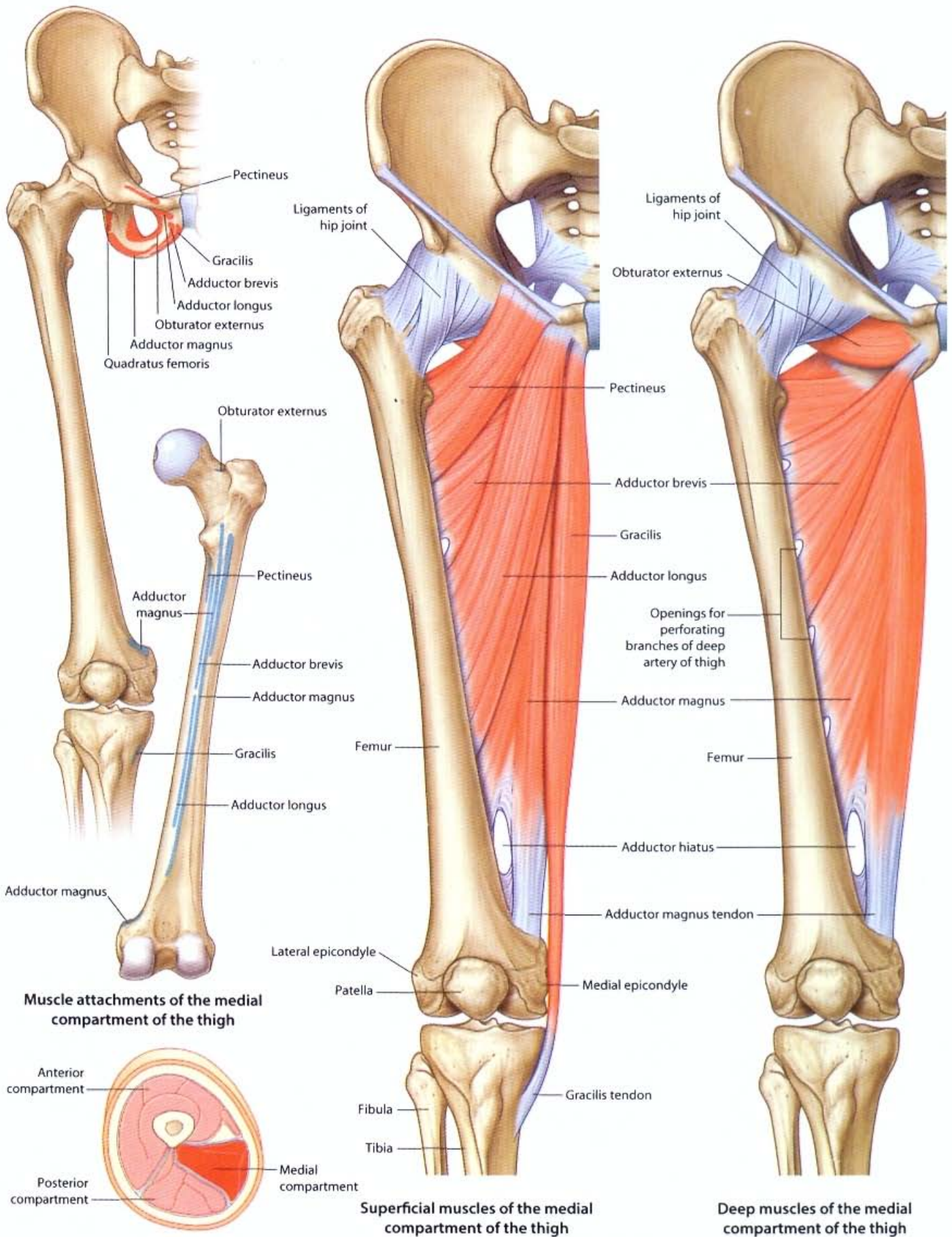
Surface anatomy of lower limb with overlay of muscles (anterior view)

Superficial muscles of the thigh (anterior view)



Superficial muscles of the thigh (posterior view)

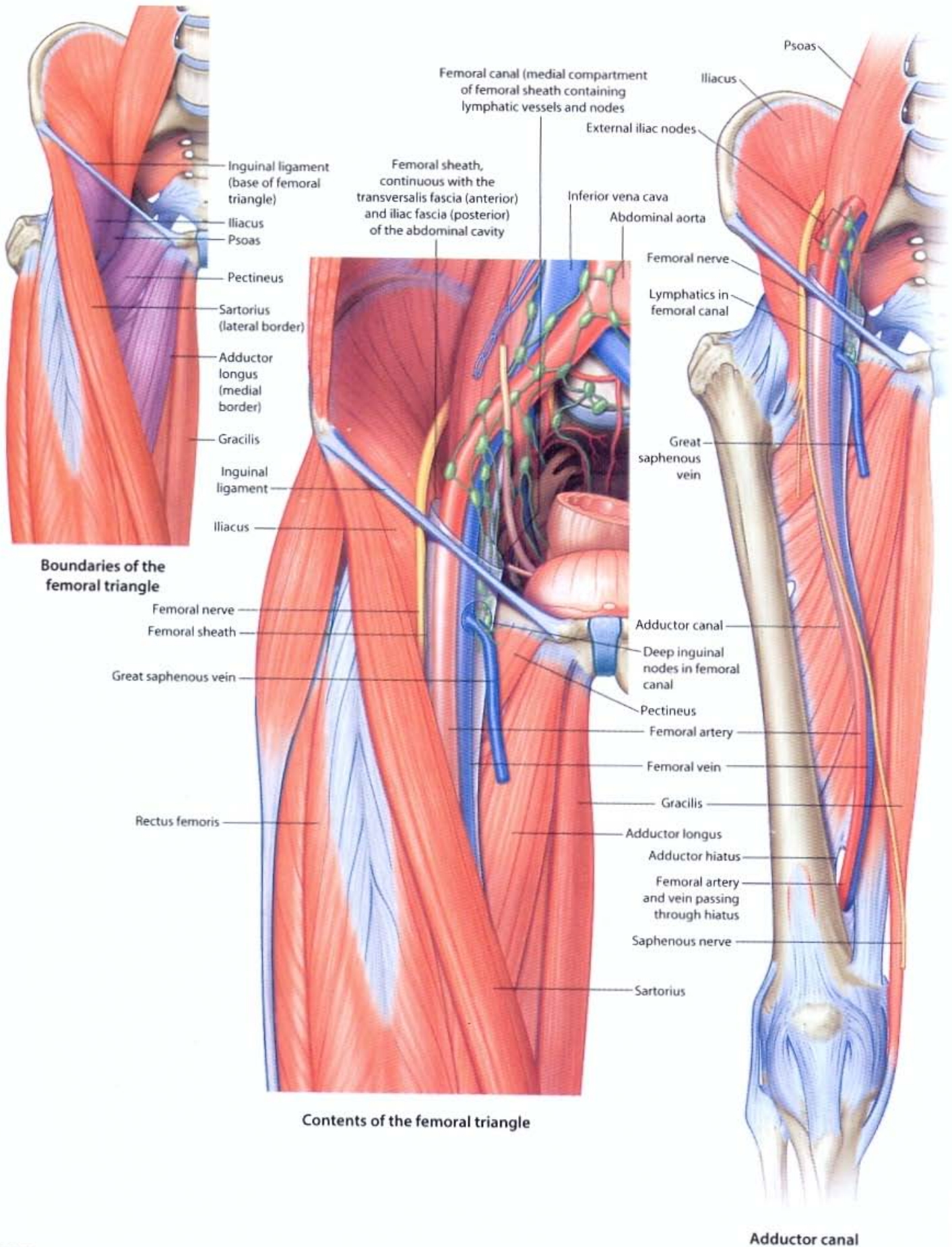


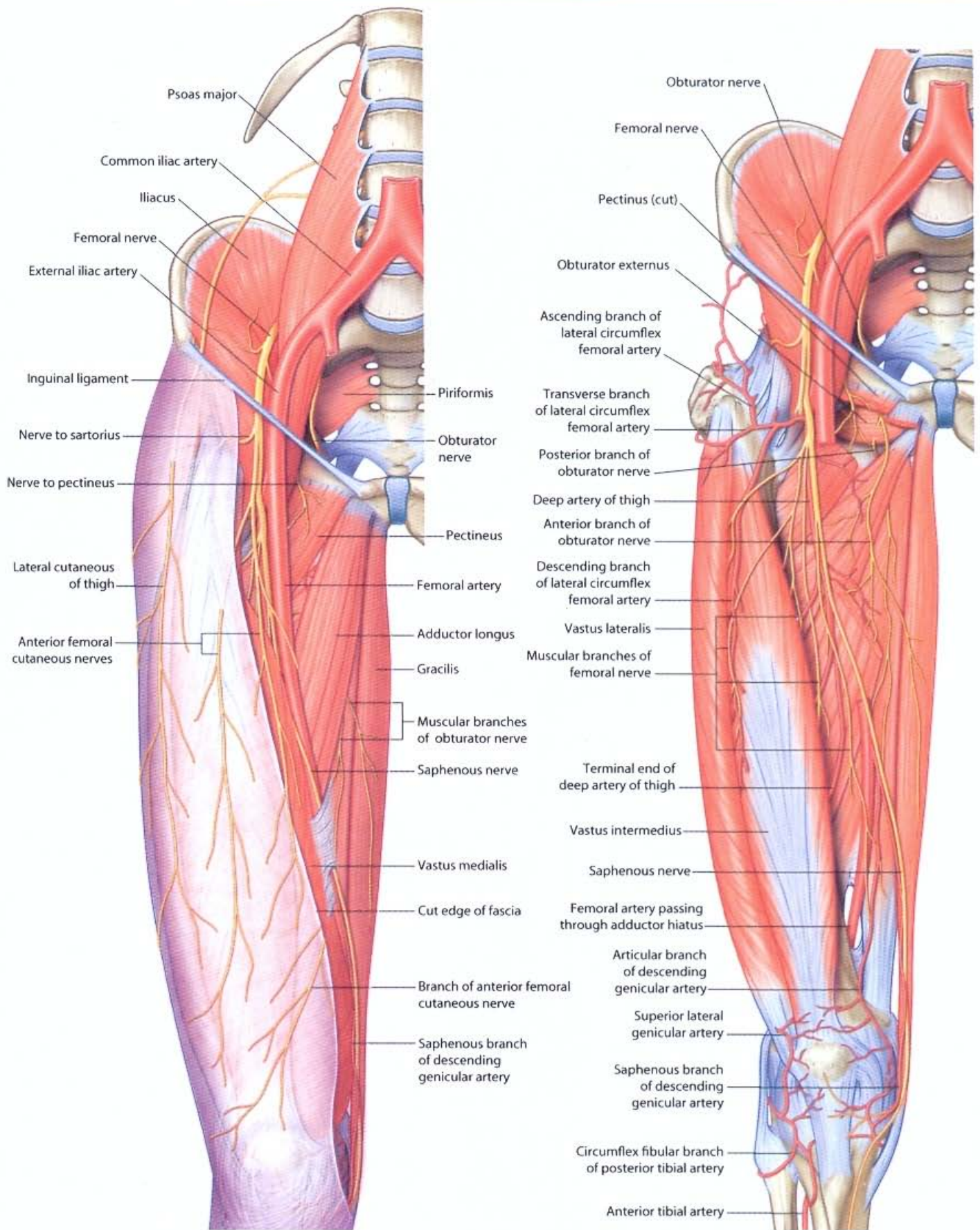


Muscle attachments of the medial compartment of the thigh

Superficial muscles of the medial compartment of the thigh

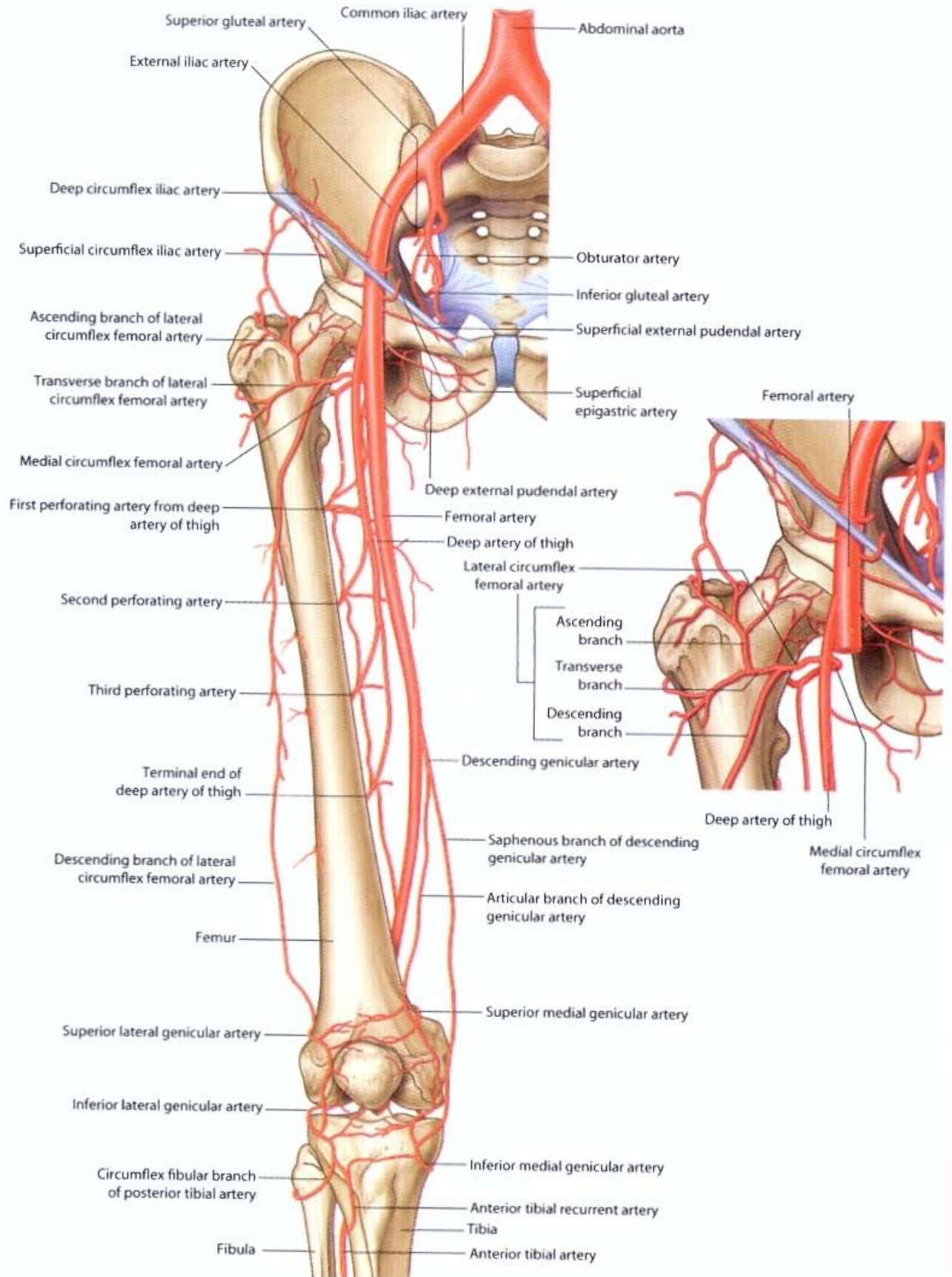
Deep muscles of the medial compartment of the thigh



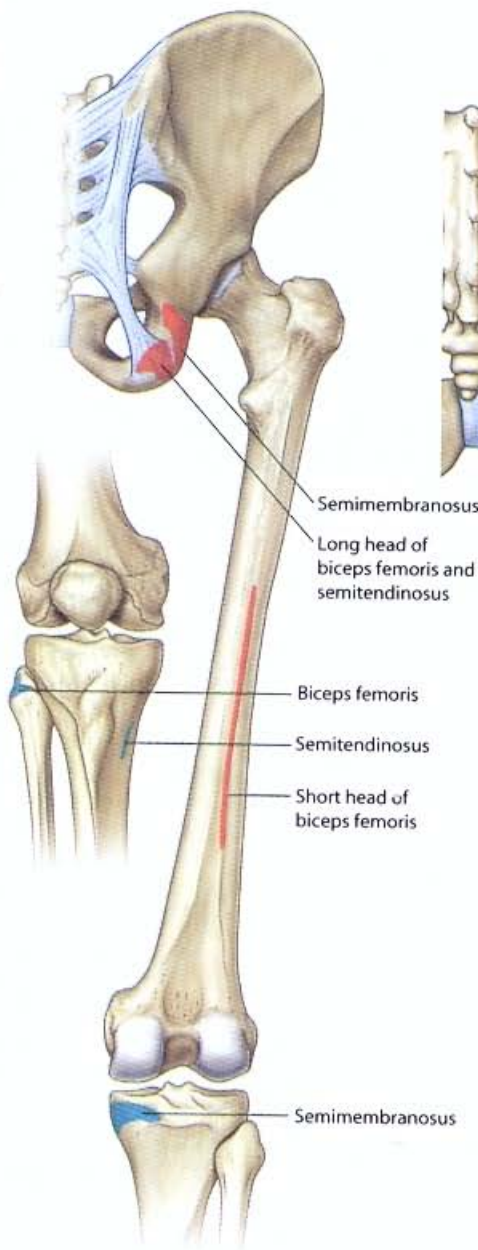


Superficial arteries and nerves of the thigh (anterior view)

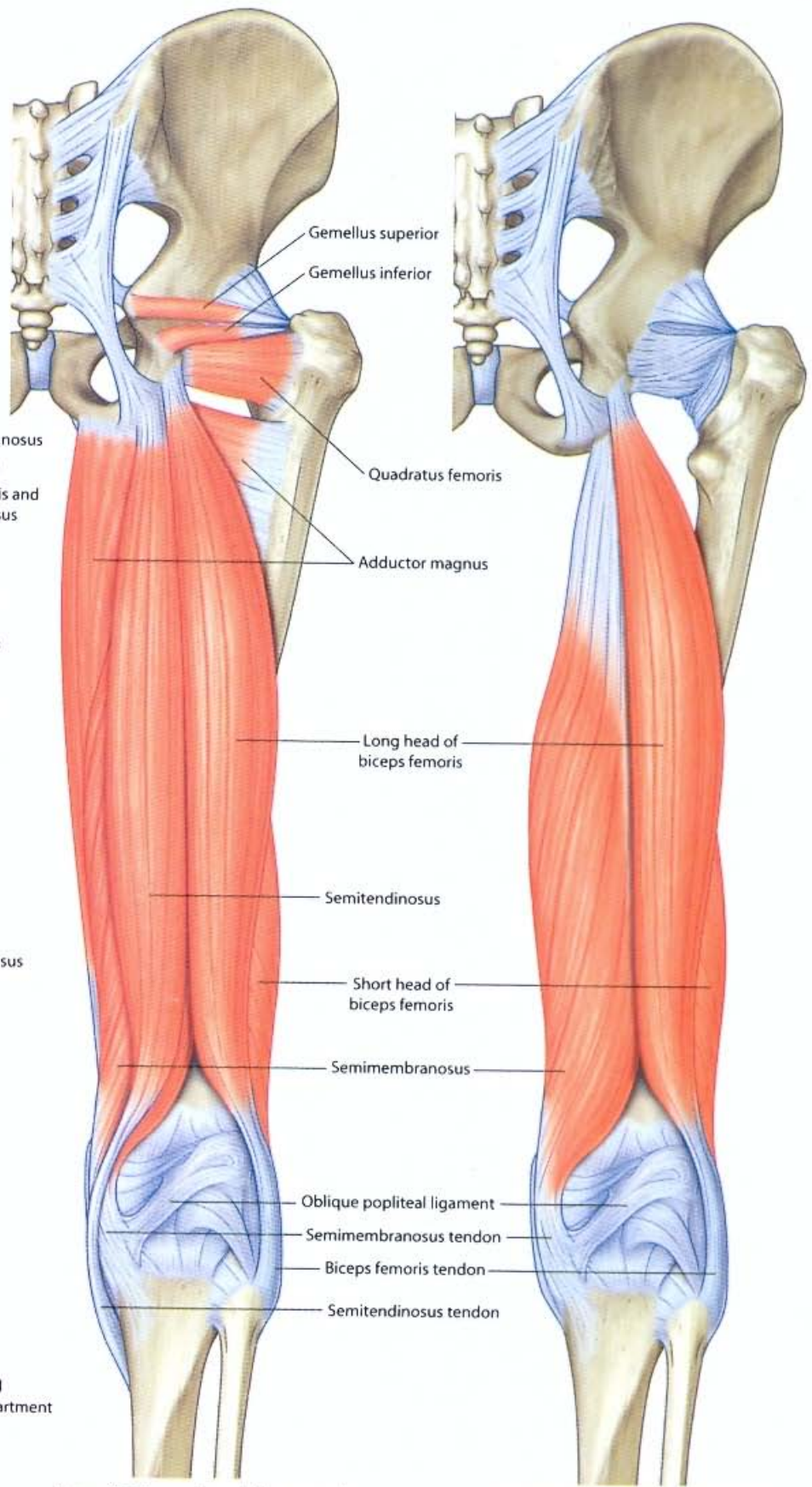
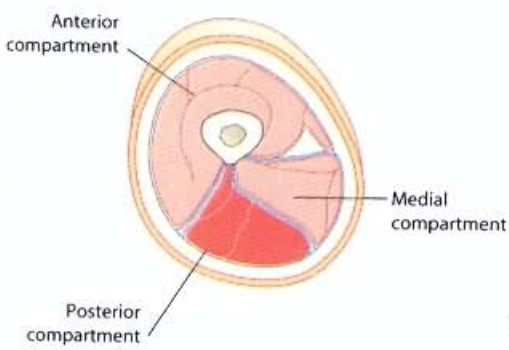
Deep arteries and nerves of the thigh (anterior view)



**Arteries of the thigh (anterior view)**



Muscle attachments of the posterior compartment of the thigh

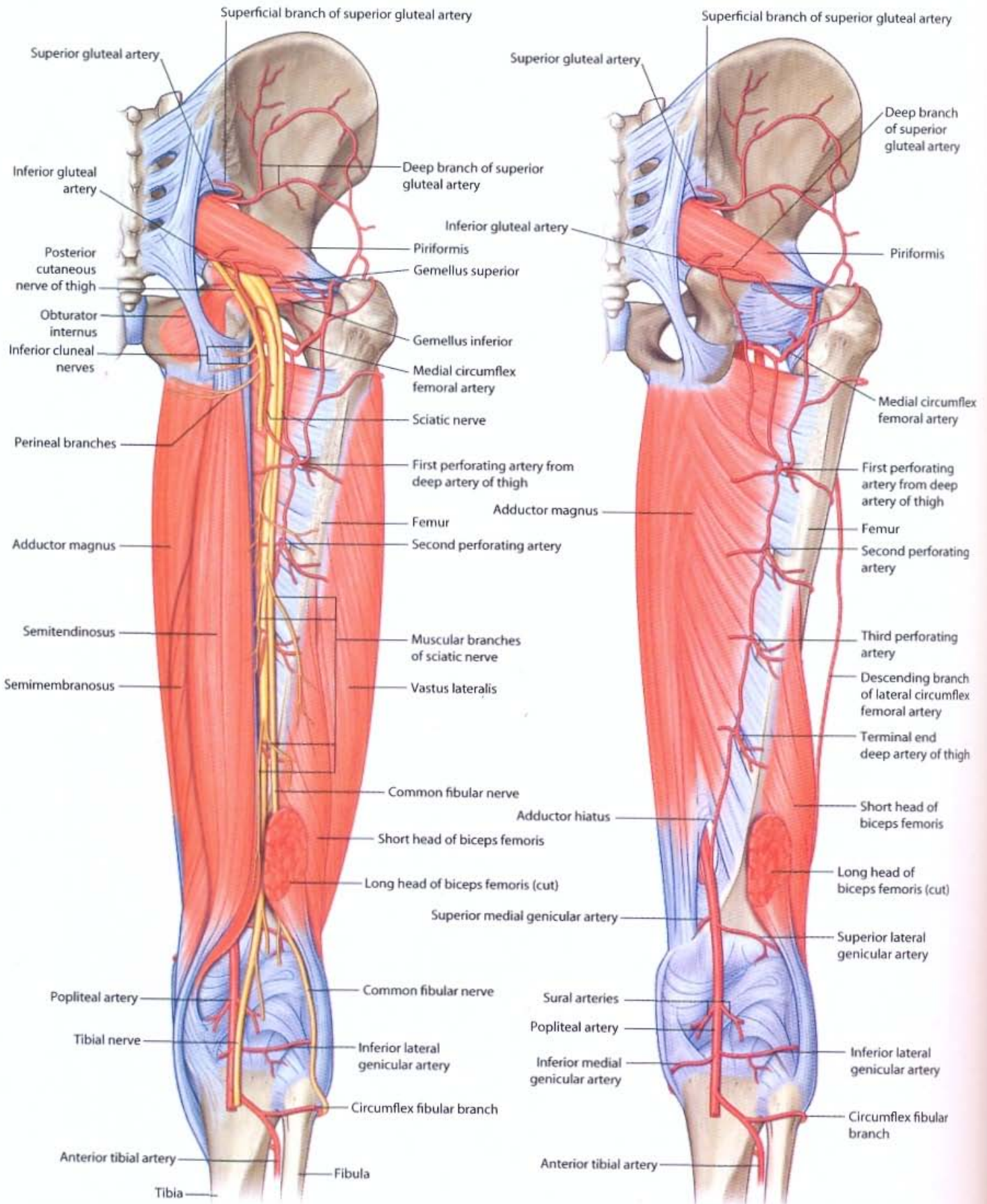


Superficial muscles of the posterior compartment of the thigh

Deep muscles of the posterior compartment of the thigh

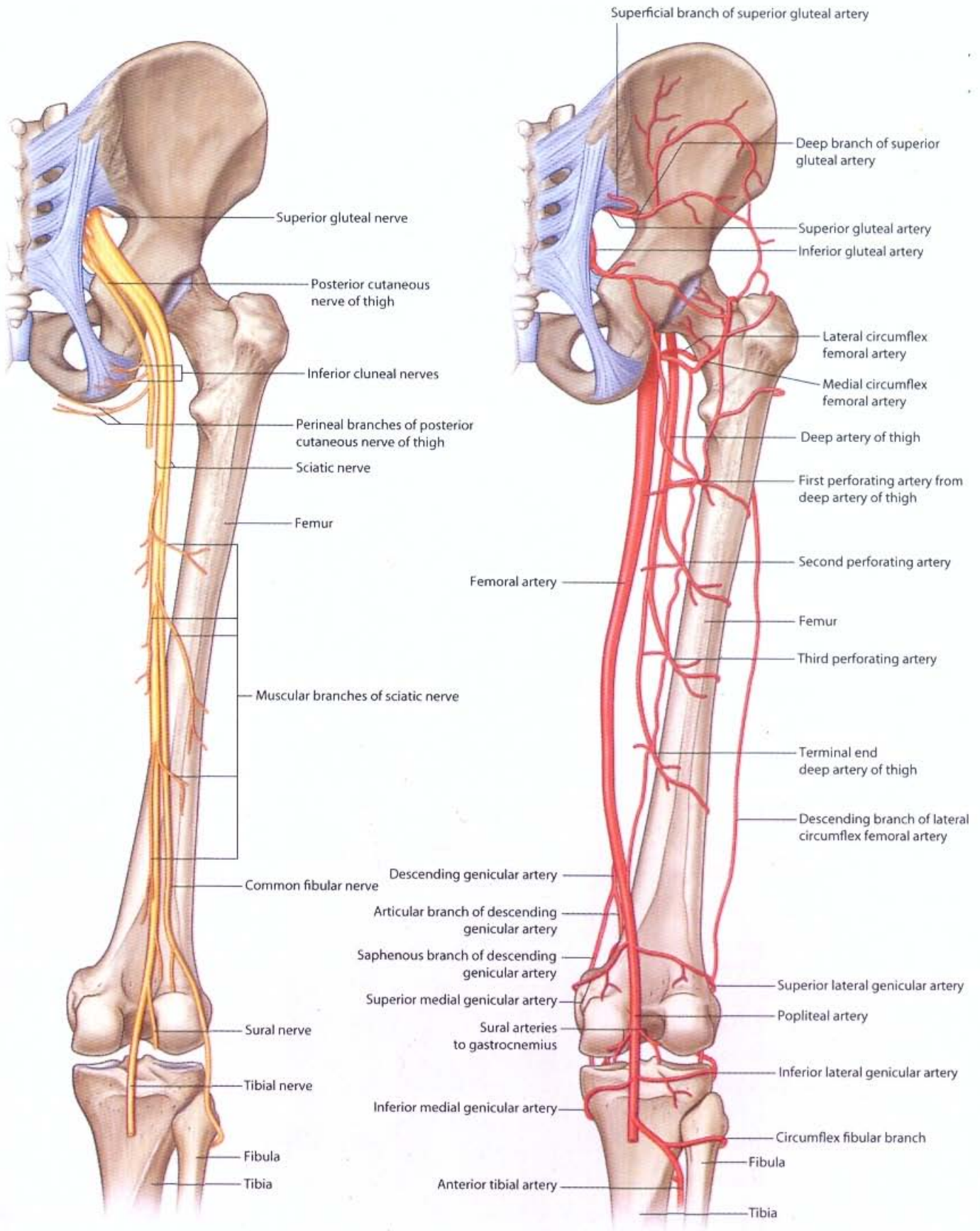


# LOWER LIMB • Posterior thigh: arteries and nerves



Arteries and nerves of the thigh (posterior view)

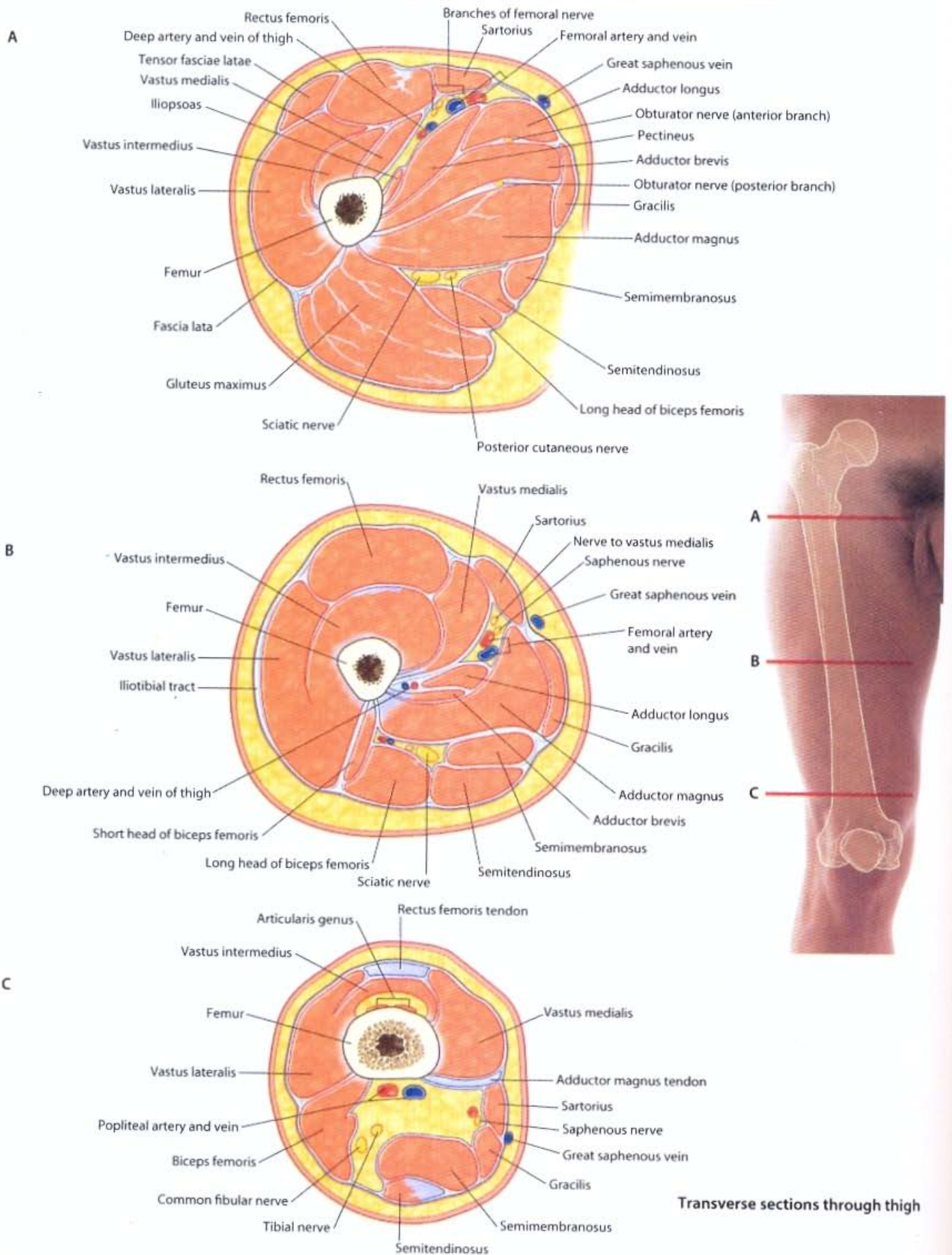
Deep arteries of the thigh (posterior view)

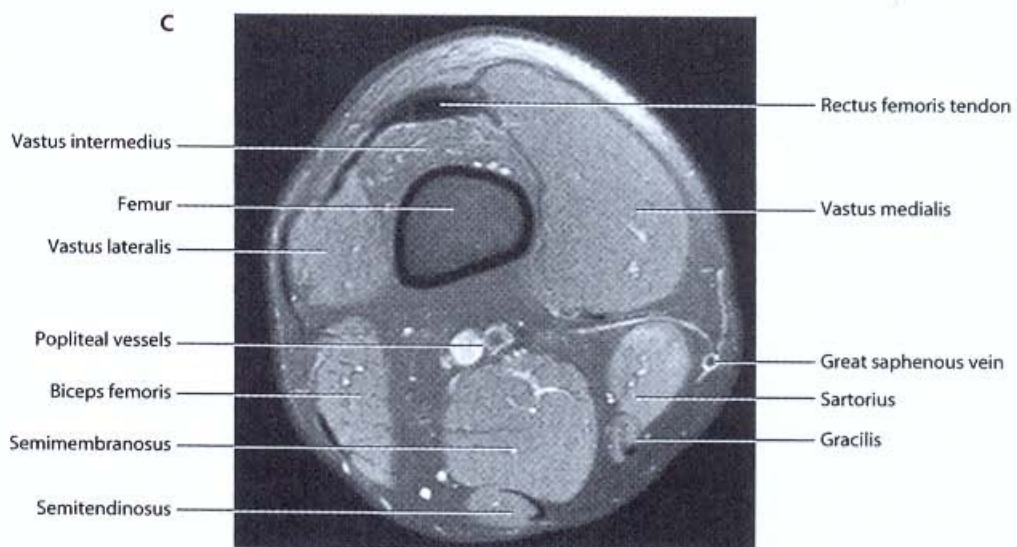
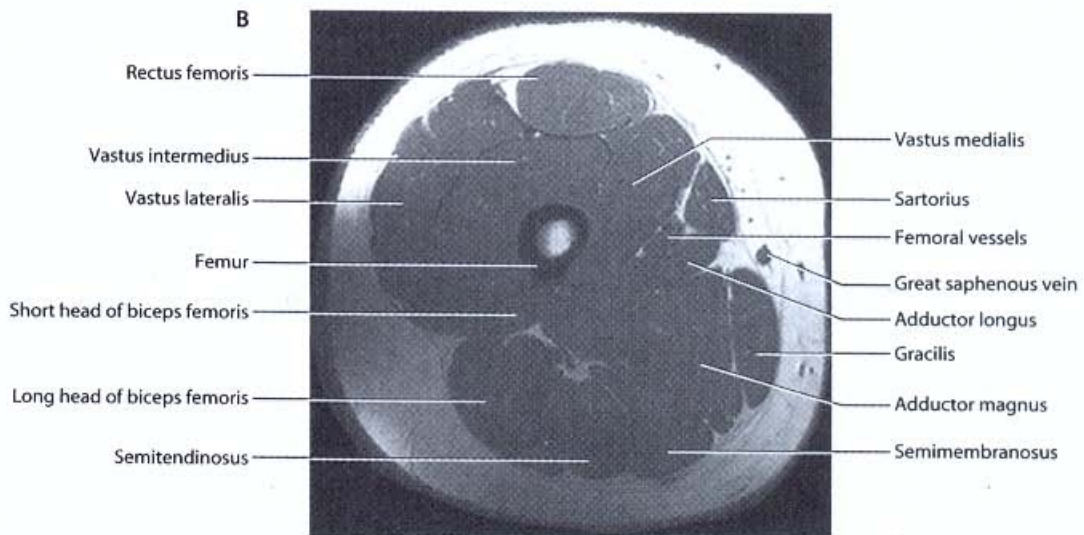
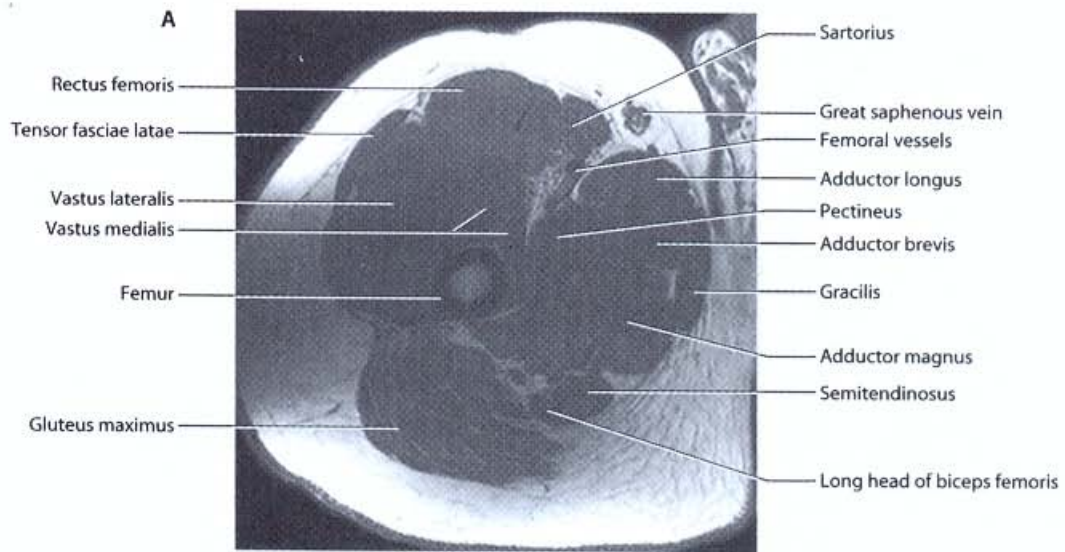
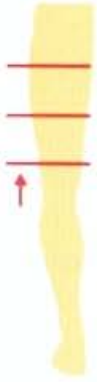

Nerves of the thigh (posterior view)

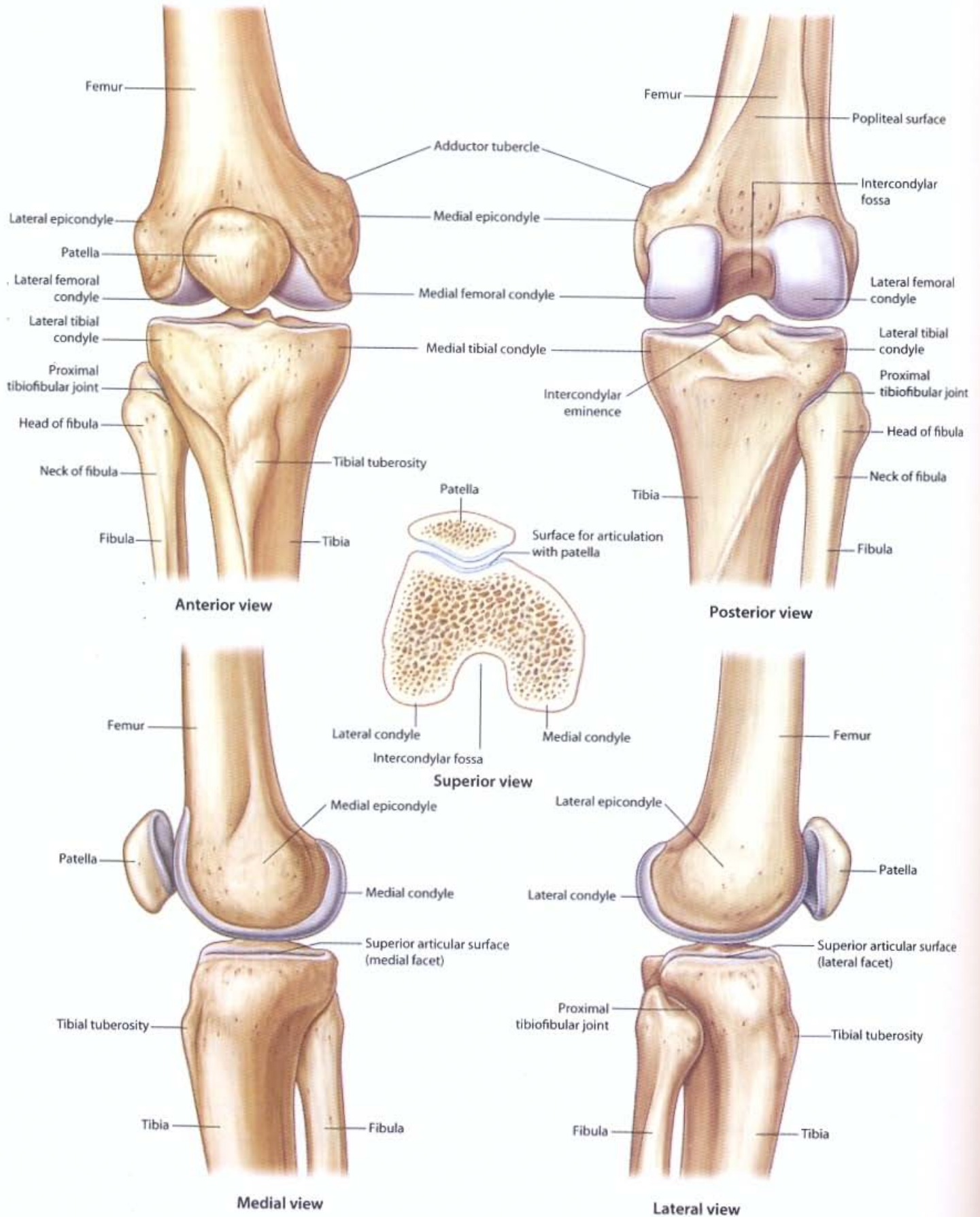
Arteries of the thigh (posterior view)

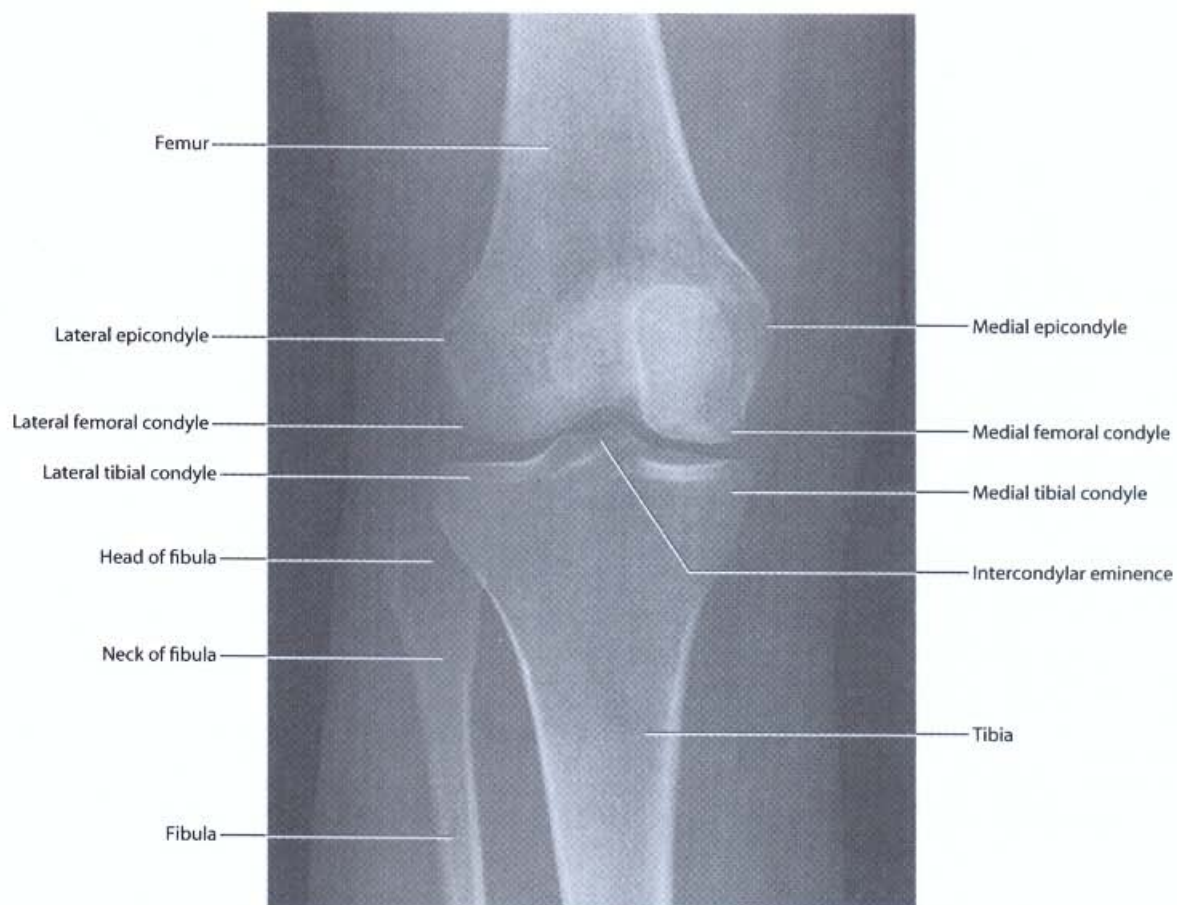
# LOWER LIMB • Transverse sections: thigh



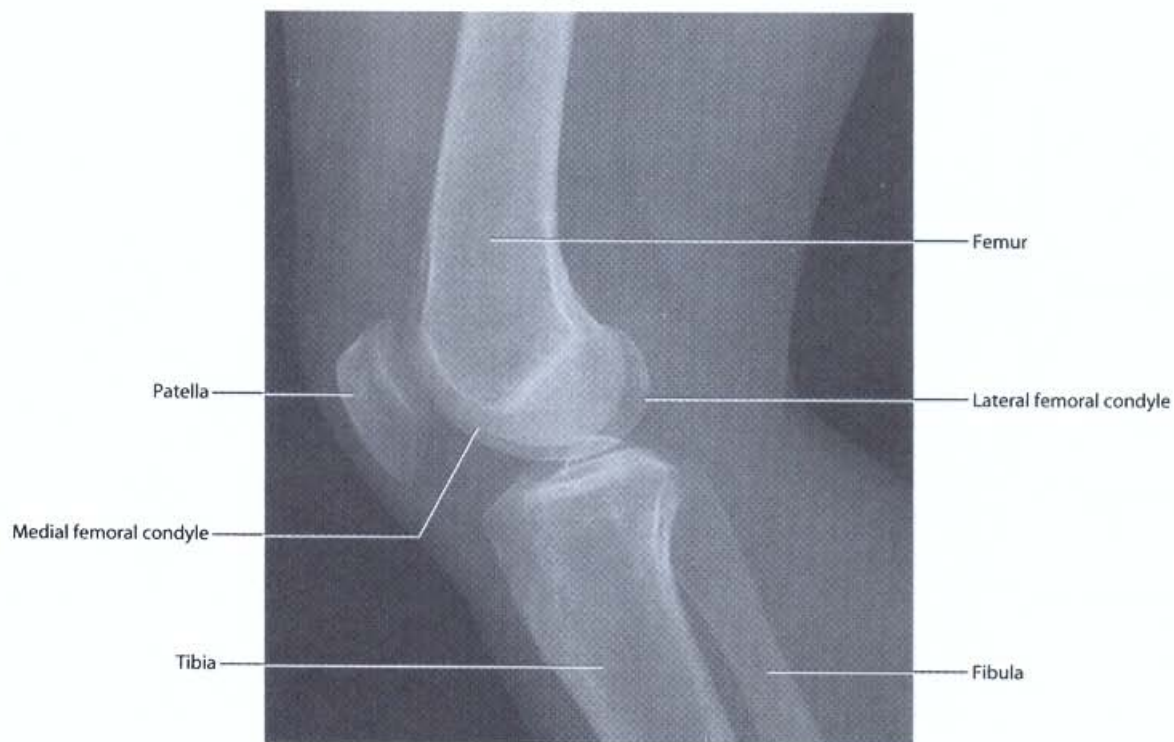

**Transverse/axial sections through the thigh.**  
**A.** Proximal/upper thigh. T1-weighted MR image in axial plane  
**B.** Middle thigh. T1-weighted MR image in axial plane  
**C.** Distal/lower thigh. T2-weighted MR image in axial plane

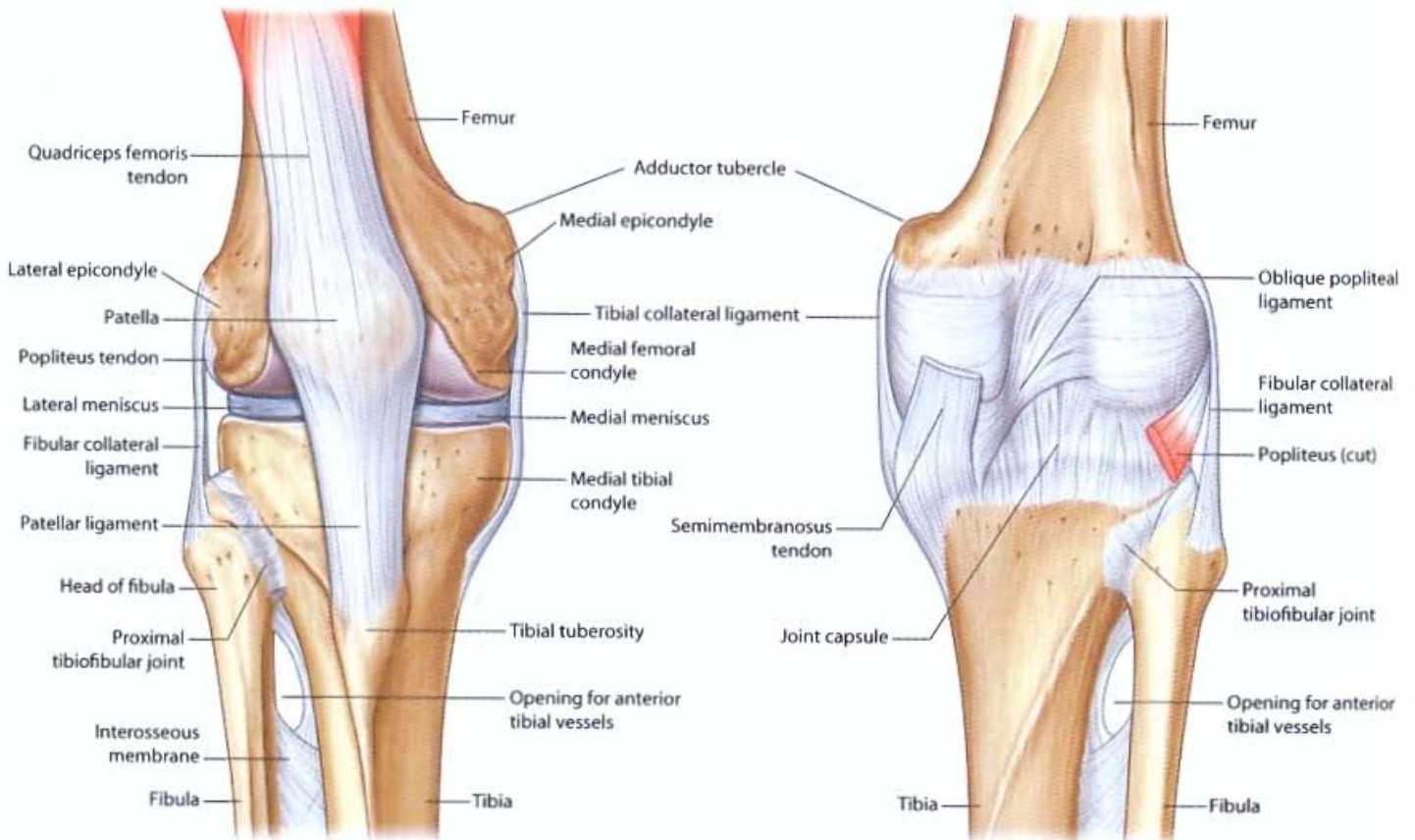




**Normal knee joint.**  
Radiograph, AP view

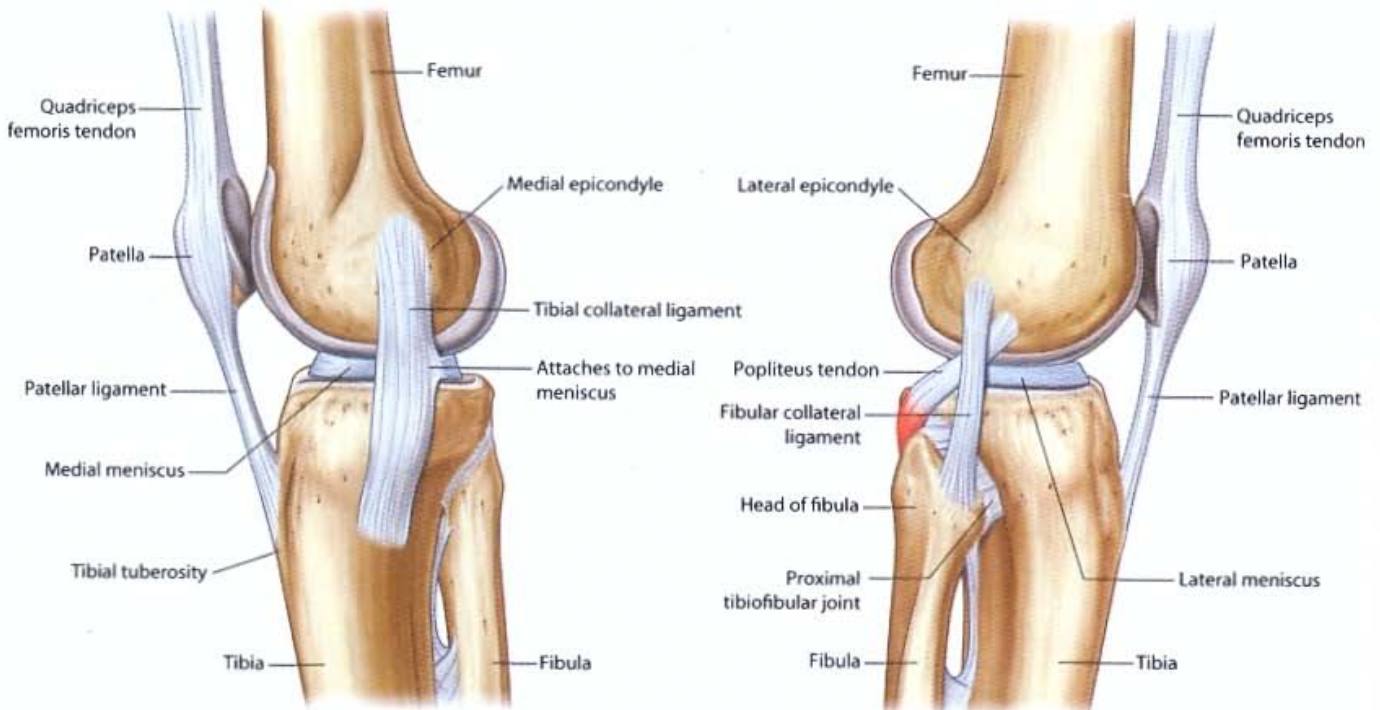


**Normal knee joint.**  
Radiograph, lateral view



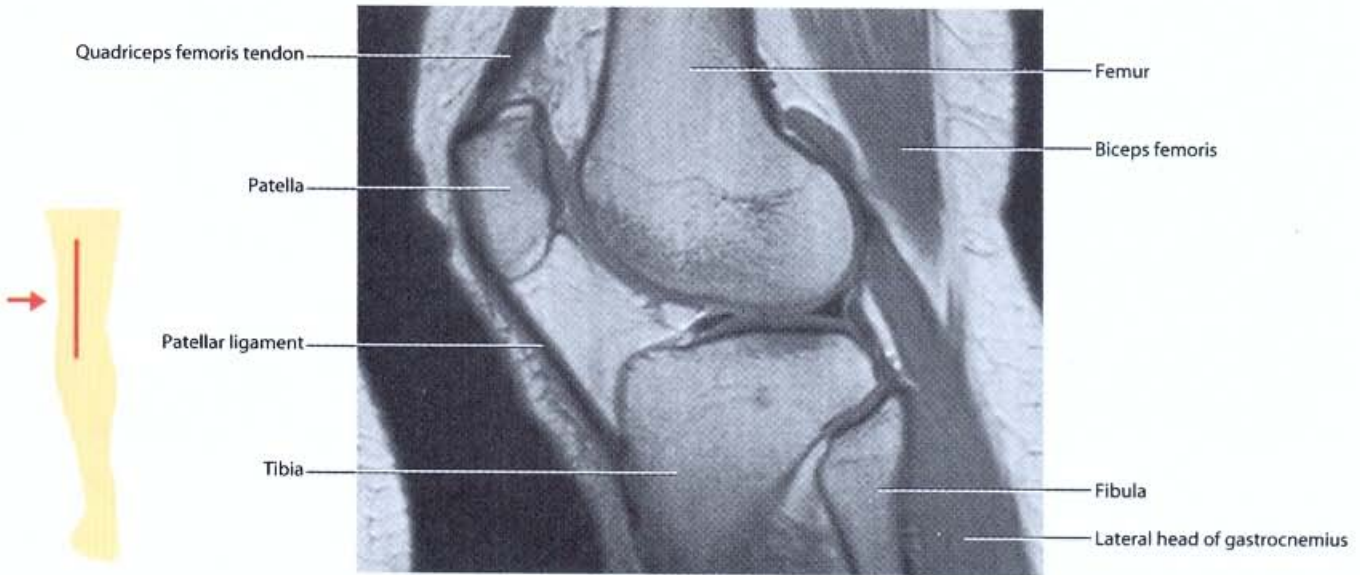
**Anterior view**

**Posterior view**

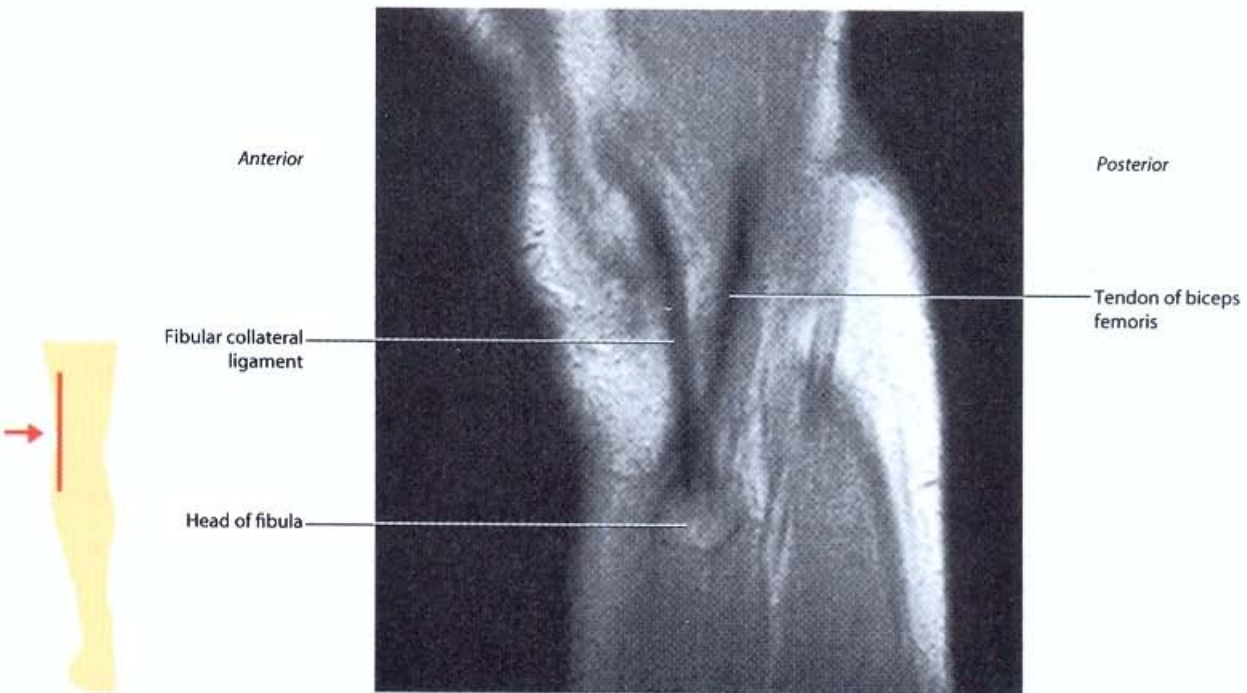


**Medial view**

**Lateral view**

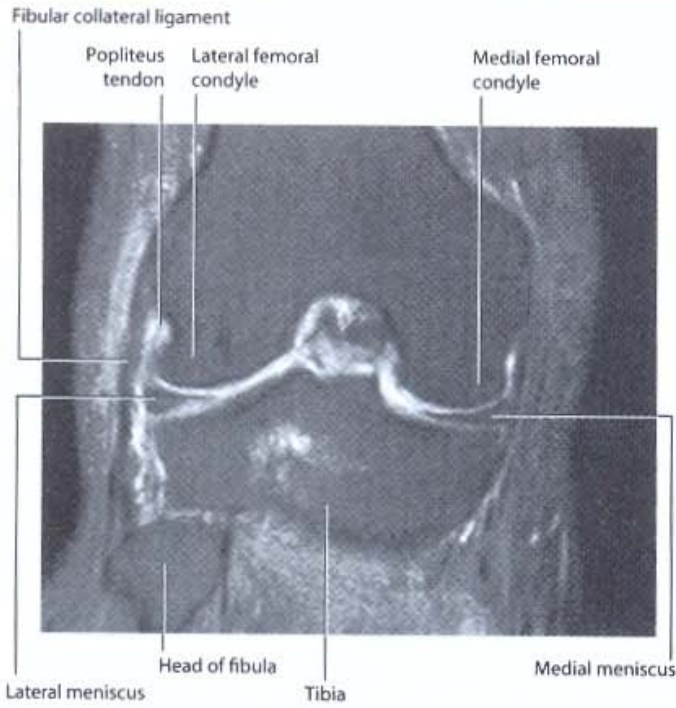


**Normal knee joint.**  
T2-weighted MR image in sagittal plane

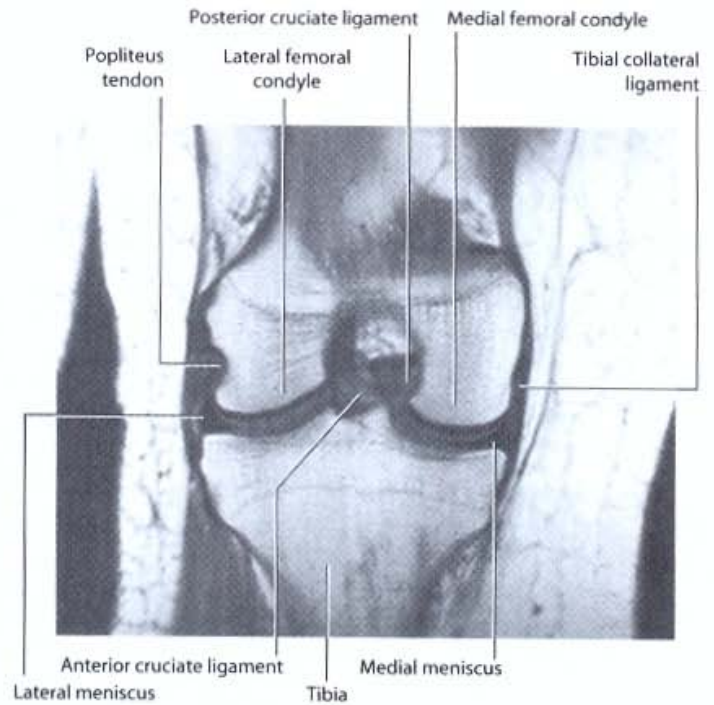


**Unique view showing the fibular collateral ligament and the tendon of the biceps femoris muscle attaching to the head of the fibula.**  
T2-weighted MR image in sagittal plane

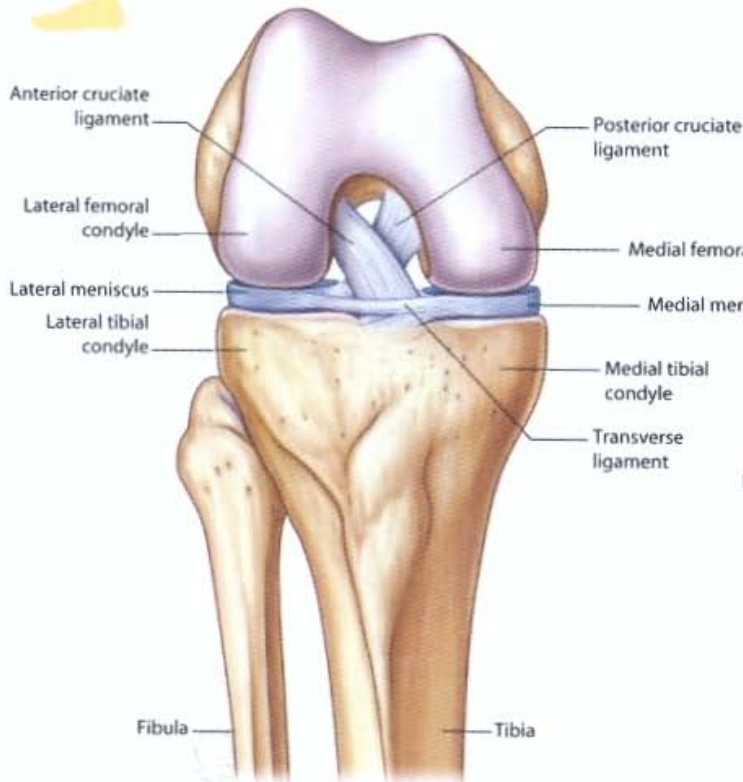




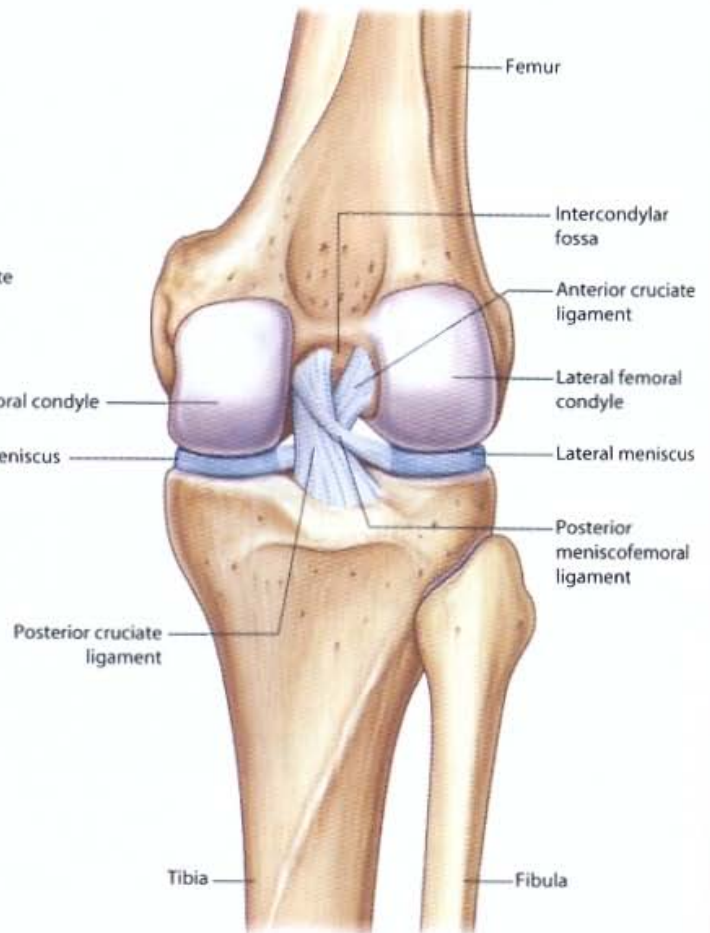
**Coronal view of knee joint showing the fibular collateral ligament and its relationship to surrounding structures.**  
T2-weighted MR image in coronal plane



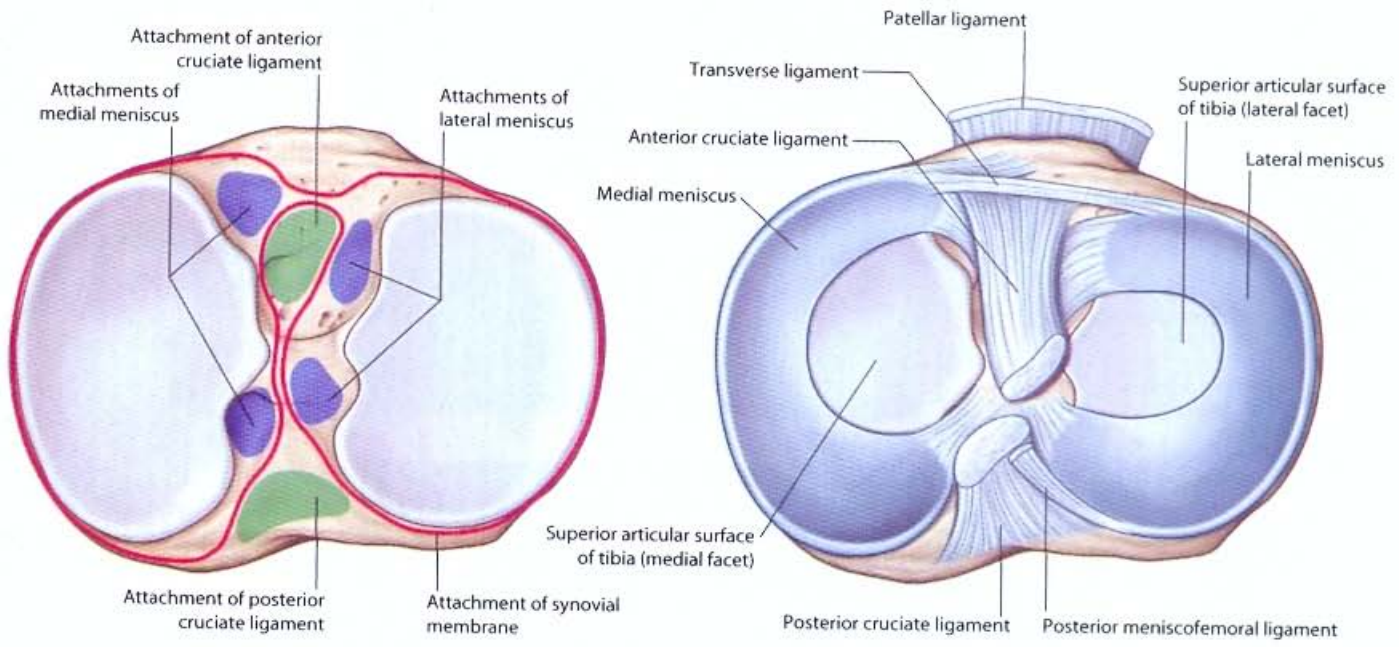
**Anterior view of knee joint showing the relationship between the tibial collateral ligament and the medial meniscus.**  
T1-weighted MR image in coronal plane



**Anterior view (flexed)**

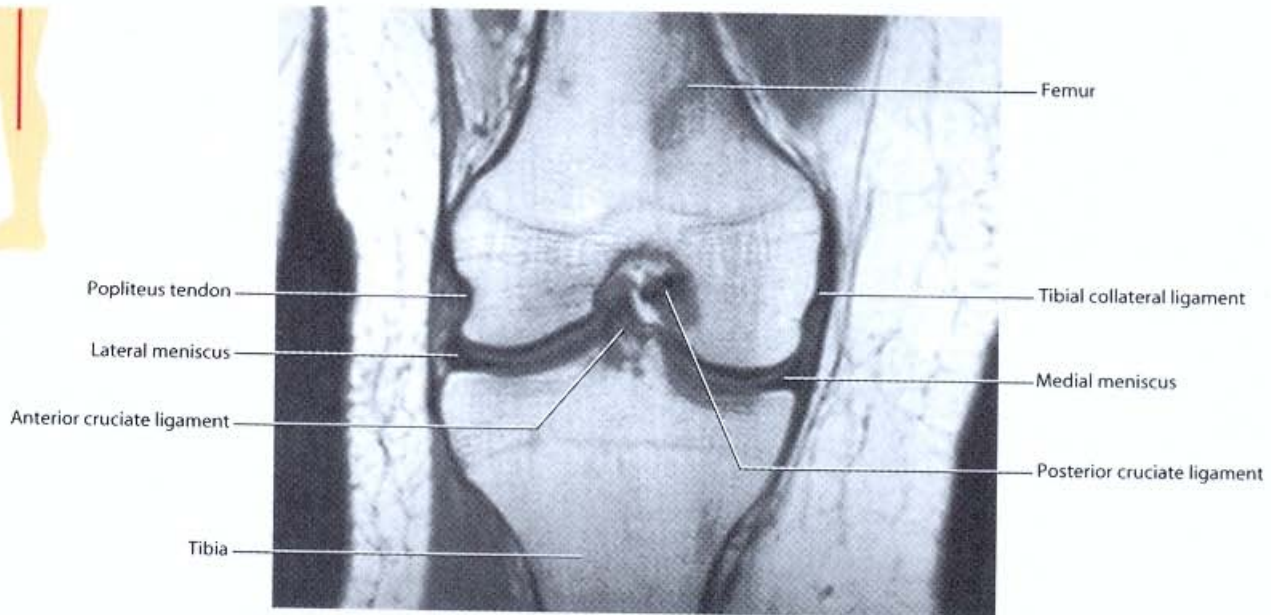

**Posterior view**

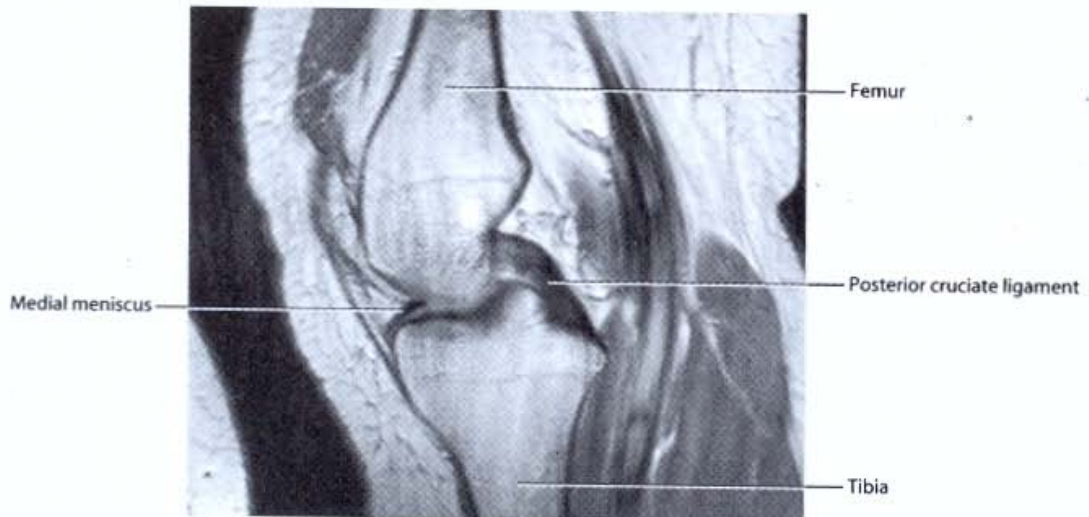
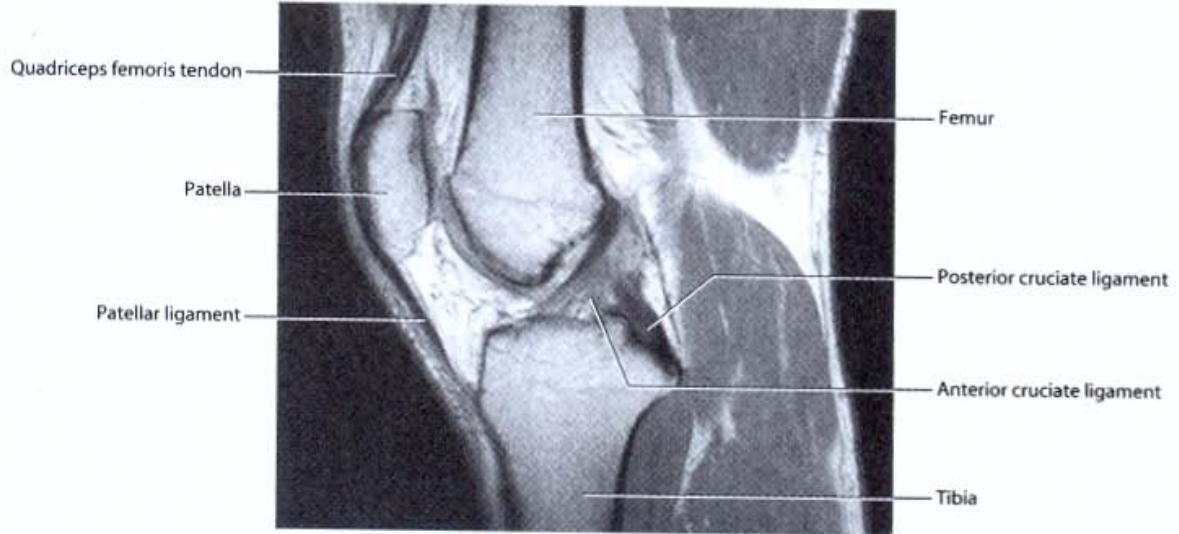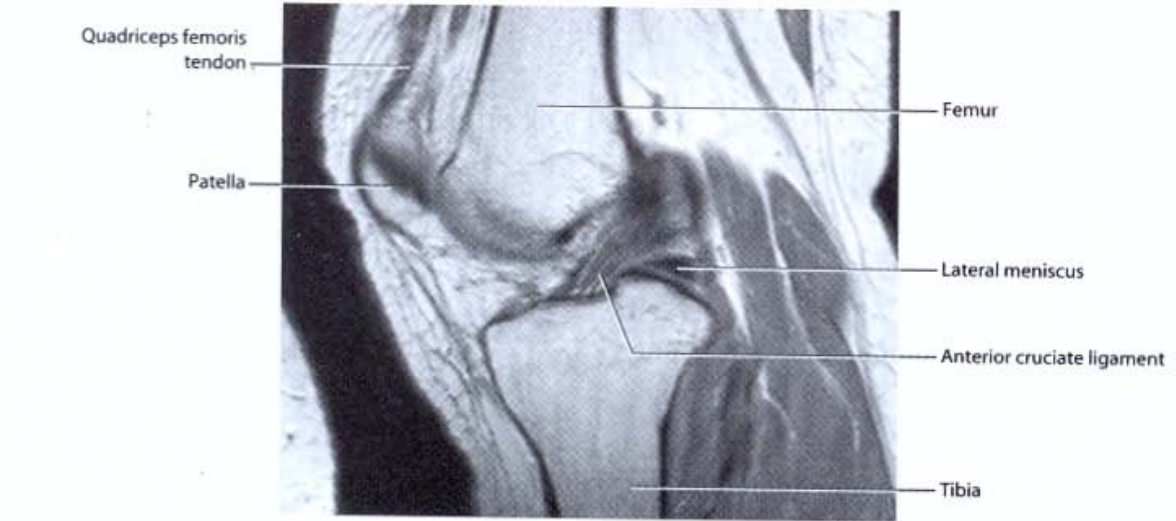


Attachments of menisci, cruciate ligaments, and synovial membrane of the right tibia. (superior view)

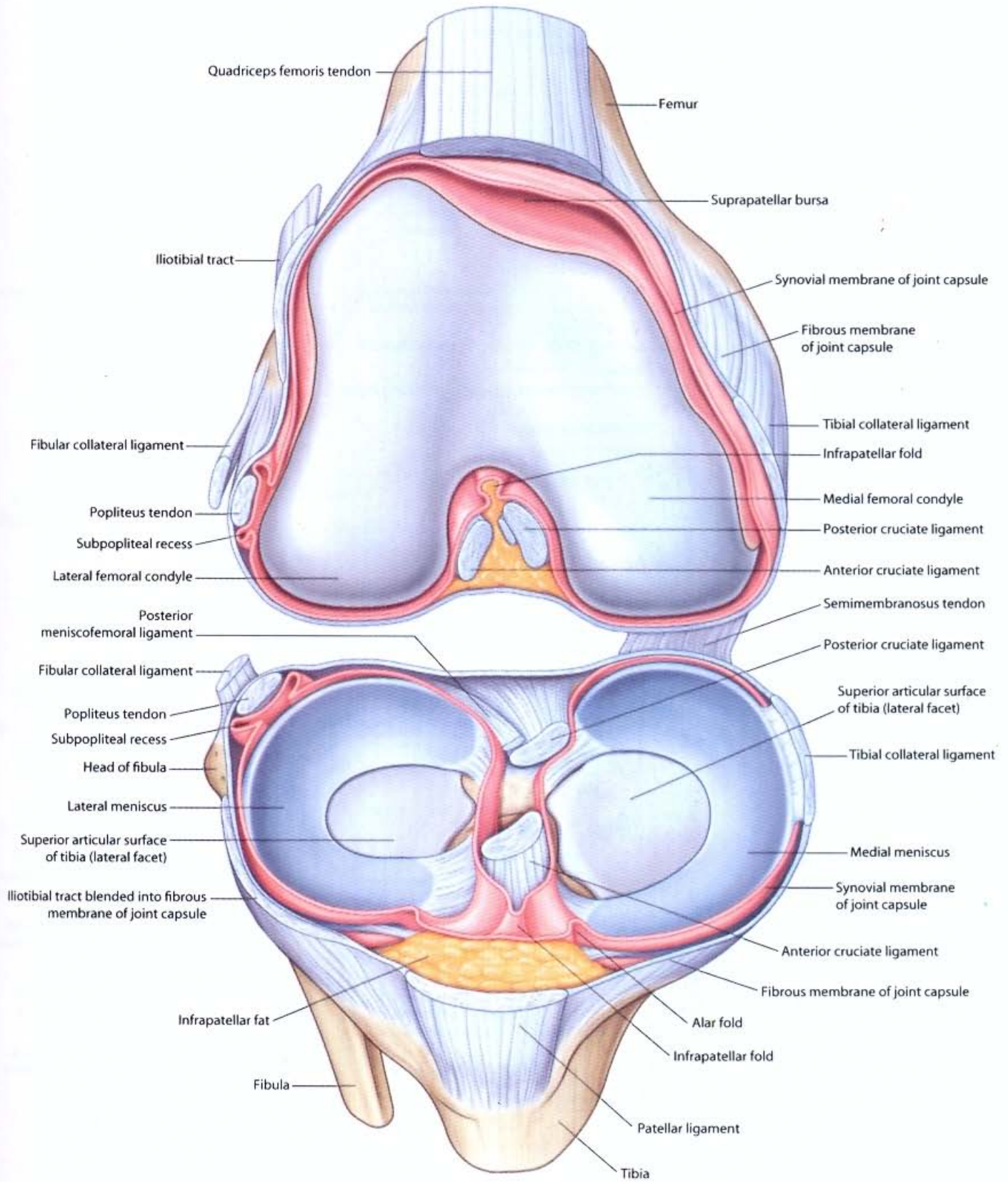
Menisci of the right knee joint. (superior view)



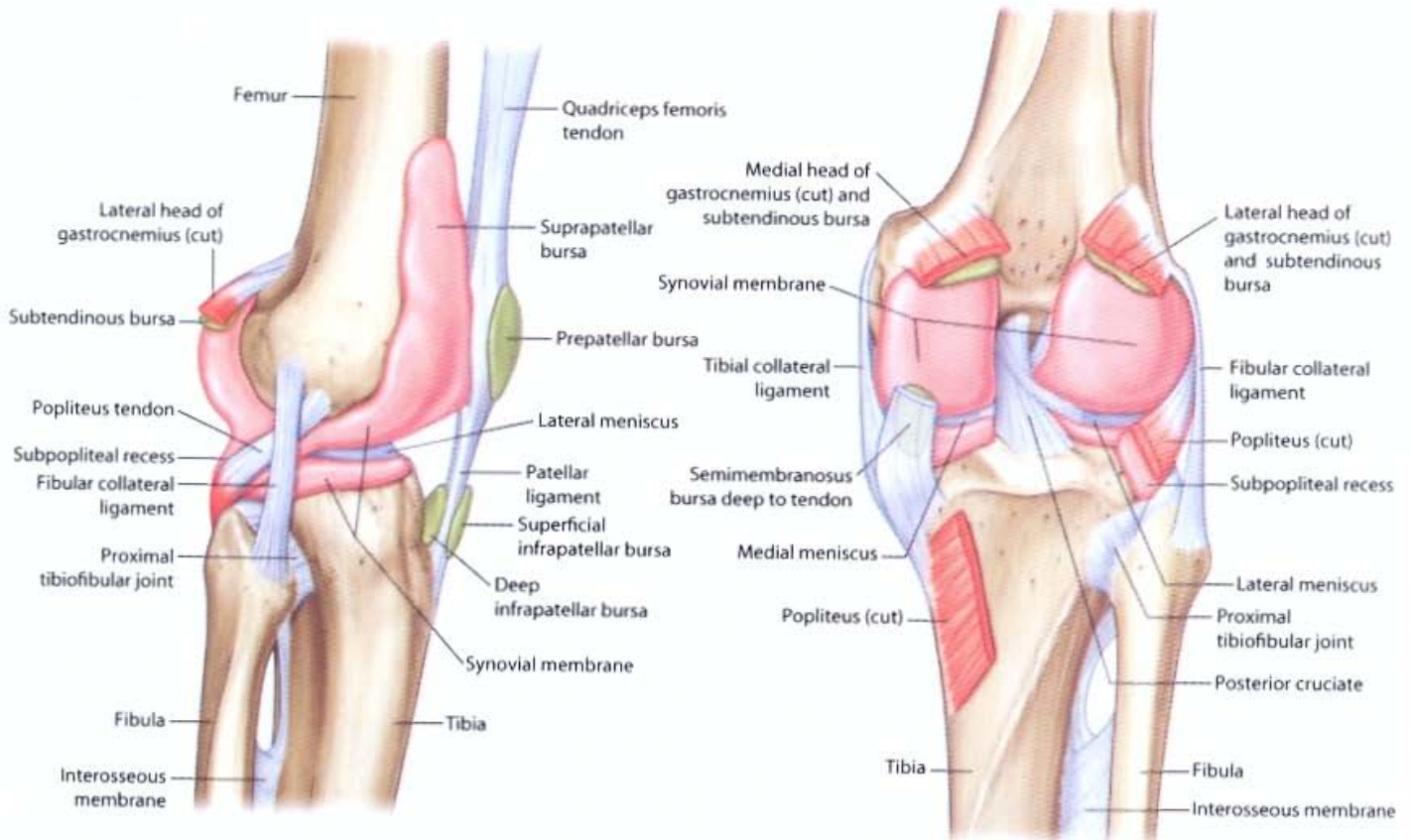
Anterior view of knee joint showing the anterior and posterior cruciate ligaments. T2-weighted MR image in coronal plane



**A series of images moving from lateral to medial showing the relationship between anterior and posterior cruciate ligaments.**  
T2-weighted MR images in sagittal plane

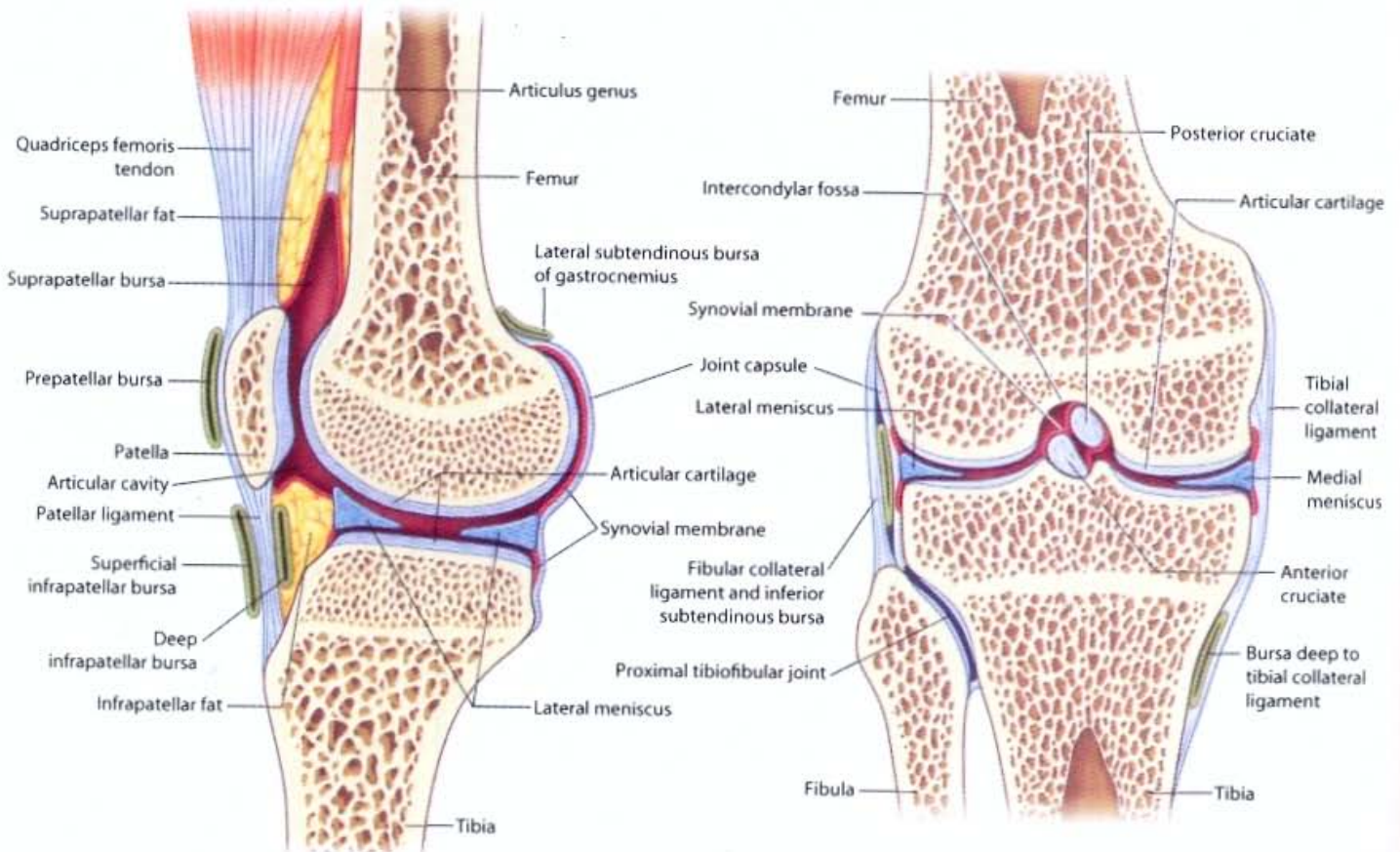


Knee joint (anterosuperior view)



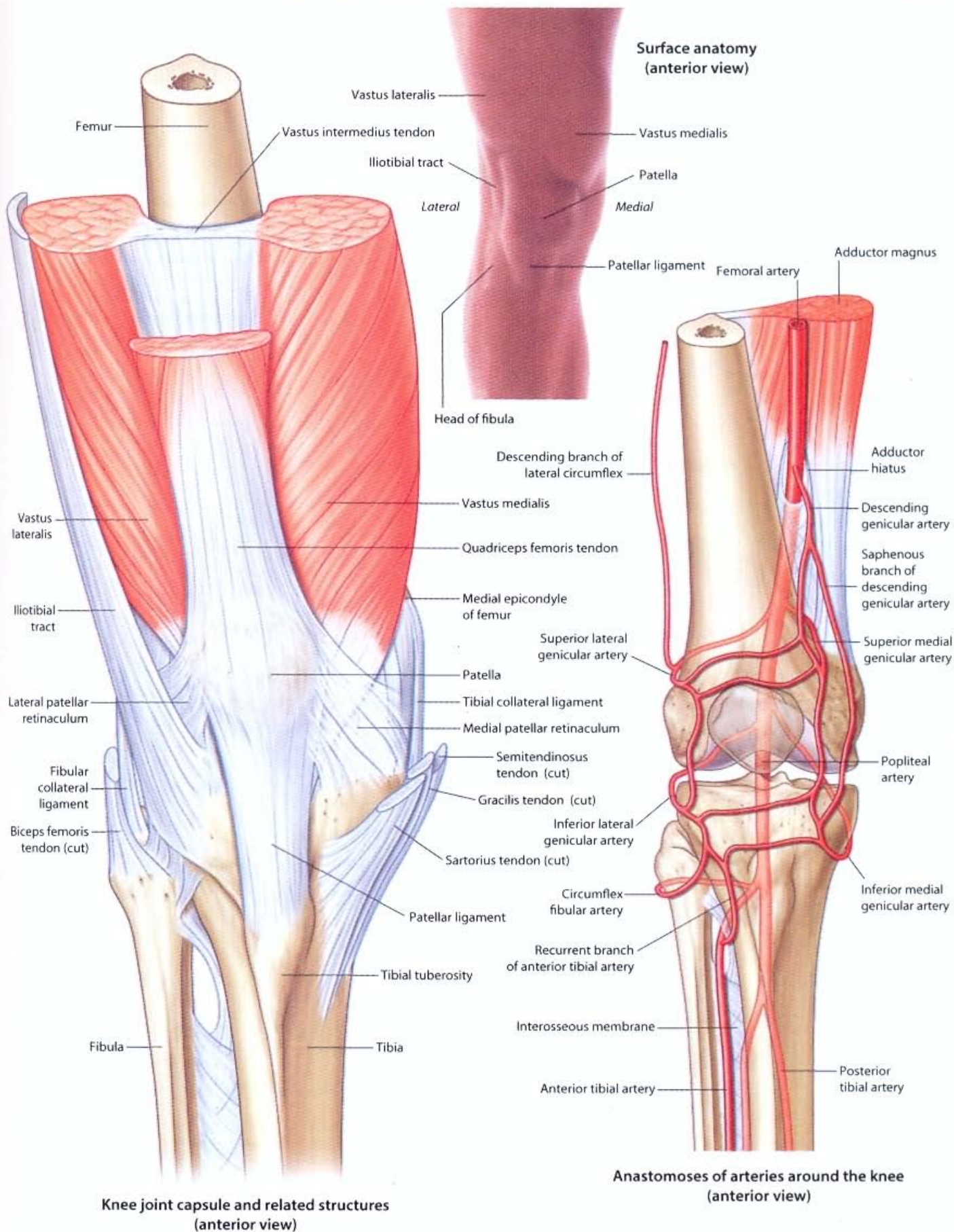
**Lateral view**

**Posterior view**

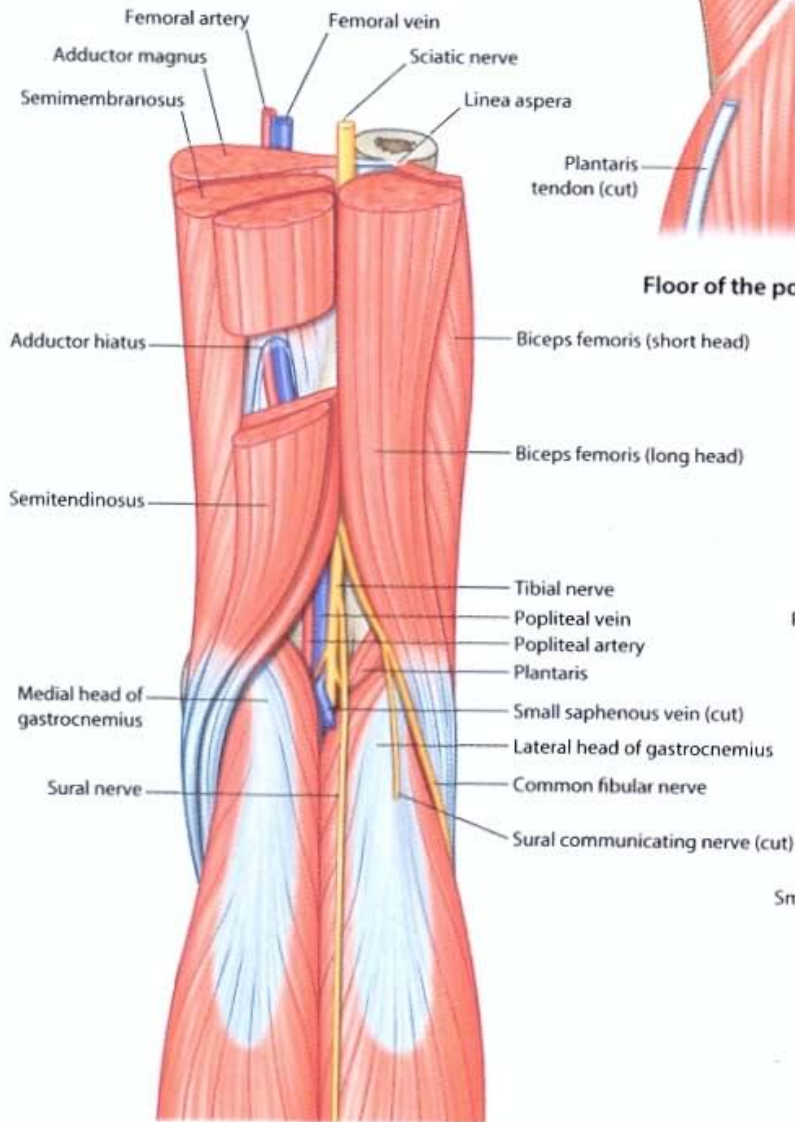
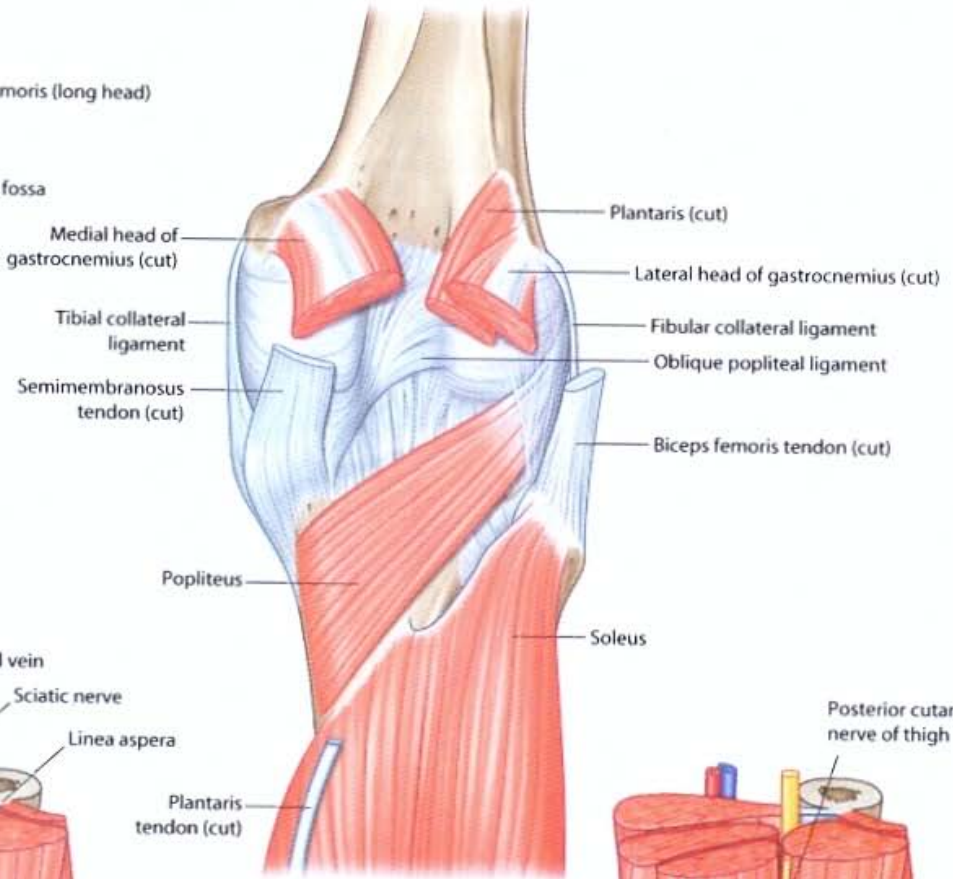
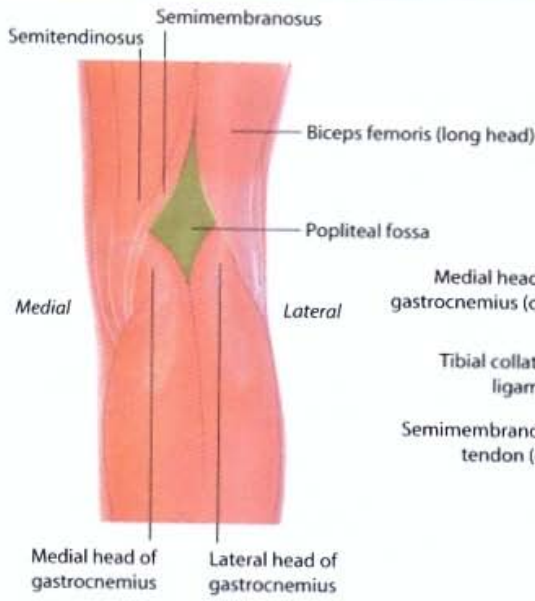


**Paramedian section through knee joint**

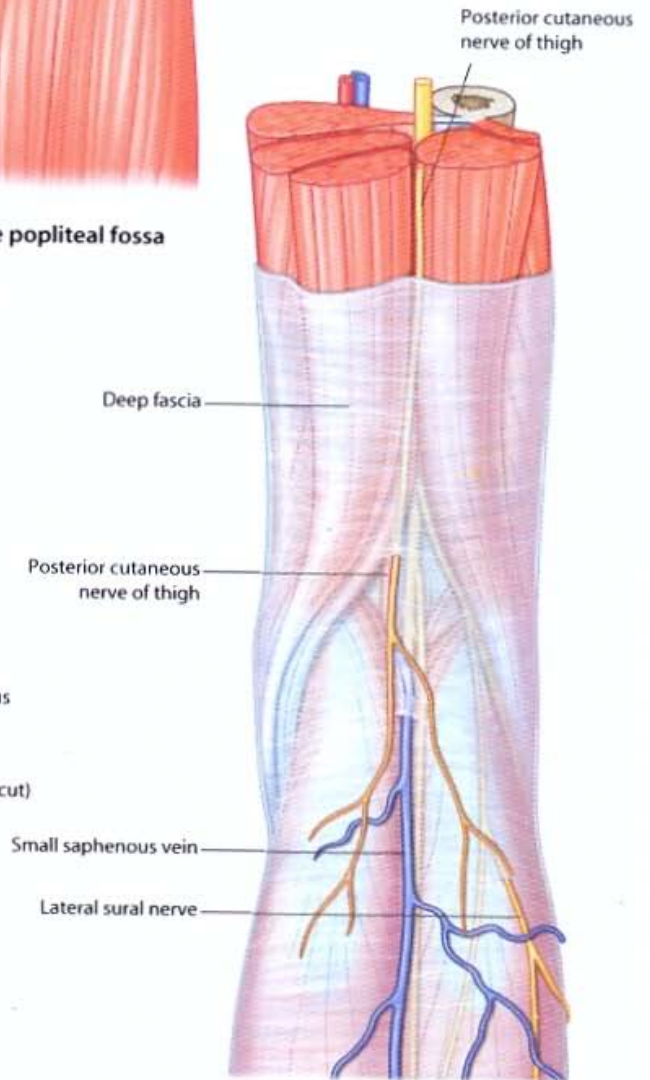
**Coronal section through knee joint (anterior view)**



# LOWER LIMB • Popliteal fossa

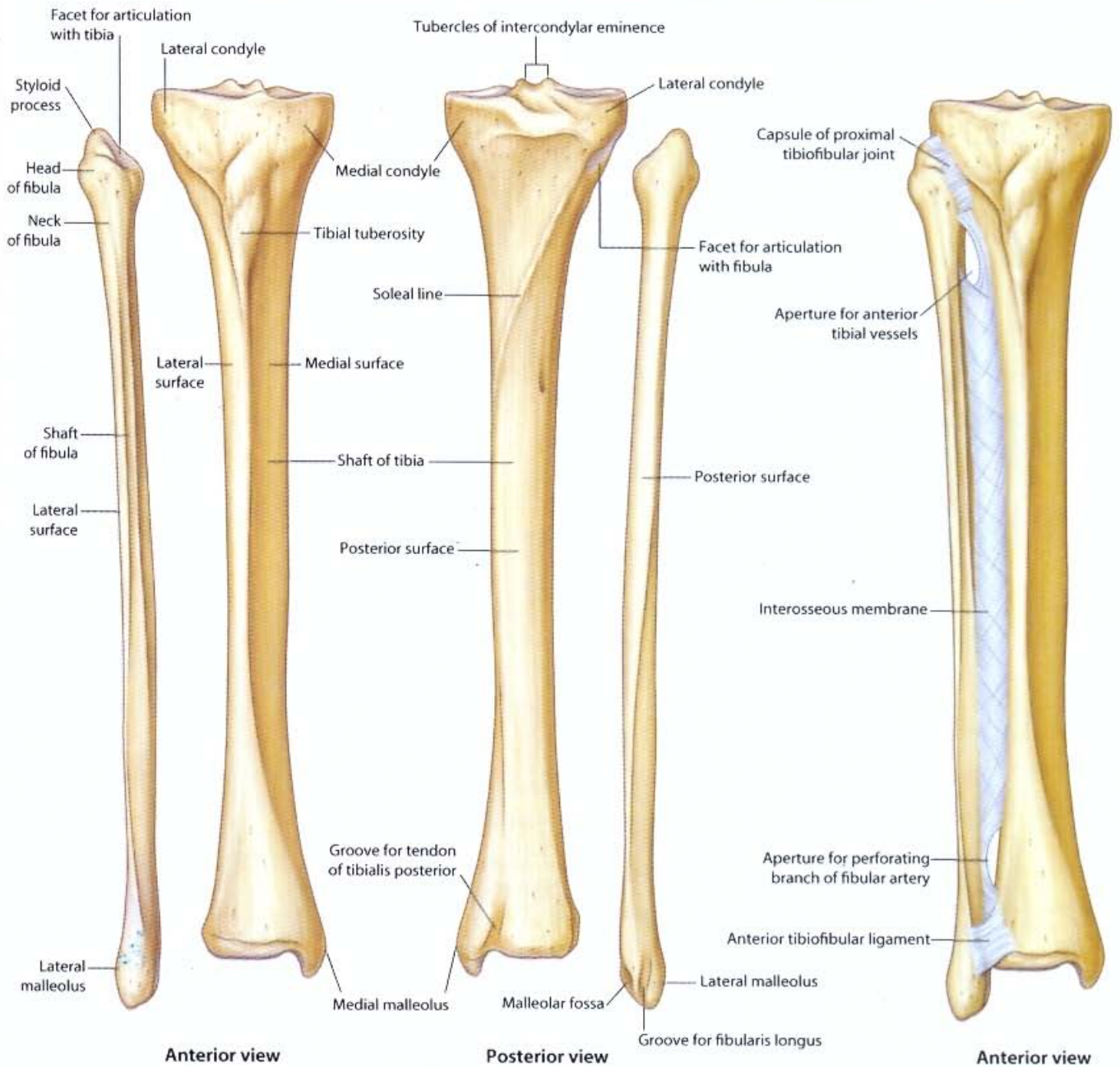


Floor of the popliteal fossa



Structures in the popliteal fossa

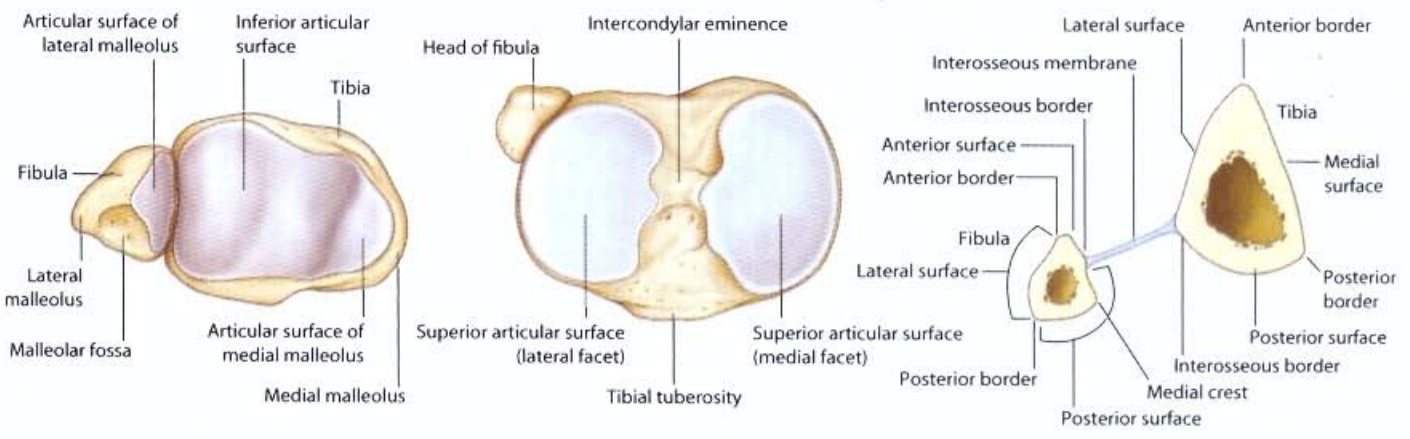
Superficial structures



Anterior view

Posterior view

Anterior view

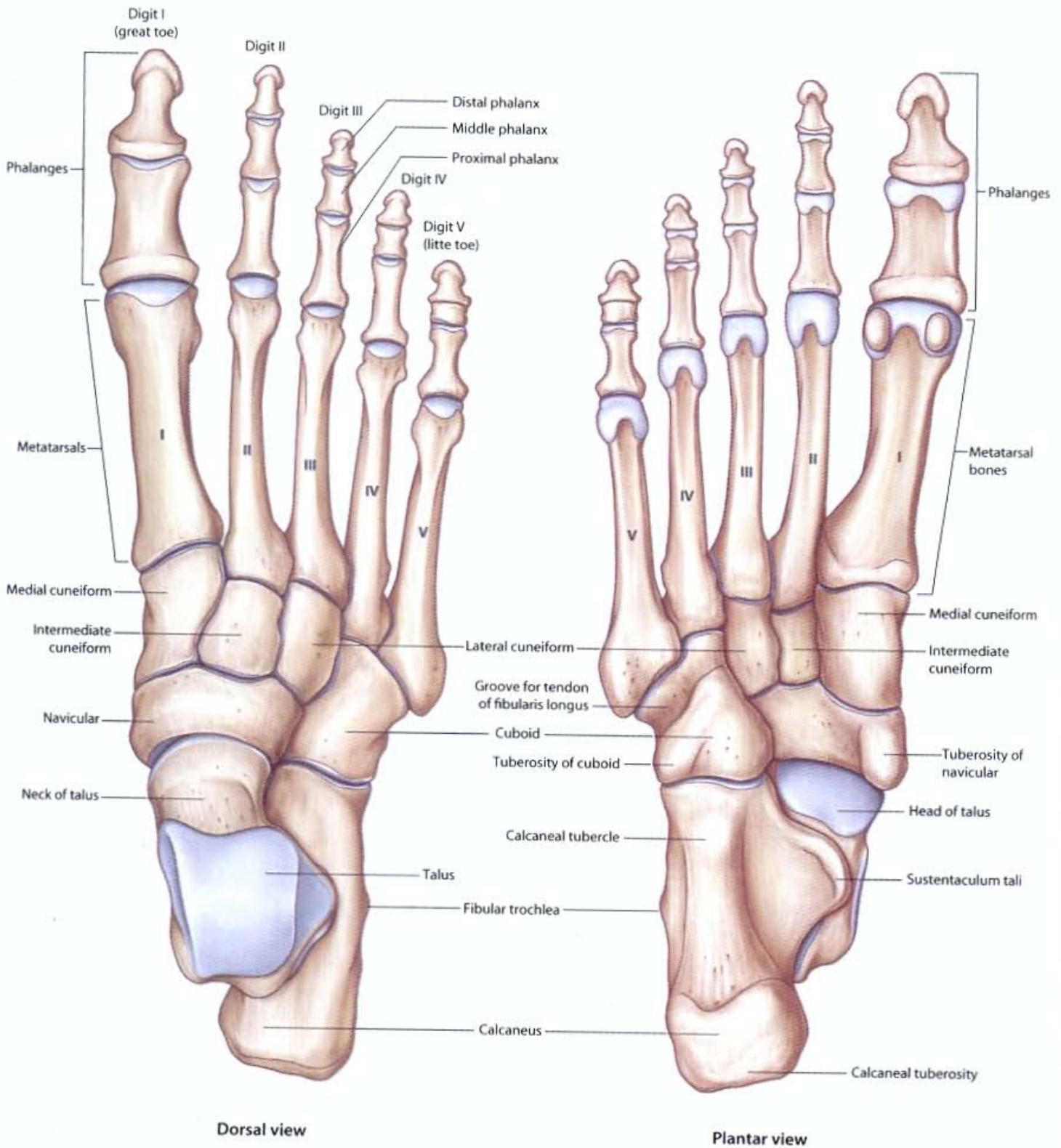


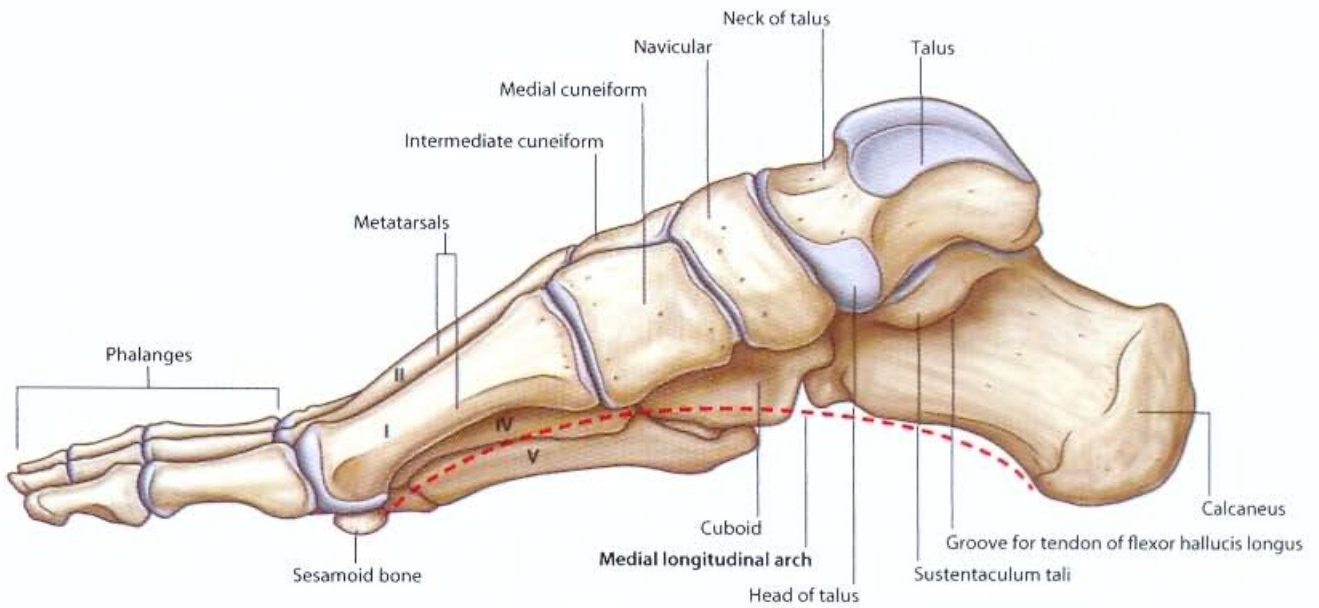
Distal tibia and fibula (inferior view)

Proximal tibia and fibula (superior view)

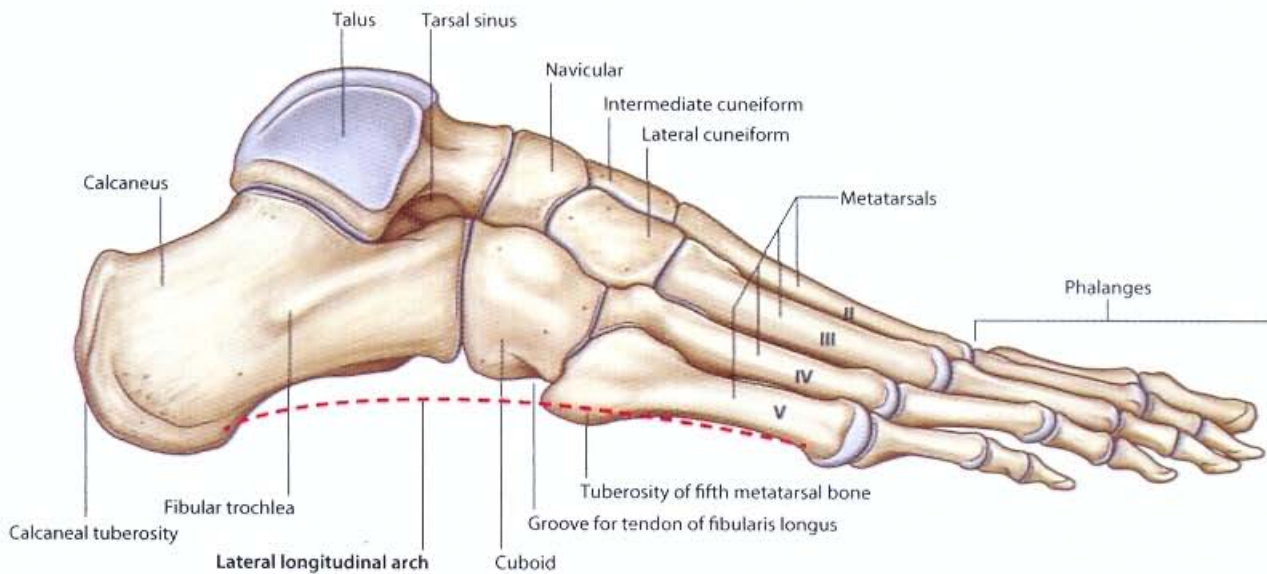
Cross section through shafts



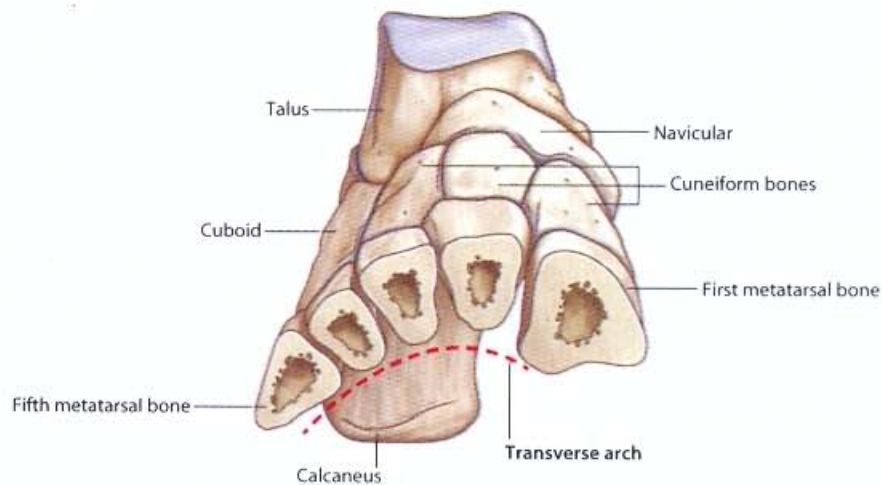




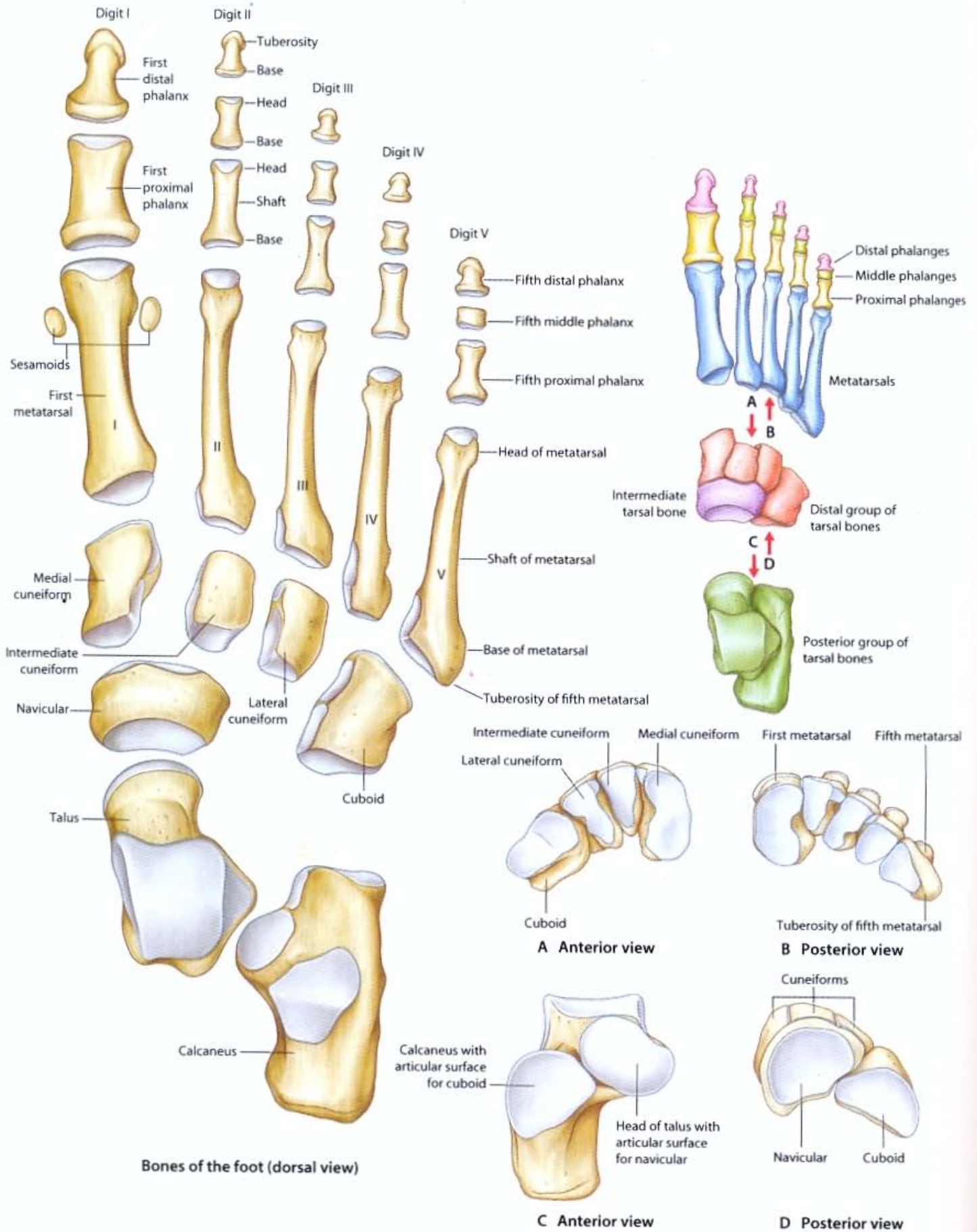
Medial view



Lateral view



Cross section through the foot bones



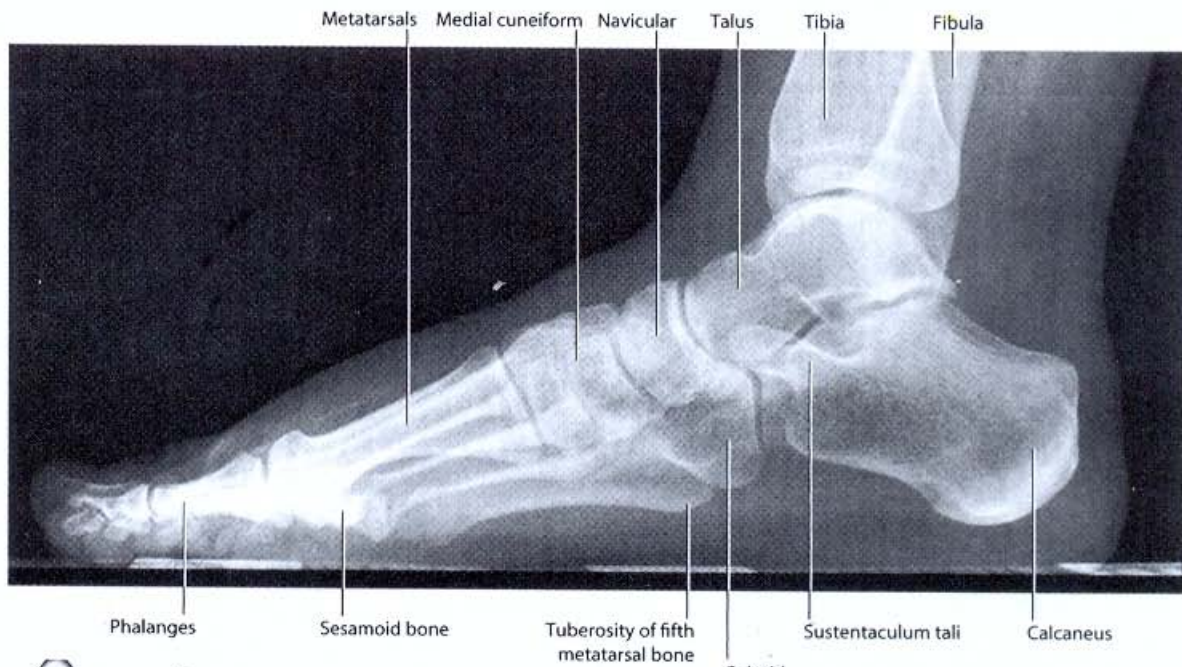
**Bones of the foot (dorsal view)**

**A Anterior view**

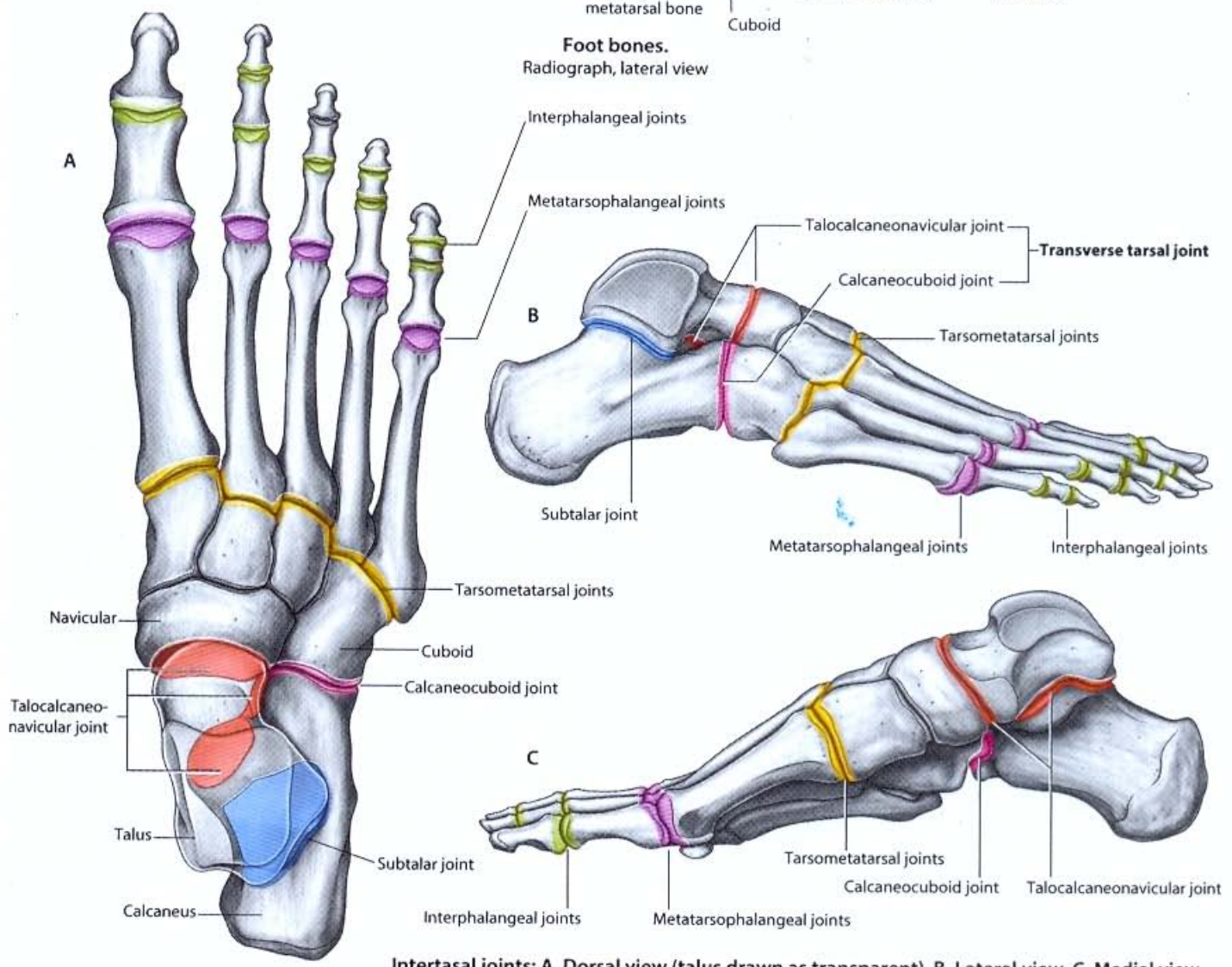
**B Posterior view**

**C Anterior view**

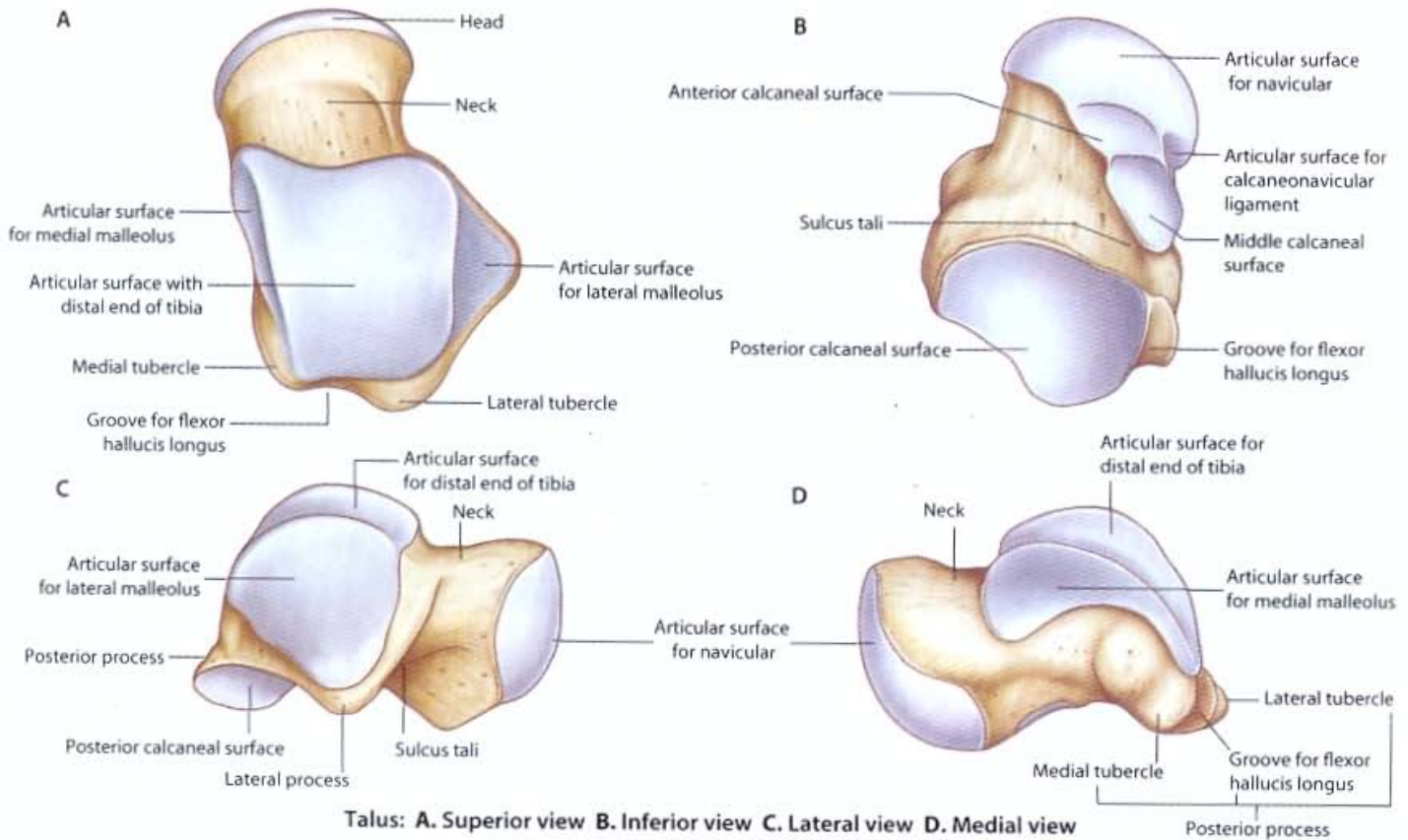
**D Posterior view**



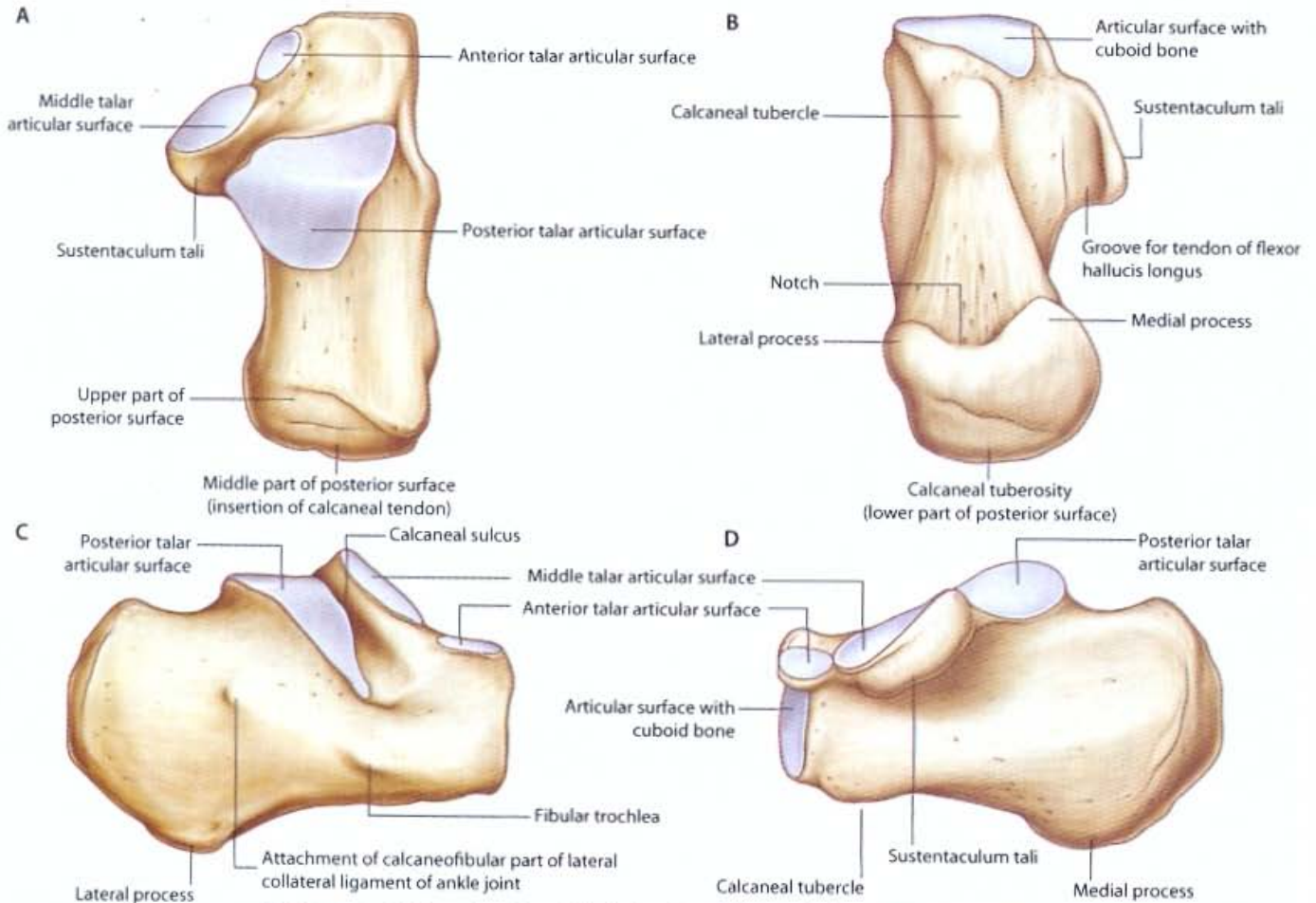
**Foot bones.**  
Radiograph, lateral view



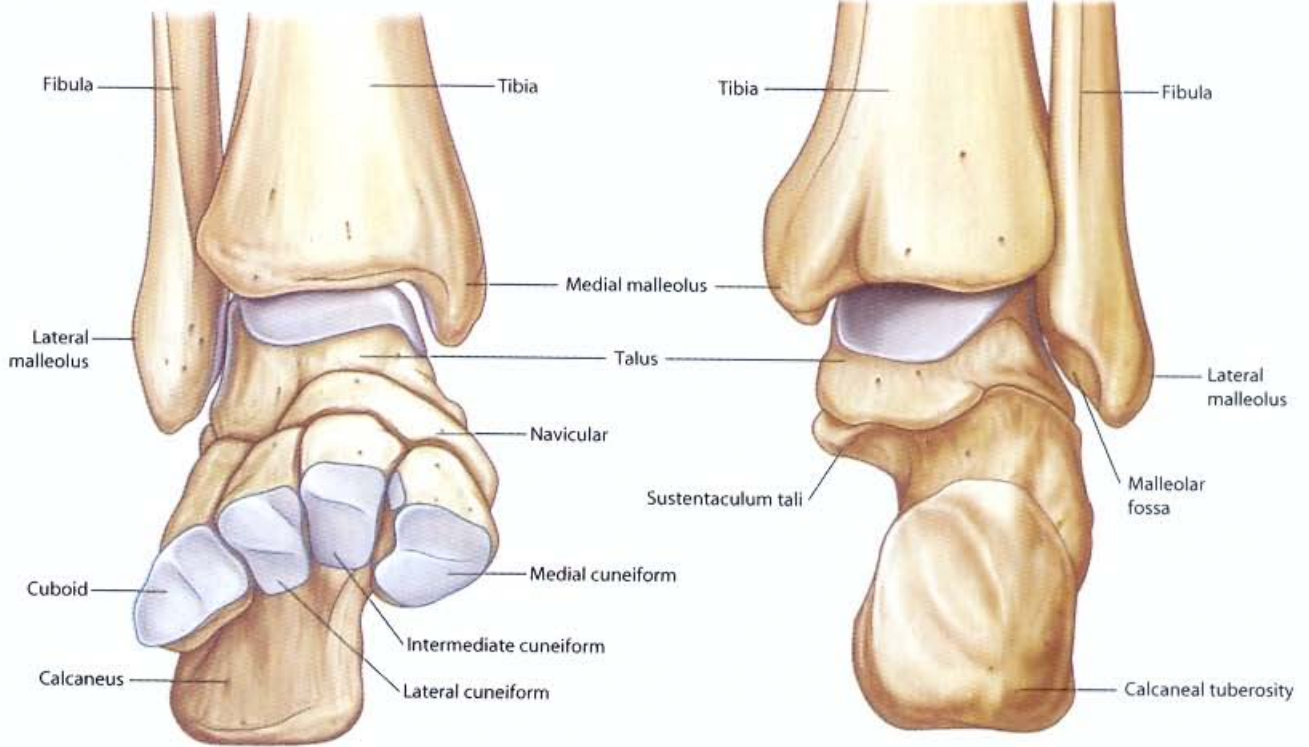
**Intertarsal joints: A. Dorsal view (talus drawn as transparent) B. Lateral view C. Medial view**



**Talus: A. Superior view B. Inferior view C. Lateral view D. Medial view**

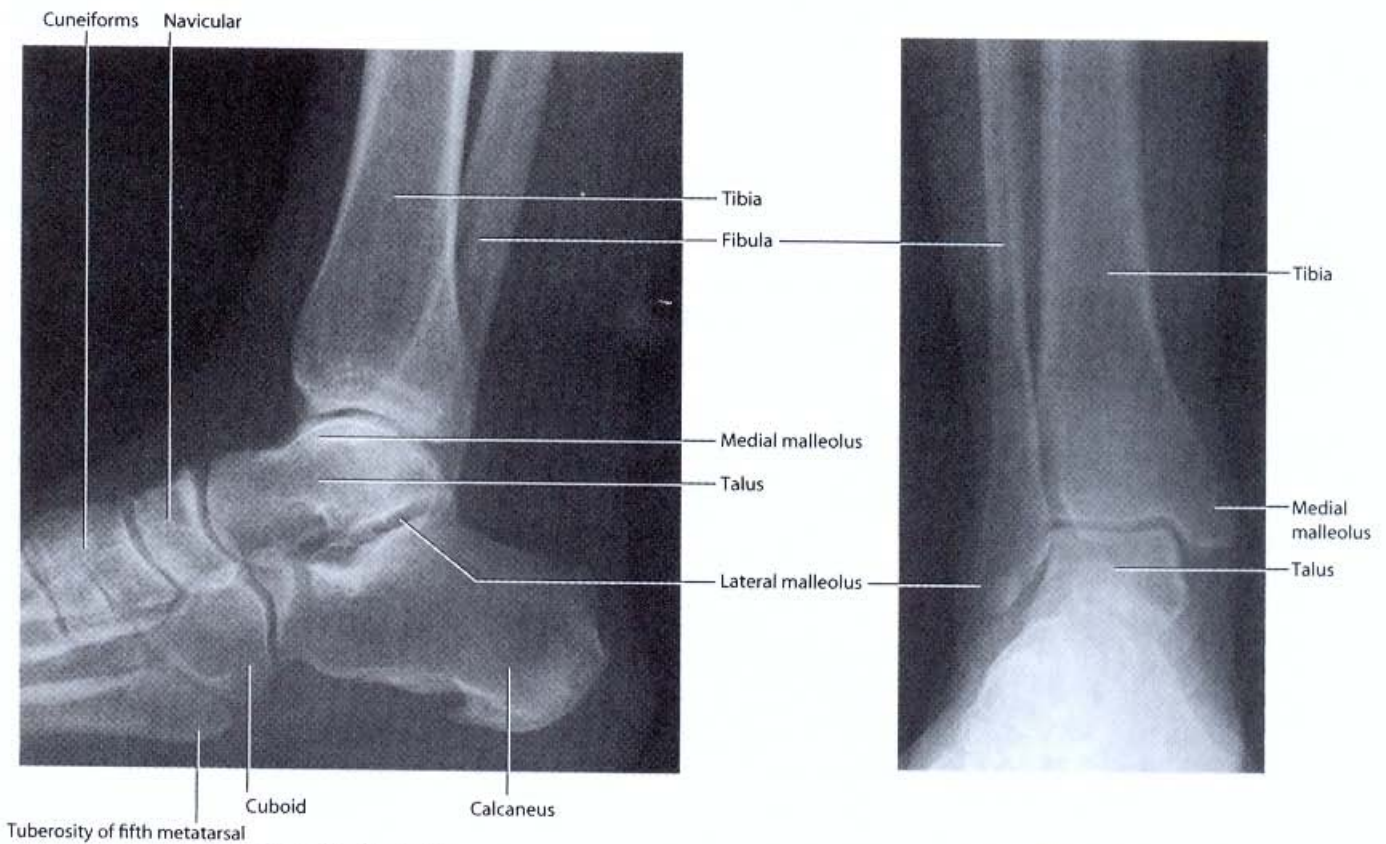


**Calcaneus: A. Superior view B. Inferior view C. Lateral view D. Medial view**



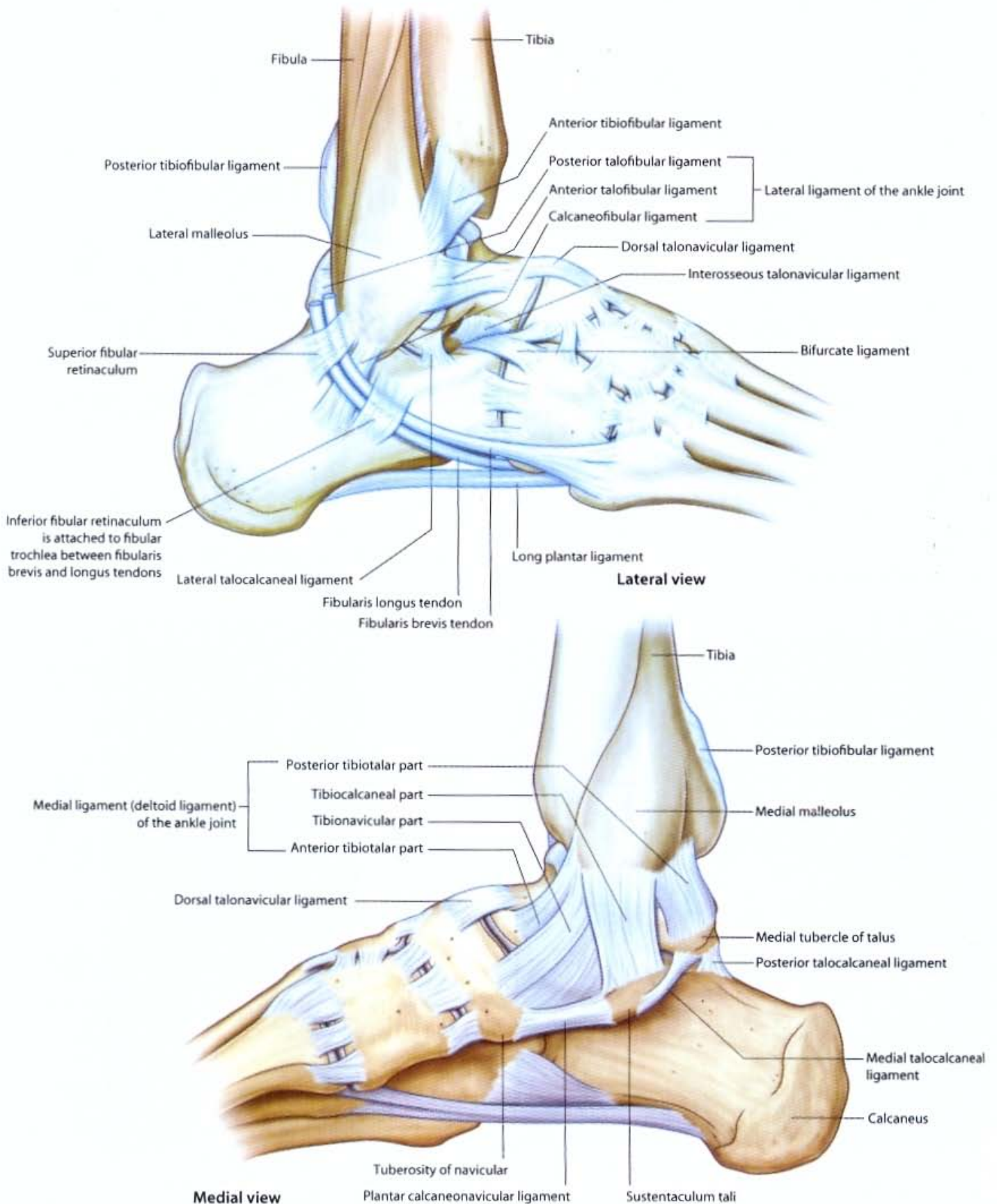
**Anterior view**  
(metatarsals and phalanges removed)

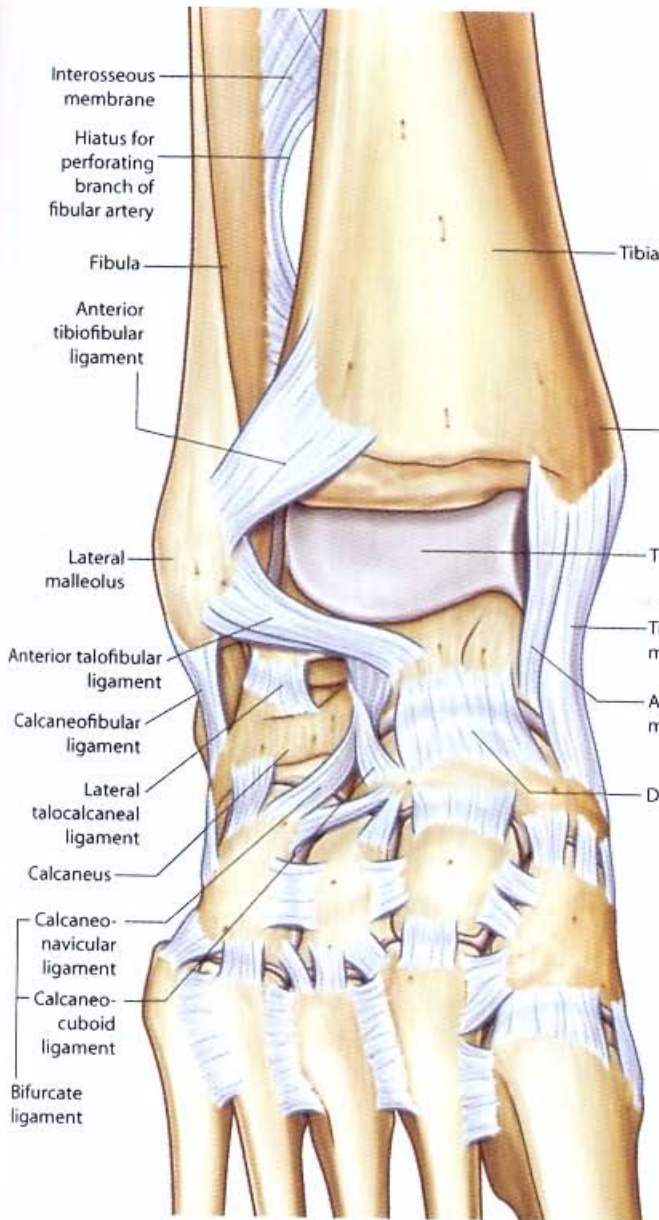
**Posterior view**



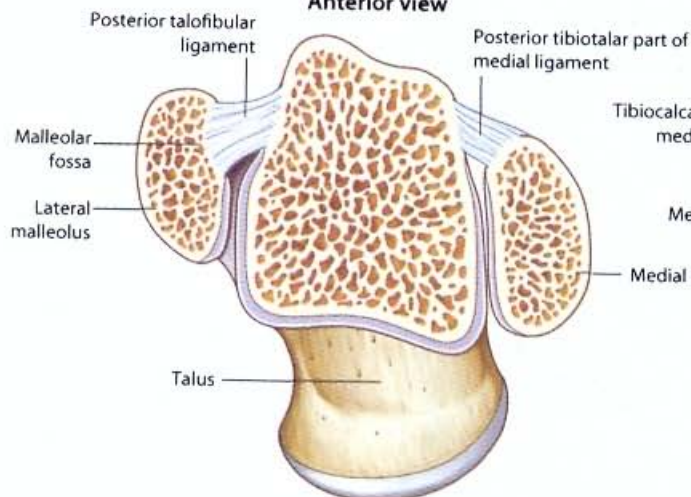
**Normal ankle joint.**  
Radiograph, lateral view

**Normal ankle joint.**  
Radiograph, AP view

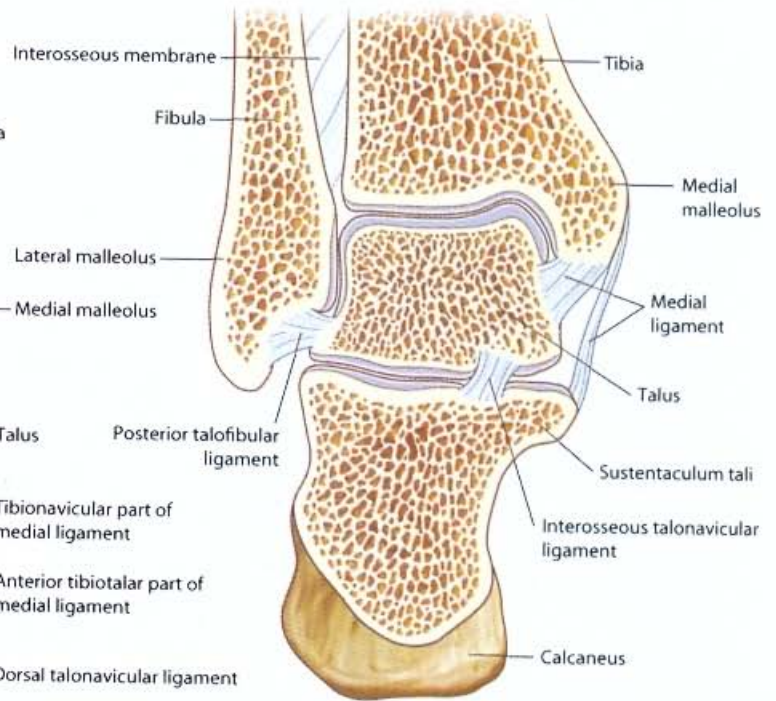




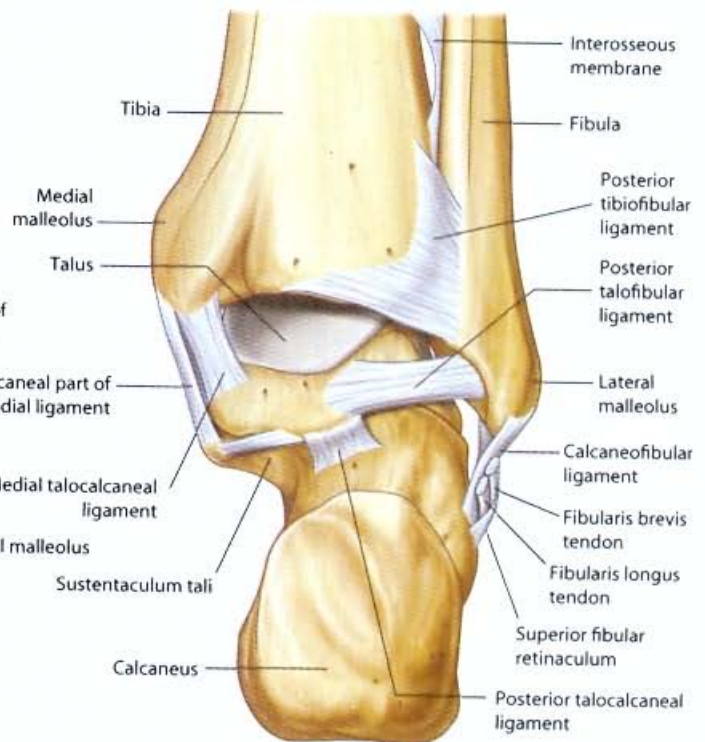Anterior view



Transverse section through ankle joint (superior view)

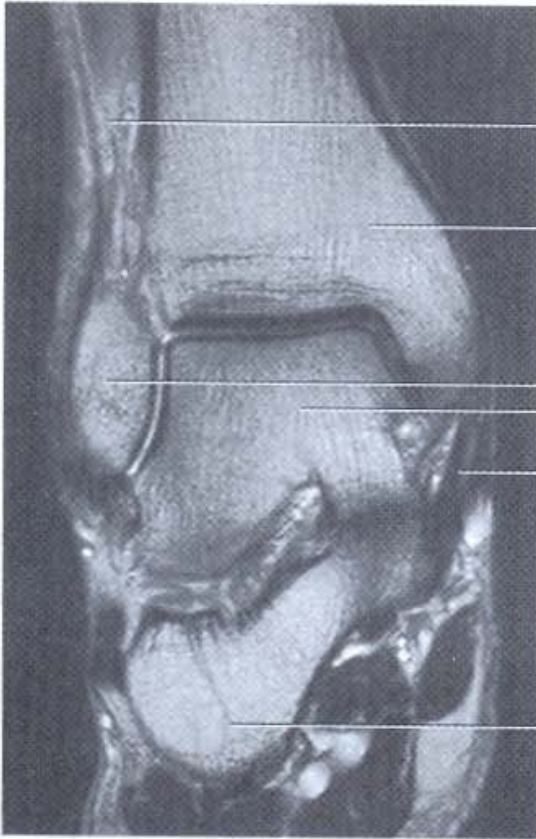


Coronal section through ankle joint (anterior view)



Posterior view





Fibula

Tibia

Lateral malleolus

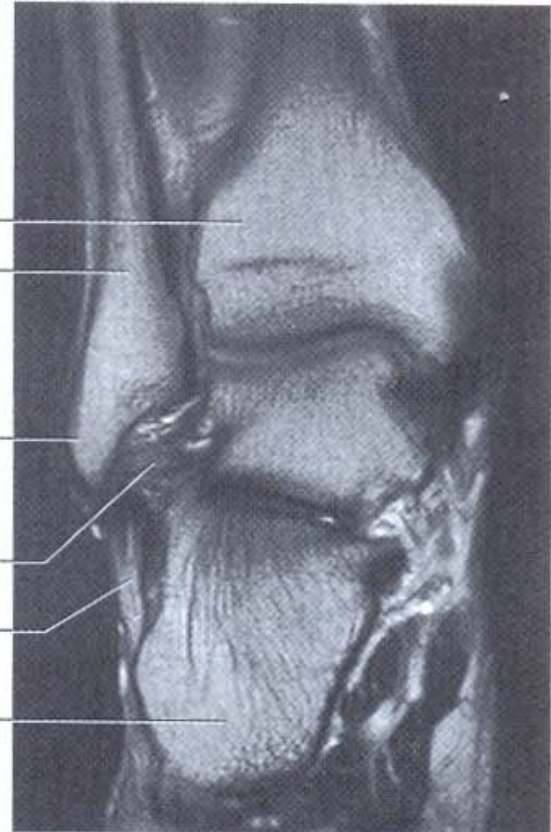
Talus

Medial ligament of ankle joint (deltoid ligament)

Posterior talofibular ligament

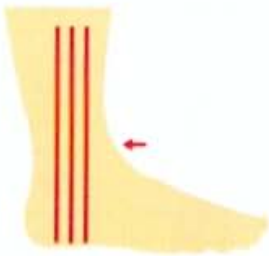Calcaneofibular ligament

Calcaneus

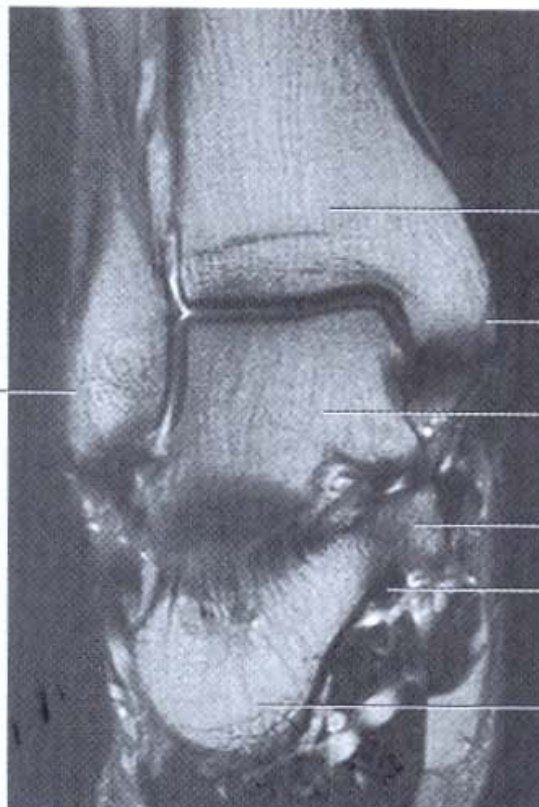


Coronal view of the ankle joint showing the medial ligament of the ankle joint (deltoid ligament).  
T2-weighted MR image in coronal plane

Coronal view of the ankle joint showing the posterior talofibular and calcaneofibular ligaments.  
T2-weighted MR image in coronal plane



Lateral malleolus



Tibia

Medial malleolus

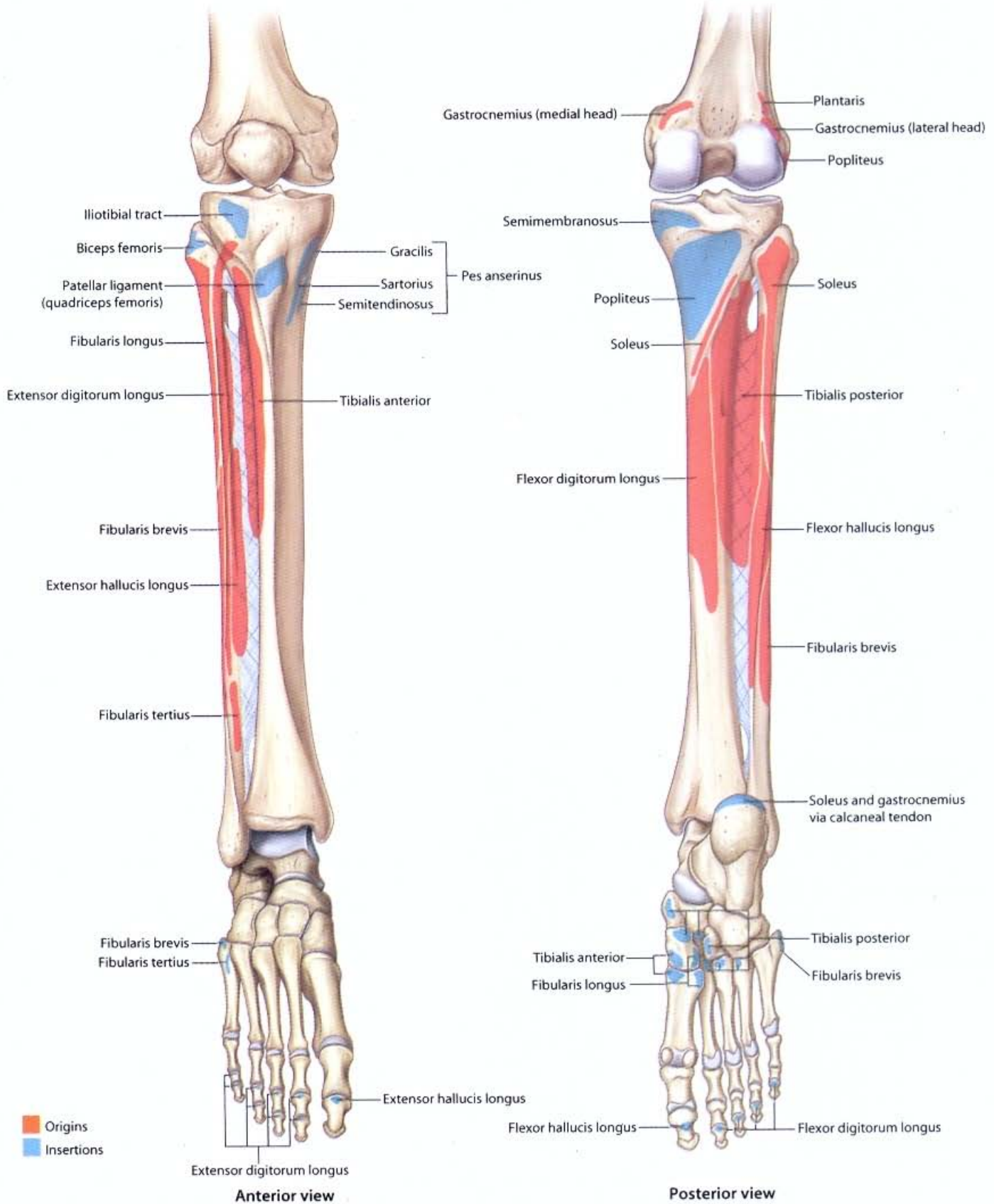
Talus

Sustentaculum tali

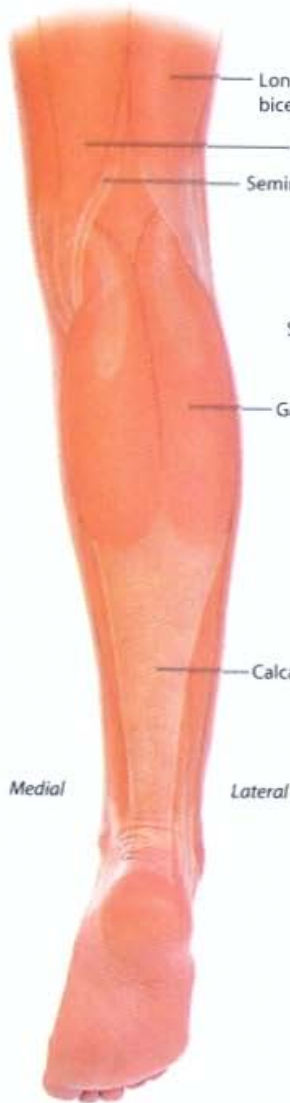Flexor hallucis longus tendon

Calcaneus

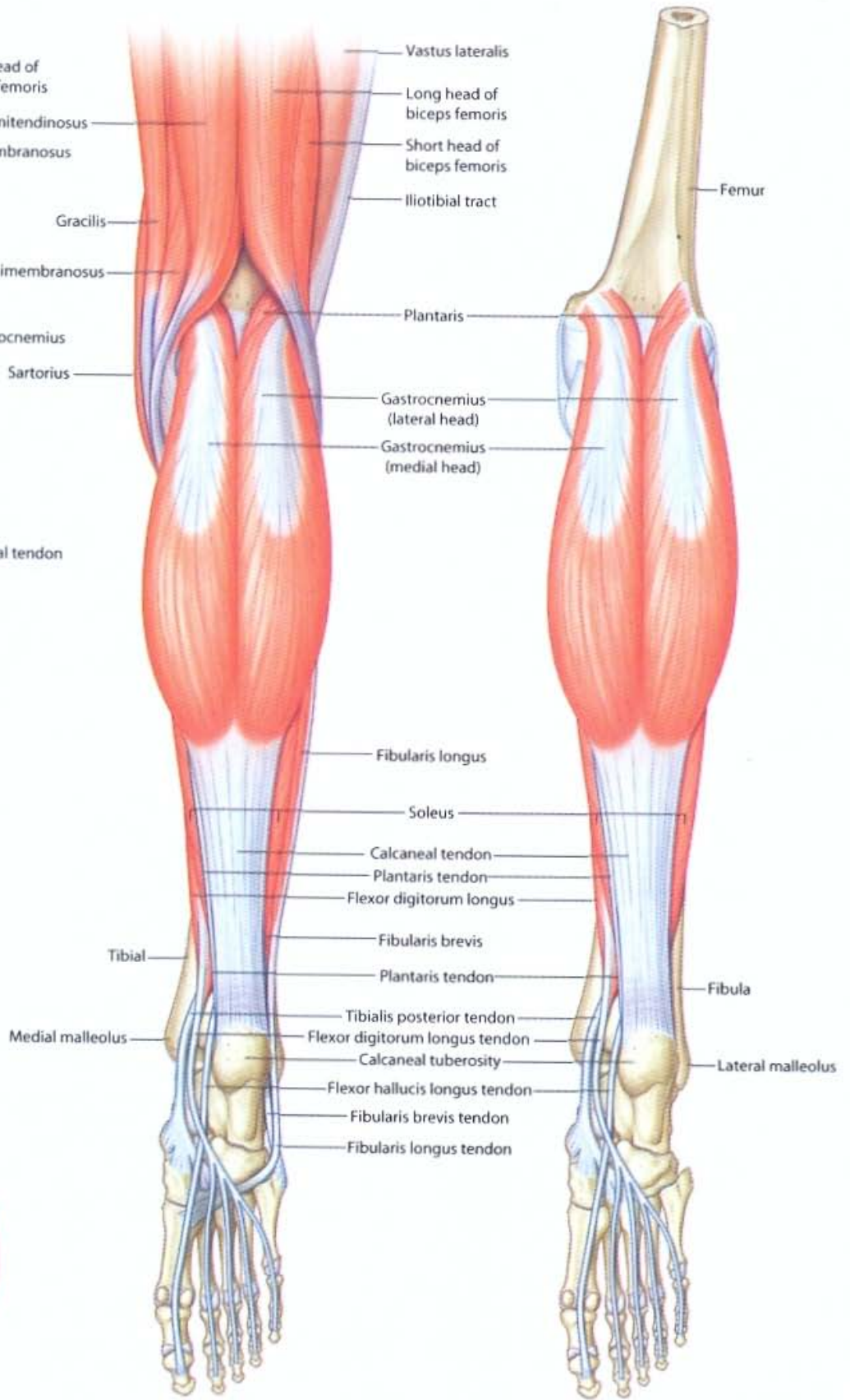
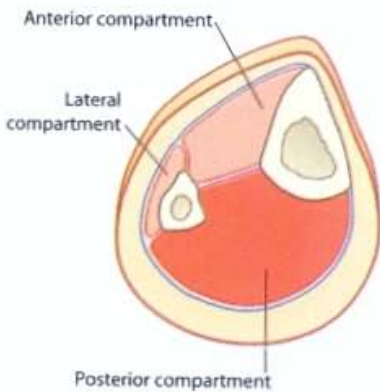
Coronal view of the ankle joint showing the flexor hallucis longus passing inferior to the sustentaculum tali.  
T2-weighted MR image in coronal plane



# LOWER LIMB • Posterior leg: superficial muscles

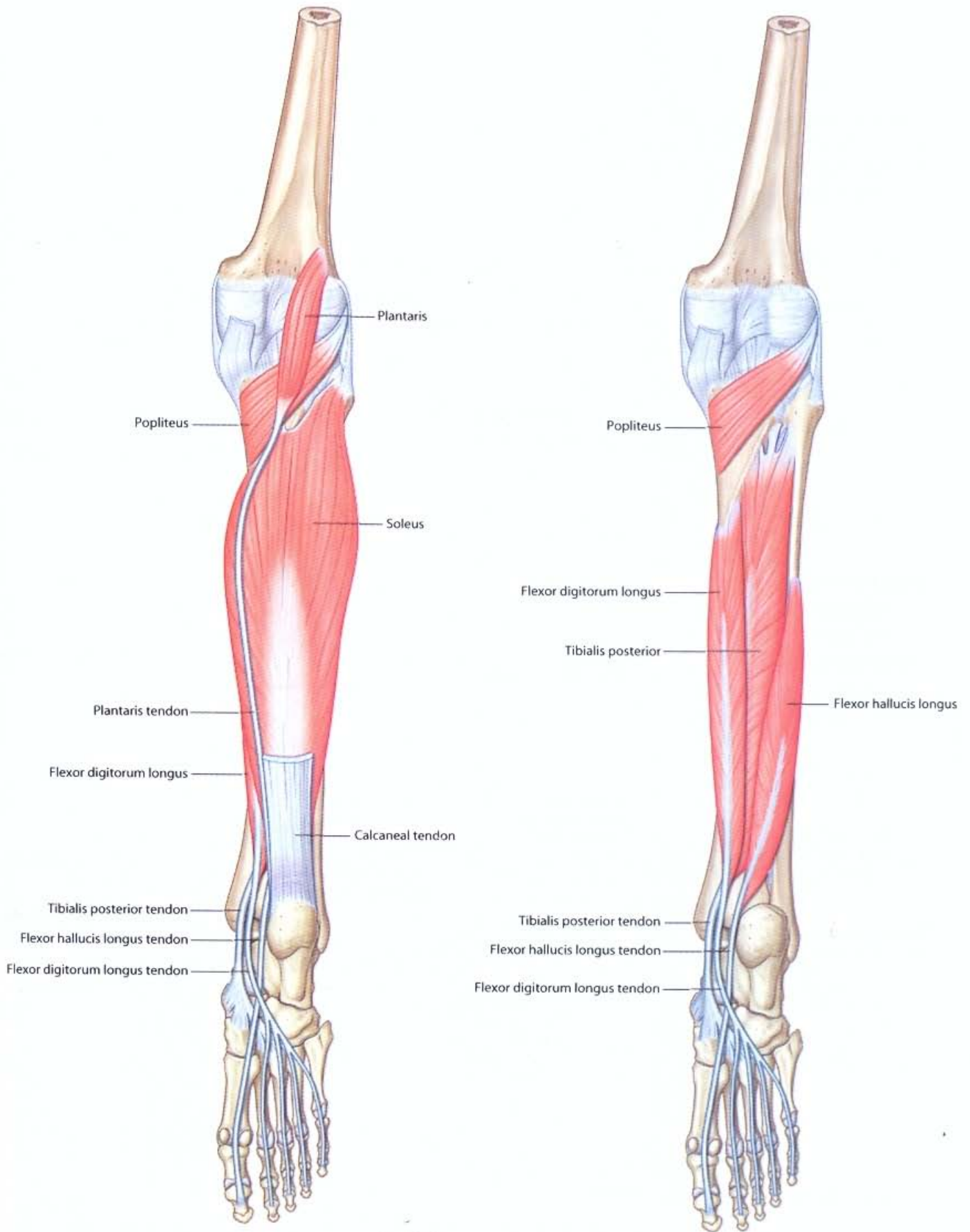


Surface anatomy of leg with overlay of muscles (posterior view)

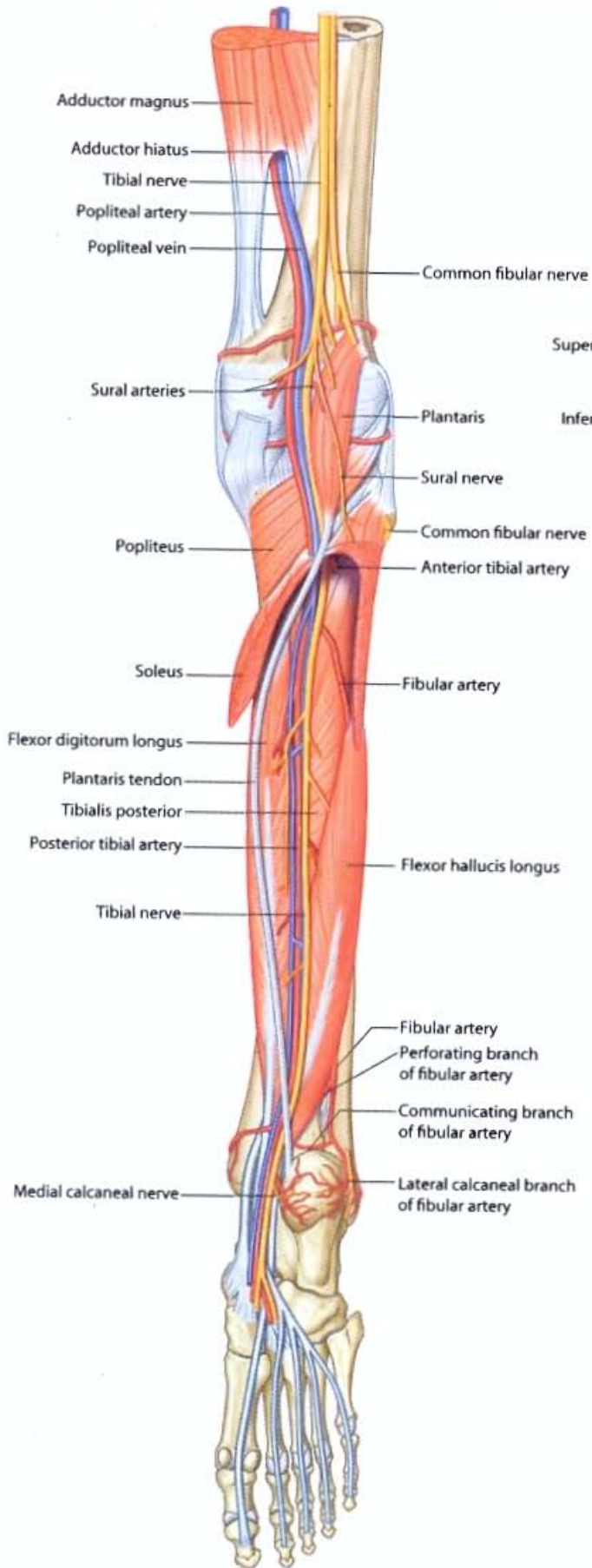


Superficial muscles of leg (posterior view)

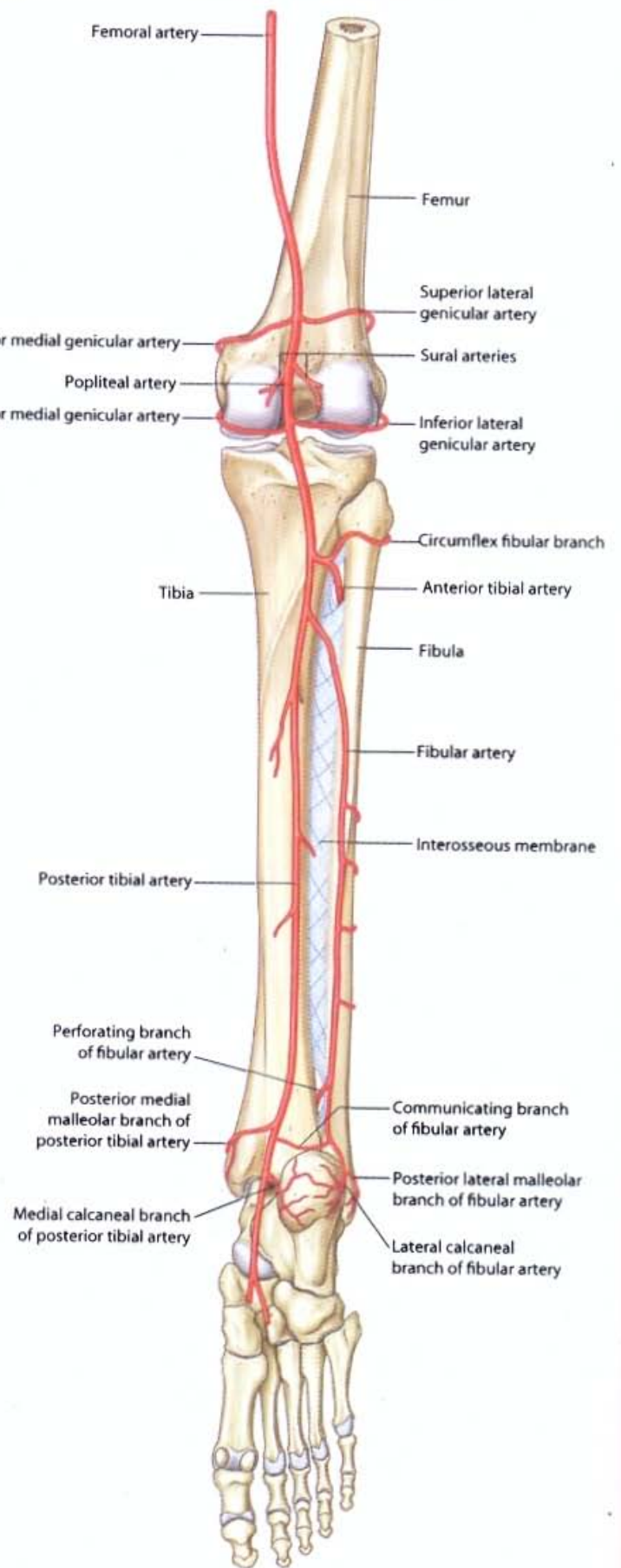
Superficial muscles of the posterior compartment of leg



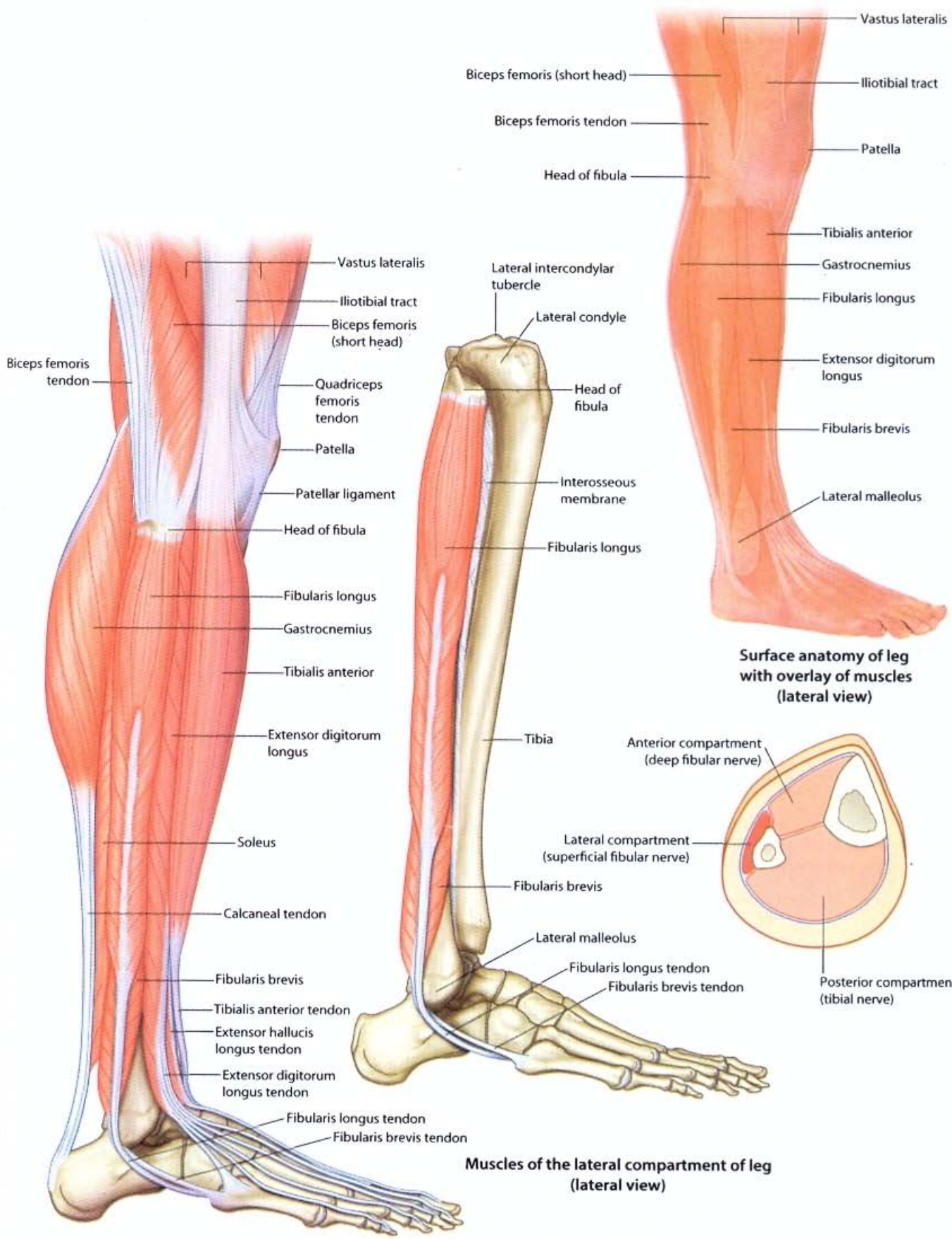
Deep muscles of the posterior compartment of leg



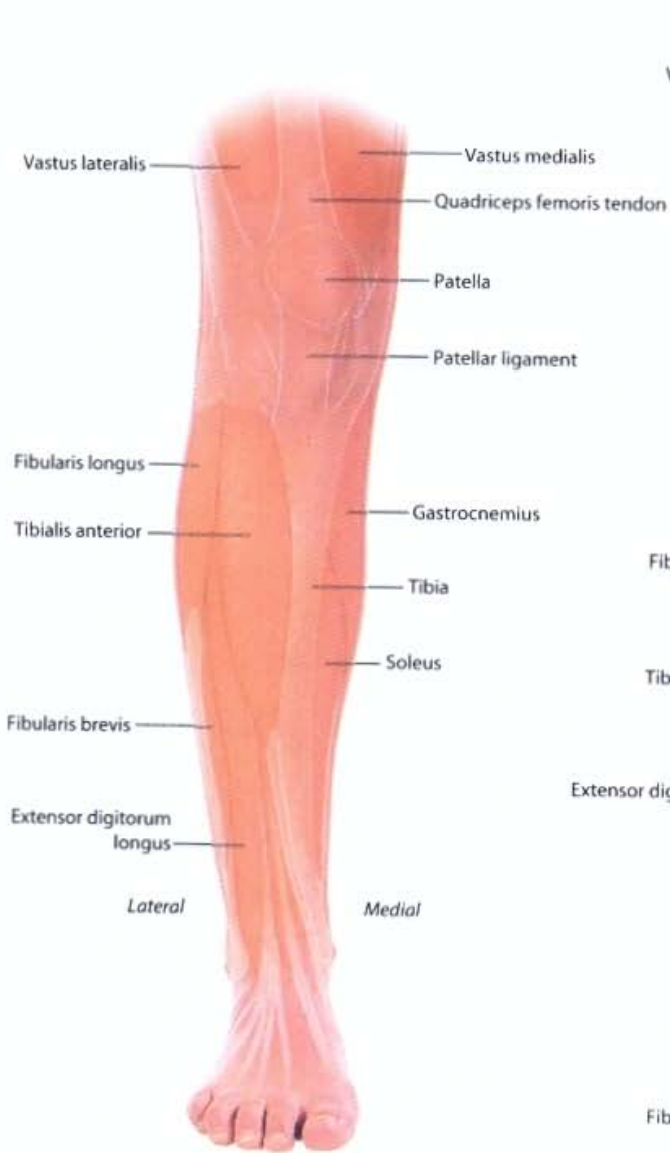
Arteries and nerves of leg (posterior view)



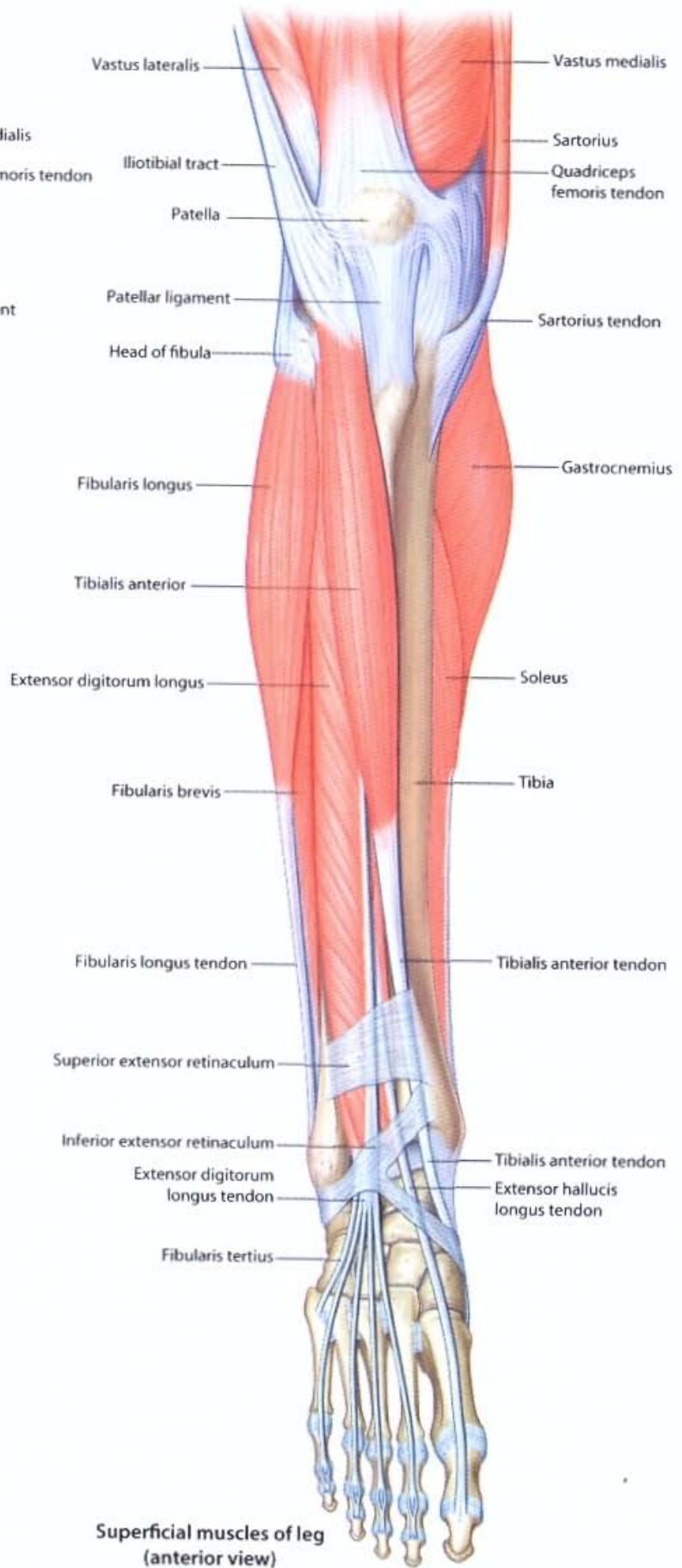
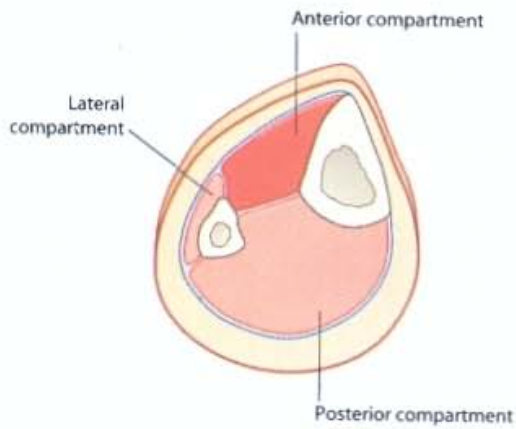
Arteries of leg (posterior view)



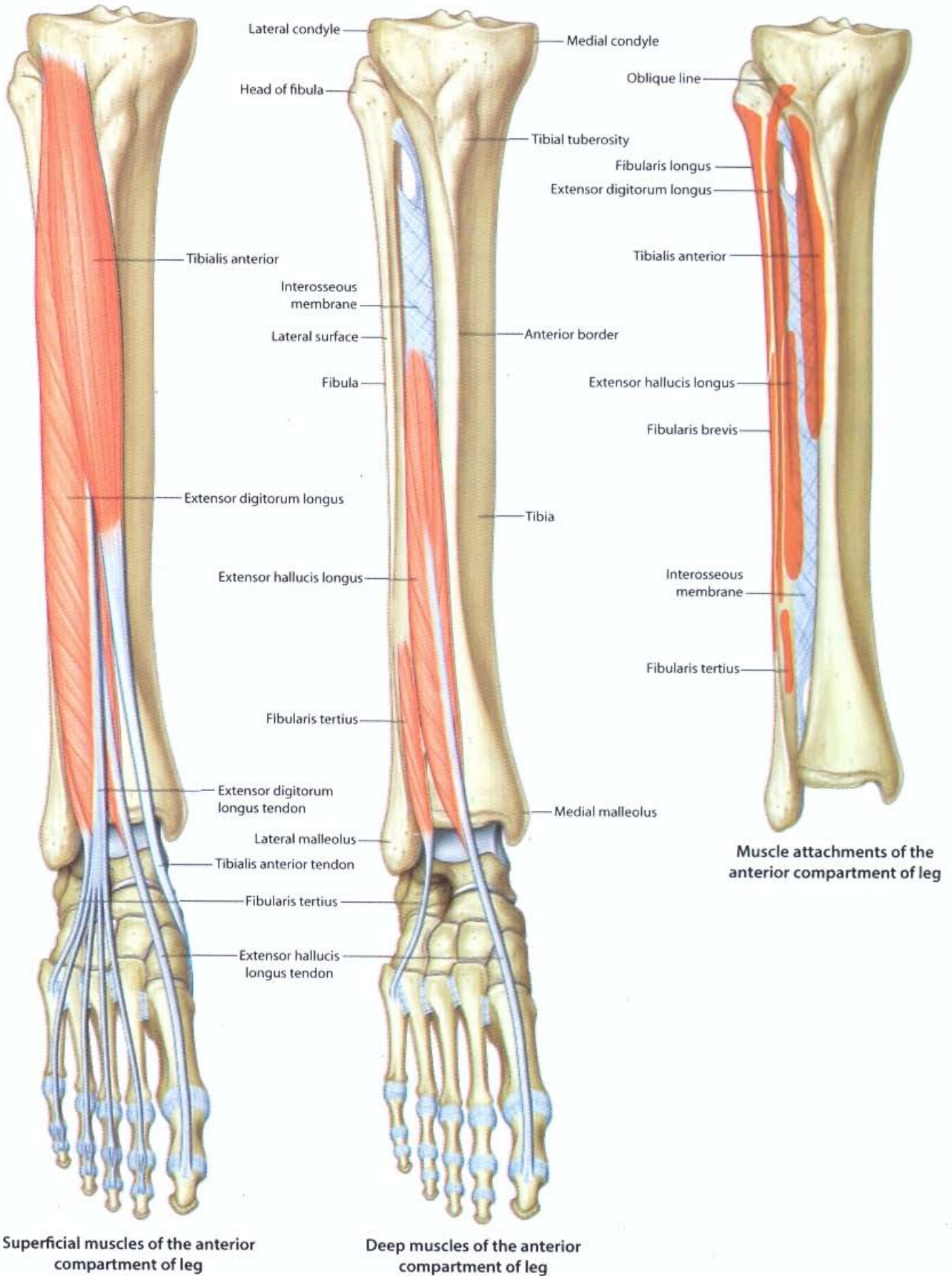
# LOWER LIMB • Anterior leg: superficial muscles



Surface anatomy of leg with overlay of muscles (anterior view)



Superficial muscles of leg (anterior view)



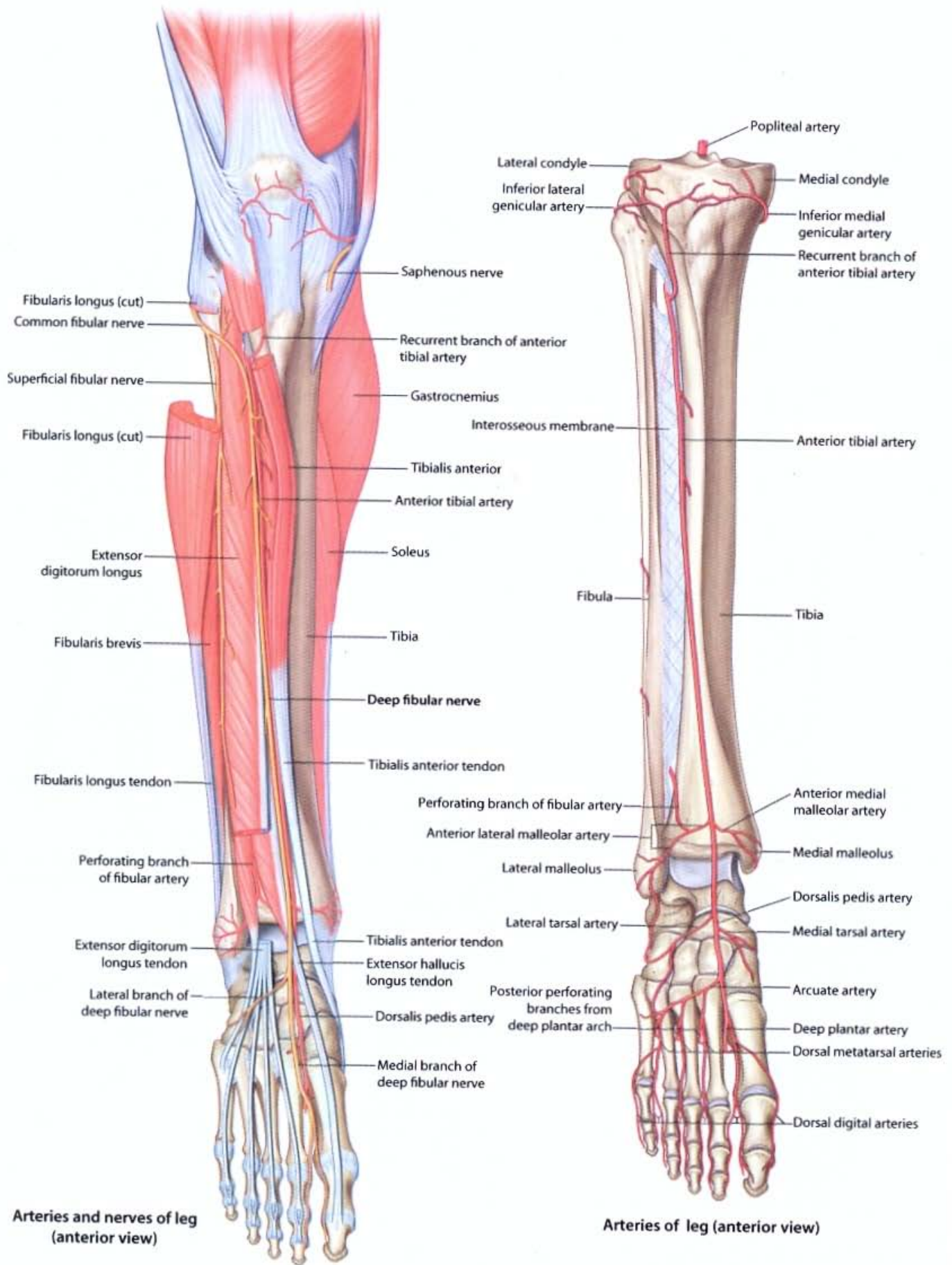
Superficial muscles of the anterior compartment of leg

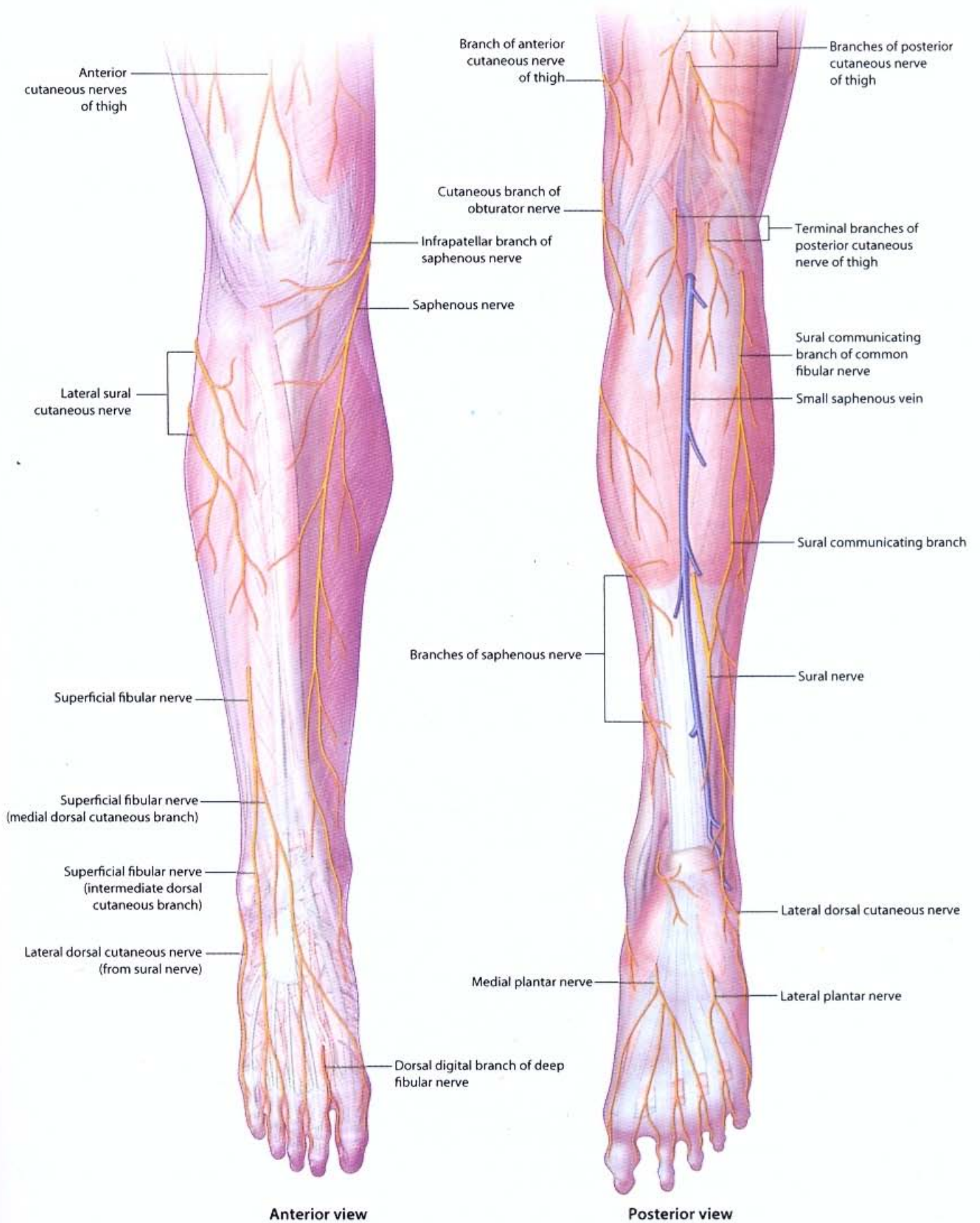
Deep muscles of the anterior compartment of leg

Muscle attachments of the anterior compartment of leg



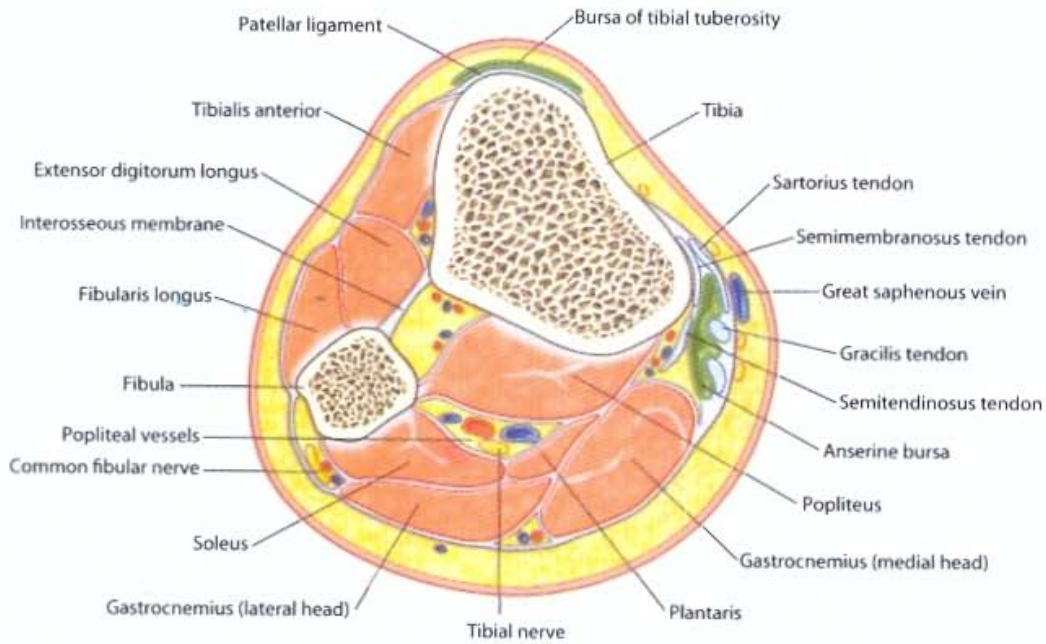
# LOWER LIMB • Anterior leg: arteries and nerves



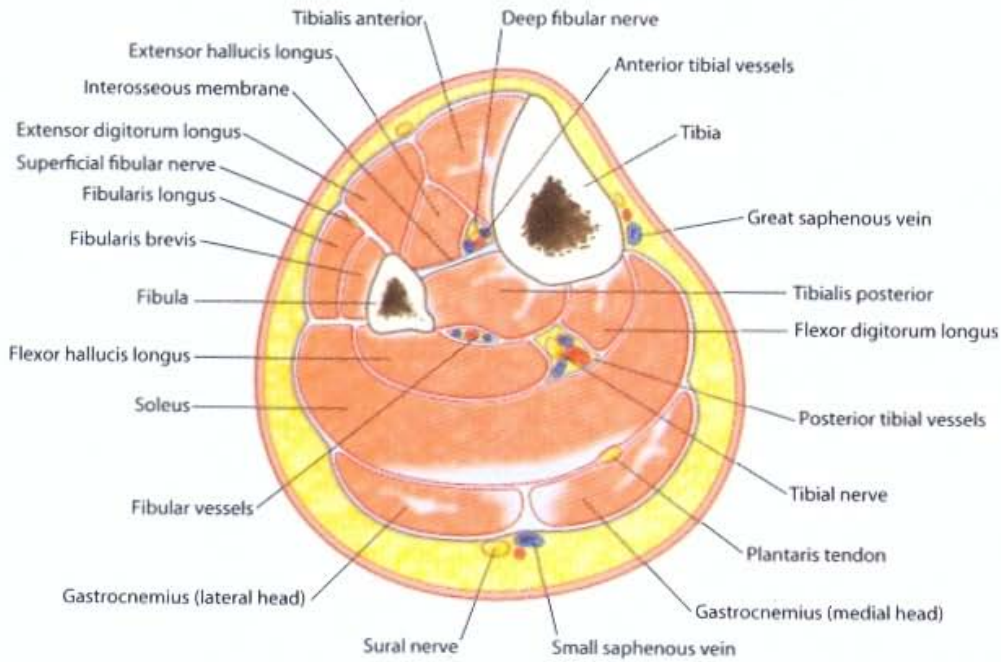


# LOWER LIMB • Transverse sections: leg

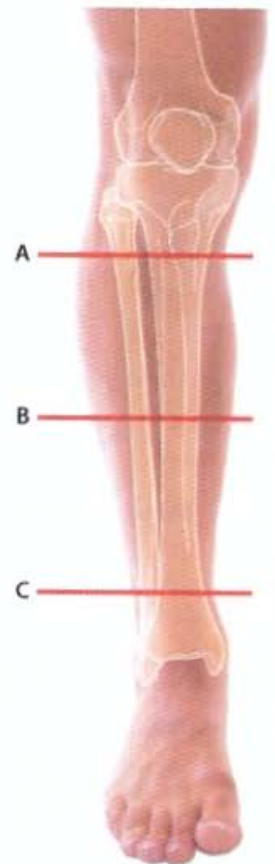
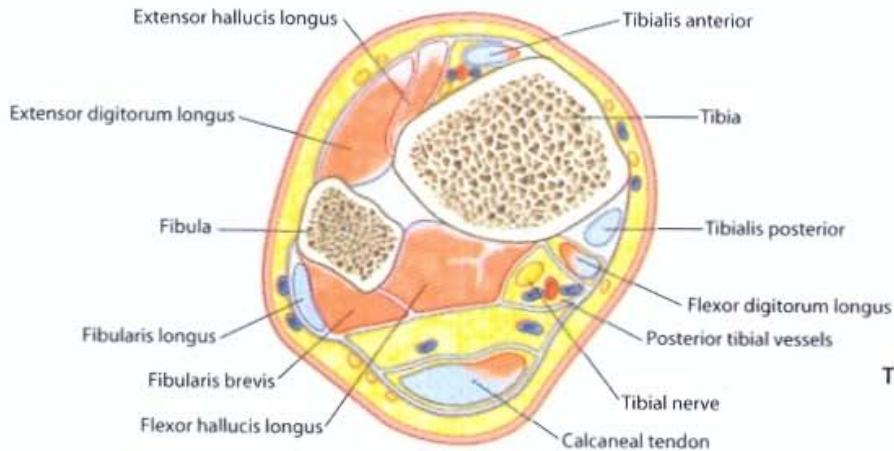
A



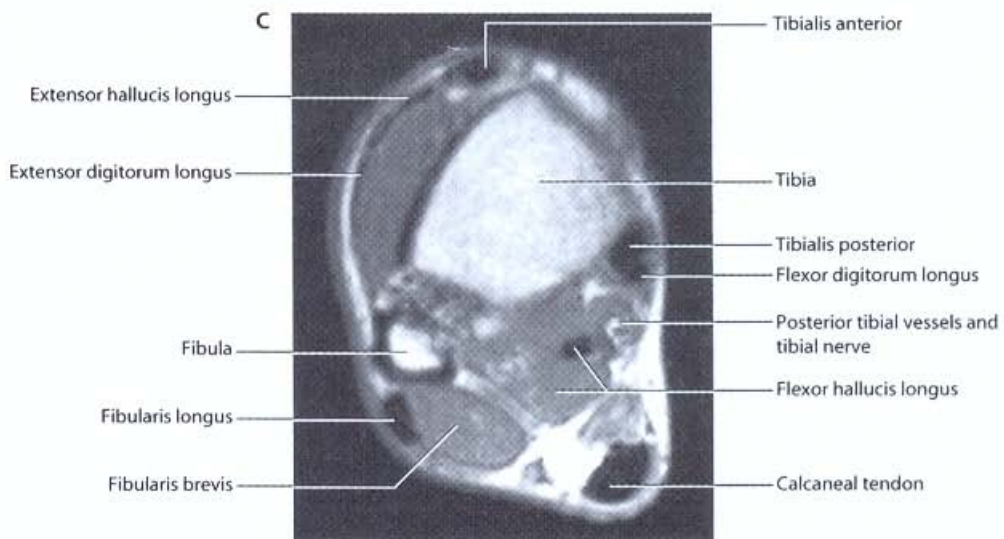
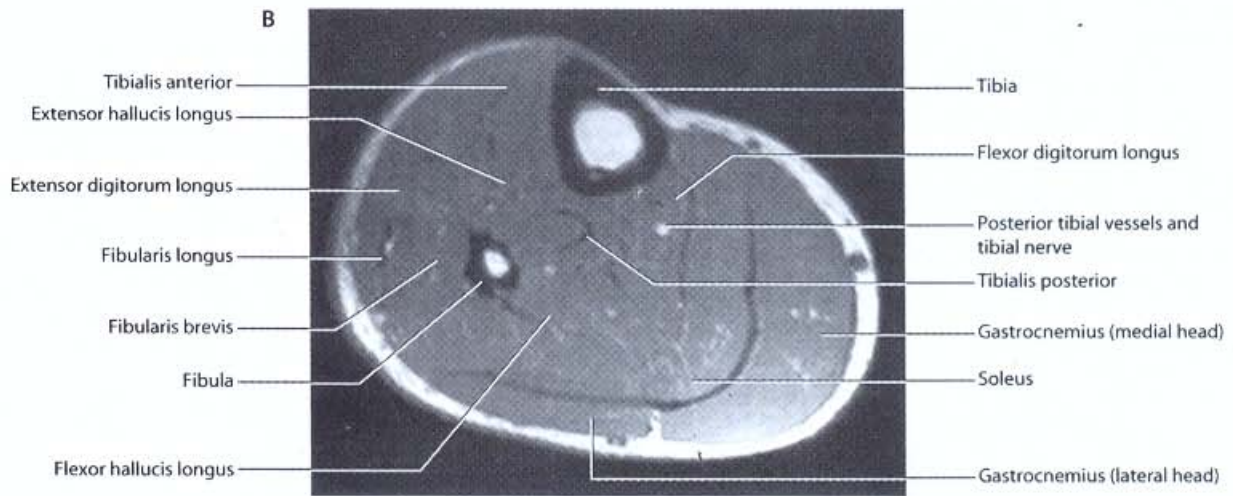
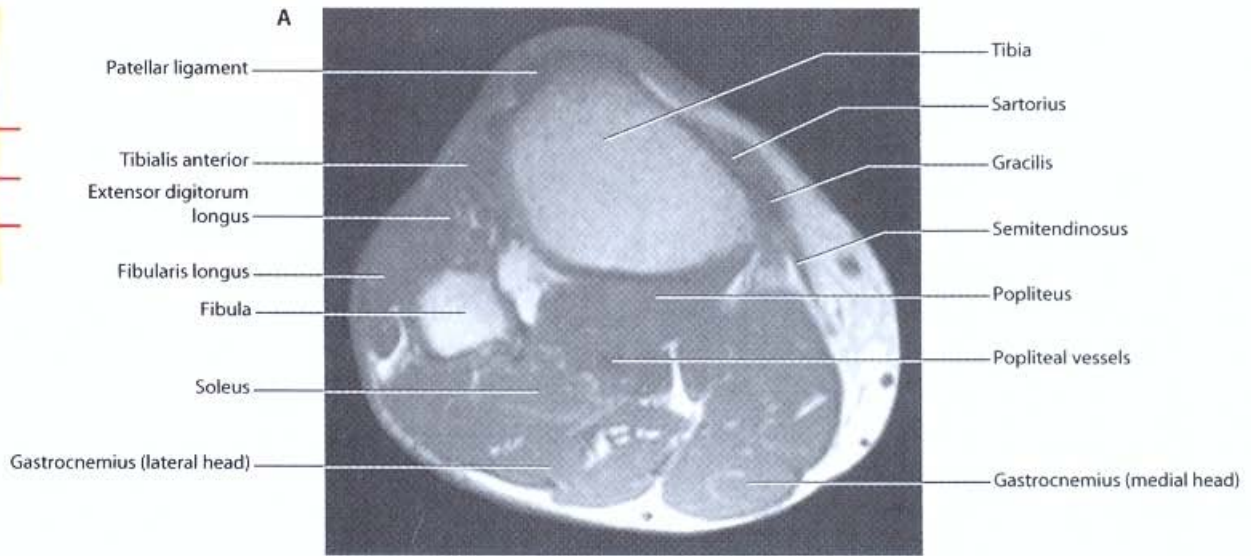
B



C



Transverse sections through leg



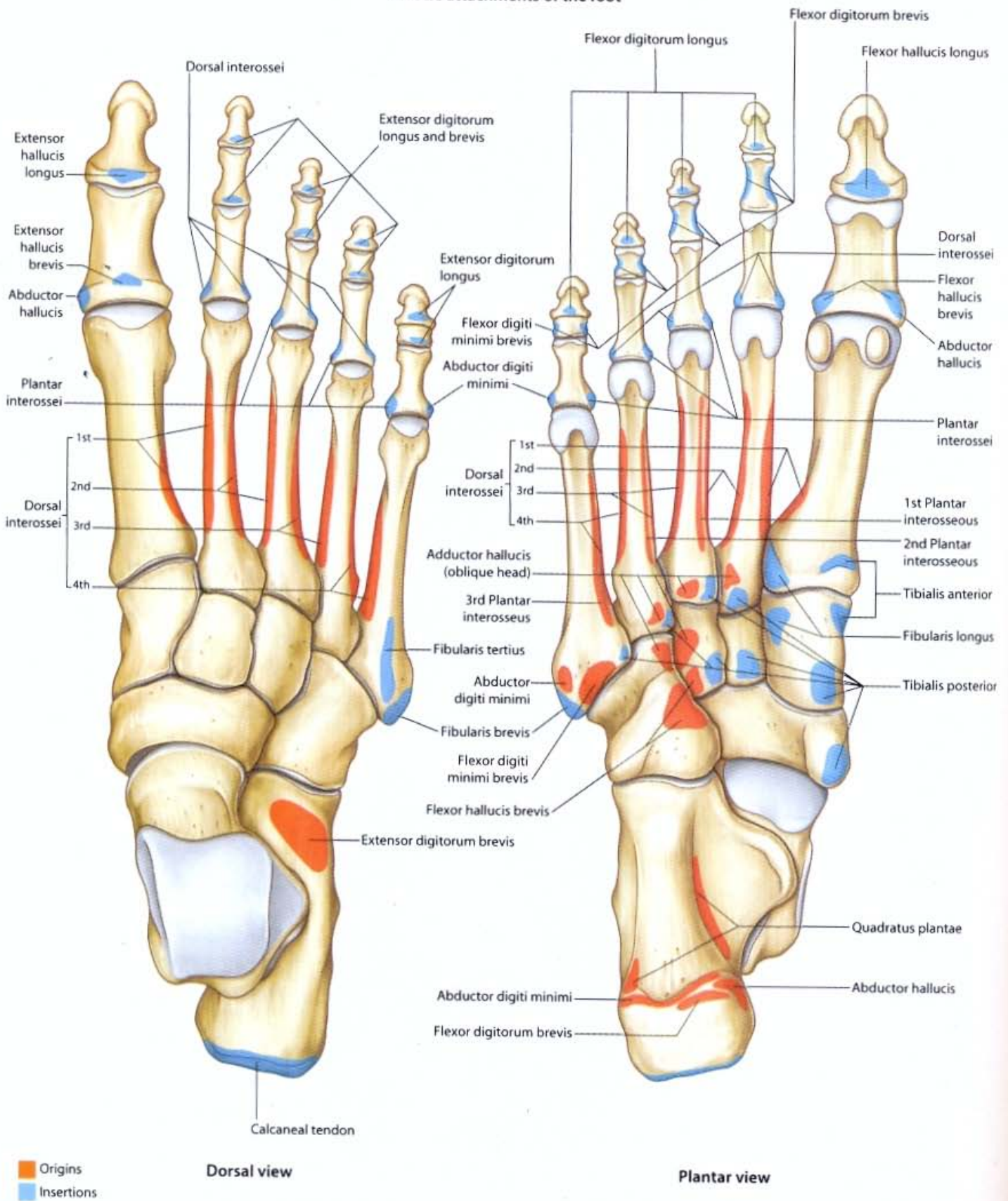
**Transverse/axial sections through the leg.**

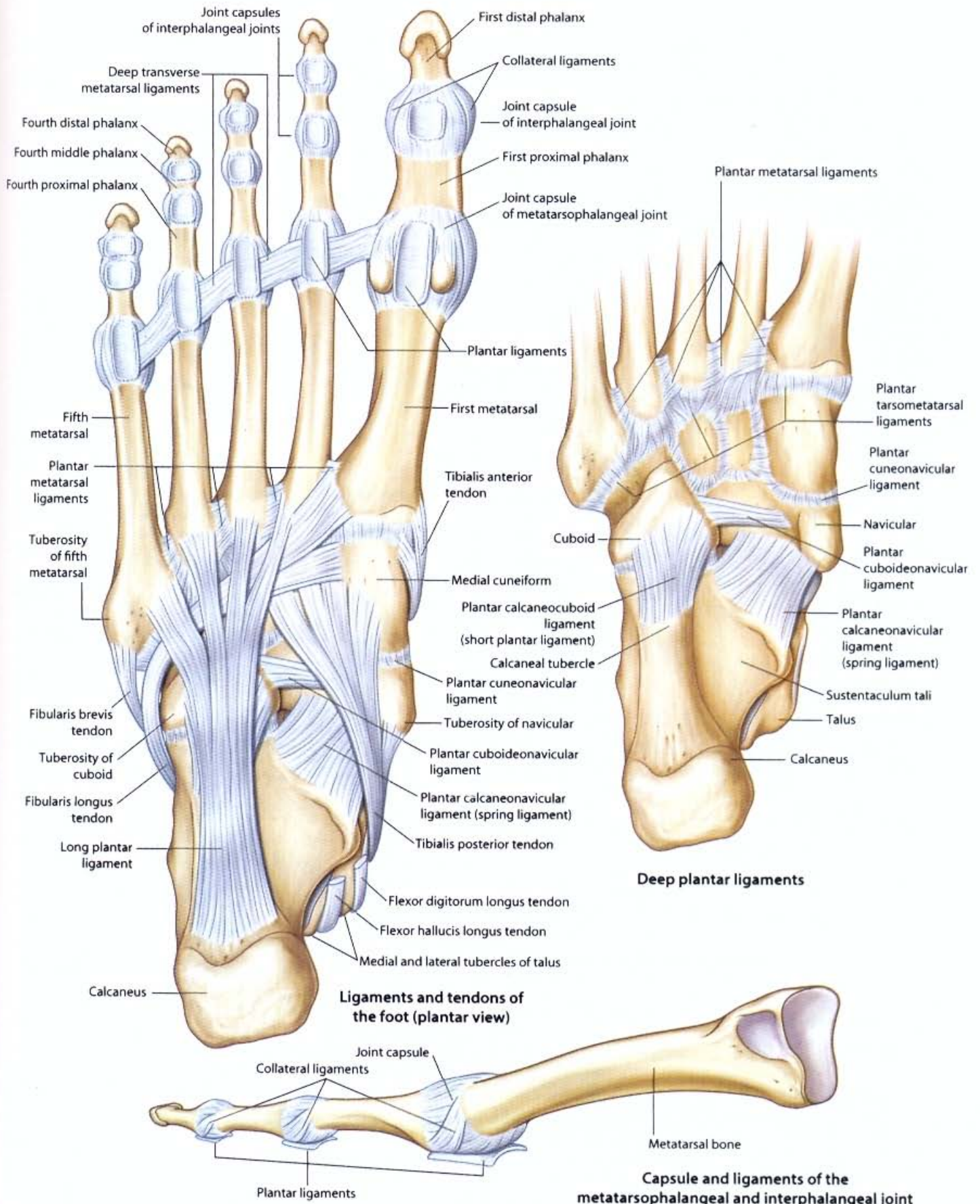
A. Proximal/upper leg. T1-weighted MR image in axial plane

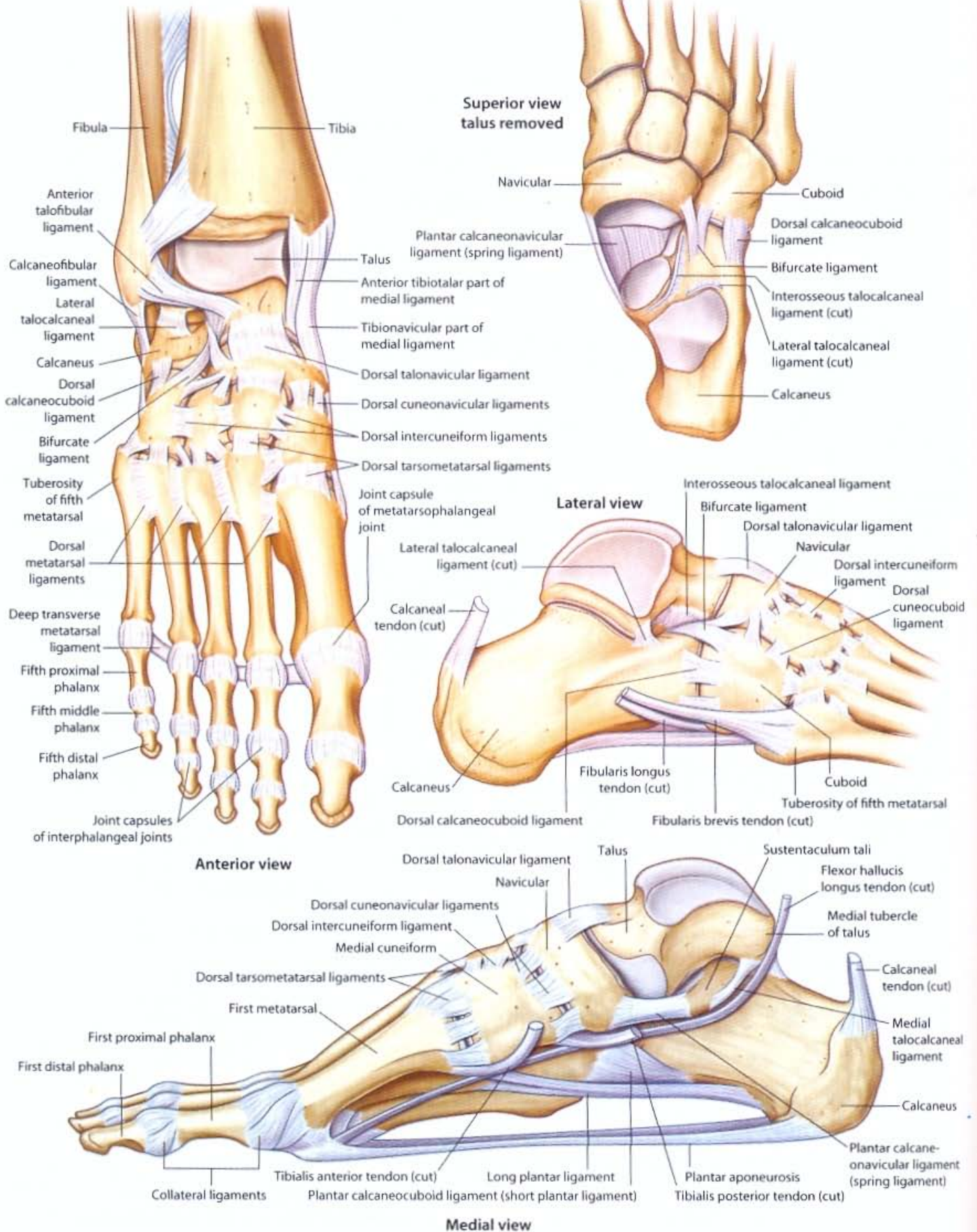
B. Middle leg. T1-weighted MR image in axial plane

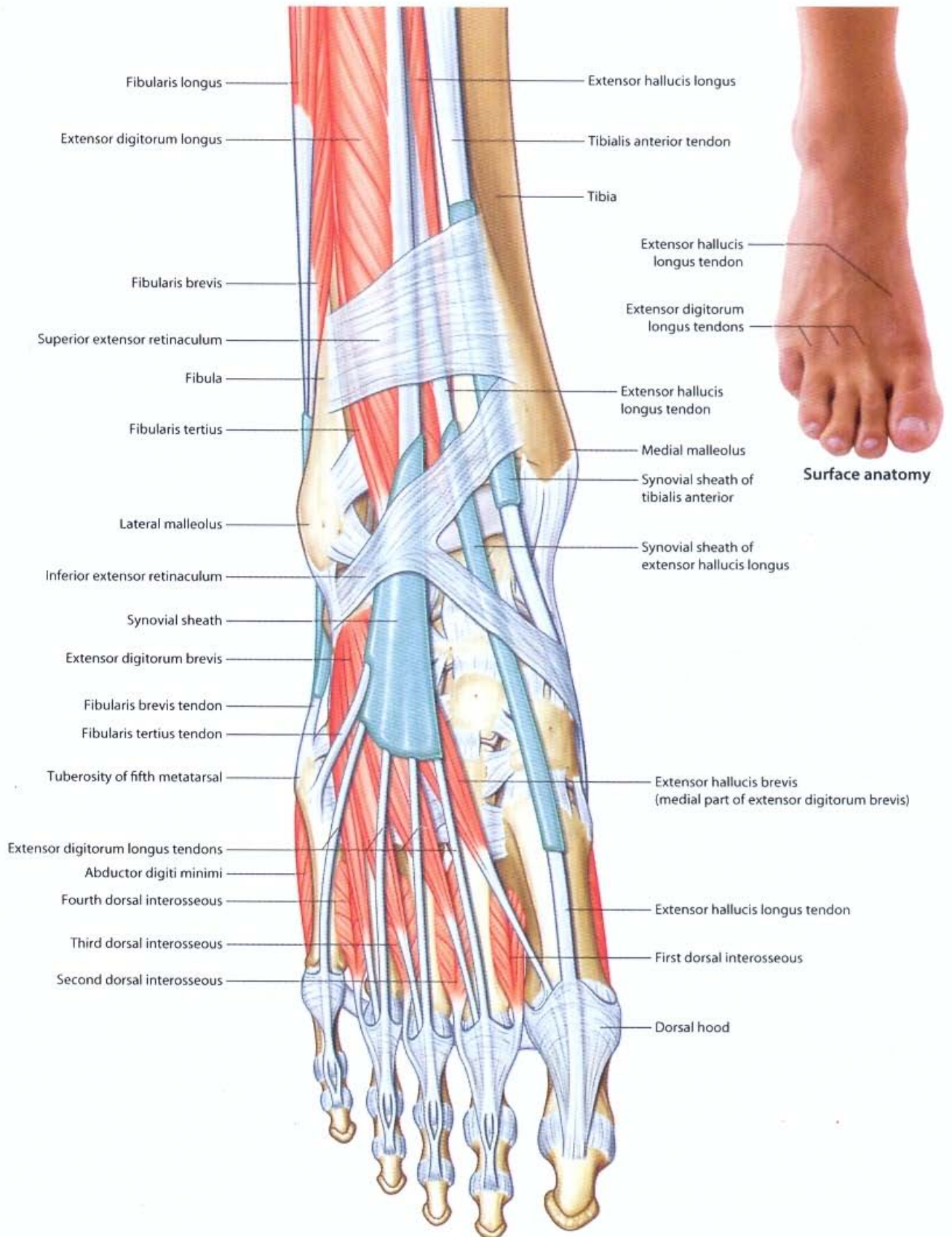
C. Distal/lower leg. T1-weighted MR image in axial plane

**Muscle attachments of the foot**



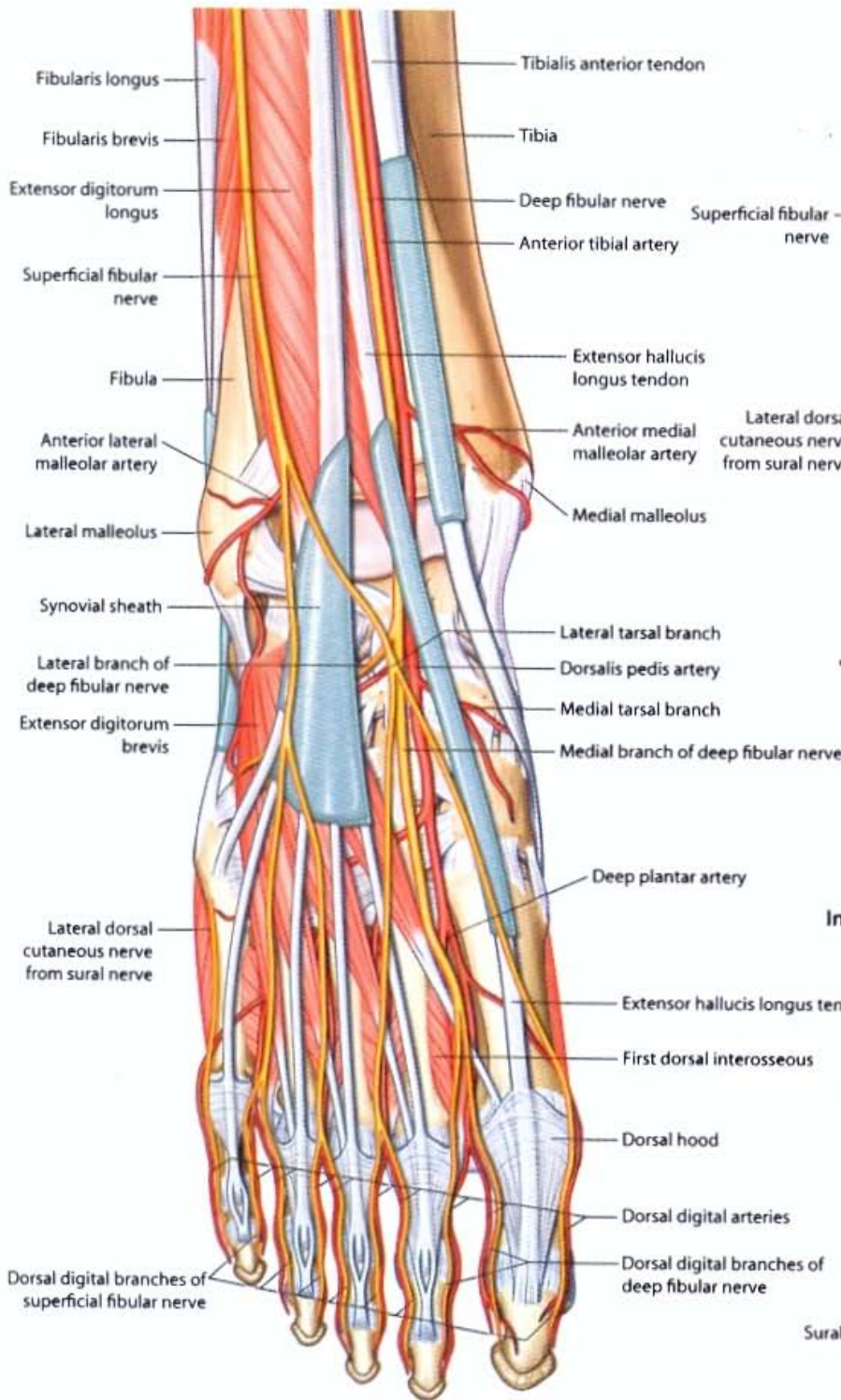




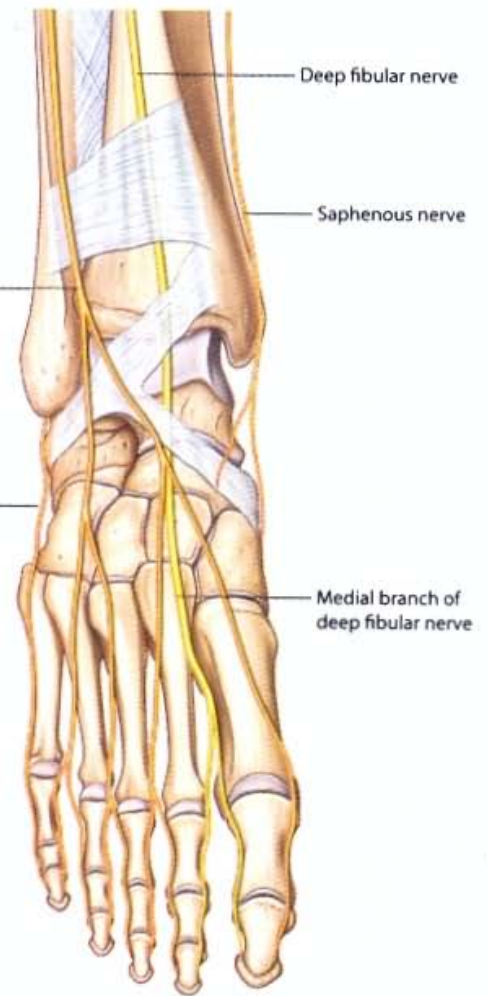


Superficial structures of the foot (dorsal view)

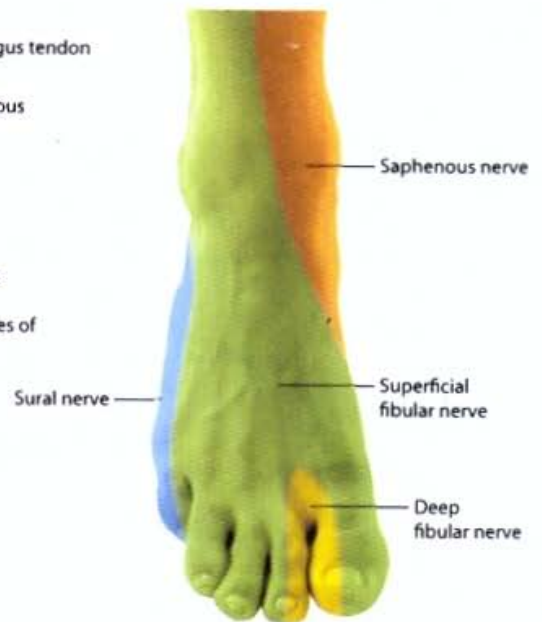




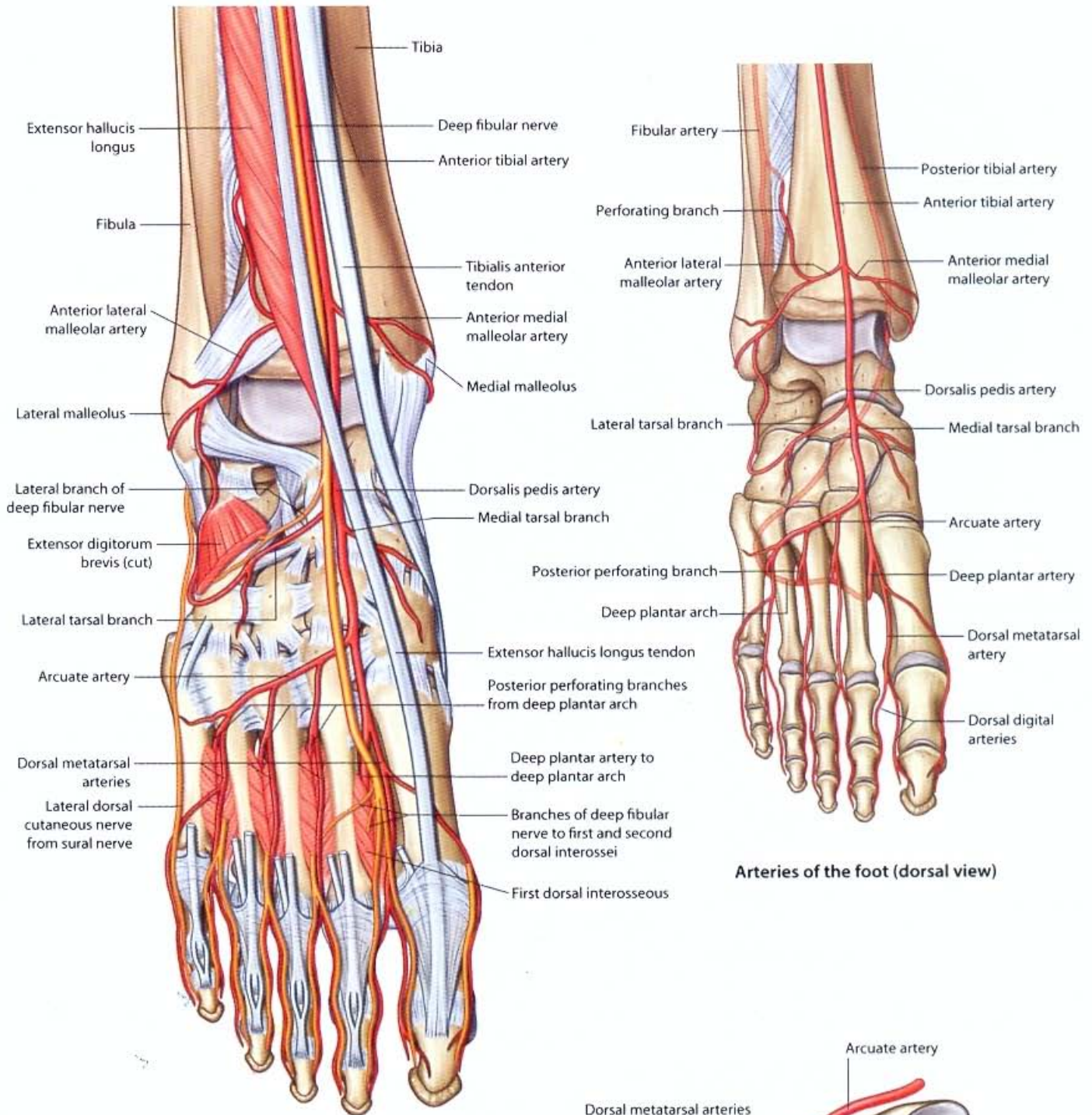
**Arteries and nerves of the foot (dorsal view)**



**Innervation of the foot (dorsal view)**

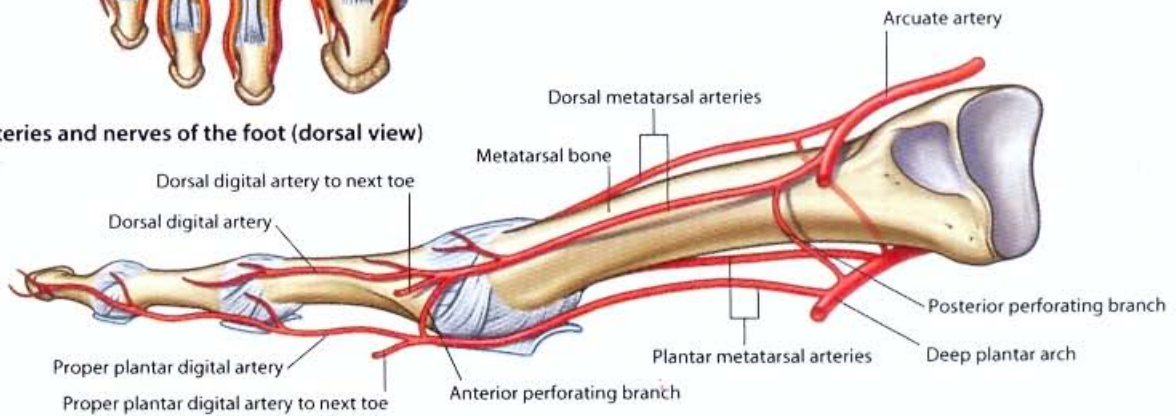


**Cutaneous distribution**

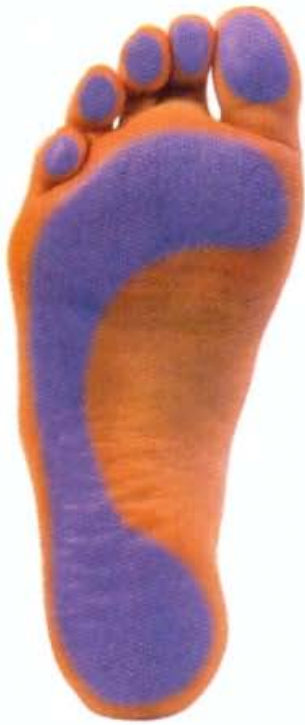

Arteries of the foot (dorsal view)

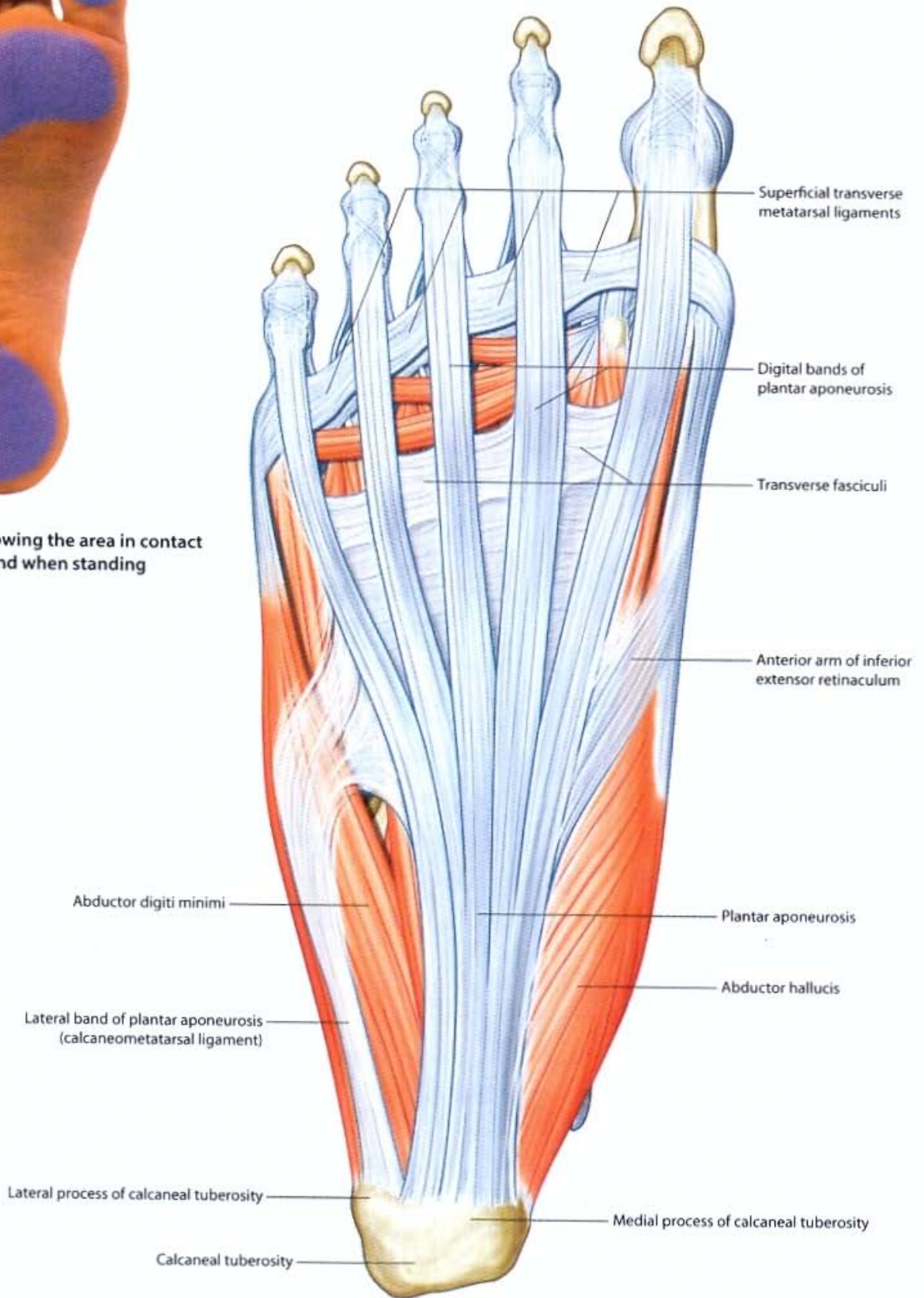
Deep arteries and nerves of the foot (dorsal view)



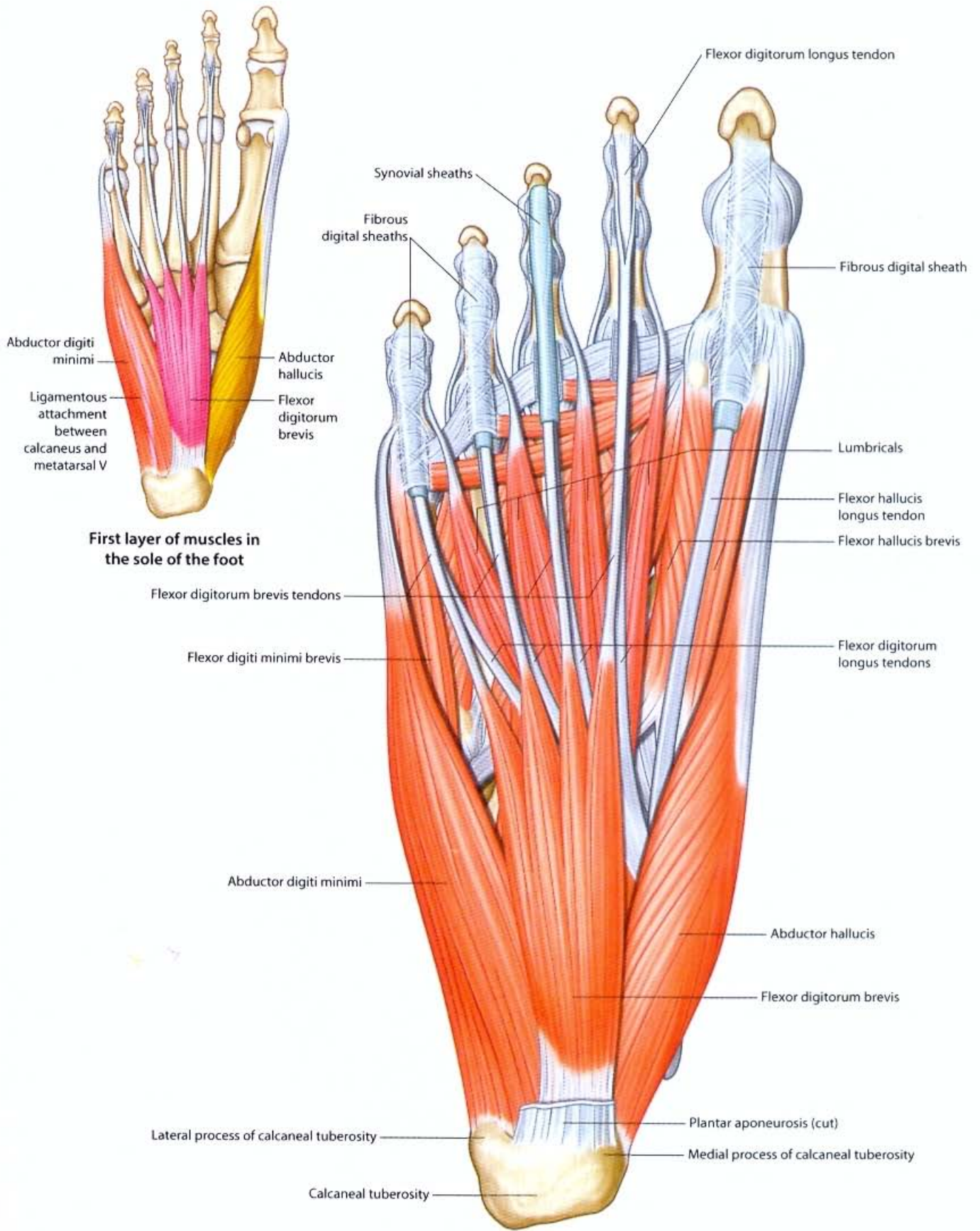
Arteries of digit III (middle toe)



Surface anatomy showing the area in contact with the ground when standing

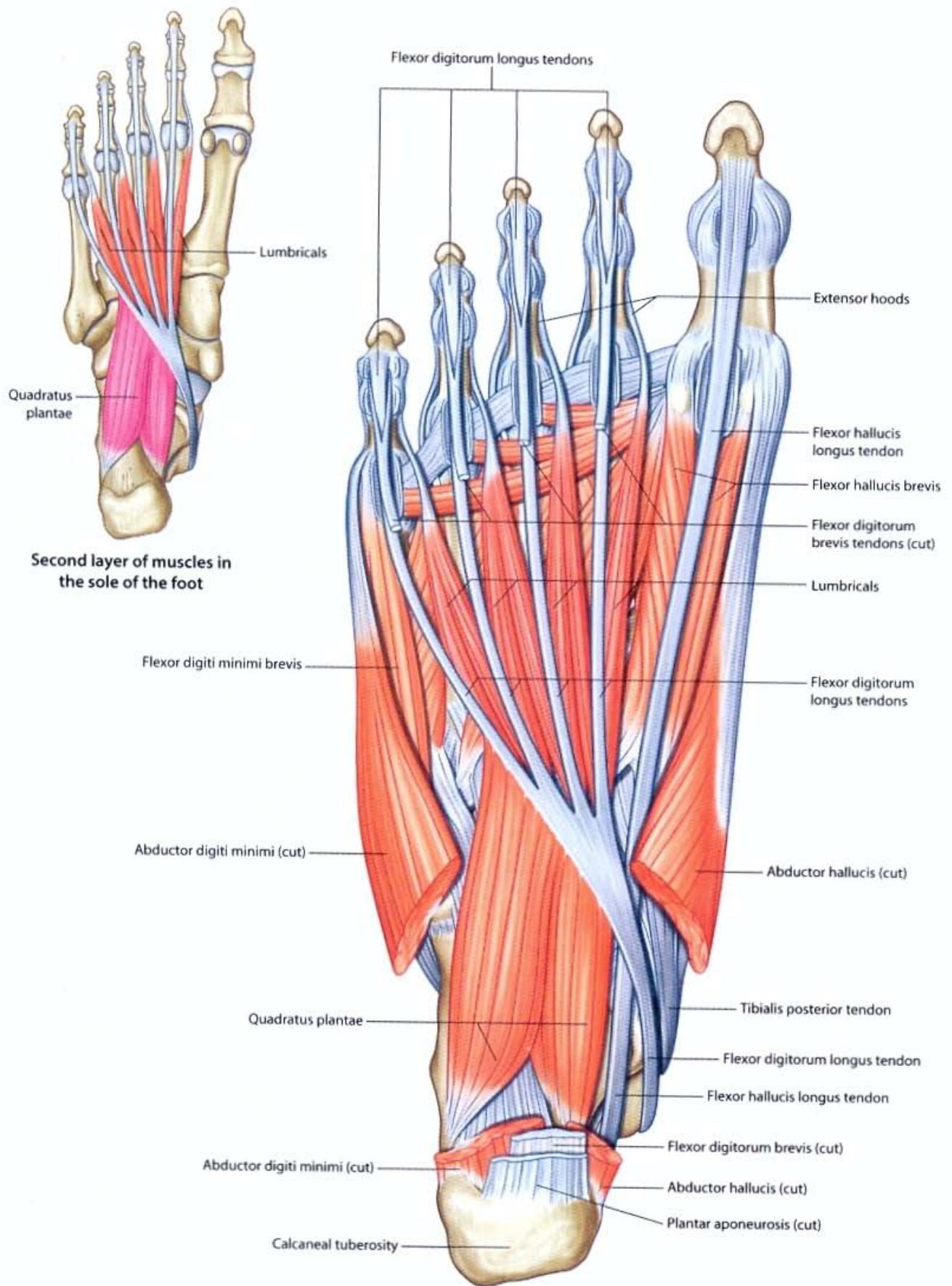


Superficial structures of the foot (plantar view)



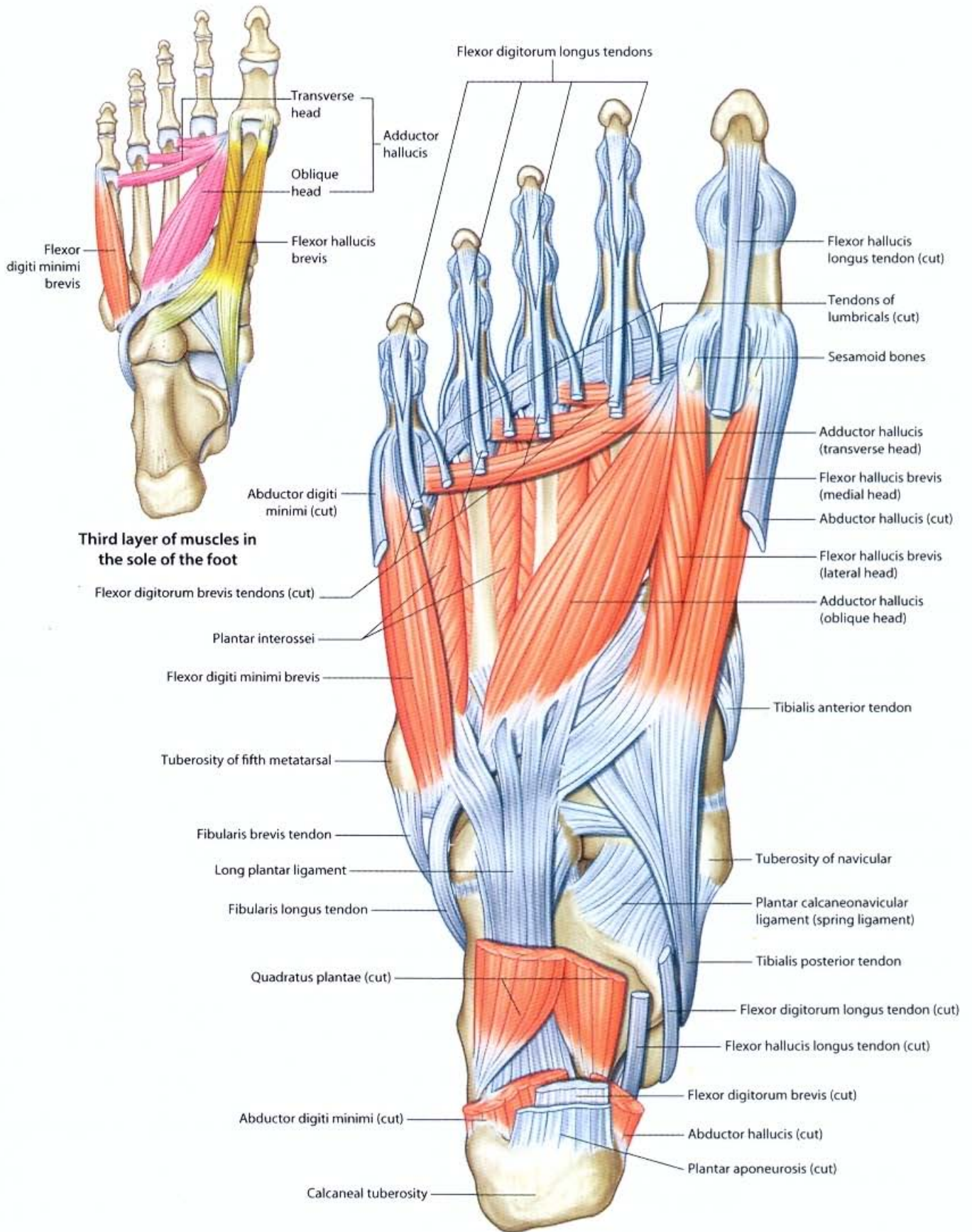
First layer of muscles in the sole of the foot

Muscles of sole of foot (first layer)



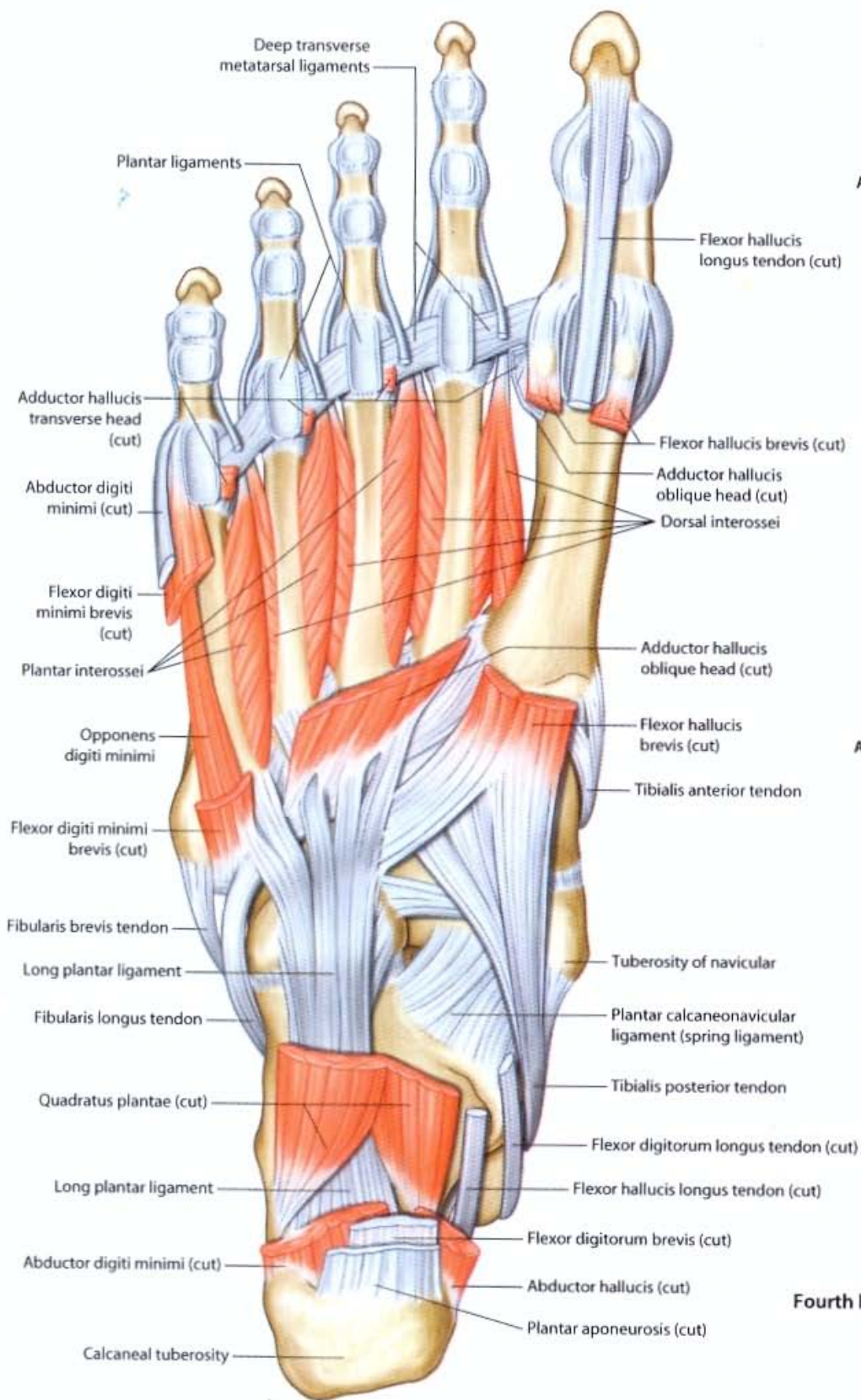
Second layer of muscles in the sole of the foot

Muscles of sole of foot (second layer)

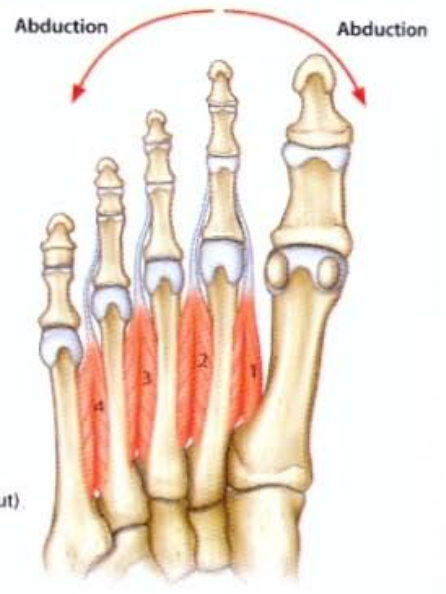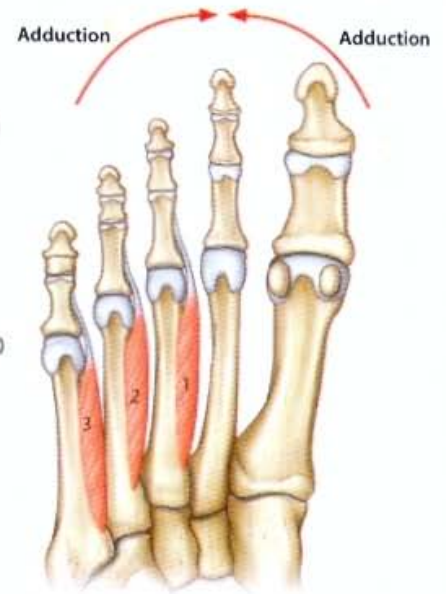


**Third layer of muscles in the sole of the foot**

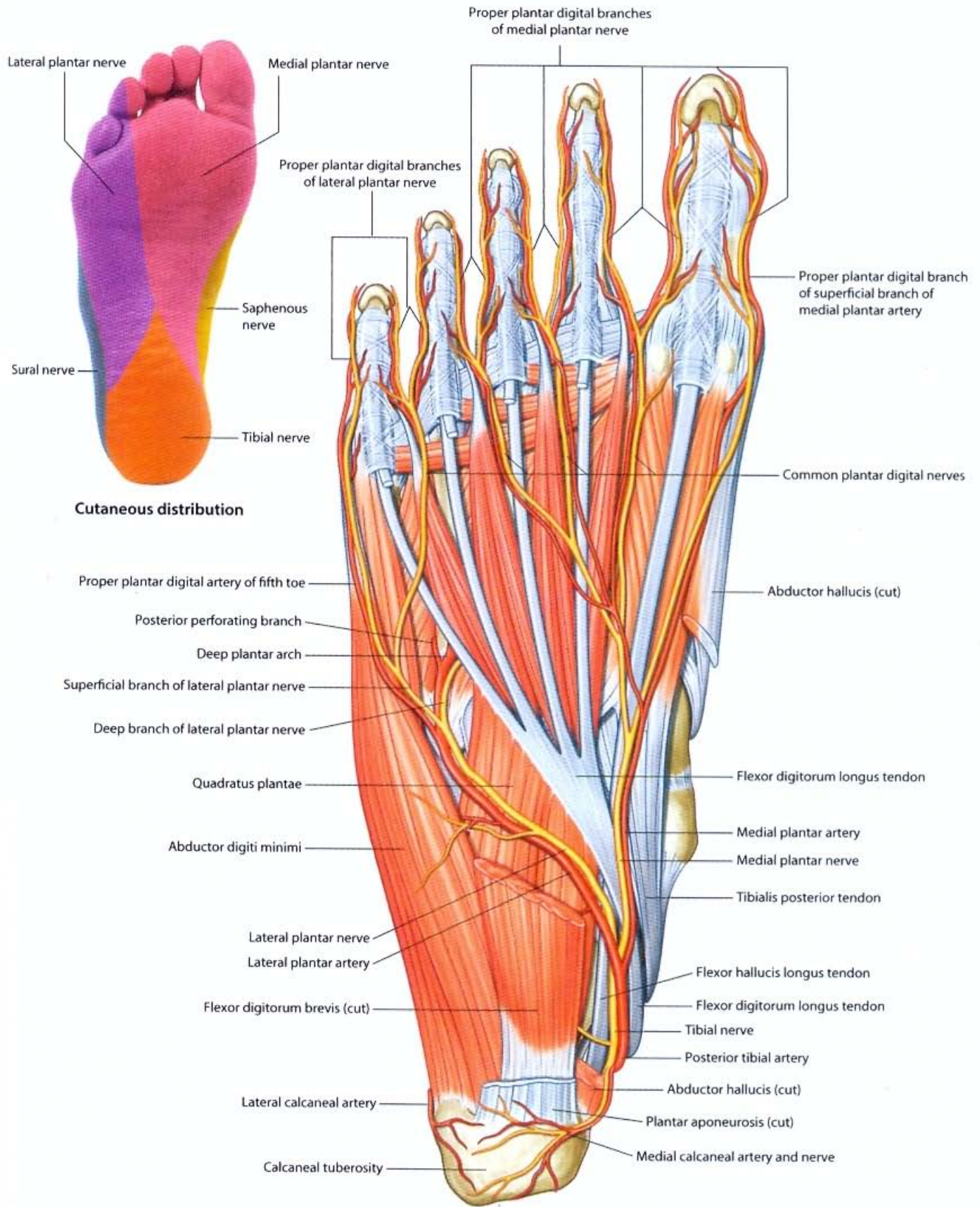
**Muscles of sole of foot (third layer)**



**Muscles of sole of foot (fourth layer)**

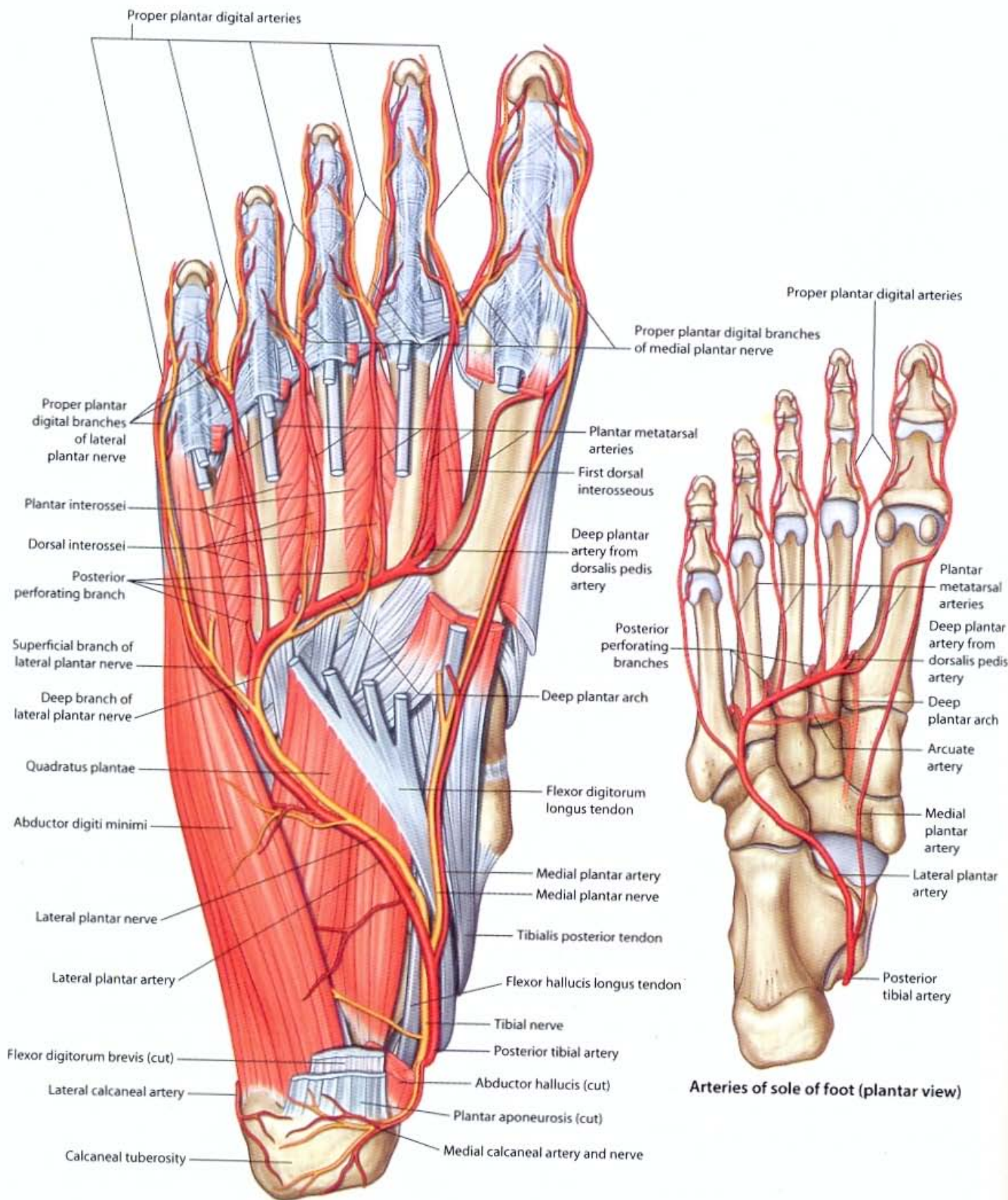


**Fourth layer of muscles in the sole of the foot**



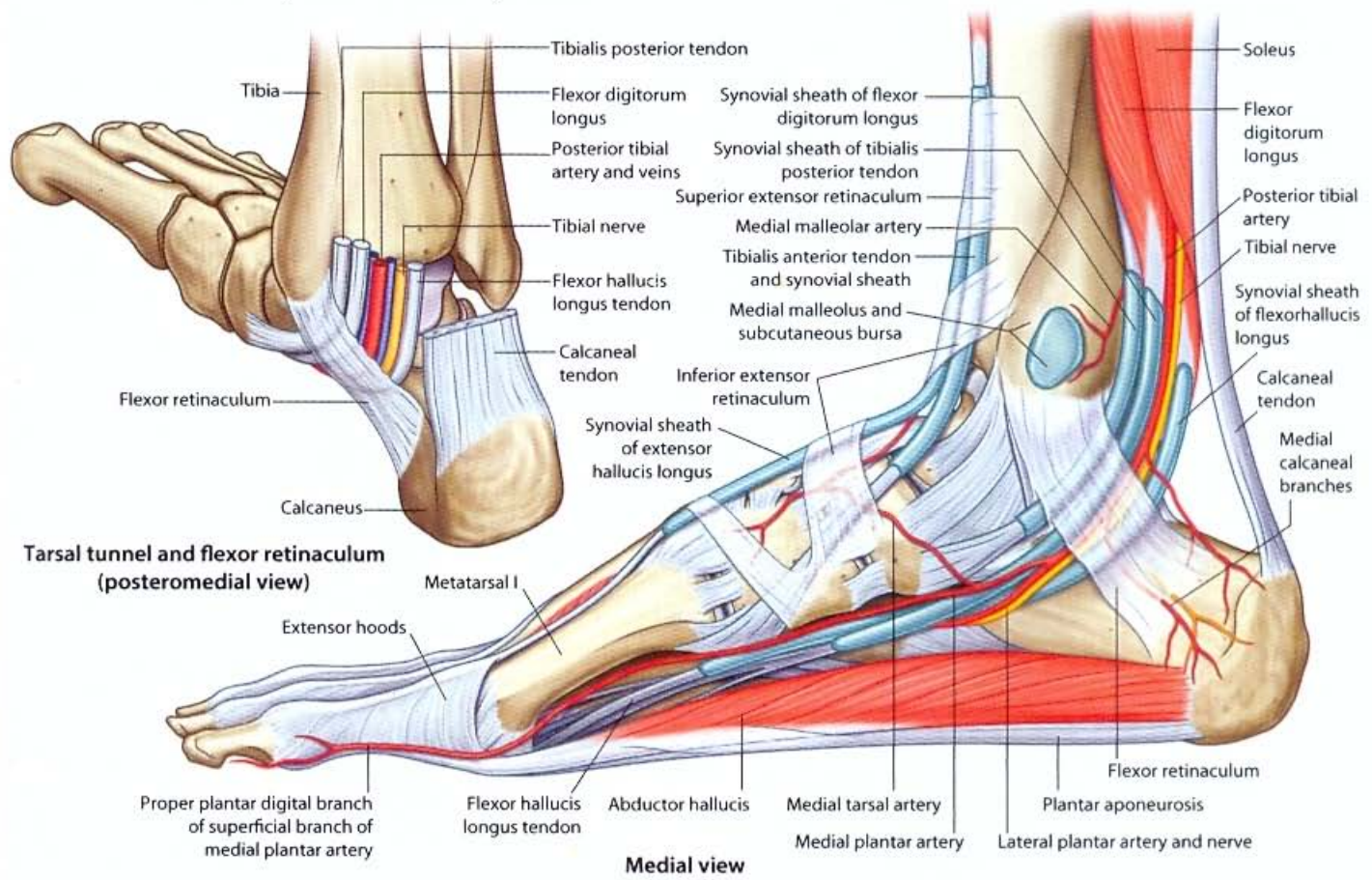
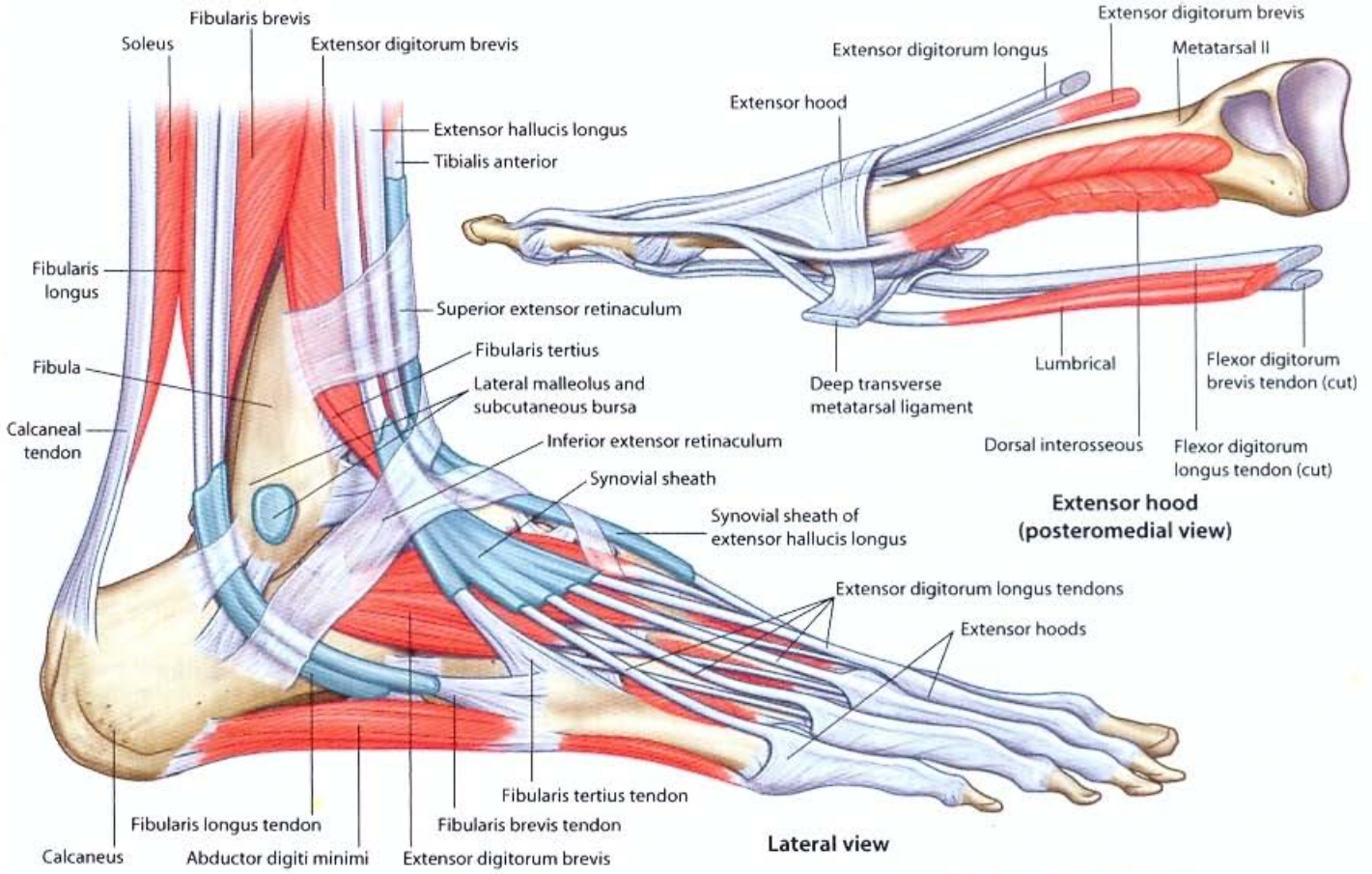
Arteries and nerves of sole of foot (plantar view)



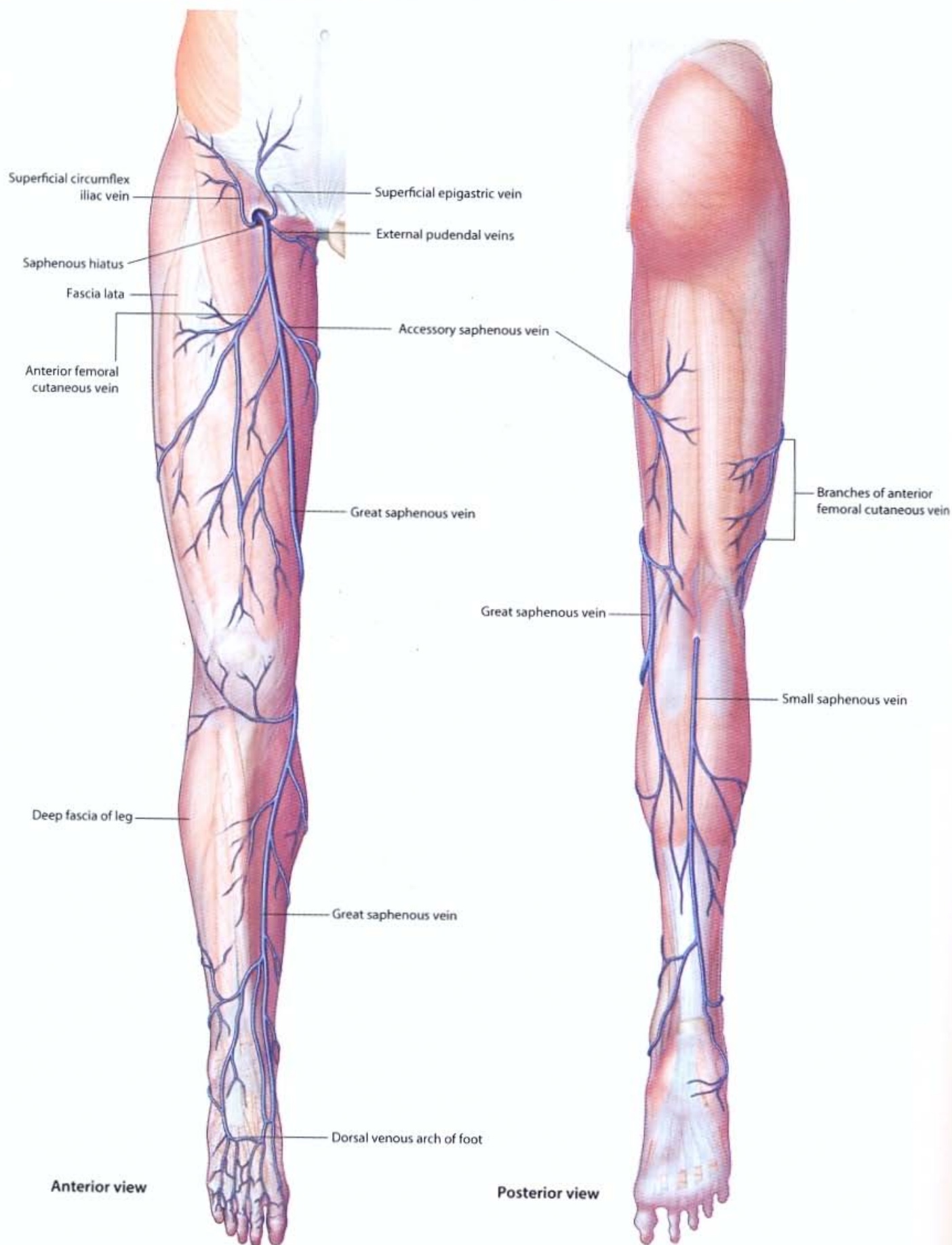


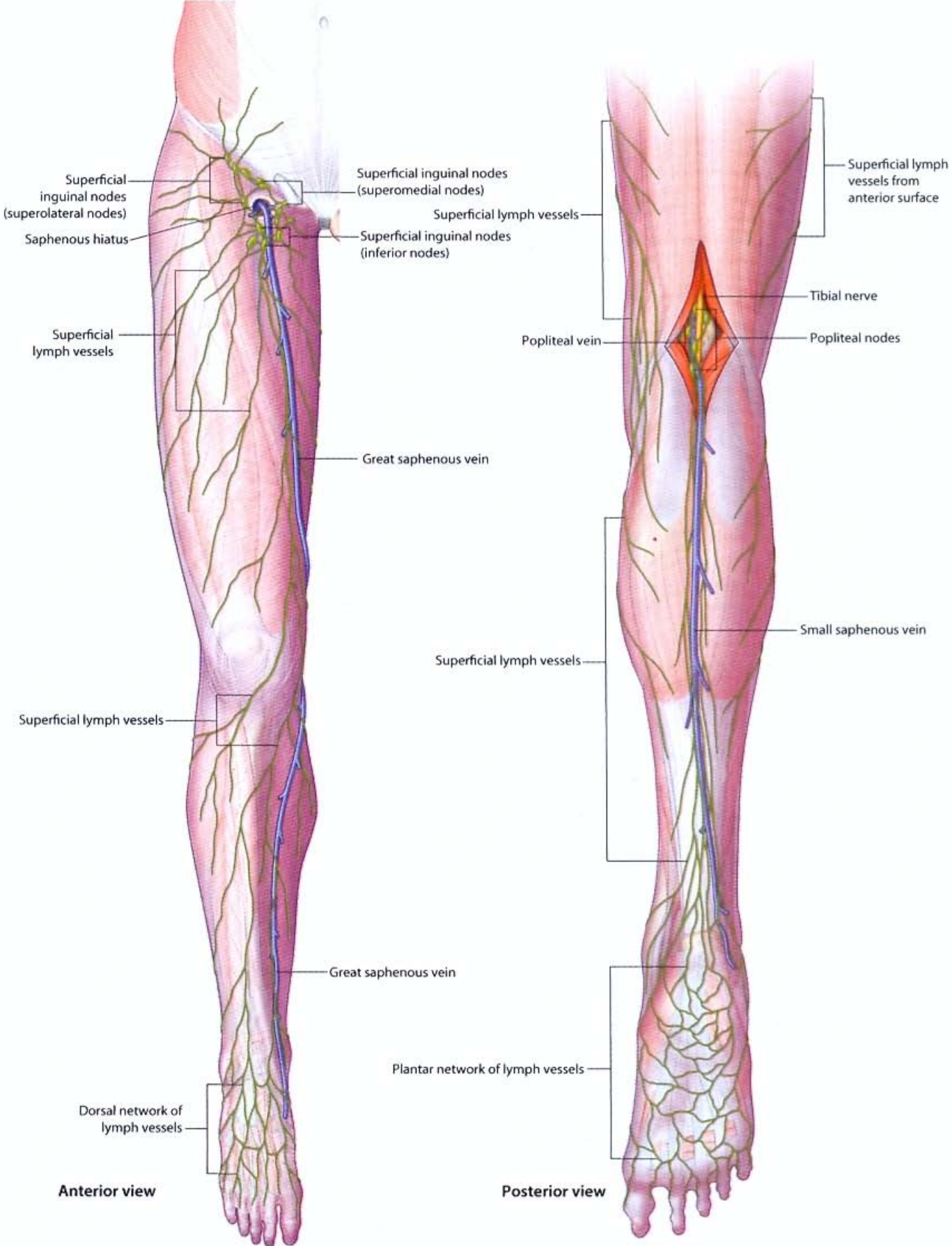
**Arteries and nerves of sole of foot (plantar view)**

**Arteries of sole of foot (plantar view)**

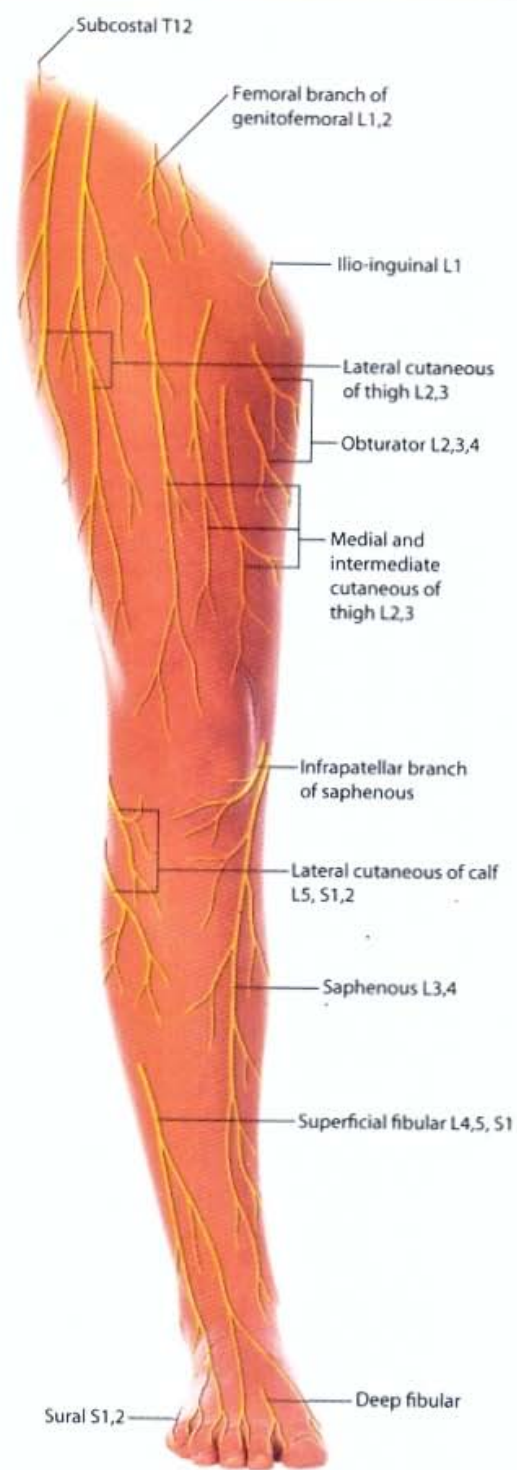


# LOWER LIMB • Superficial veins of the lower limb

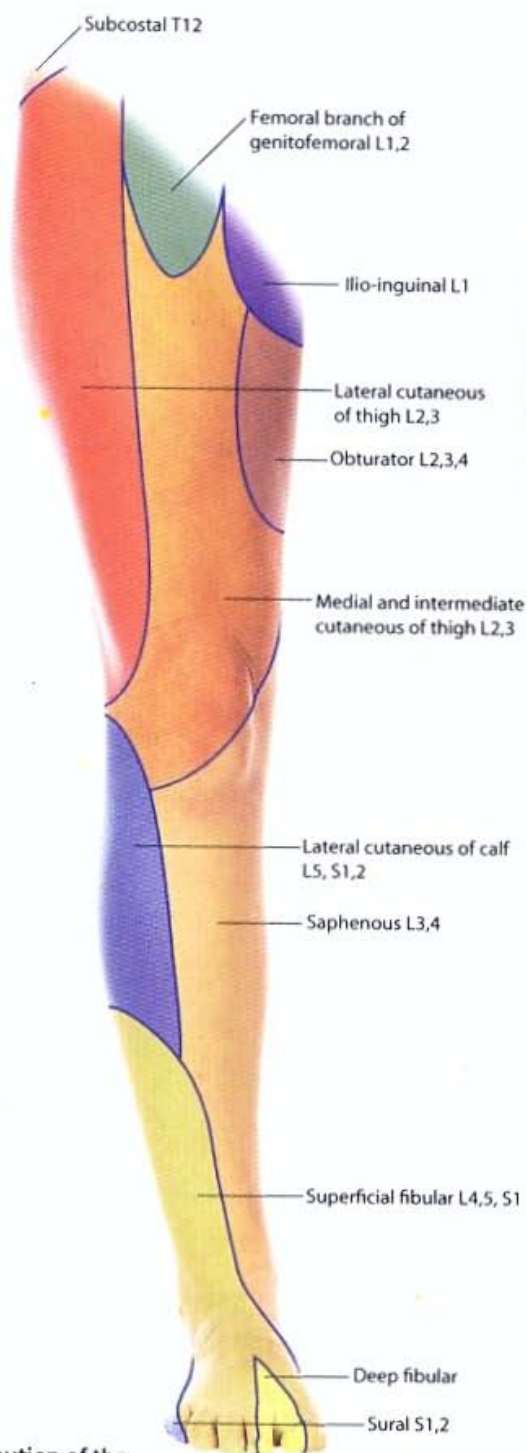




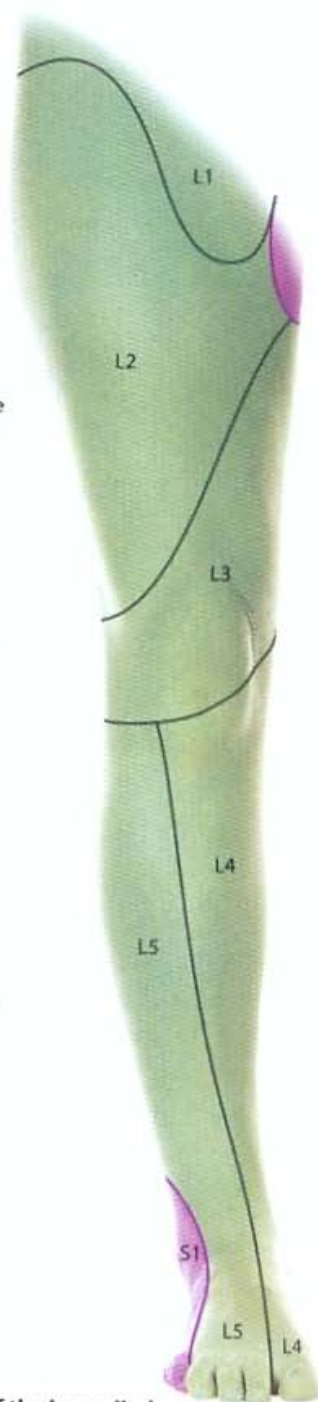
# LOWER LIMB • Anterior cutaneous nerves and dermatomes of the lower limb



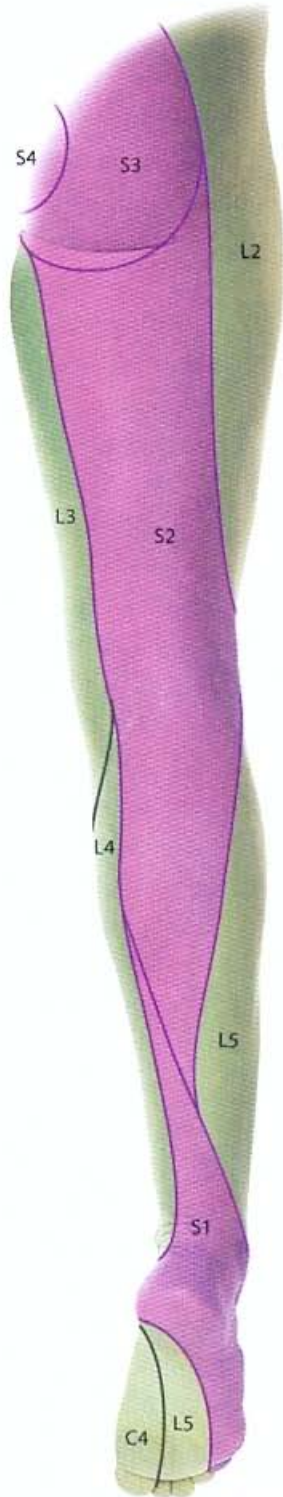
Cutaneous nerves of the lower limb



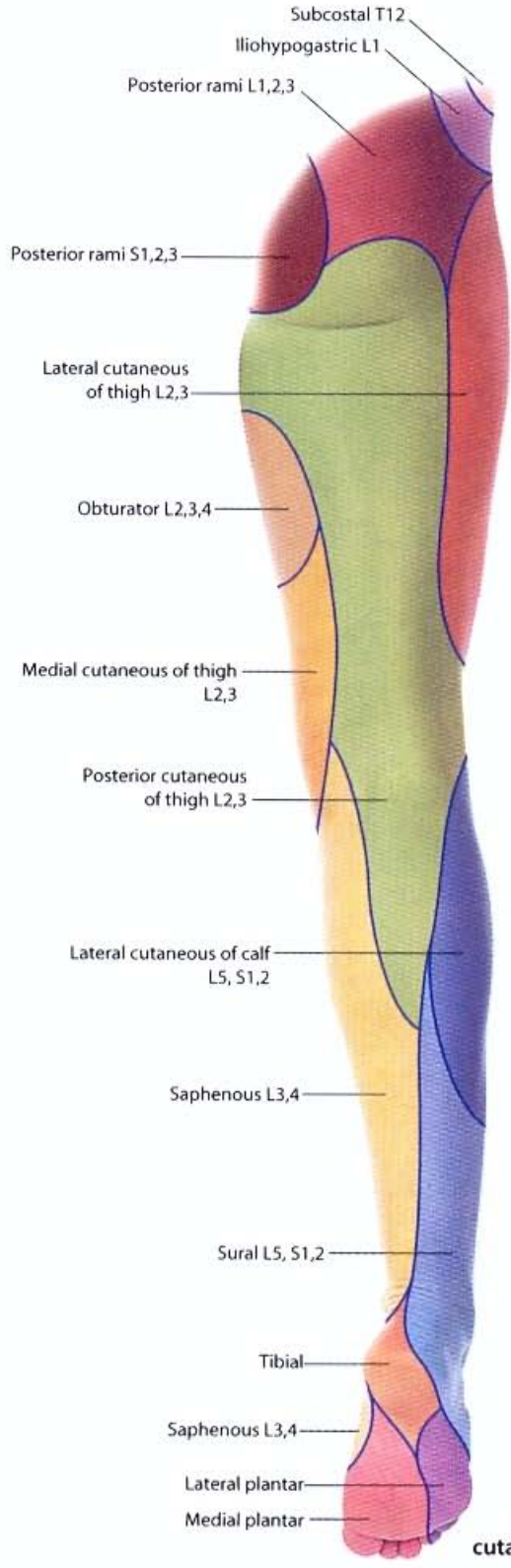
Areas of distribution of the cutaneous nerves of the lower limb



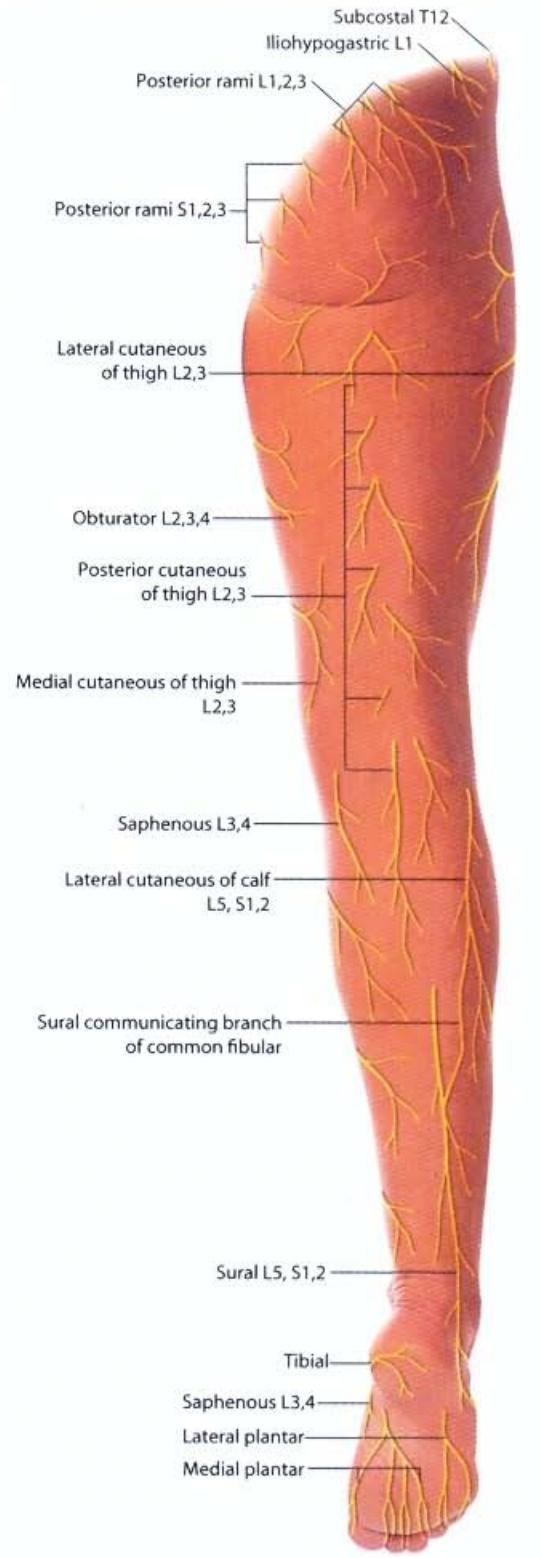
Dermatomes of the lower limb



Dermatomes of the lower limb



Areas of distribution of the cutaneous nerves of the lower limb



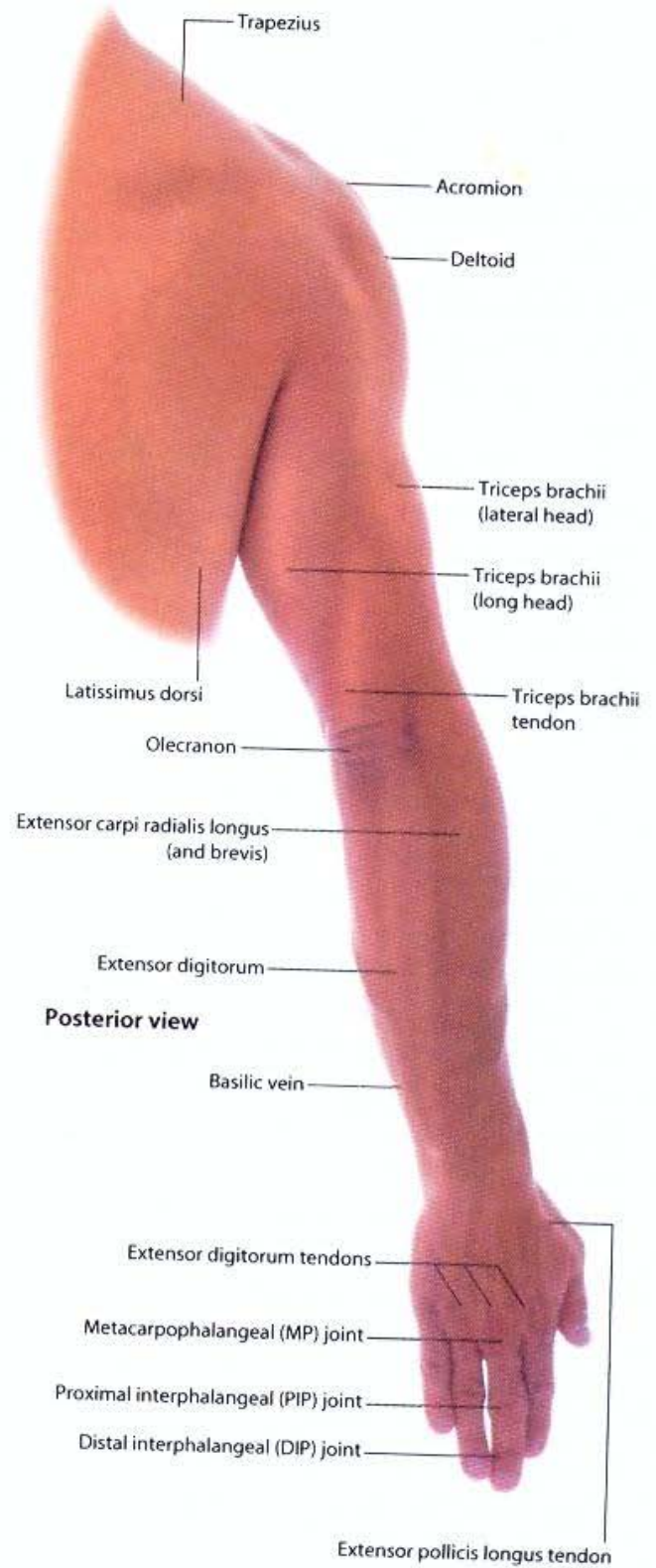
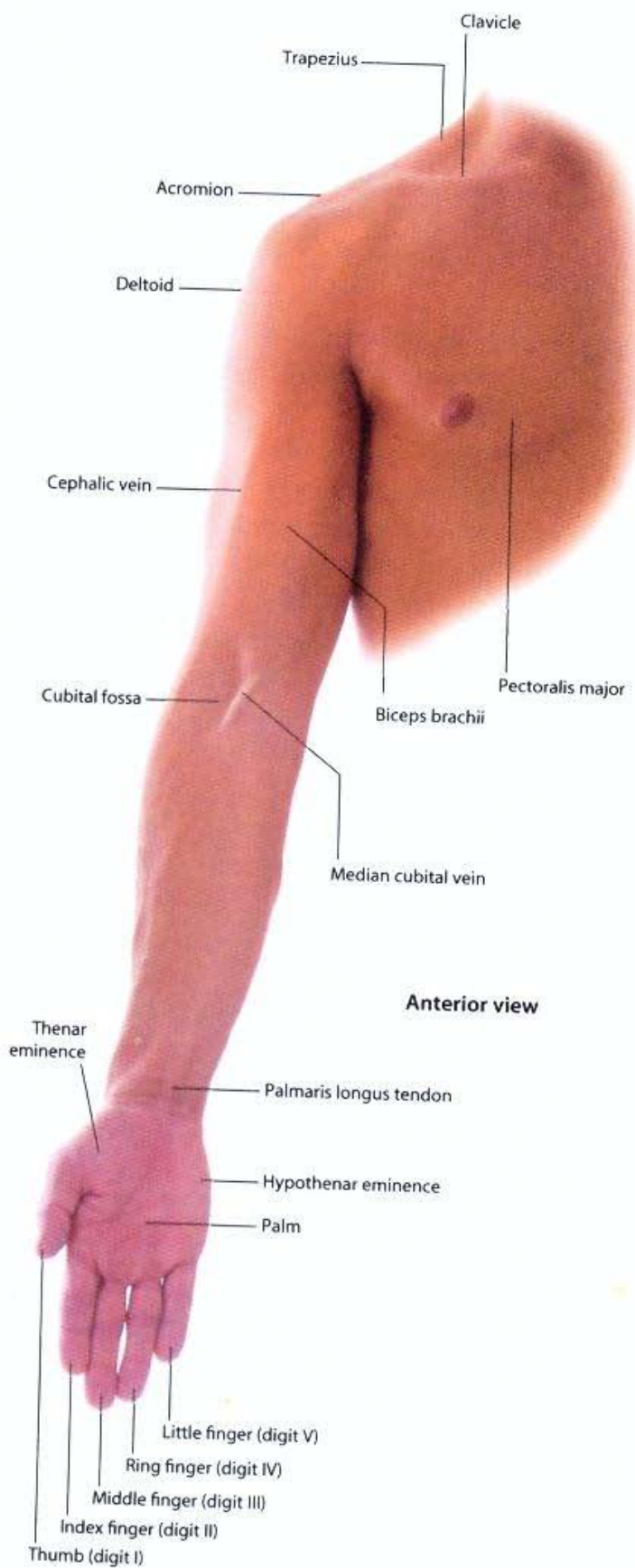
Cutaneous nerves of the lower limb

# 7

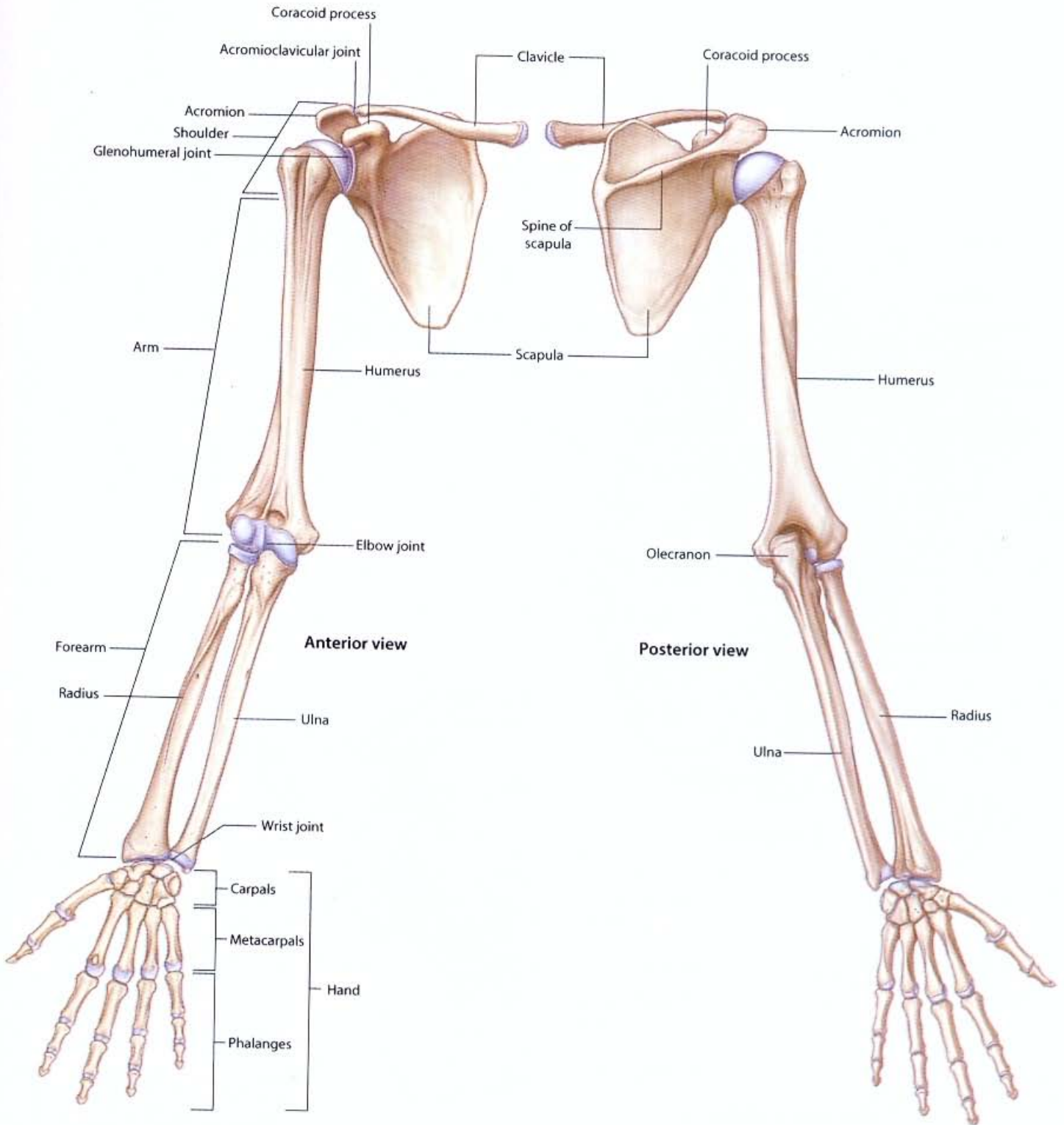
# UPPER LIMB

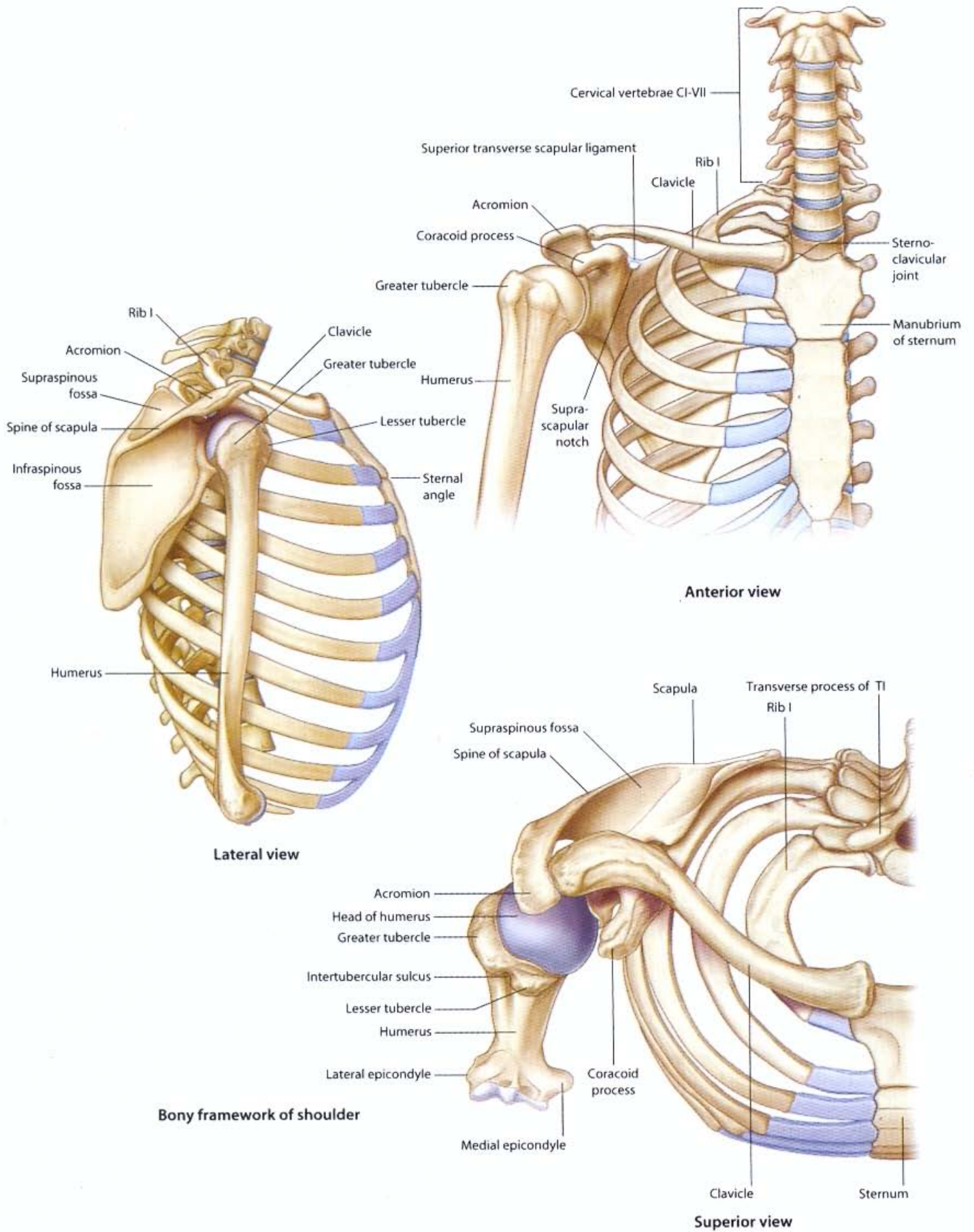
## CONTENTS

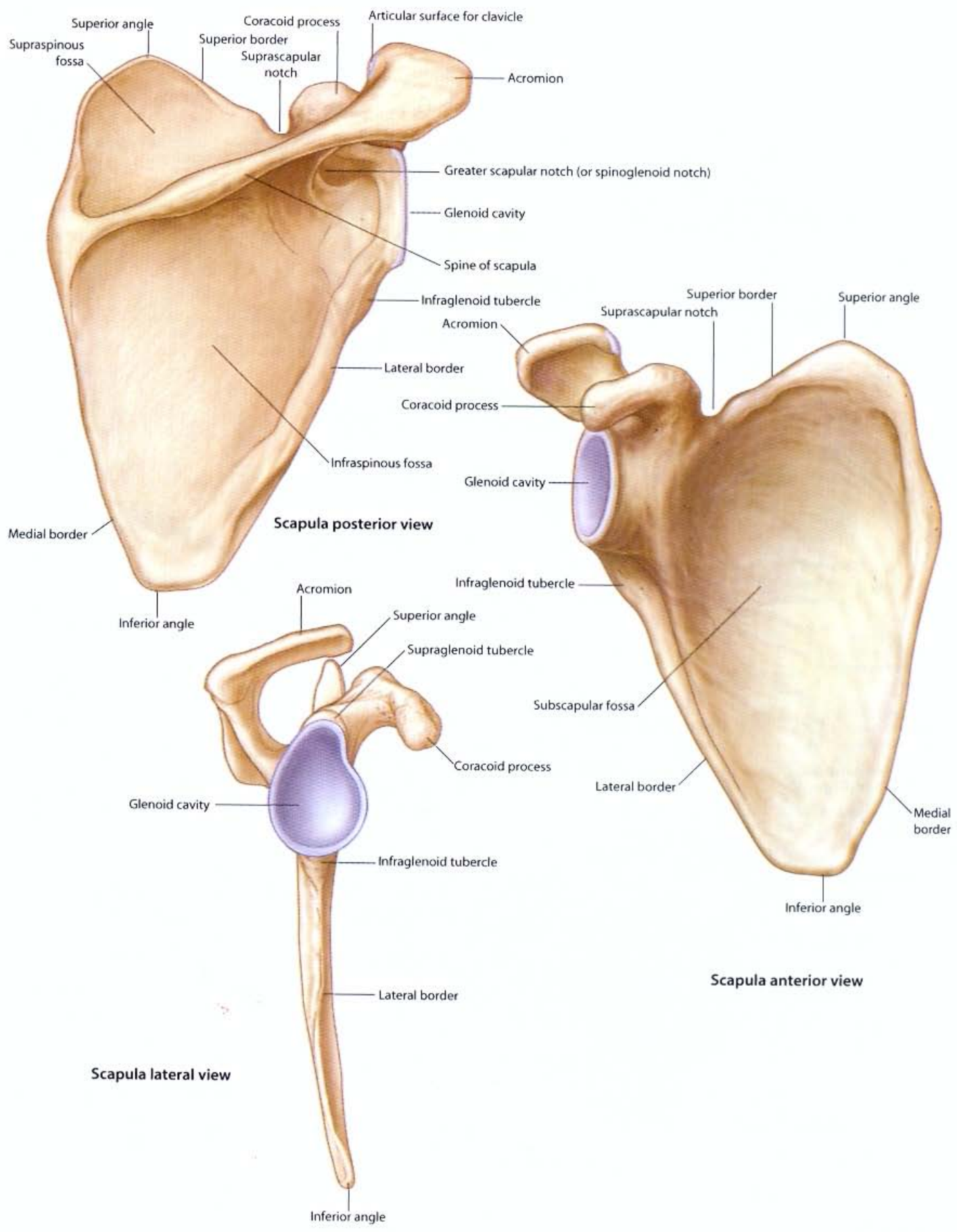
<i>Surface anatomy</i>	350	<i>Bones of the hand and wrist joint</i>	392
<i>Bones of the upper limb</i>	351	<i>Imaging of the hand and wrist joint</i>	393
<i>Bony framework of shoulder</i>	352	<i>Bones of the hand</i>	394
<i>Scapula</i>	353	<i>Joints and ligaments of the hand</i>	395
<i>Clavicle: joints and ligaments</i>	354	<i>Muscle attachments of forearm</i>	396
<i>Proximal humerus</i>	355	<i>Anterior compartment of forearm: muscles</i>	397
<i>Glenohumeral joint</i>	356	<i>Anterior compartment of forearm: arteries and nerves</i>	400
<i>Muscle attachments</i>	358	<i>Posterior compartment of forearm: muscles</i>	401
<i>Pectoral region</i>	360	<i>Posterior compartment of forearm: arteries and nerves</i>	403
<i>Deep pectoral region</i>	361	<i>Transverse sections: forearm</i>	404
<i>Walls of the axilla</i>	362	<i>Carpal tunnel</i>	406
<i>The four rotator cuff muscles</i>	364	<i>Muscle attachments of the hand</i>	408
<i>Deep vessels and nerves of the shoulder</i>	366	<i>Superficial palmar region (palm) of hand</i>	409
<i>Axillary artery</i>	367	<i>Tendon sheaths of hand</i>	410
<i>Brachial artery</i>	368	<i>Lumbrical muscles</i>	411
<i>Brachial plexus</i>	369	<i>Intrinsic muscles of hand</i>	412
<i>Medial and lateral cords</i>	370	<i>Palmar region (palm) of hand: arteries and nerves</i>	414
<i>Posterior cord</i>	371	<i>Arteries of the hand</i>	416
<i>Distal end of humerus and proximal end of radius and ulna</i>	372	<i>Innervation of the hand: median and ulnar nerves</i>	417
<i>Muscle attachments</i>	373	<i>Dorsum of hand</i>	418
<i>Anterior compartment: muscles</i>	374	<i>Dorsal hoods</i>	419
<i>Anterior compartment: arteries and nerves</i>	376	<i>Dorsum of hand: arteries</i>	420
<i>Veins of the arm</i>	377	<i>Dorsum of hand: nerves</i>	421
<i>Posterior compartment: muscles</i>	378	<i>Anatomical snuffbox</i>	422
<i>Posterior compartment: arteries and nerves</i>	380	<i>Superficial veins and lymphatics of forearm</i>	423
<i>Lymphatics of the arm</i>	381	<i>Anterior cutaneous nerves of forearm</i>	424
<i>Transverse sections: arm</i>	382	<i>Posterior cutaneous nerves of upper limb</i>	425
<i>Anterior cutaneous nerves of the arm</i>	384		
<i>Posterior cutaneous nerves of the arm</i>	385		
<i>Elbow joint</i>	386		
<i>Elbow joint: capsule and ligaments</i>	388		
<i>Cubital fossa</i>	390		
<i>Radius and ulna</i>	391		

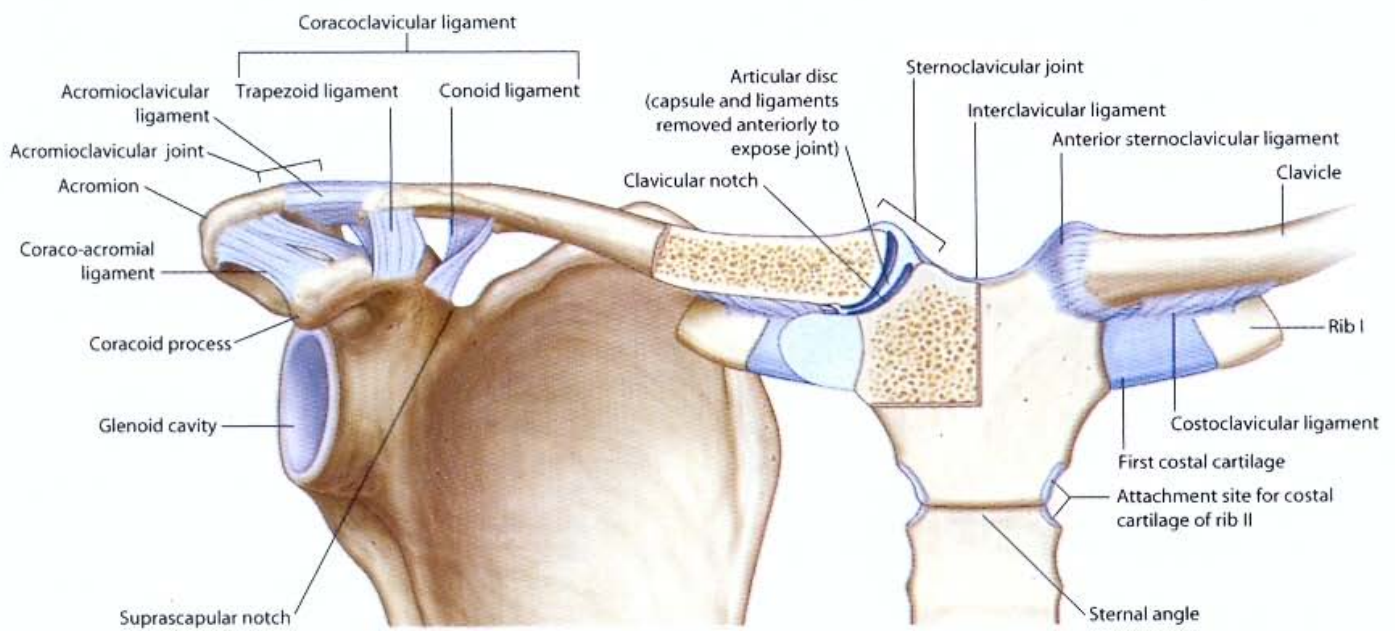
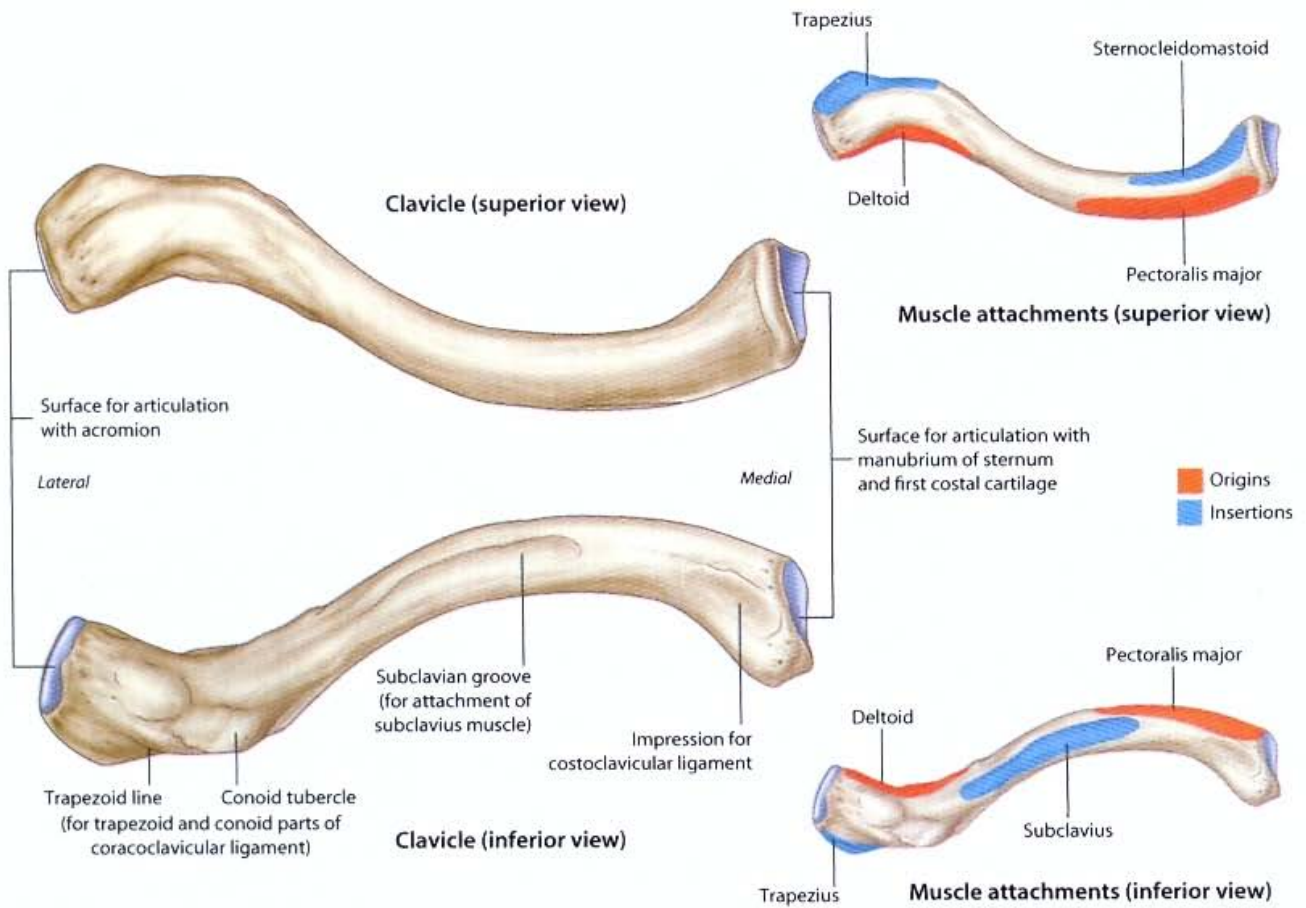


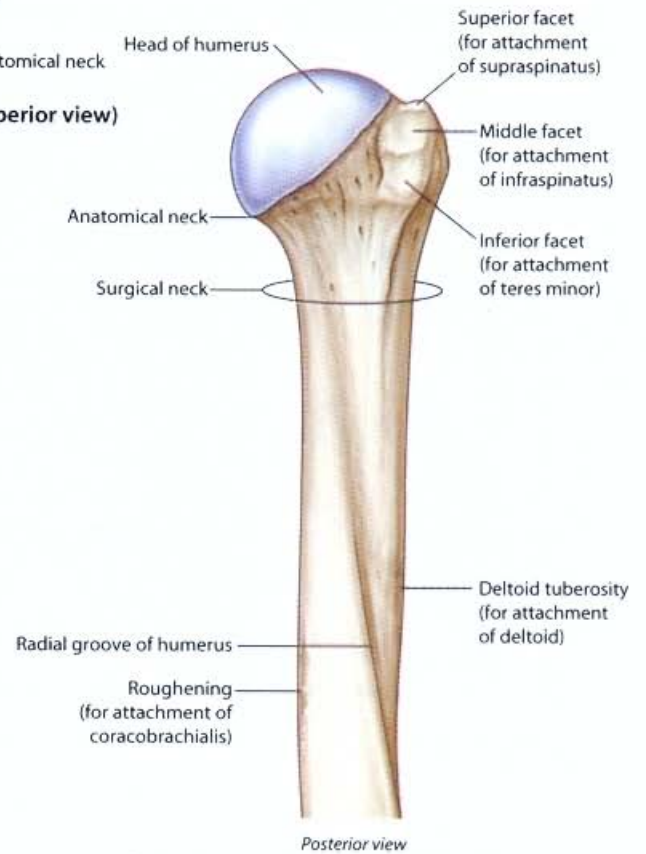
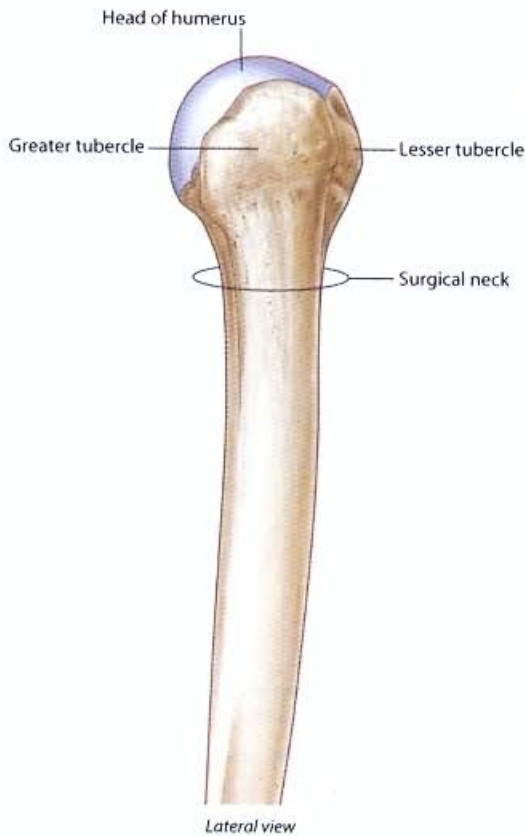
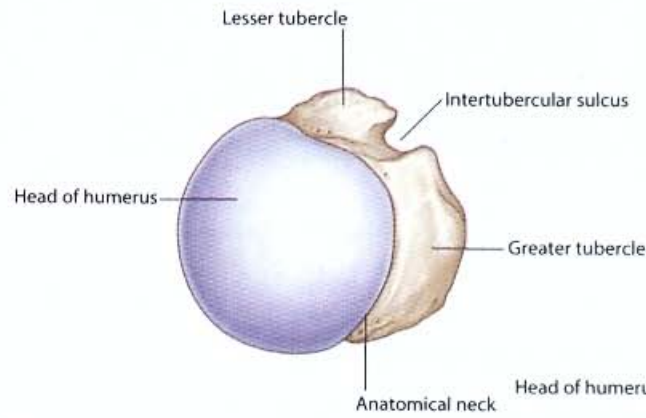
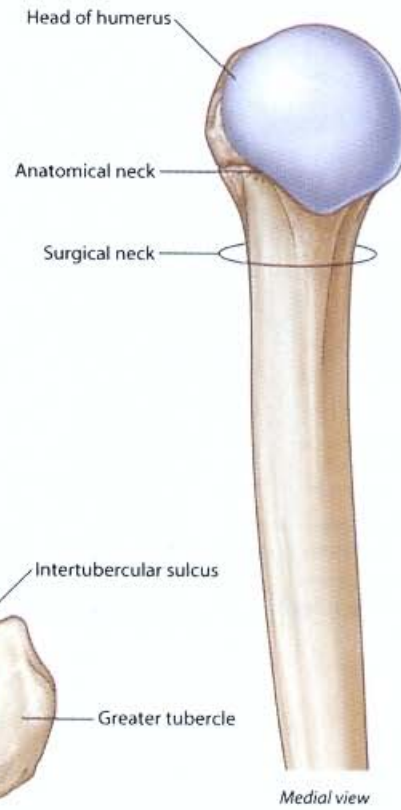
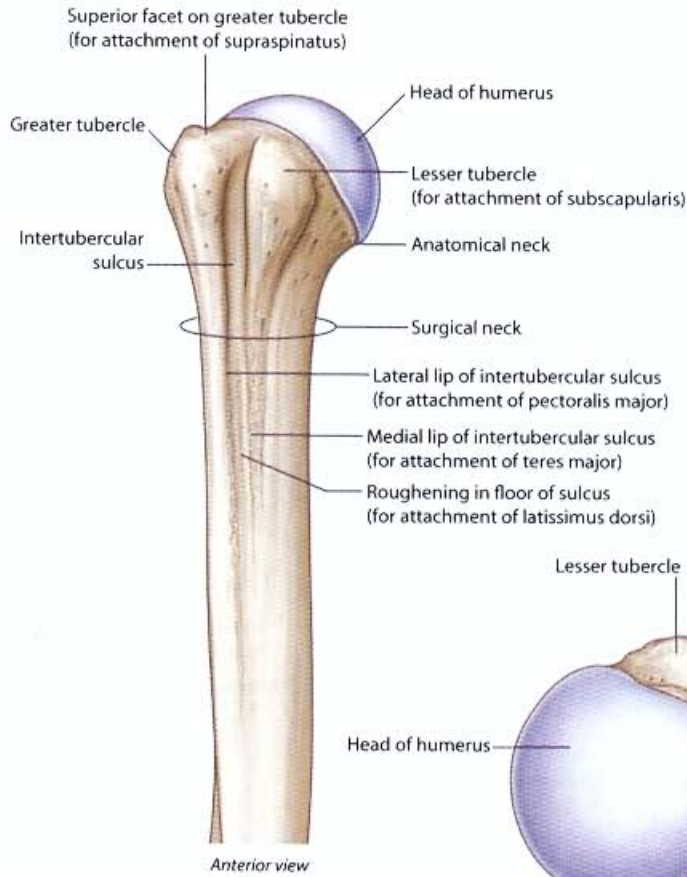




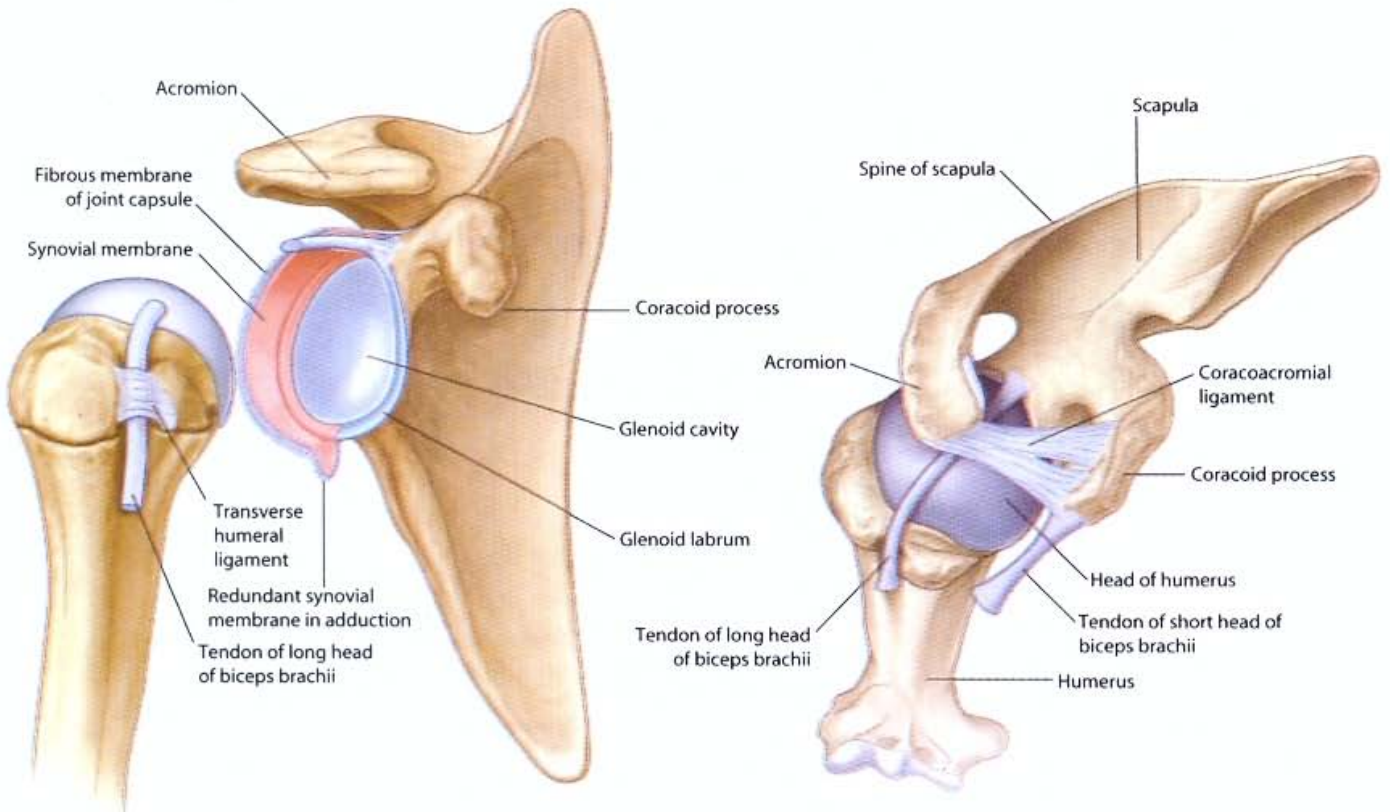






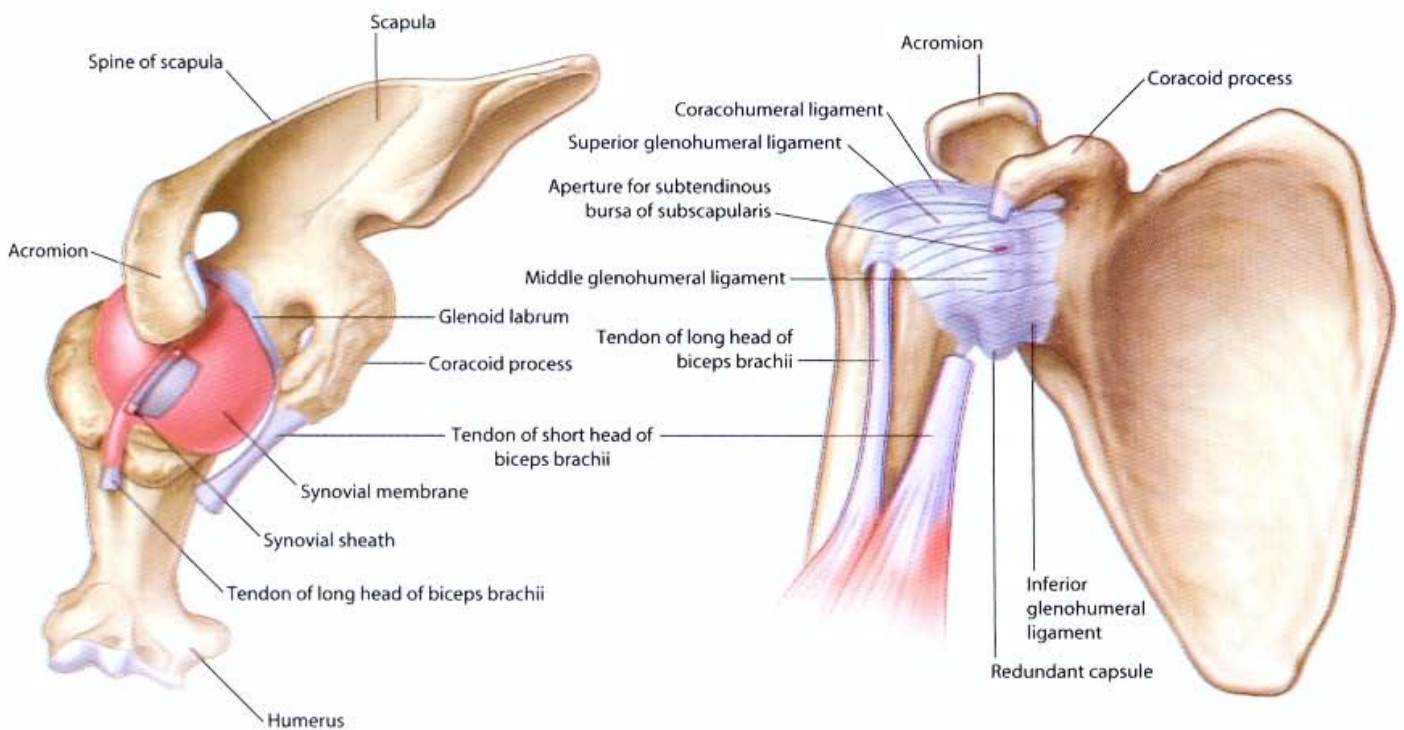


Proximal end of humerus



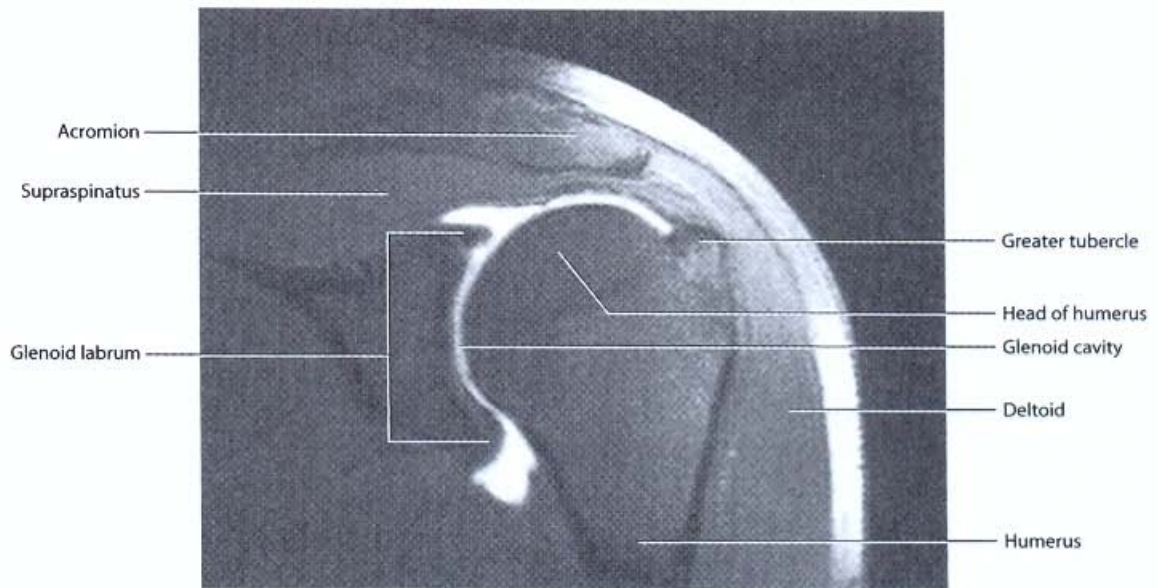
**Origins of biceps brachii tendons (superior view)**

**Articular surfaces of glenohumeral joint (anterolateral oblique view)**

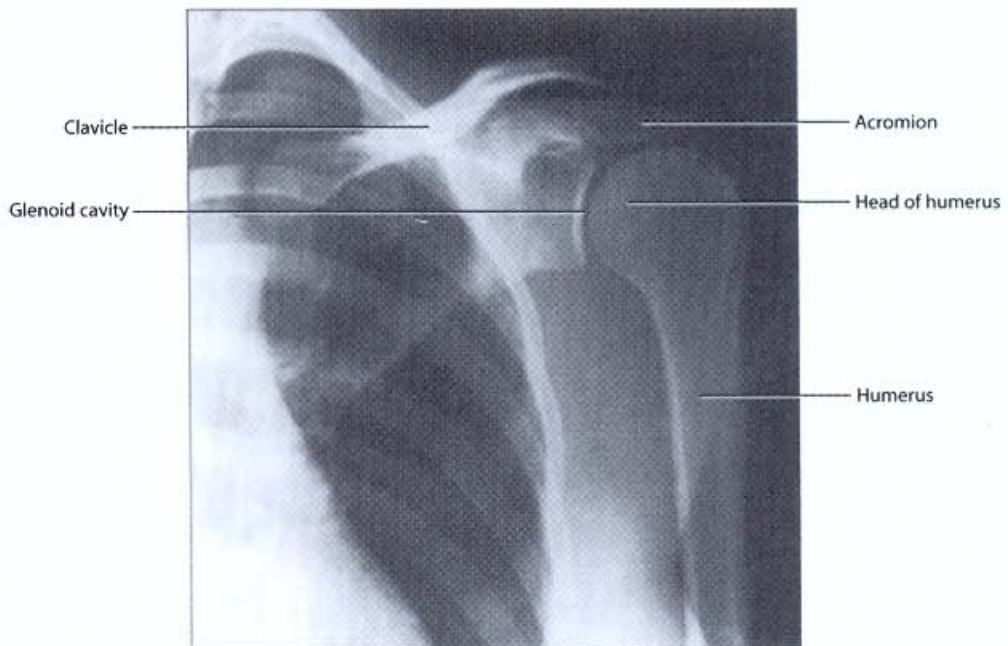

**Synovial membrane (superior view)**

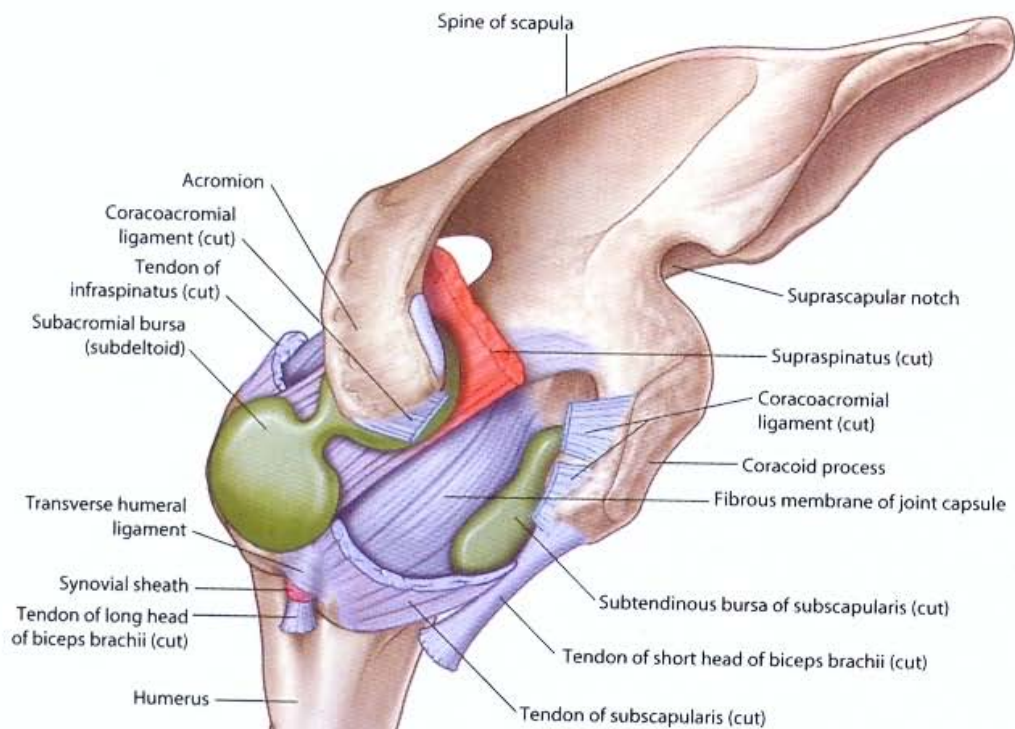
**Fibrous membrane of joint capsule (anterior view)**



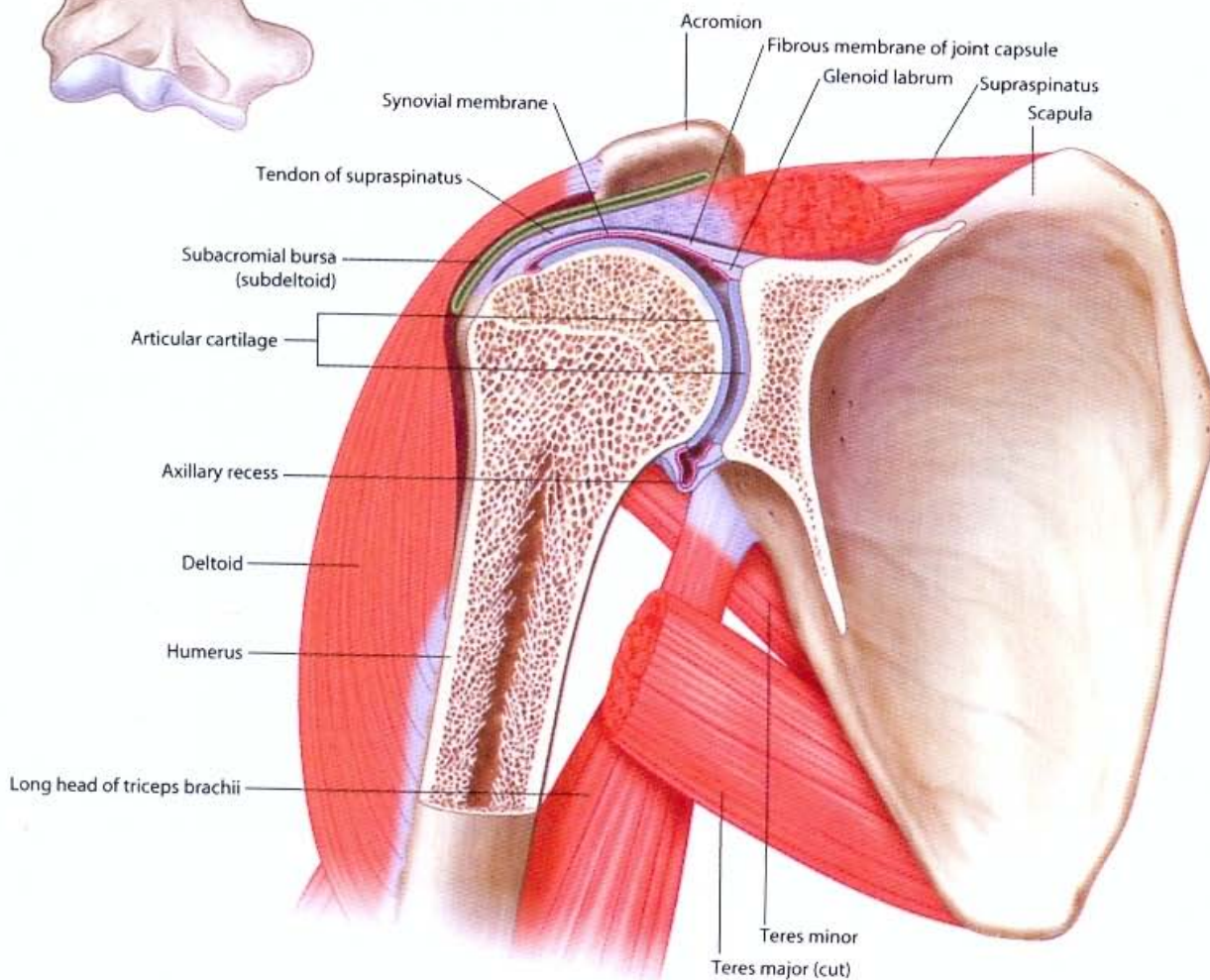
**Anterior view of the glenohumeral joint.**  
T1-weighted MR image in coronal plane



**Normal glenohumeral joint.**  
Radiograph, AP view



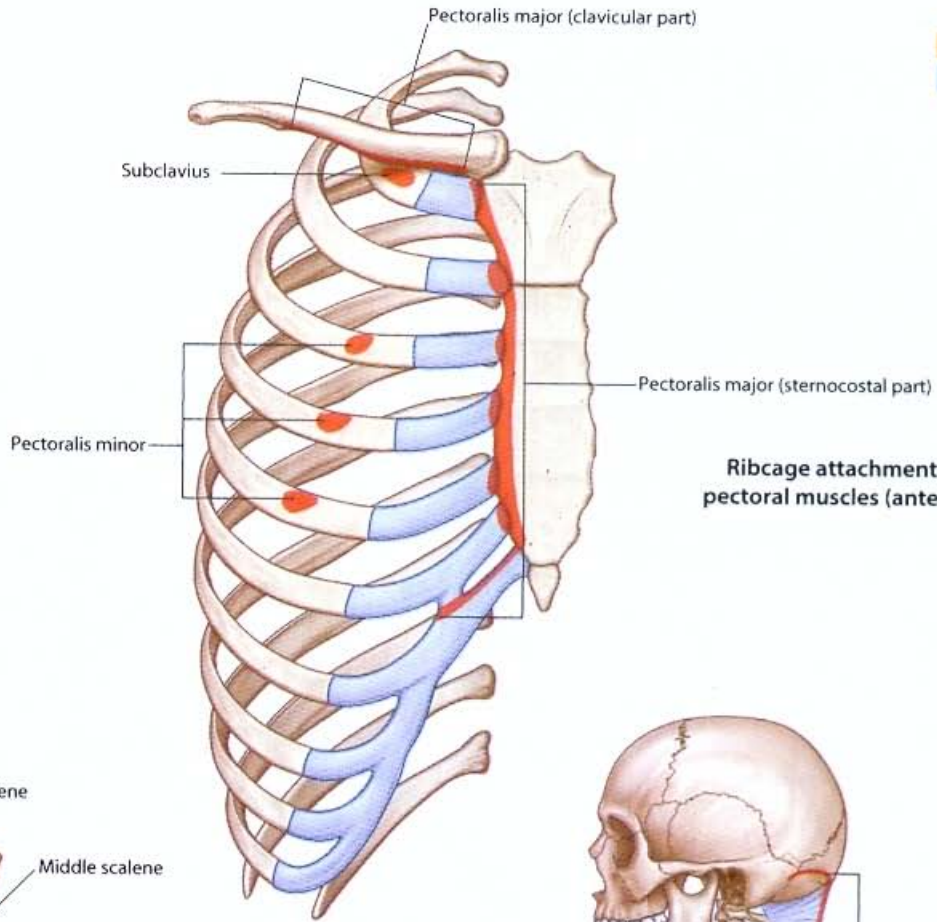
**Bursae of the glenohumeral joint (superior view)**



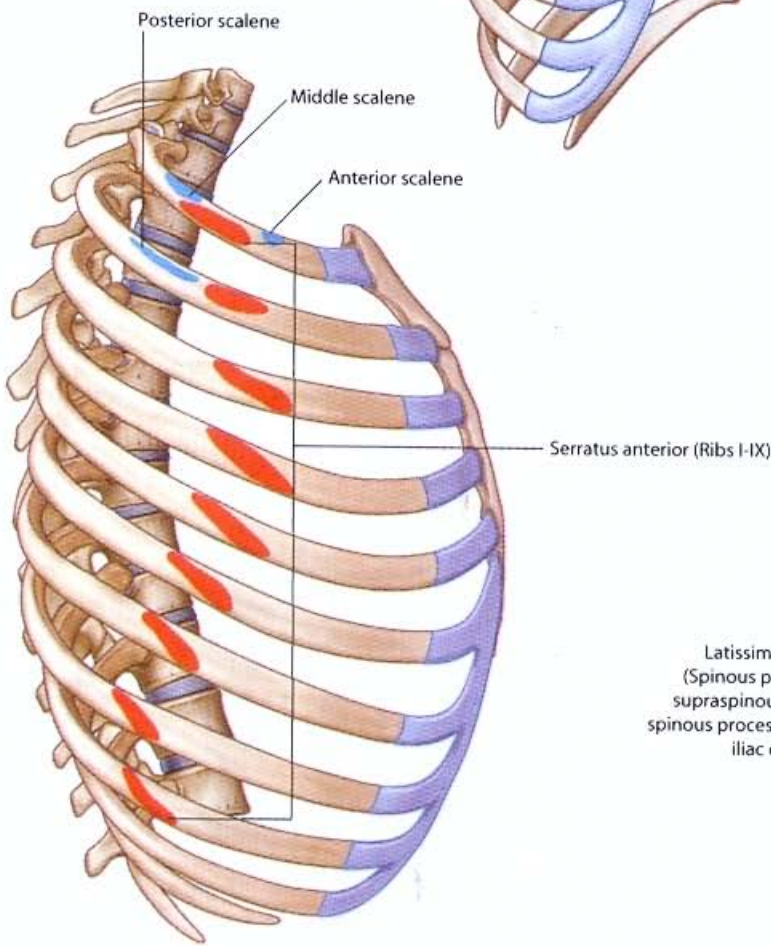
**Glenohumeral joint (anterior view)**



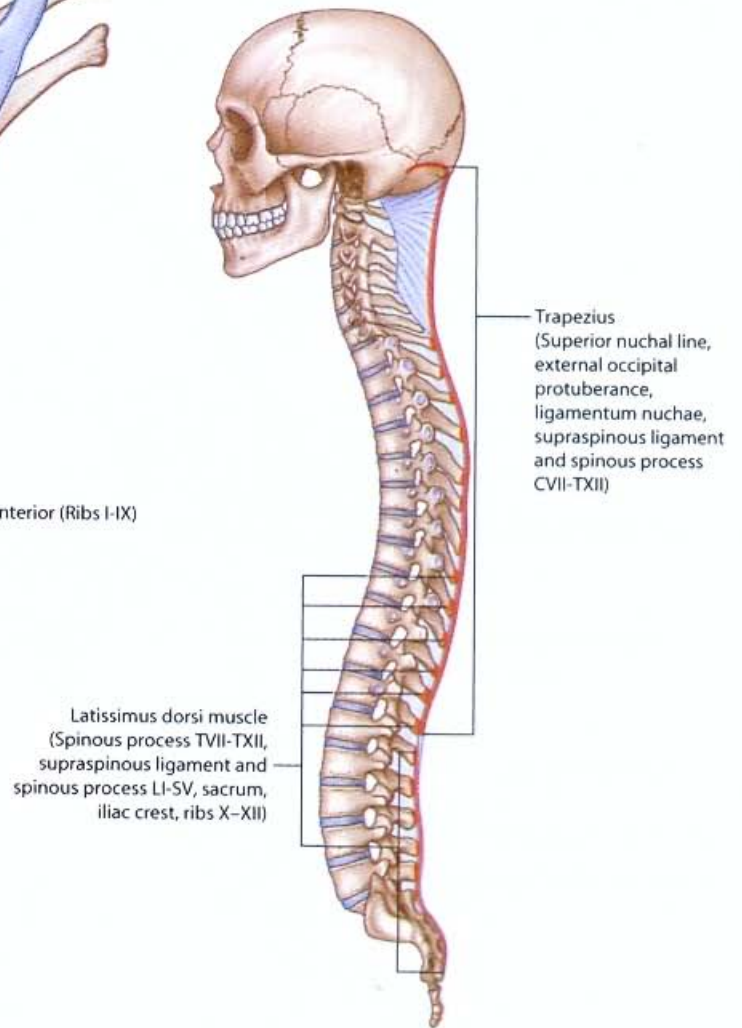
■ Origins  
■ Insertions



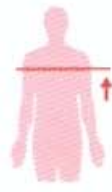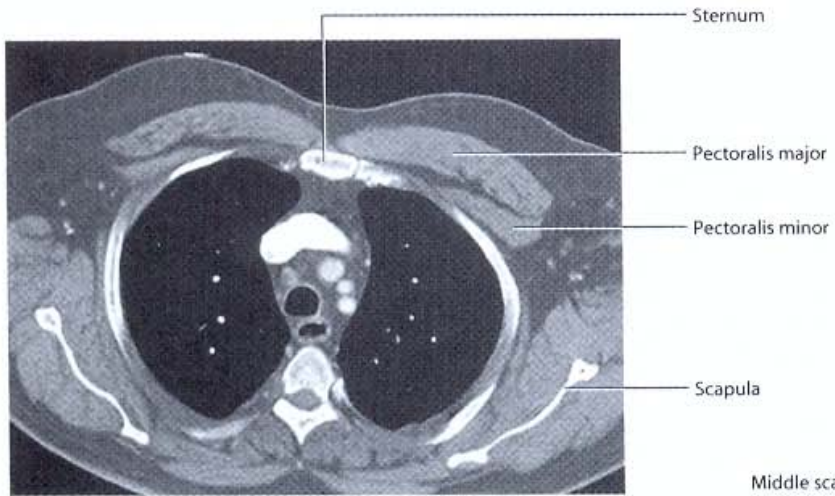
**Ribcage attachments of the pectoral muscles (anterior view)**



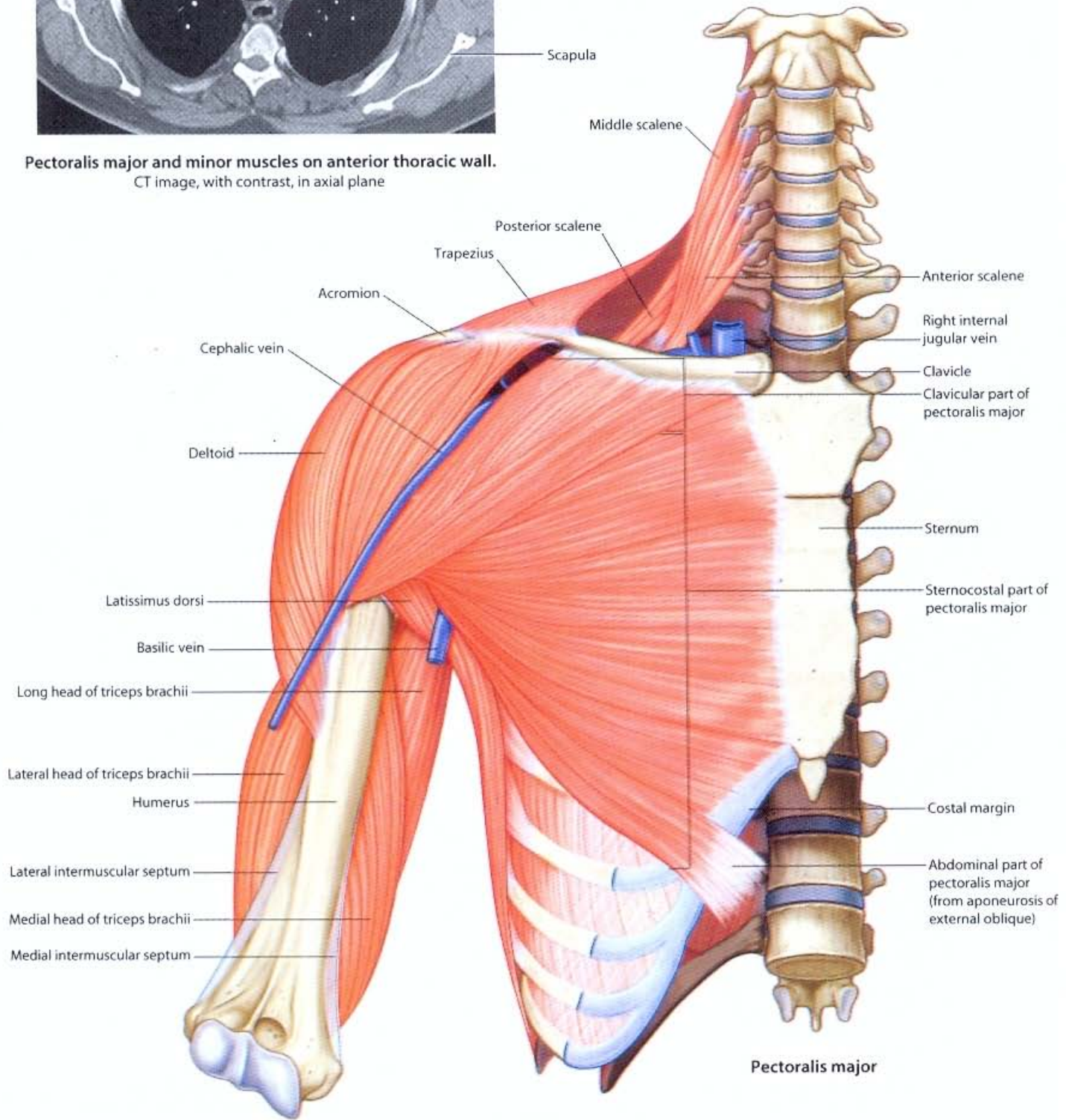
**Ribcage attachments of serratus anterior and scalene muscles (lateral view)**

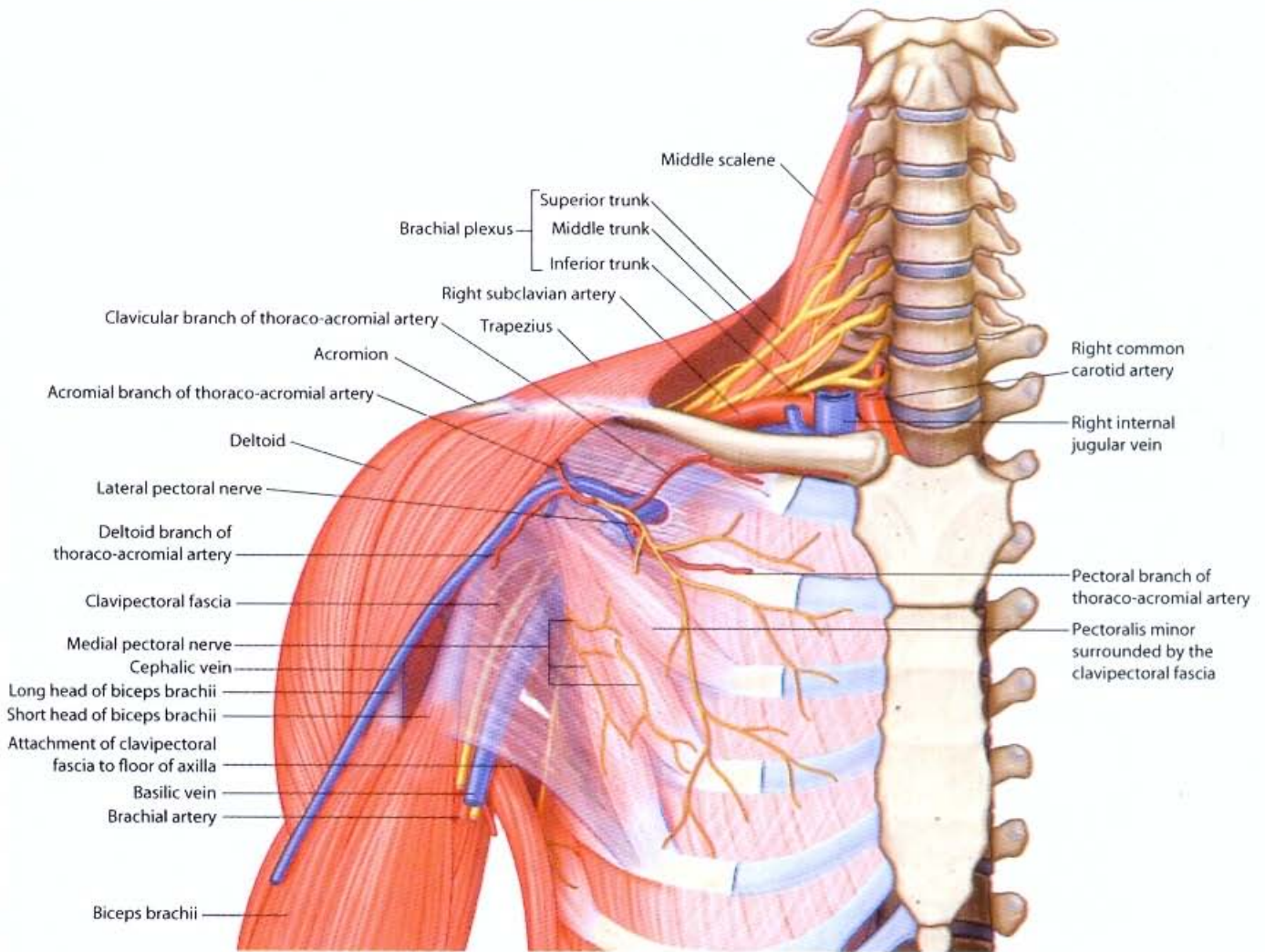


**Attachments of trapezius and latissimus dorsi muscles (lateral view)**

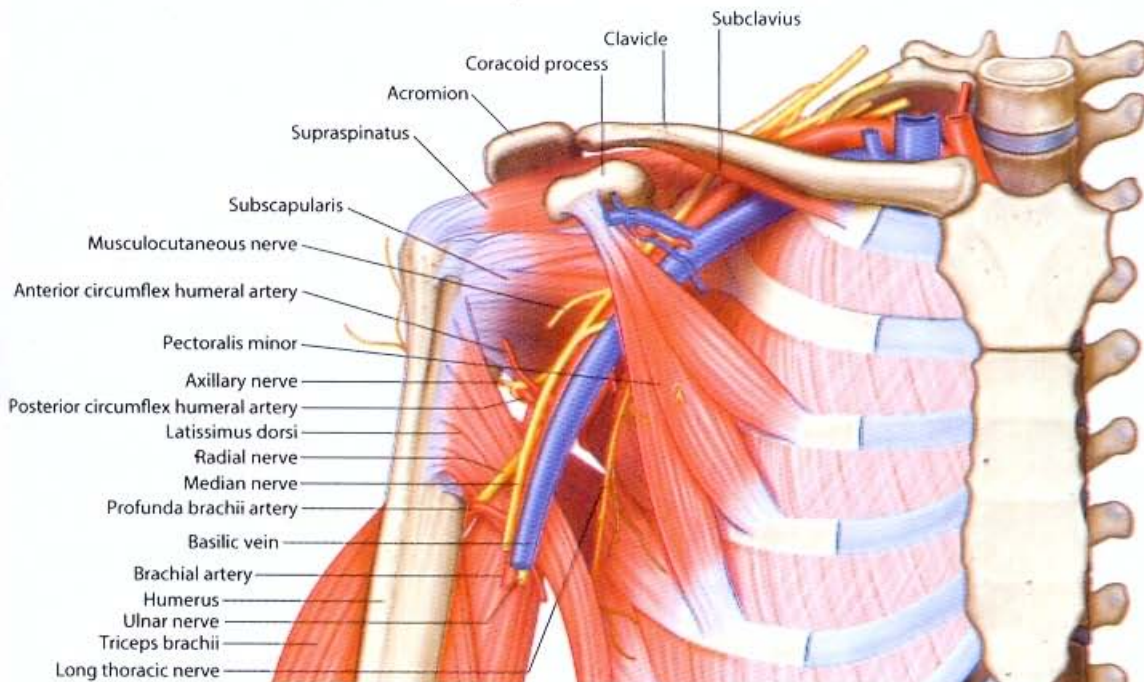


**Pectoralis major and minor muscles on anterior thoracic wall.**  
CT image, with contrast, in axial plane

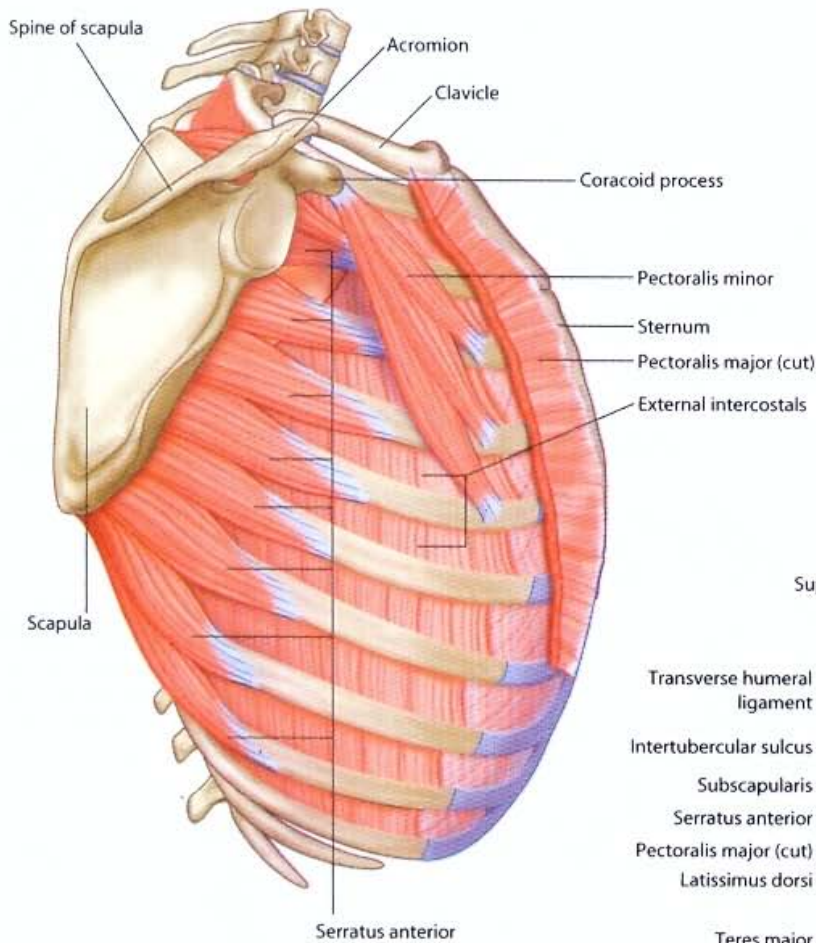




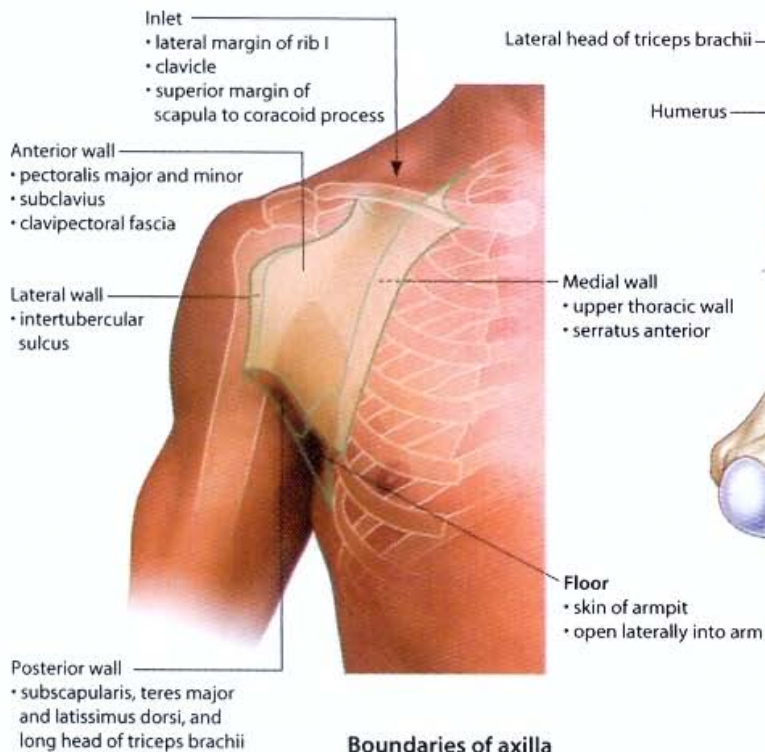
Clavipectoral fascia and related structures



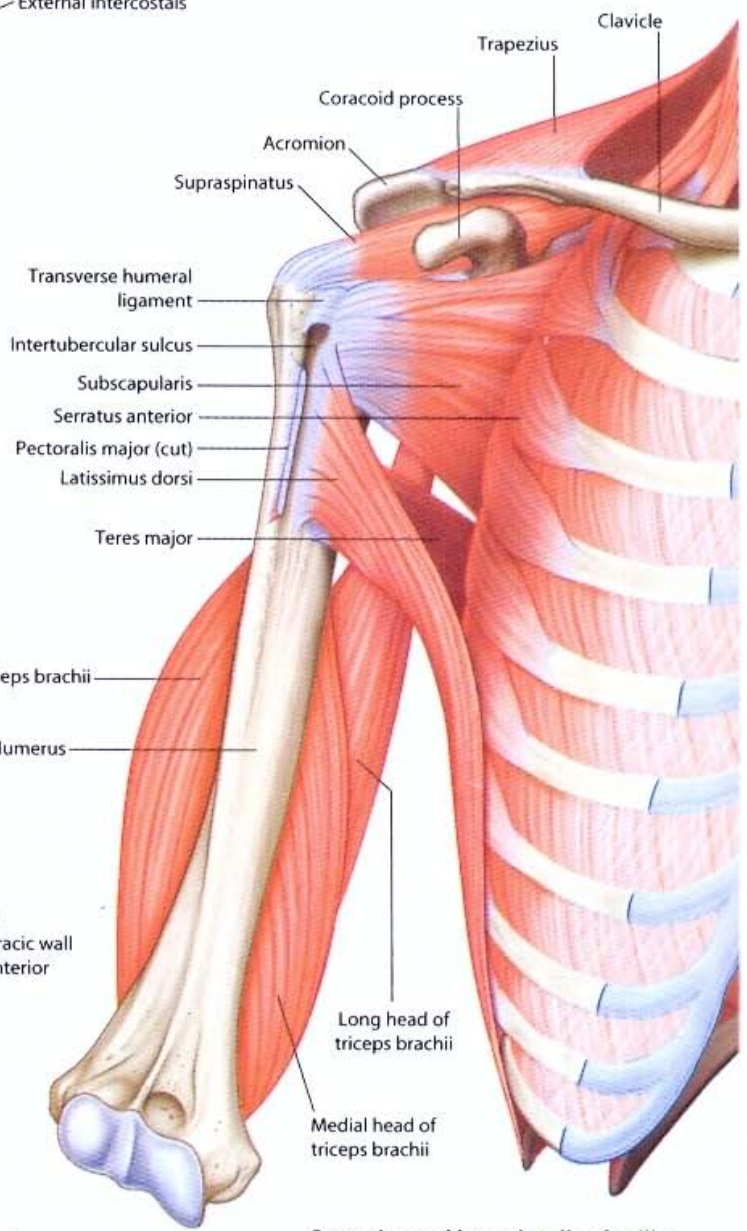
Pectoralis minor



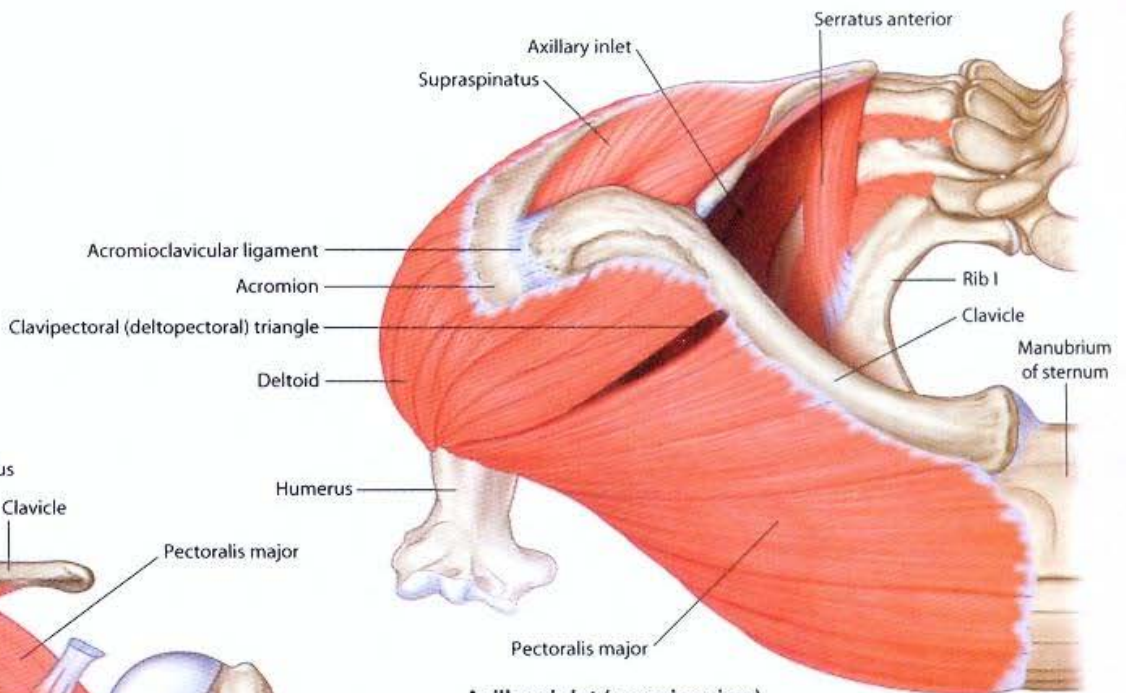
**Medial and anterior walls of axilla**



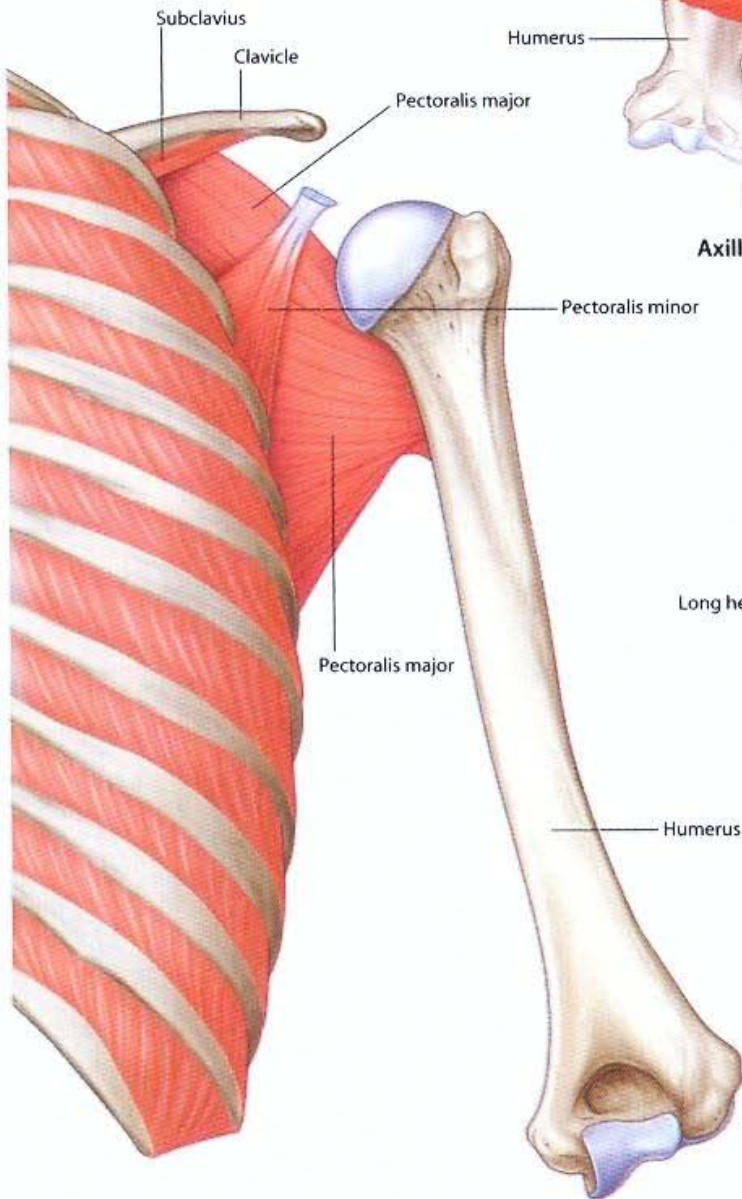
**Boundaries of axilla**



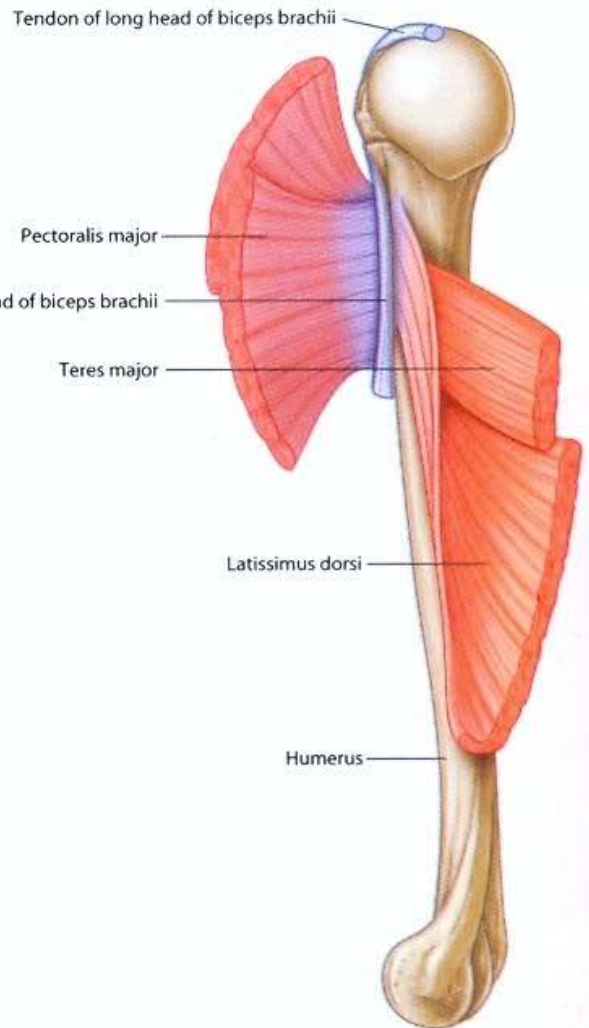
**Posterior and lateral walls of axilla**



Axillary inlet (superior view)

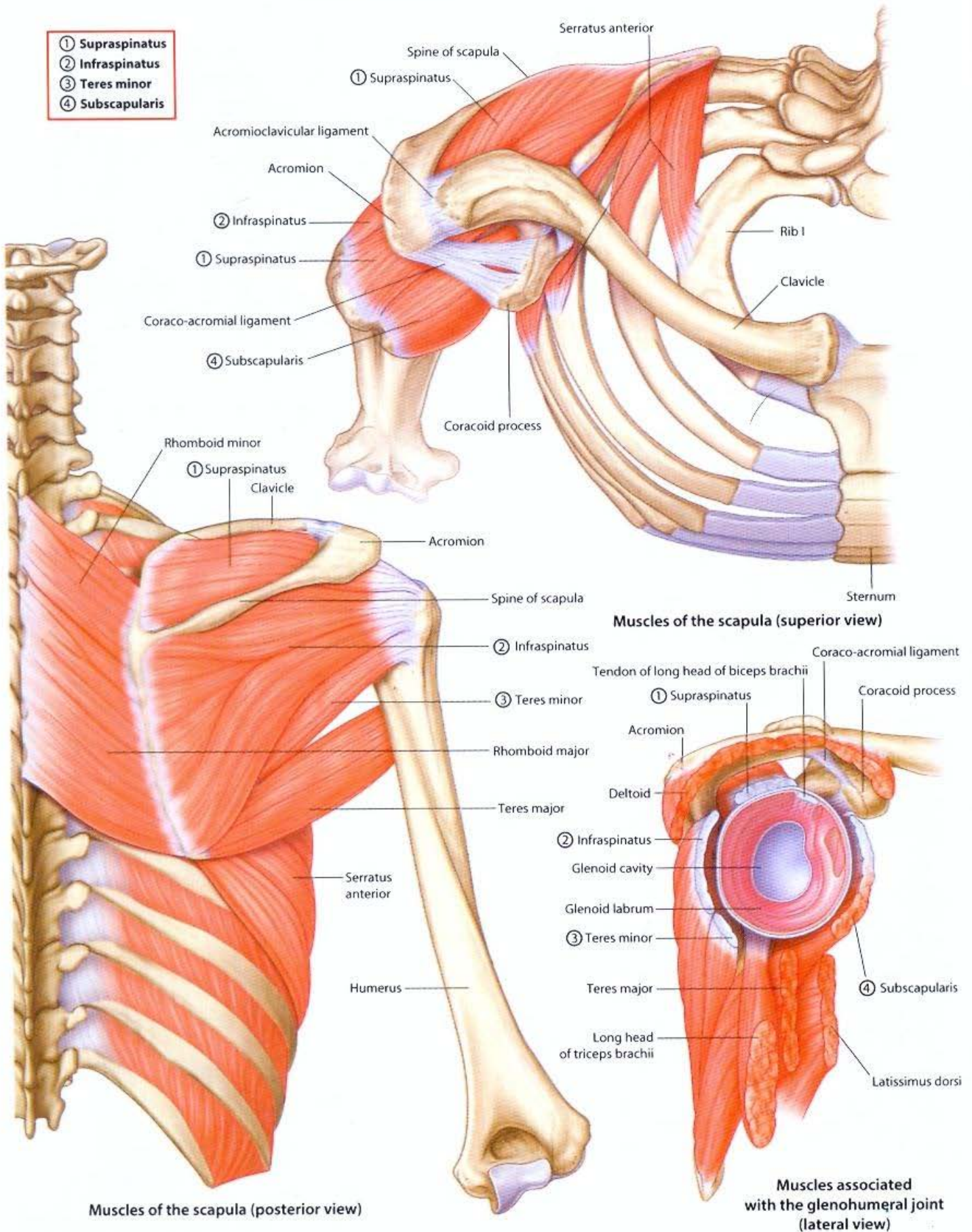


Anterior wall of axilla (posterior view)



Lateral wall of axilla (medial view)

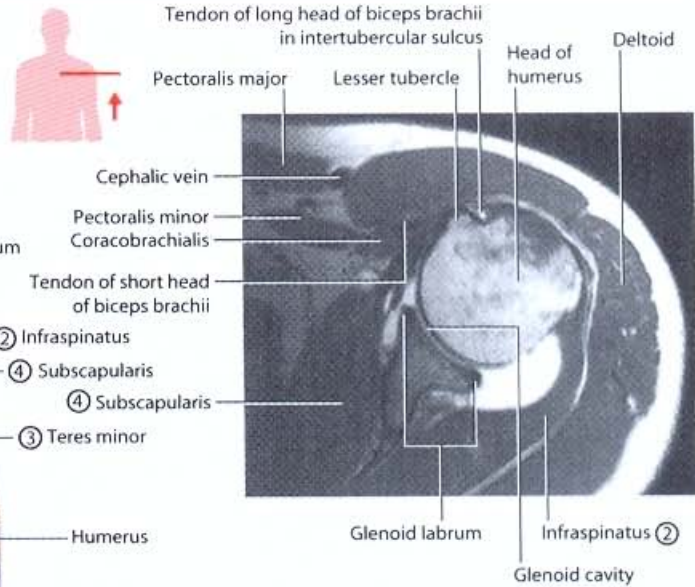
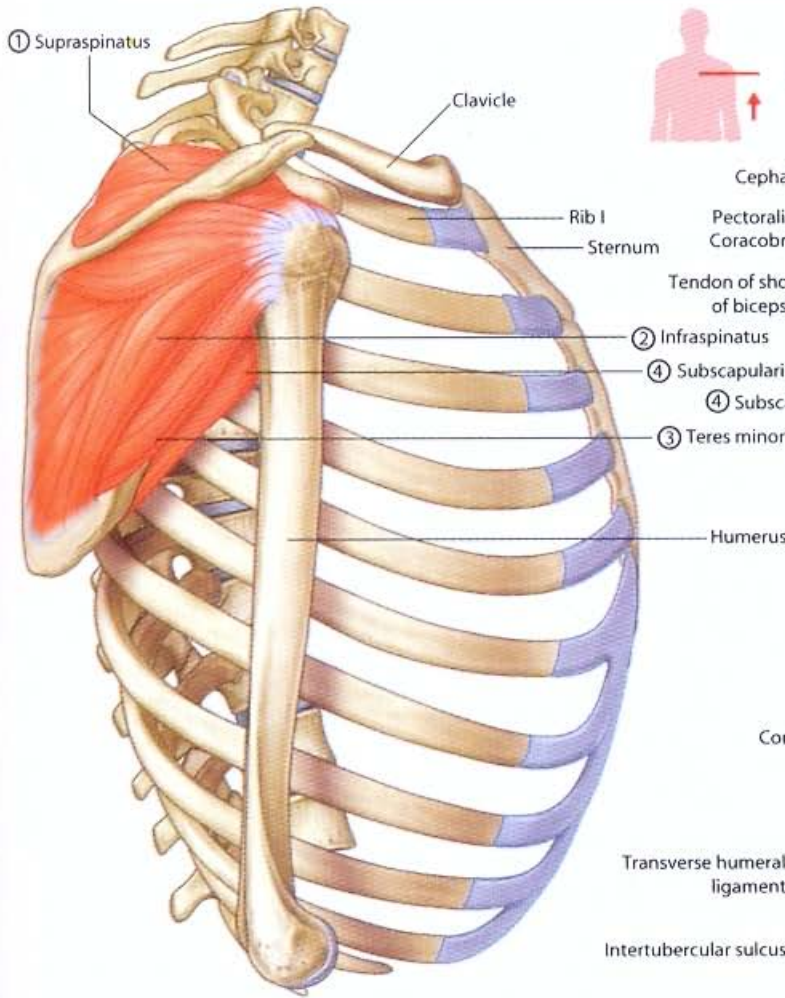
- ① Supraspinatus
- ② Infraspinatus
- ③ Teres minor
- ④ Subscapularis



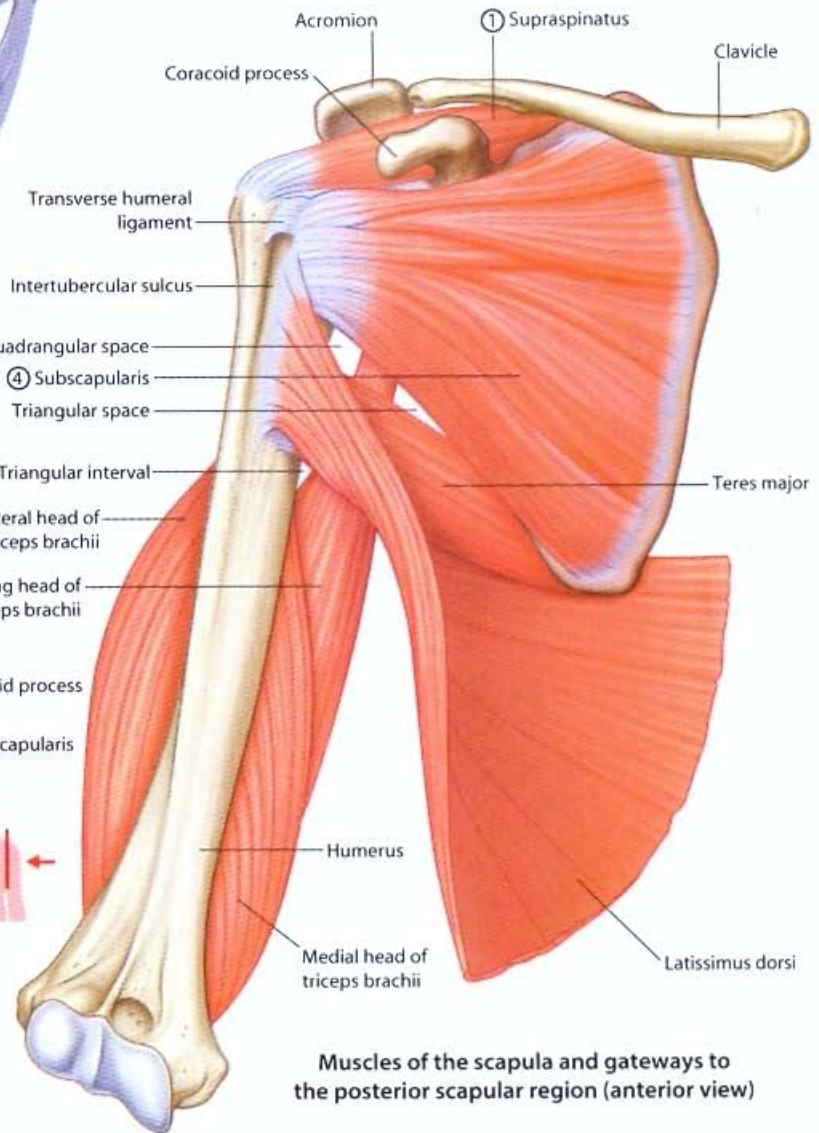
Muscles of the scapula (posterior view)

Muscles of the scapula (superior view)

Muscles associated with the glenohumeral joint (lateral view)

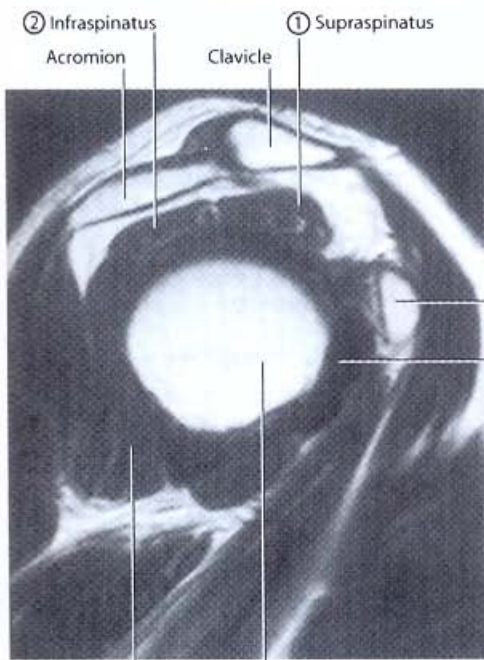


Muscles associated with the glenohumeral joint. T1-weighted MR image in axial plane

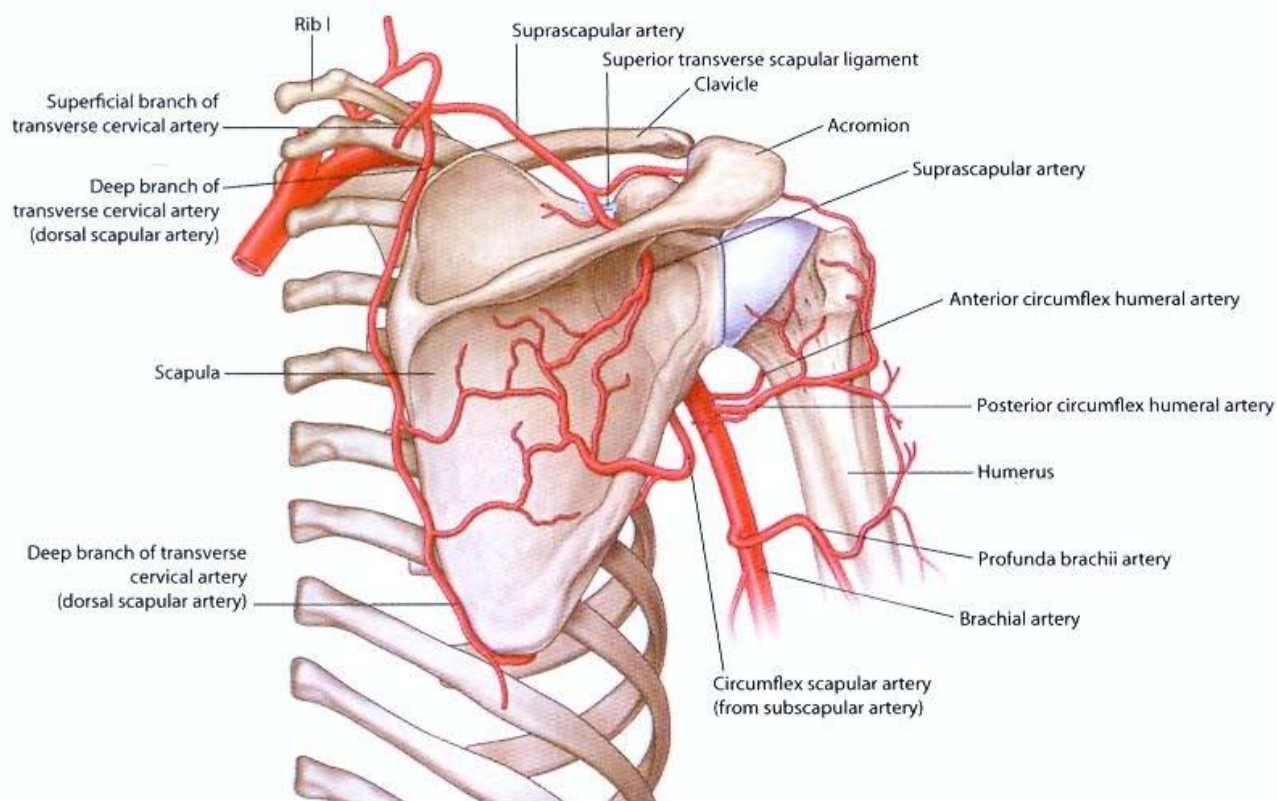


Muscles of the scapula and gateways to the posterior scapular region (anterior view)

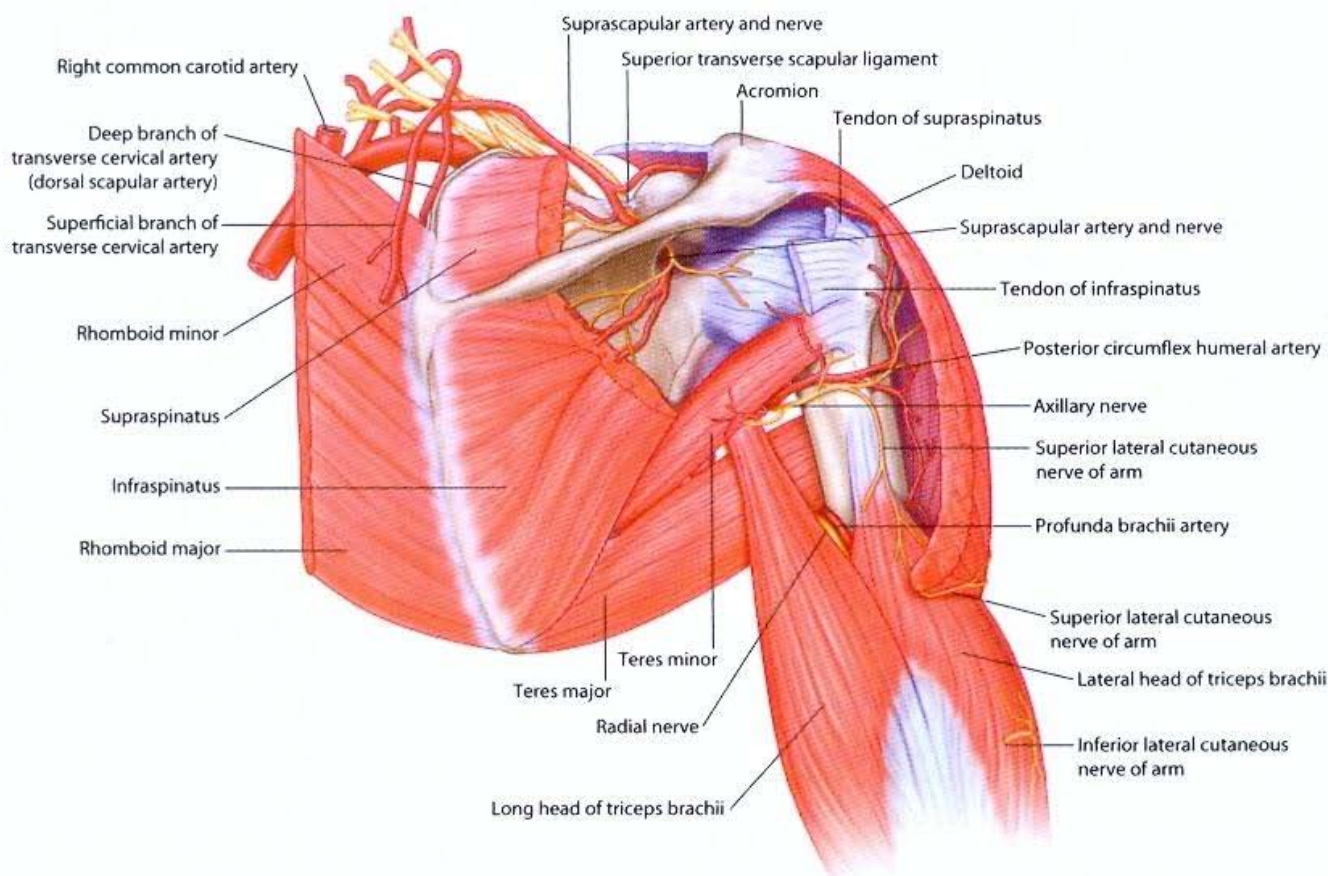
Muscles of the scapula (lateral view)



Muscles associated with the glenohumeral joint. T1-weighted MR image in sagittal plane

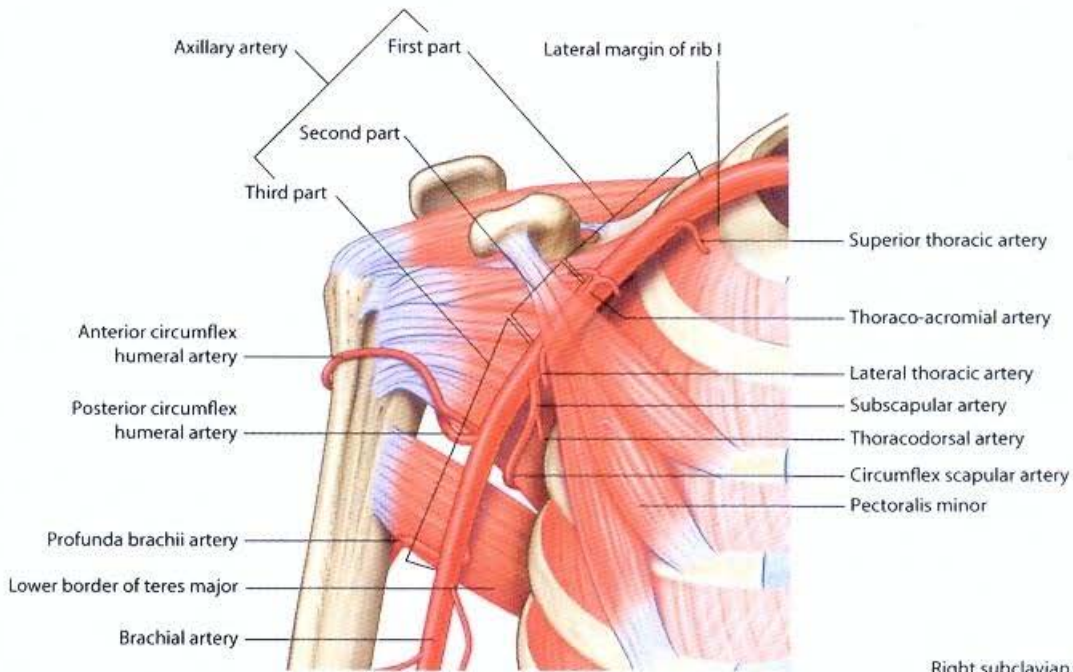


**Arteries of the shoulder (posterior view)**

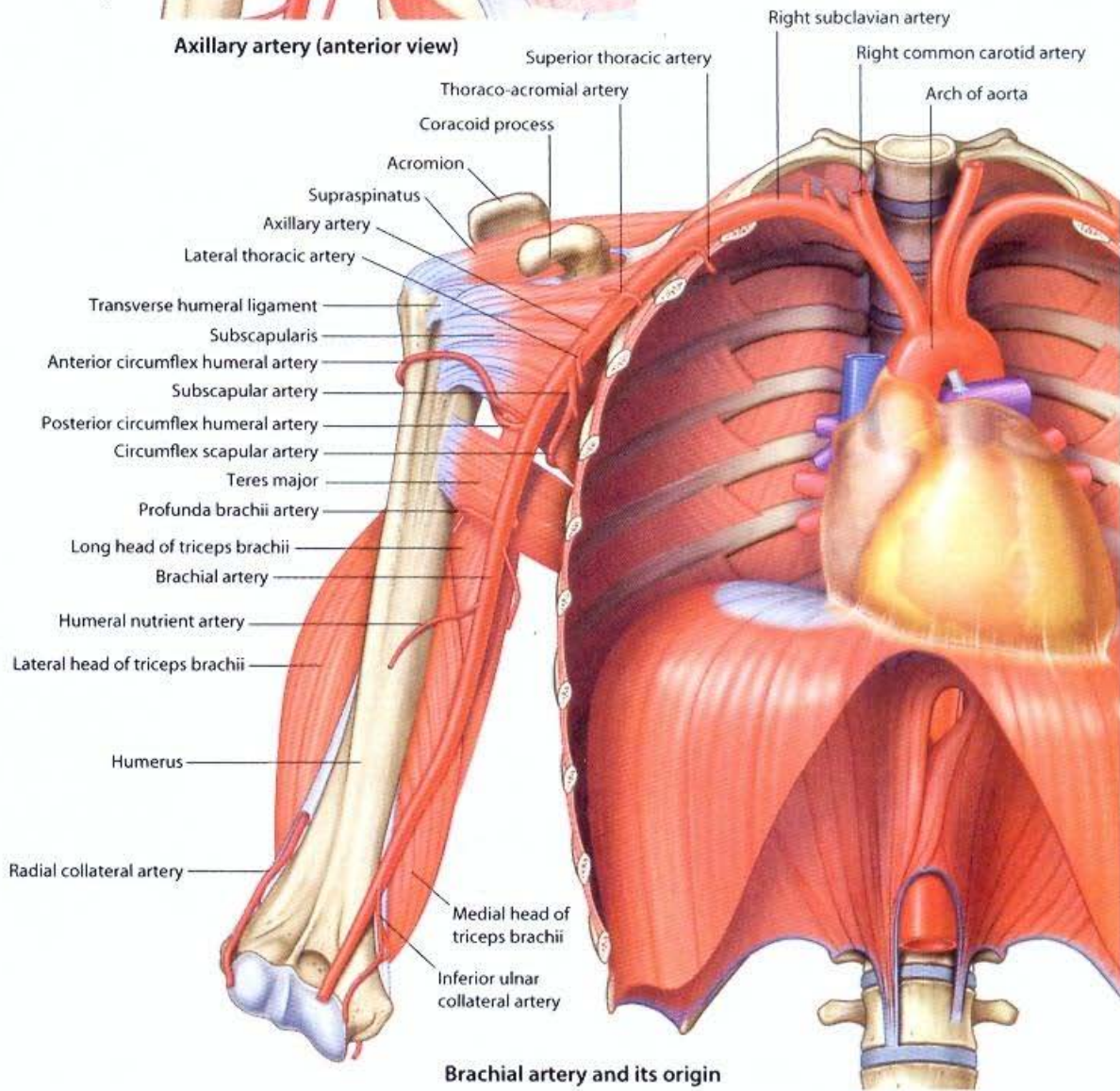


**Deep arteries and nerves of the shoulder (posterior view)**



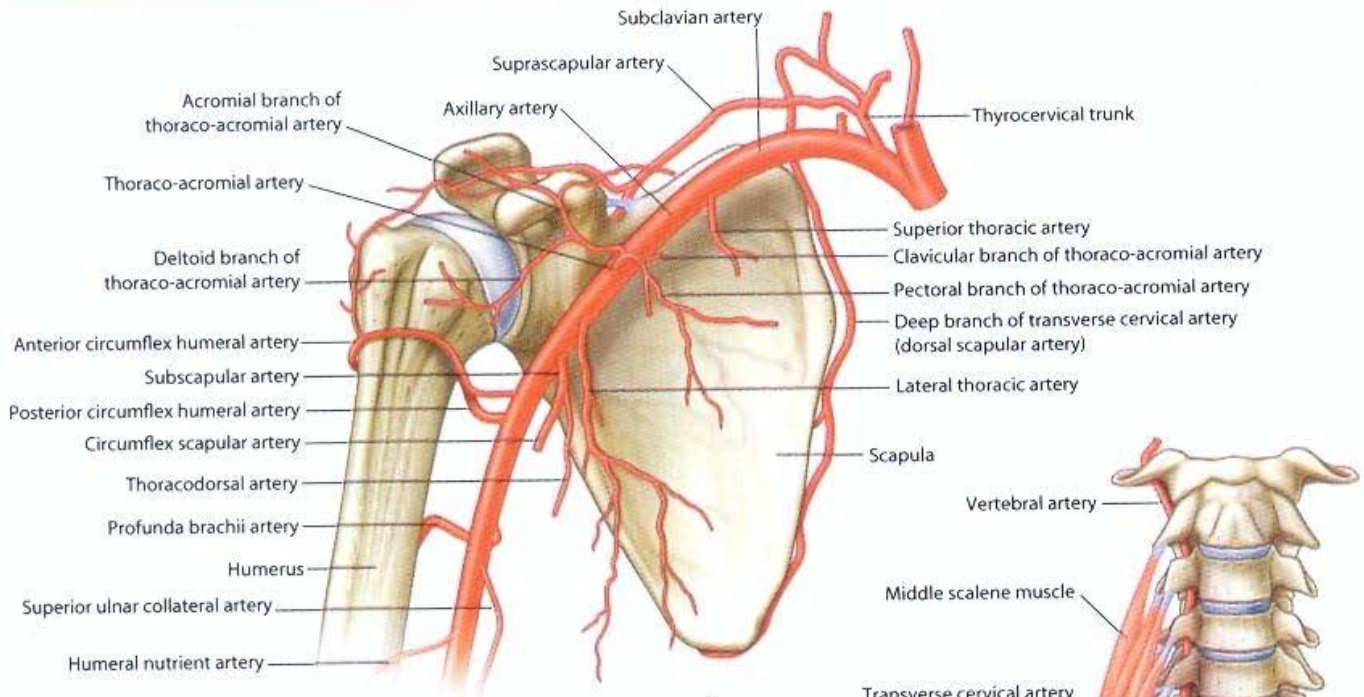


**Axillary artery (anterior view)**

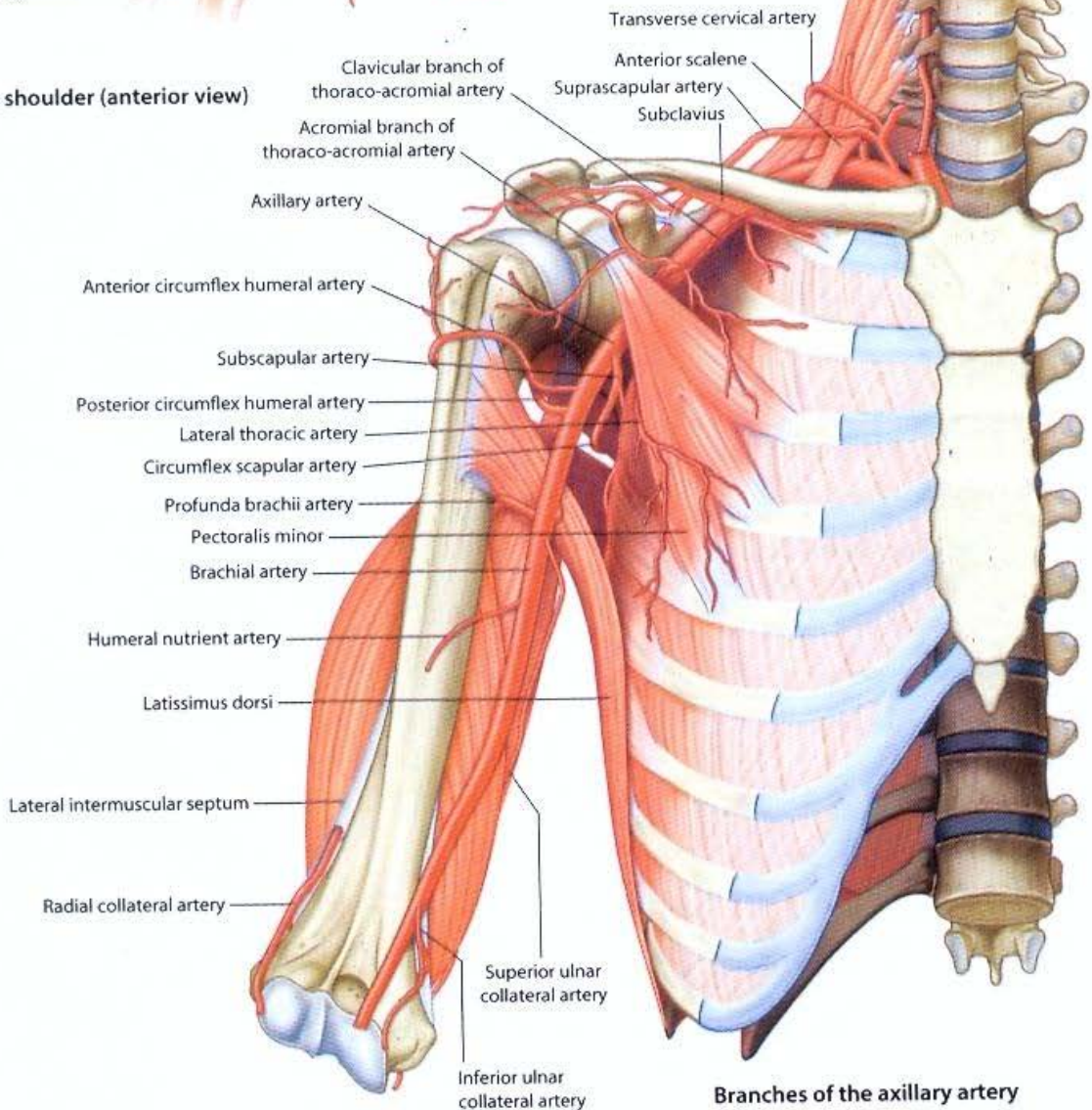


**Brachial artery and its origin**

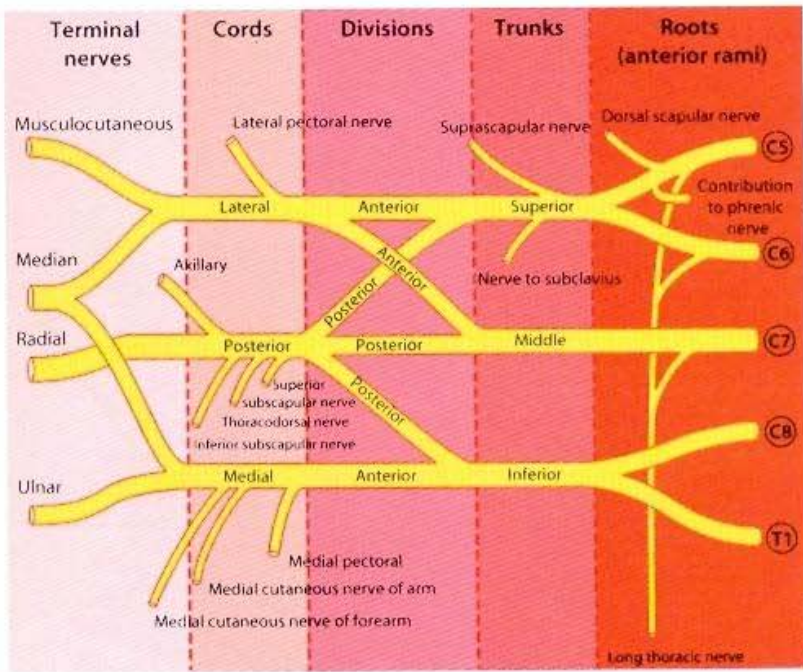
# UPPER LIMB • Brachial artery



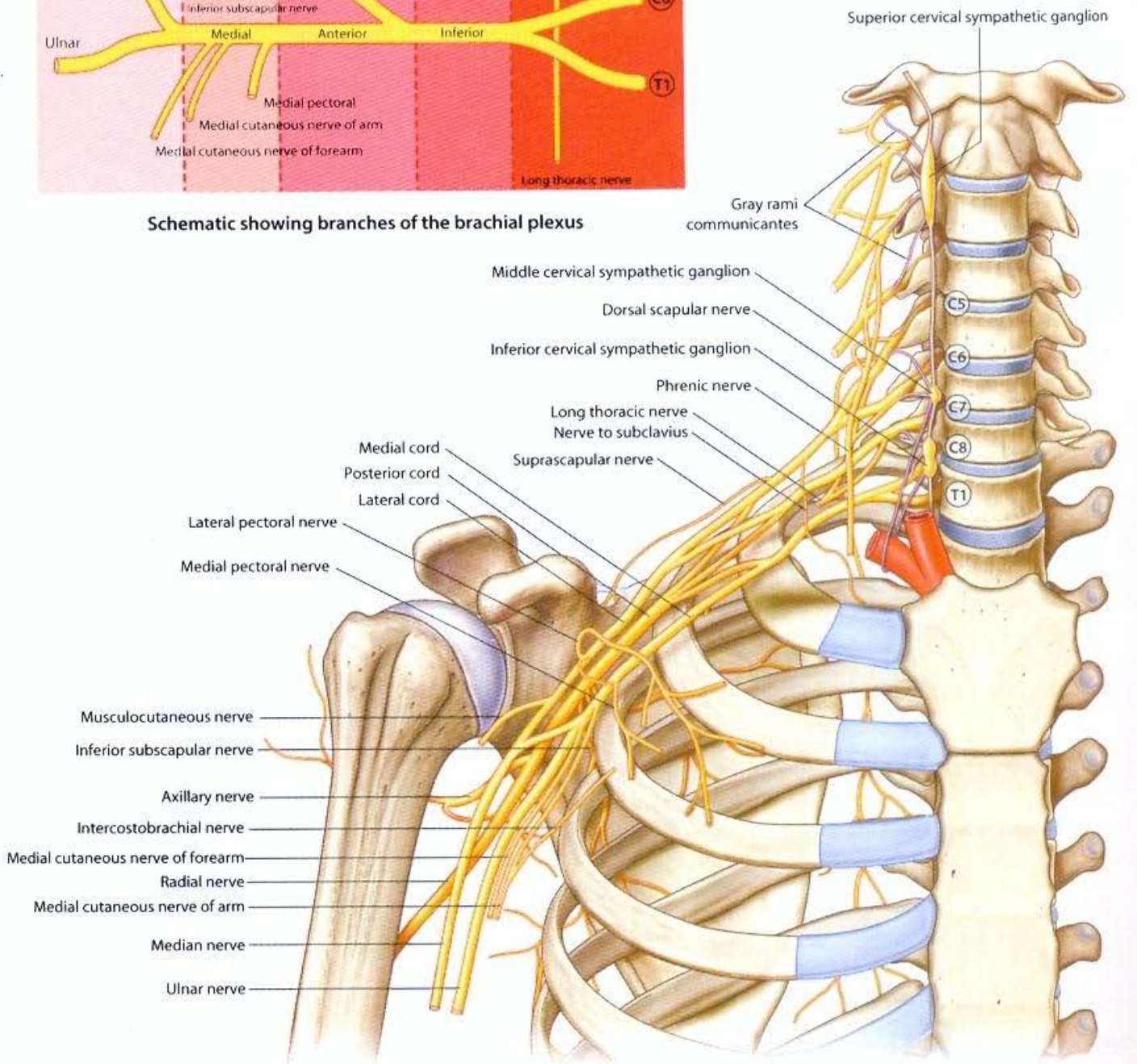
**Arteries of the shoulder (anterior view)**



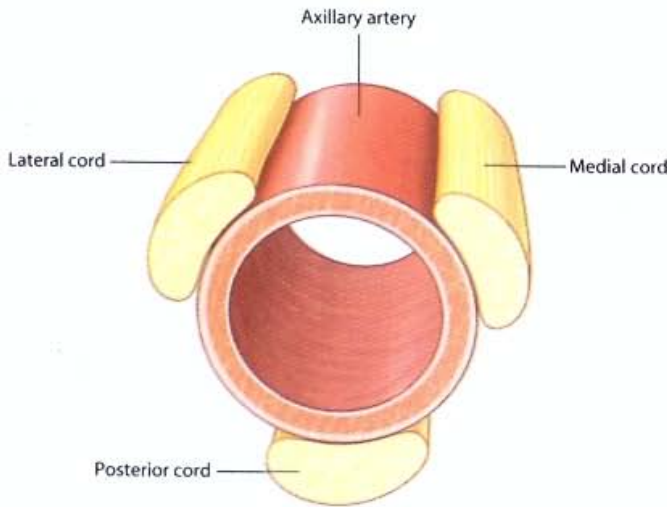
**Branches of the axillary artery**



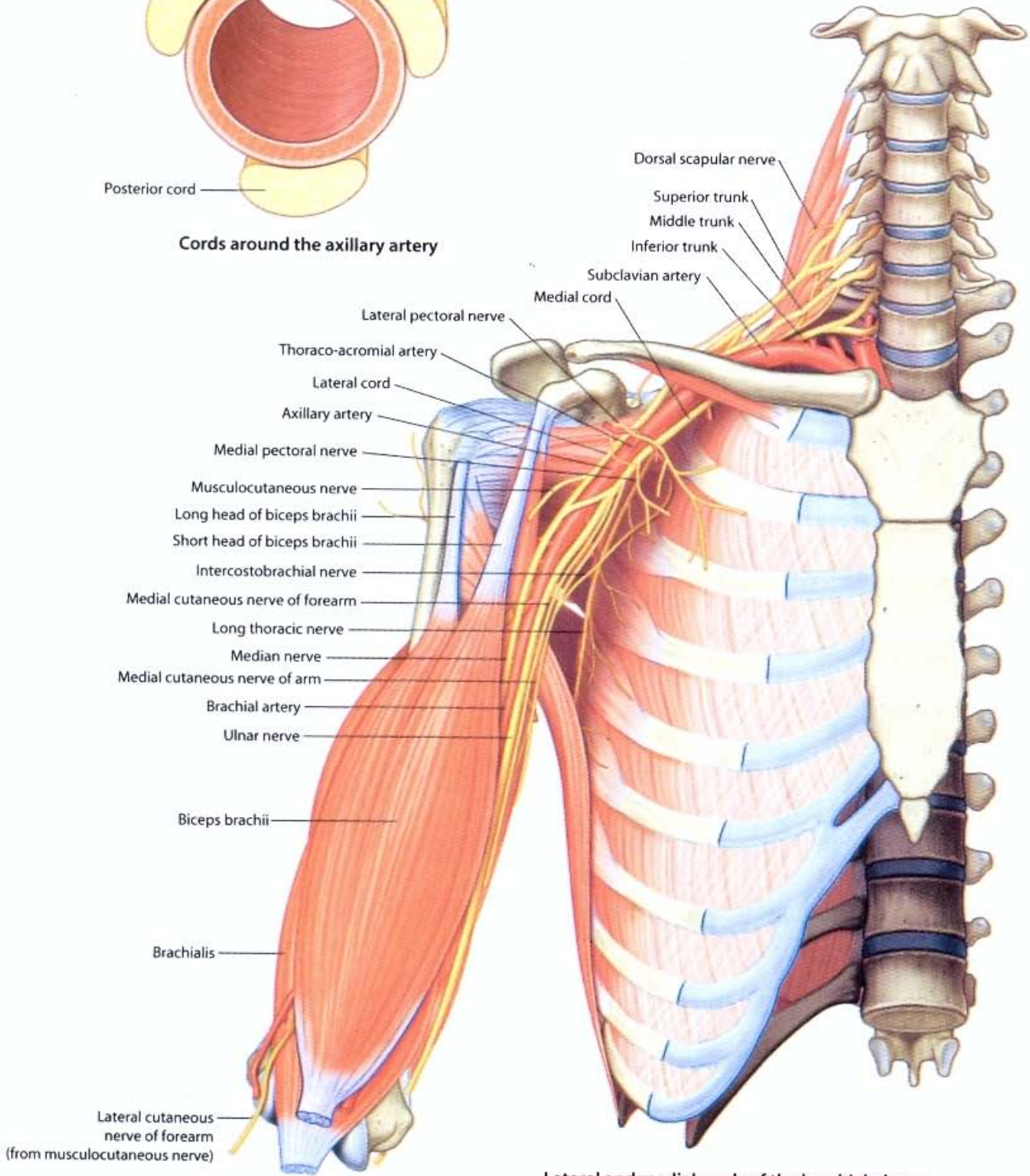
Schematic showing branches of the brachial plexus



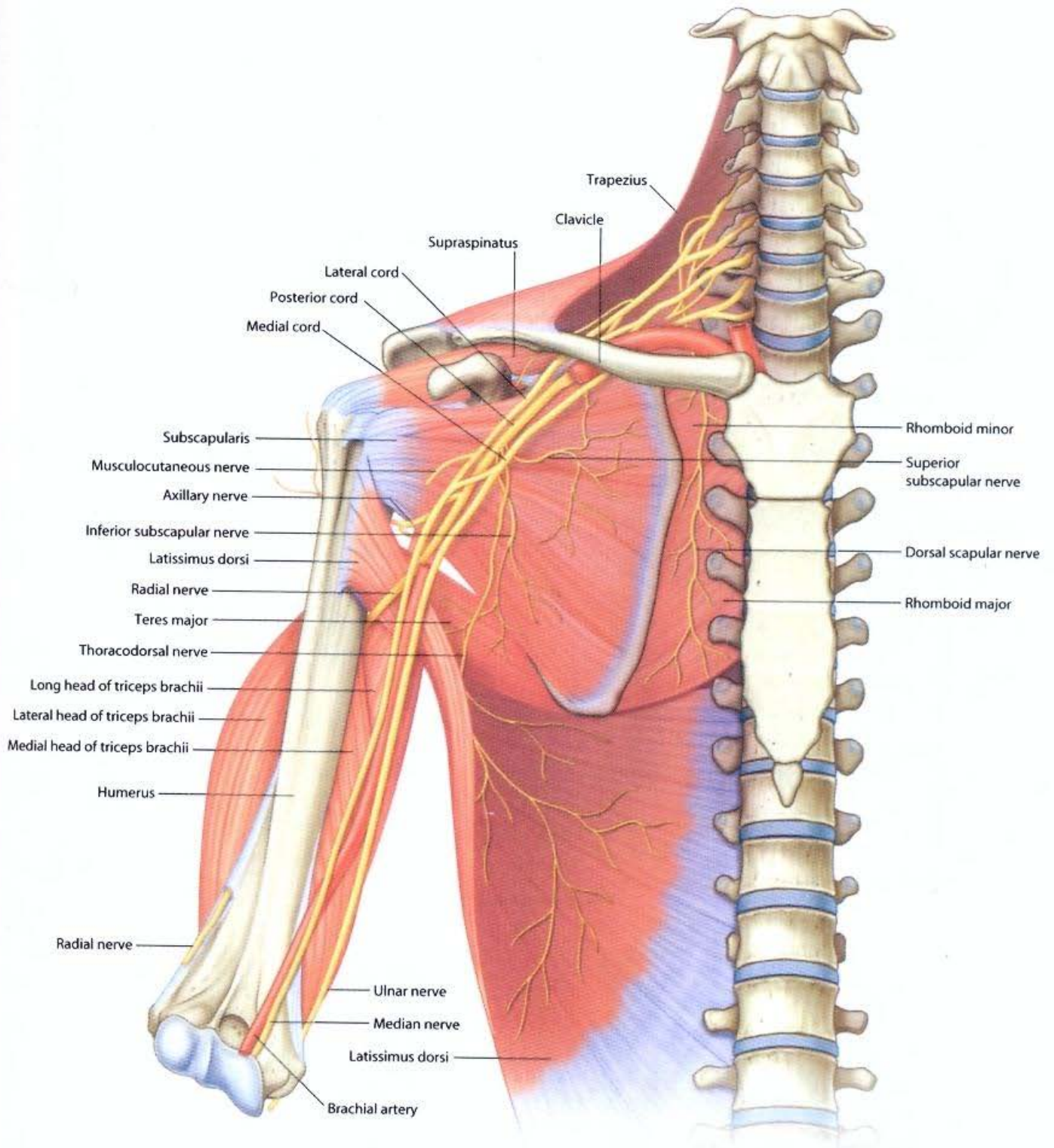
Brachial plexus



**Cords around the axillary artery**

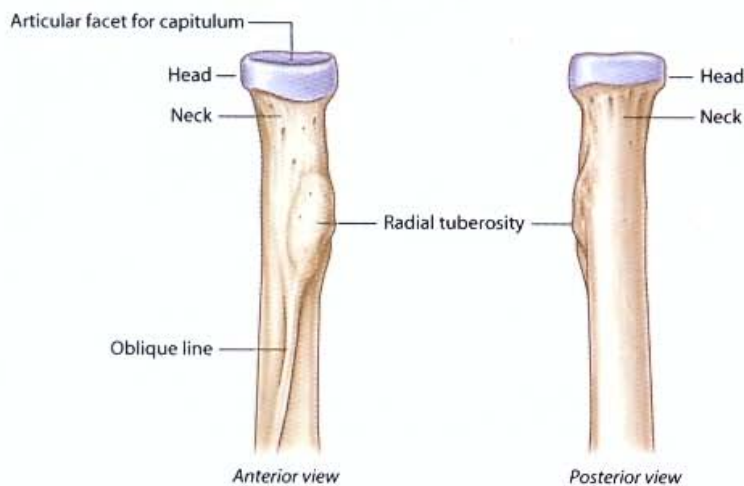
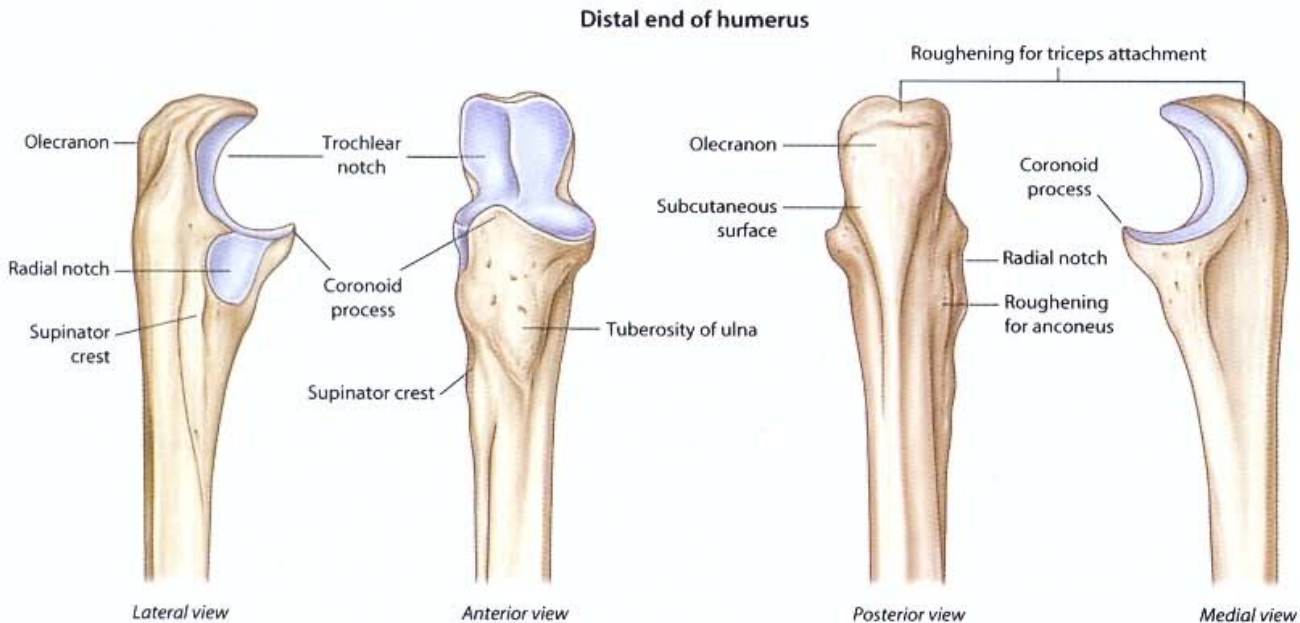
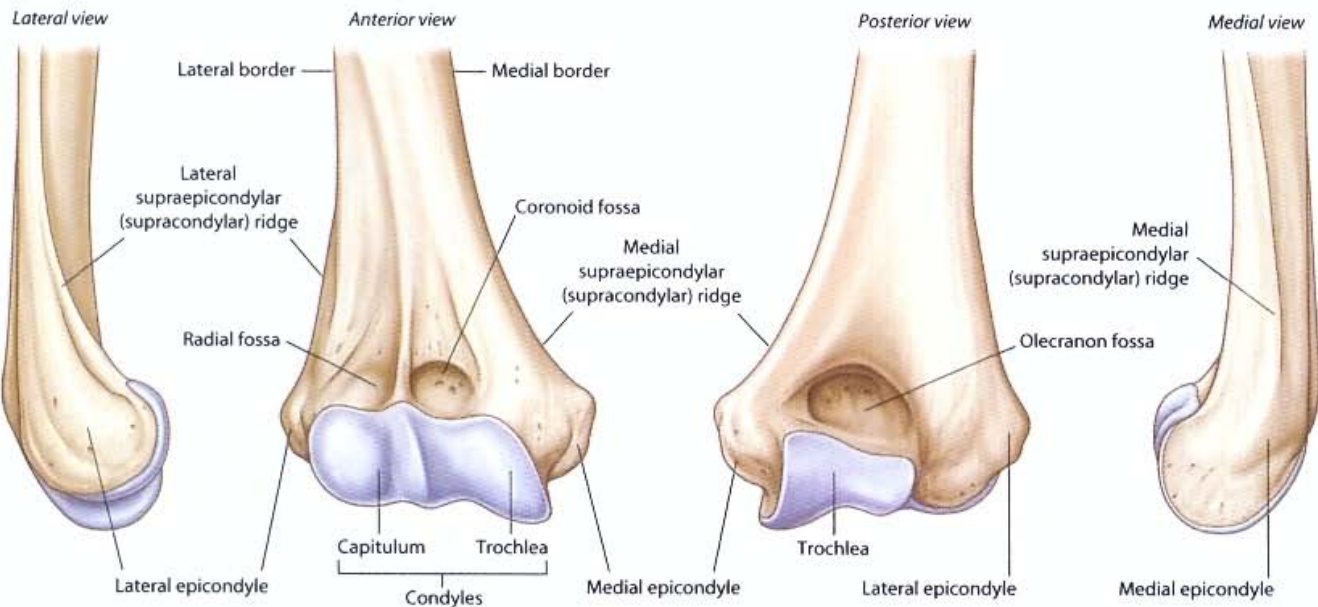


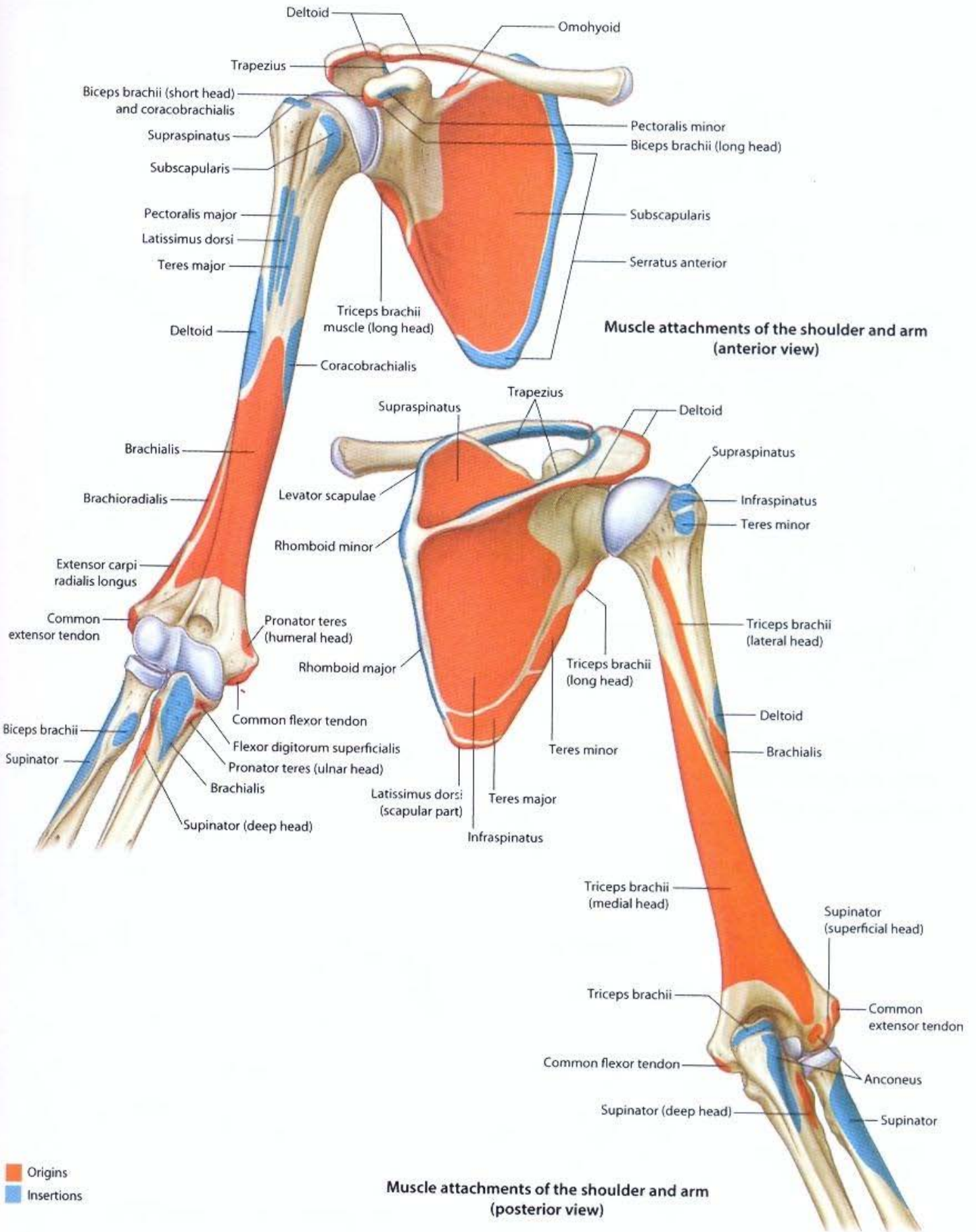
**Lateral and medial cords of the brachial plexus**

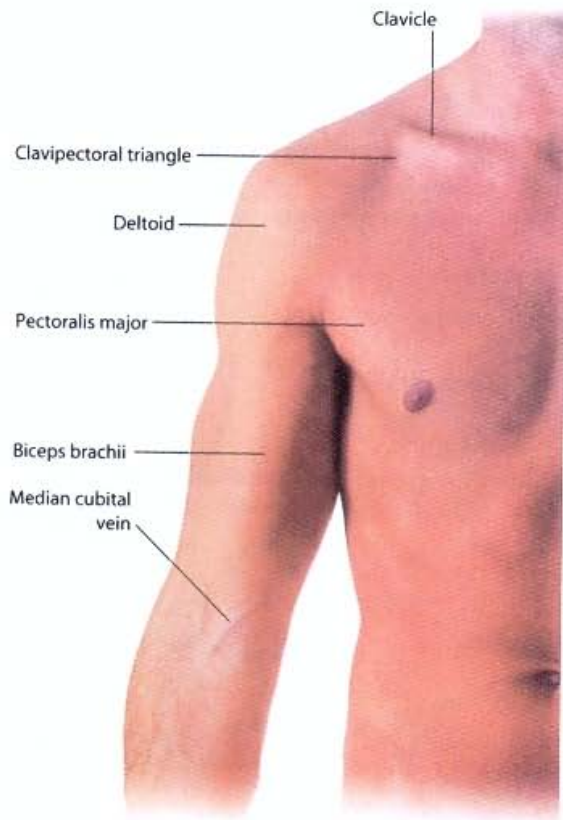


Posterior cord of the brachial plexus  
(ribs and associated muscles removed)

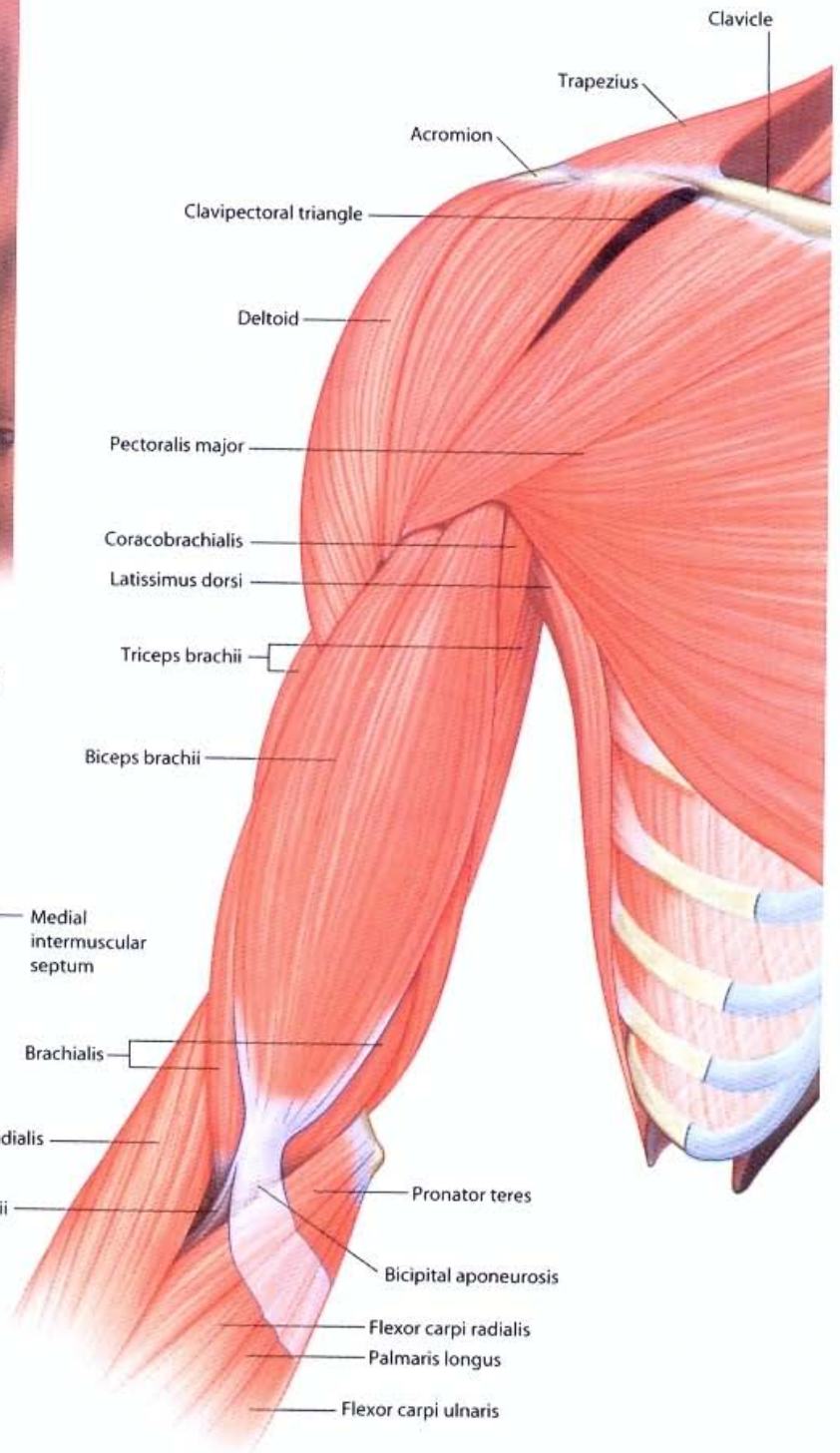
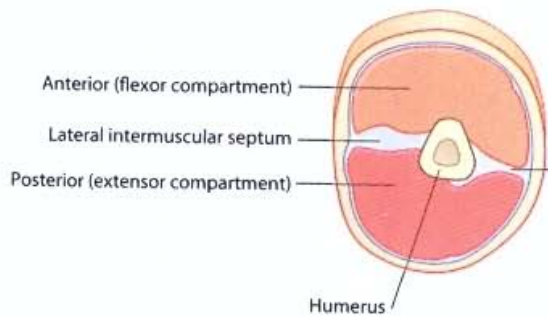
# UPPER LIMB • Distal end of humerus and proximal end of radius and ulna





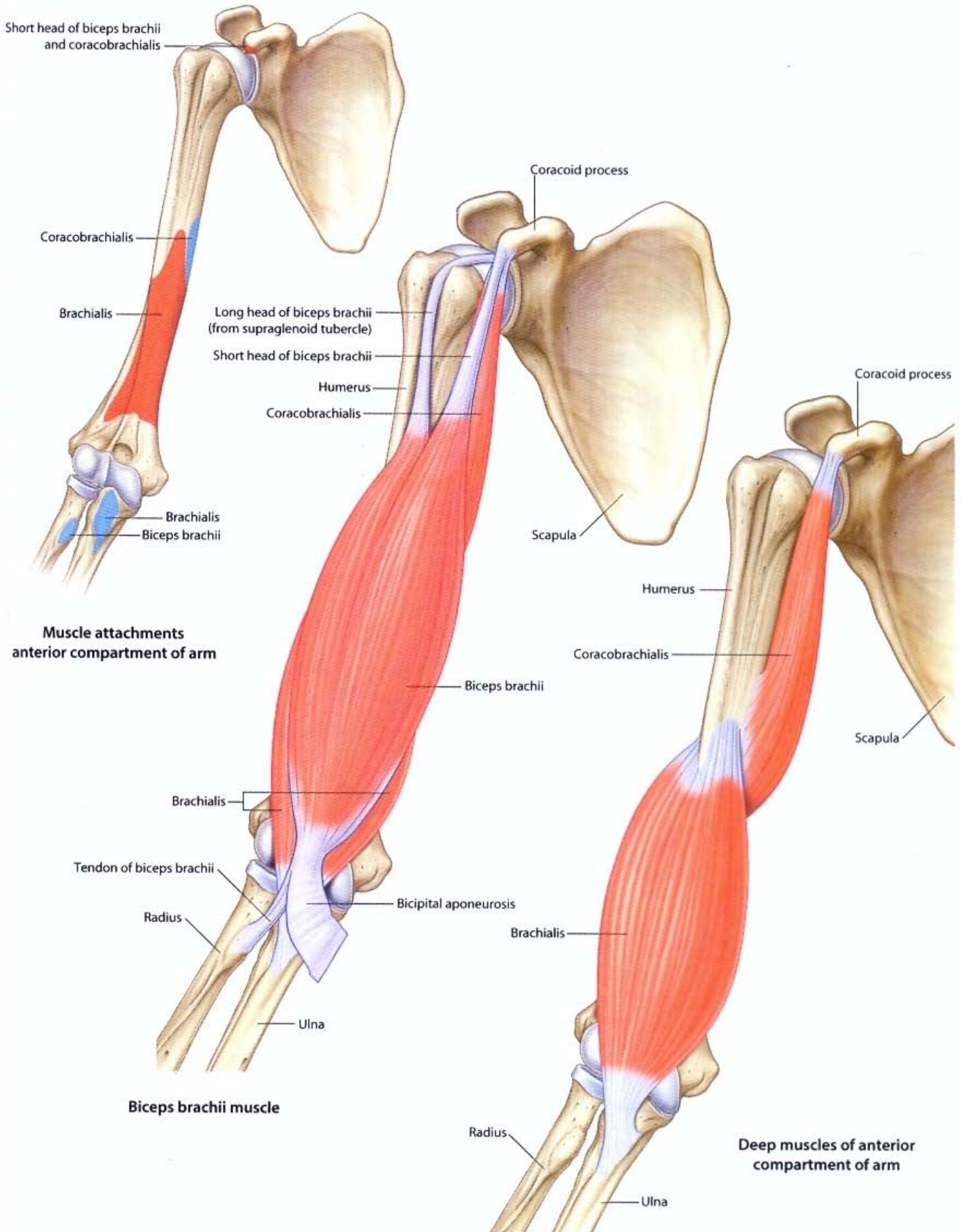


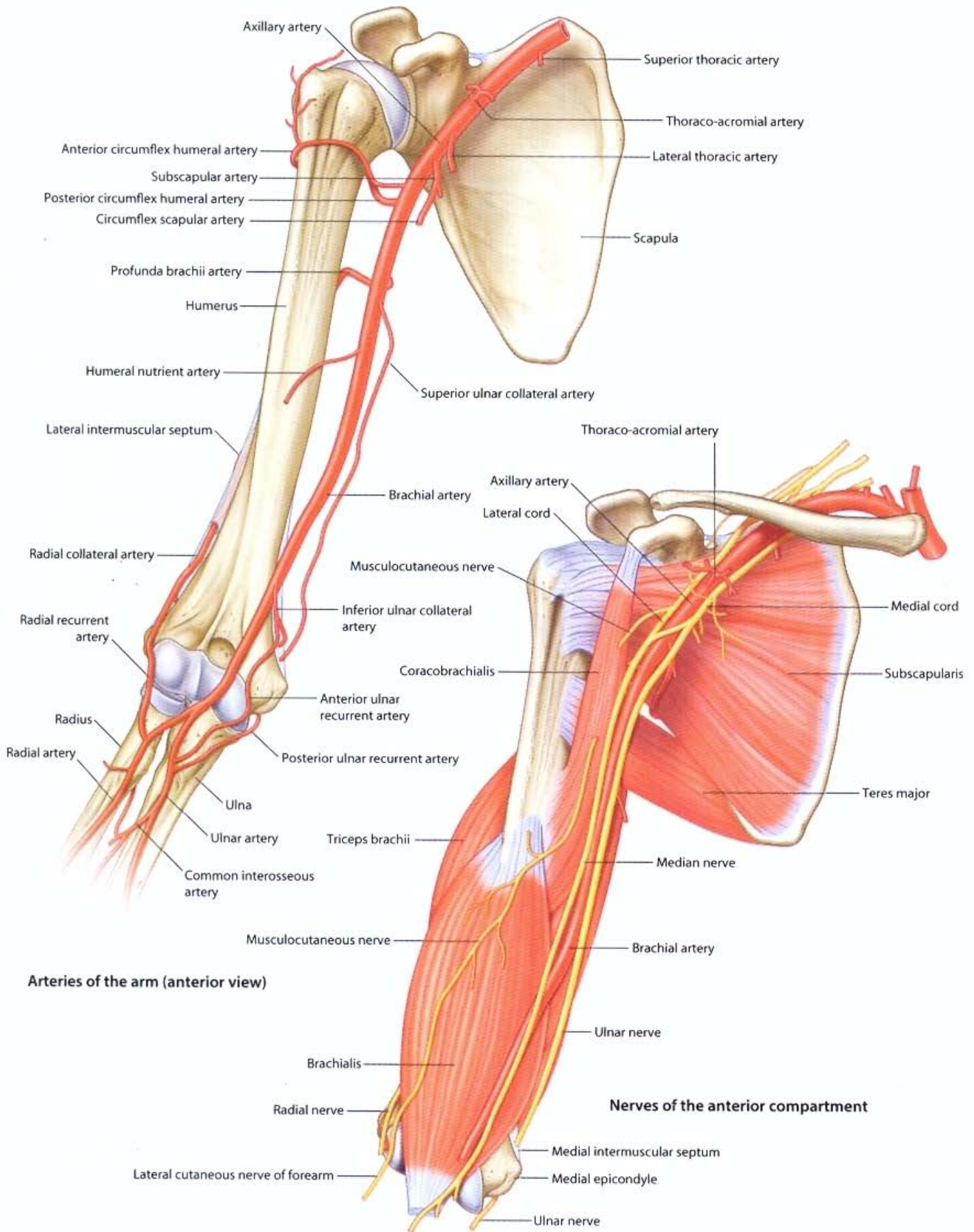
**Surface anatomy of anterior compartment**

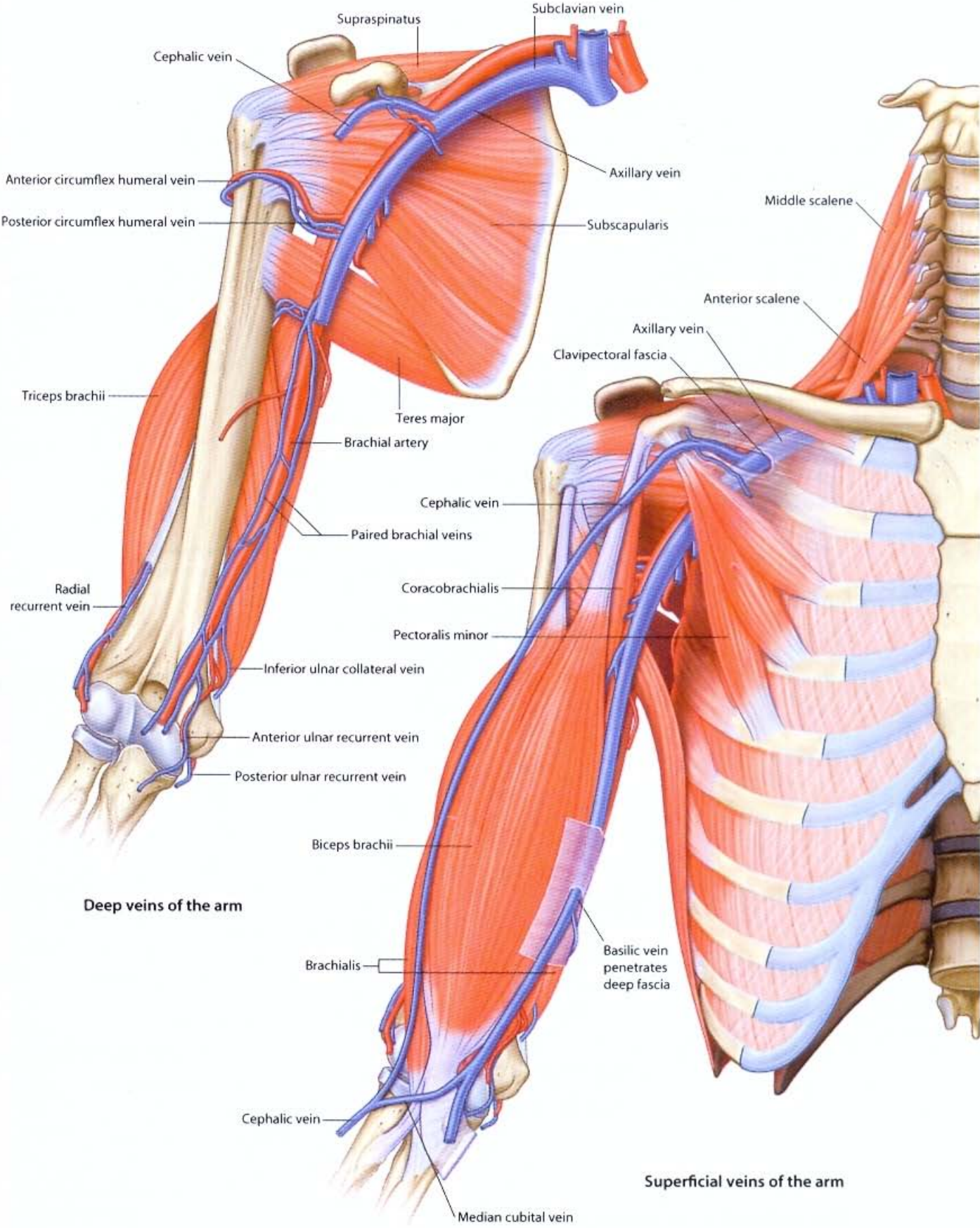


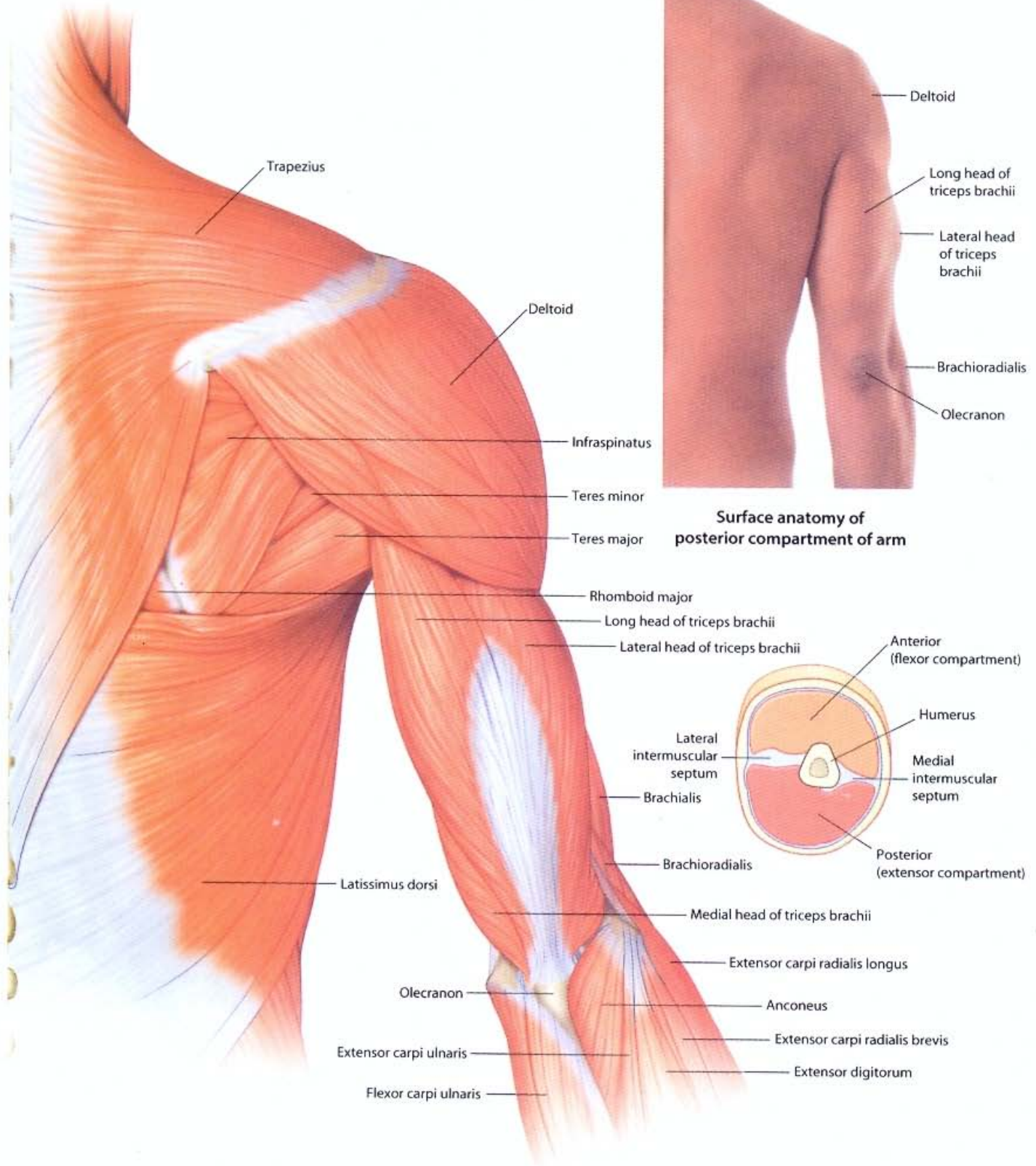
**Muscles of anterior compartment of arm**



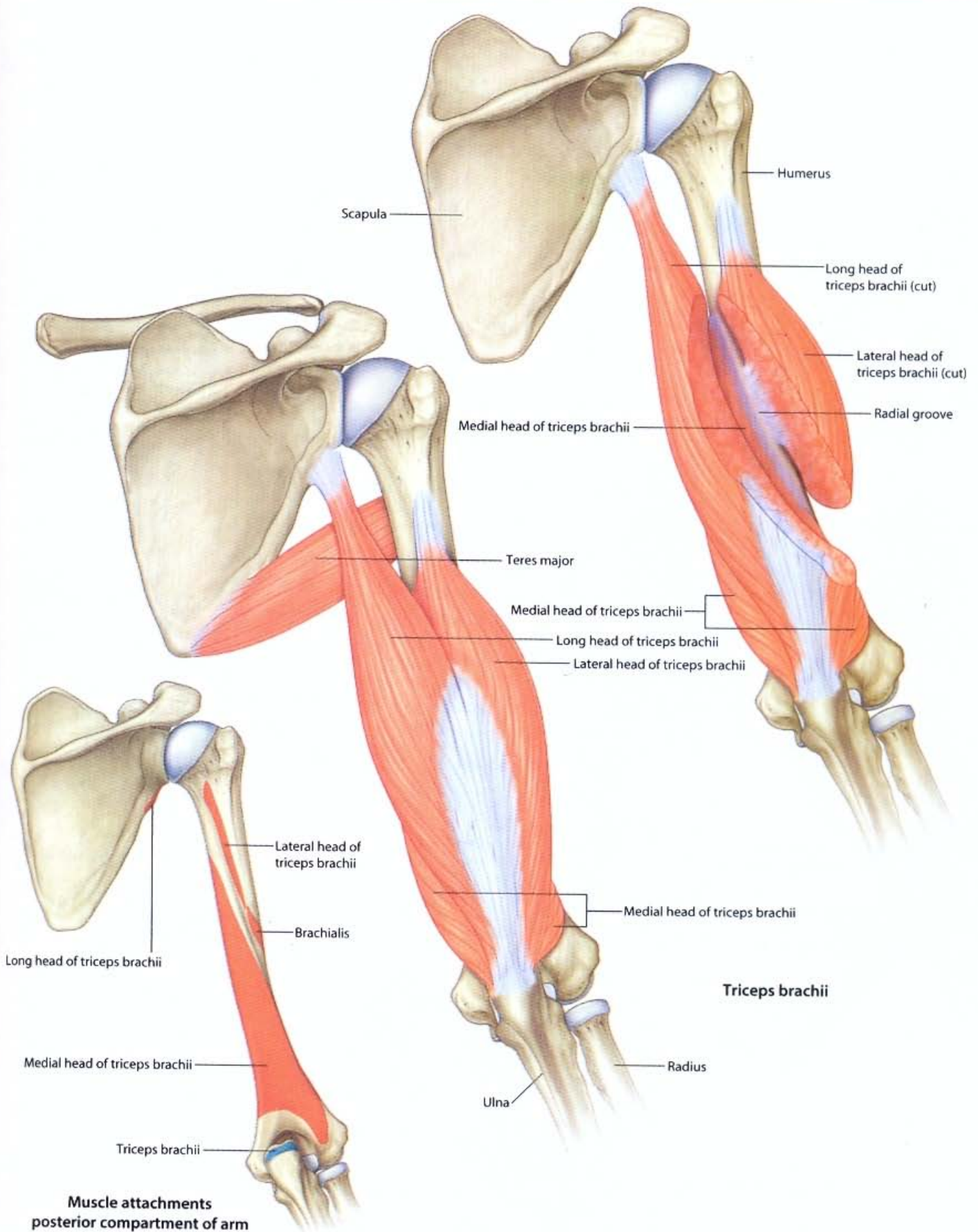




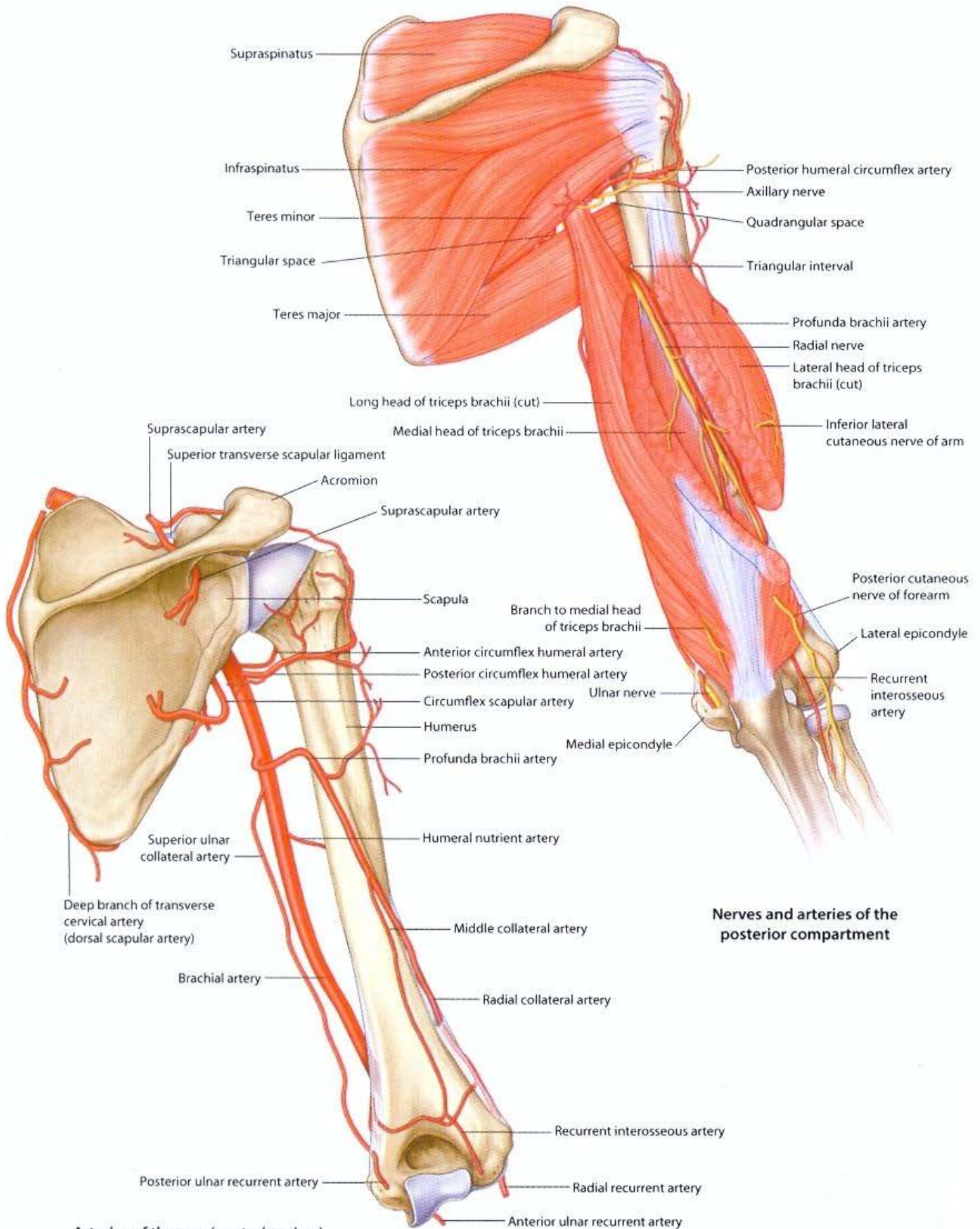




**Muscles of posterior compartment of arm**

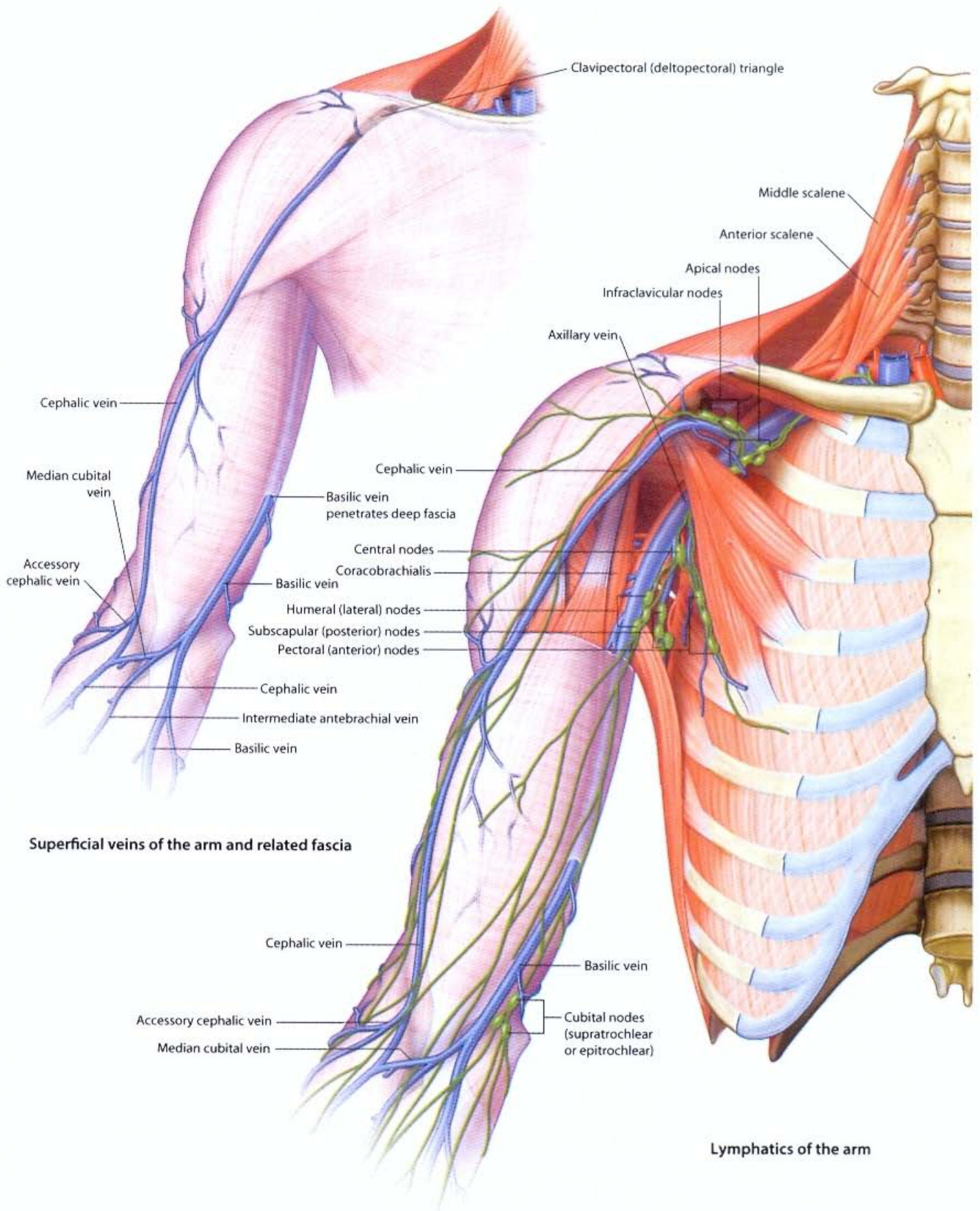


Muscle attachments posterior compartment of arm



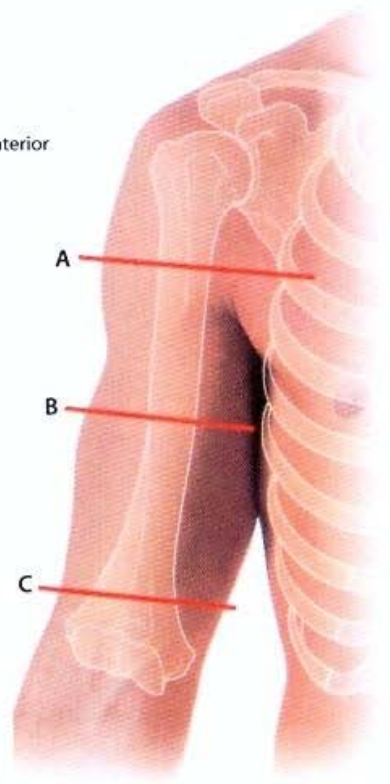
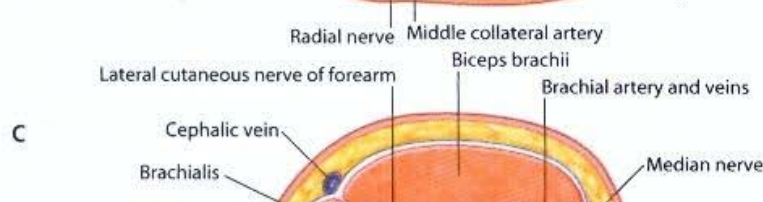
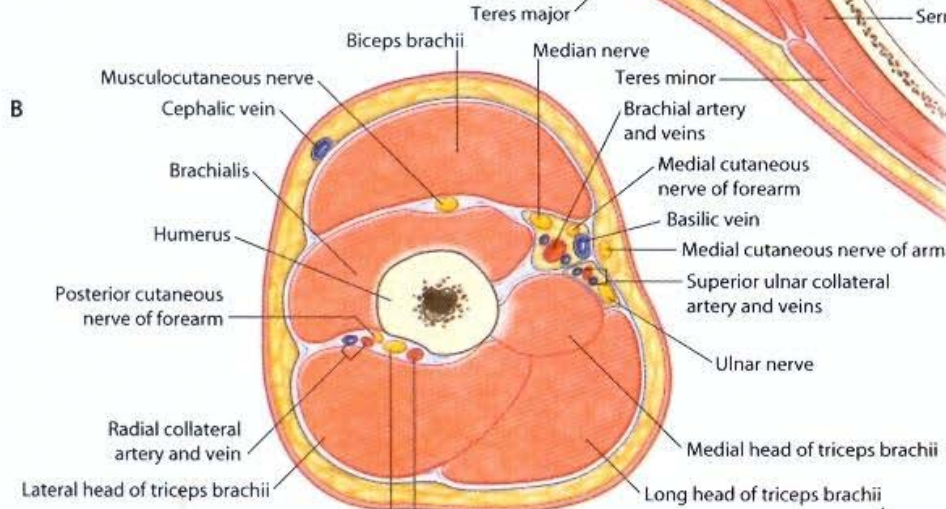
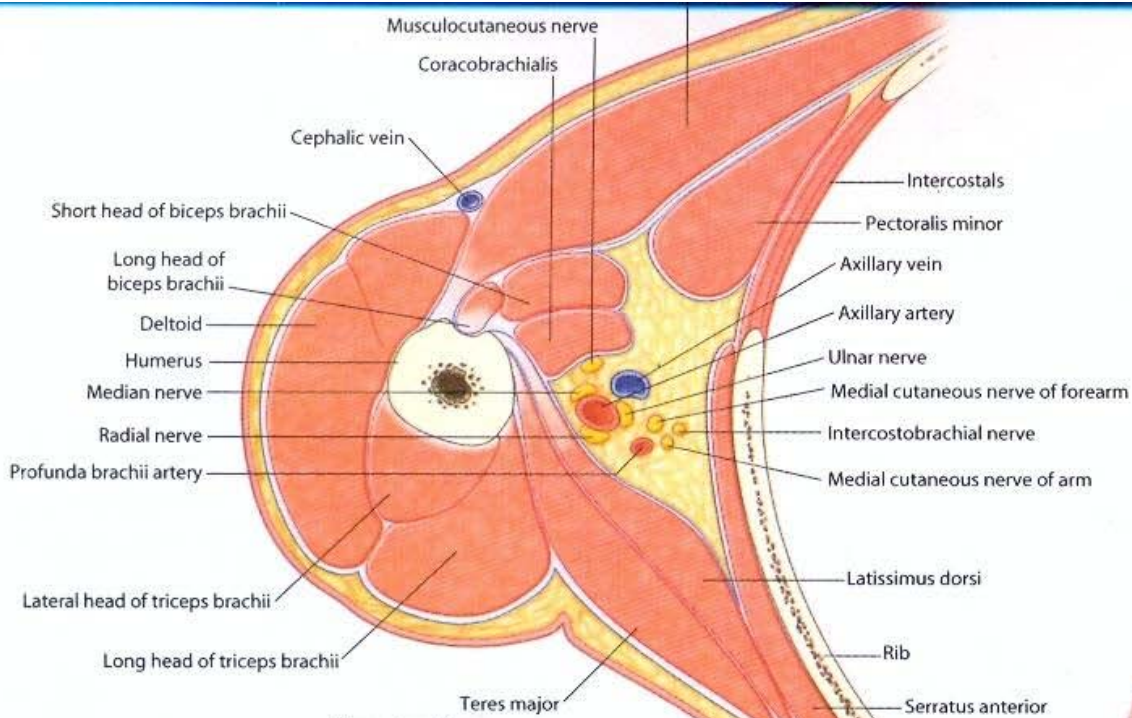
**Nerves and arteries of the posterior compartment**

**Arteries of the arm (posterior view)**

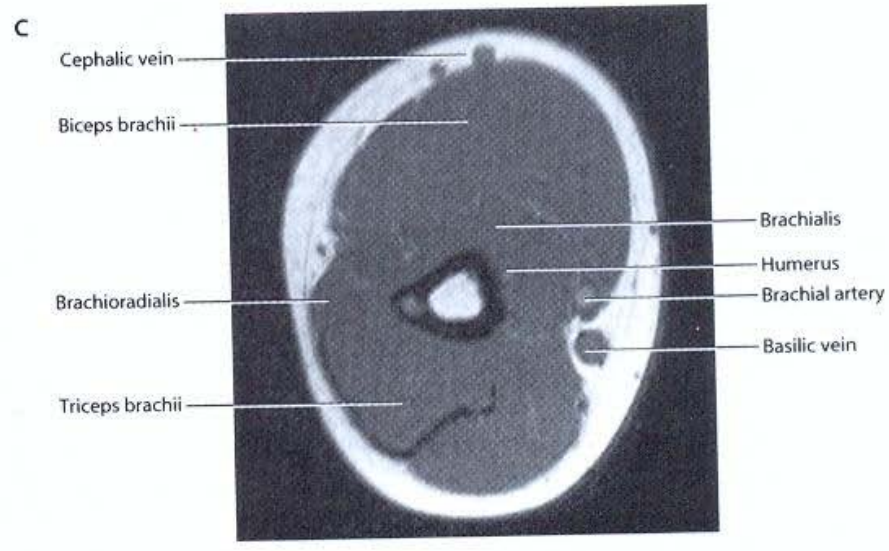
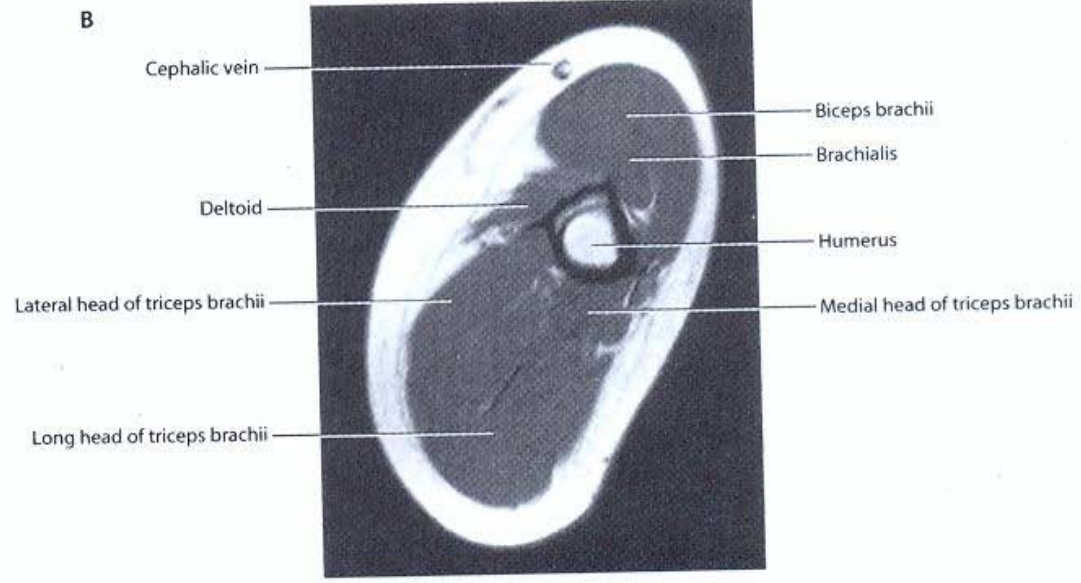
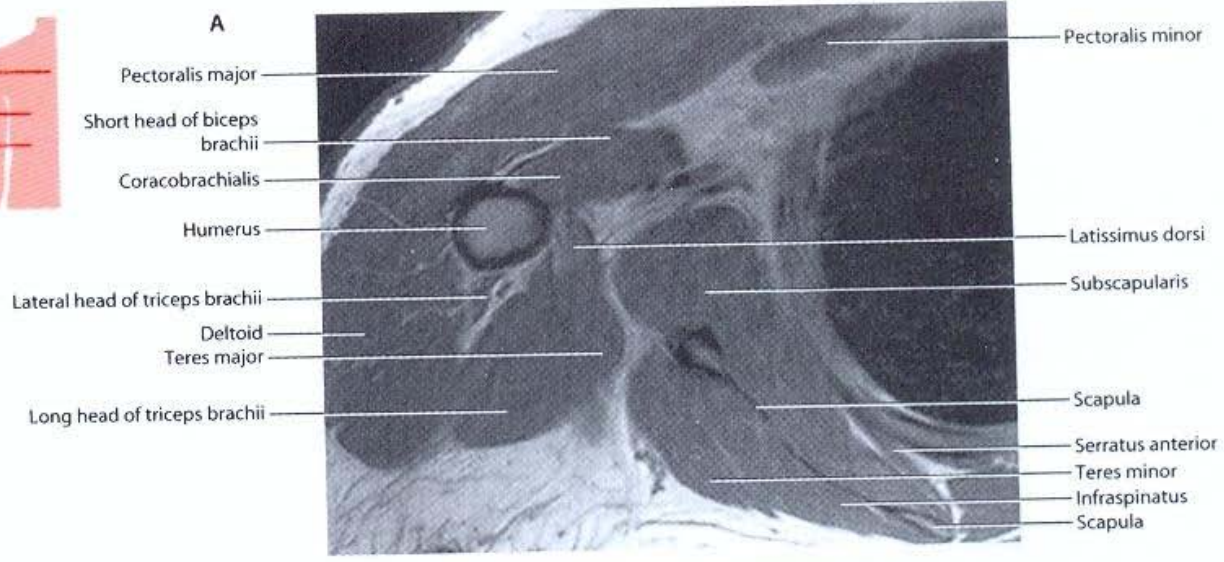


Superficial veins of the arm and related fascia

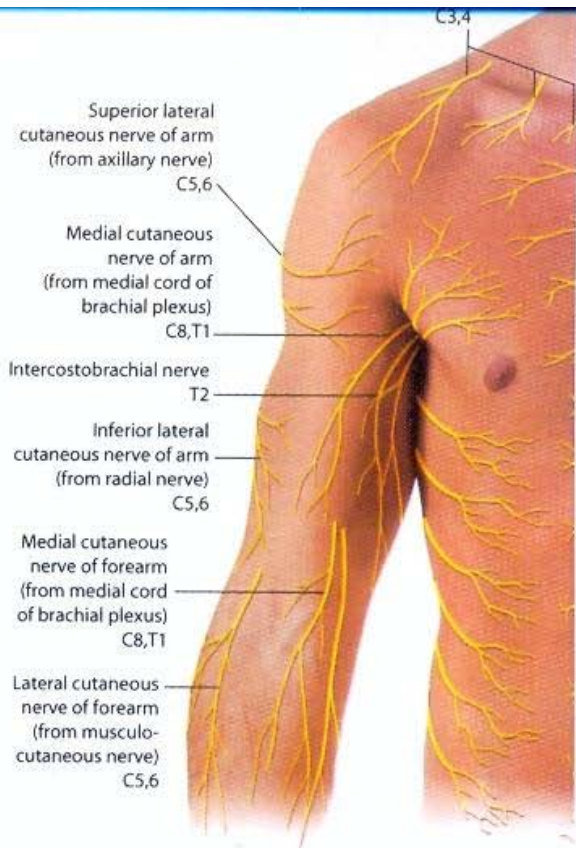
Lymphatics of the arm



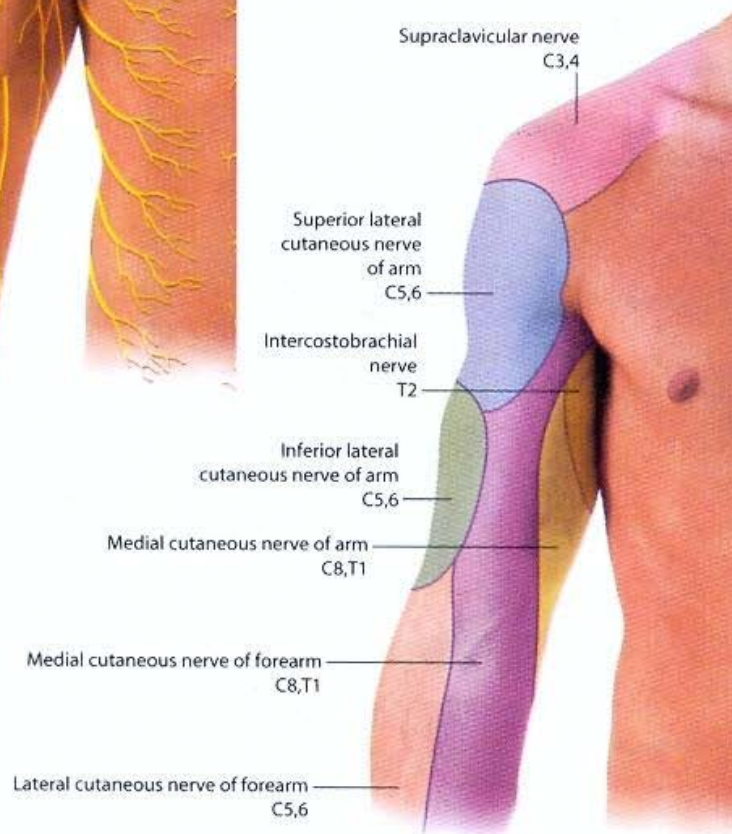




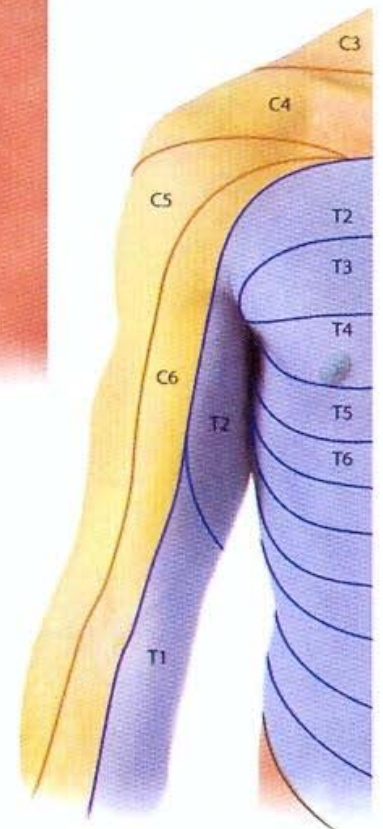
Transverse/axial sections through the arm.  
 A. Proximal/upper arm. B. Middle arm. C. Distal/lower arm.  
 T1-weighted MR image in axial plane



Cutaneous nerves of the arm

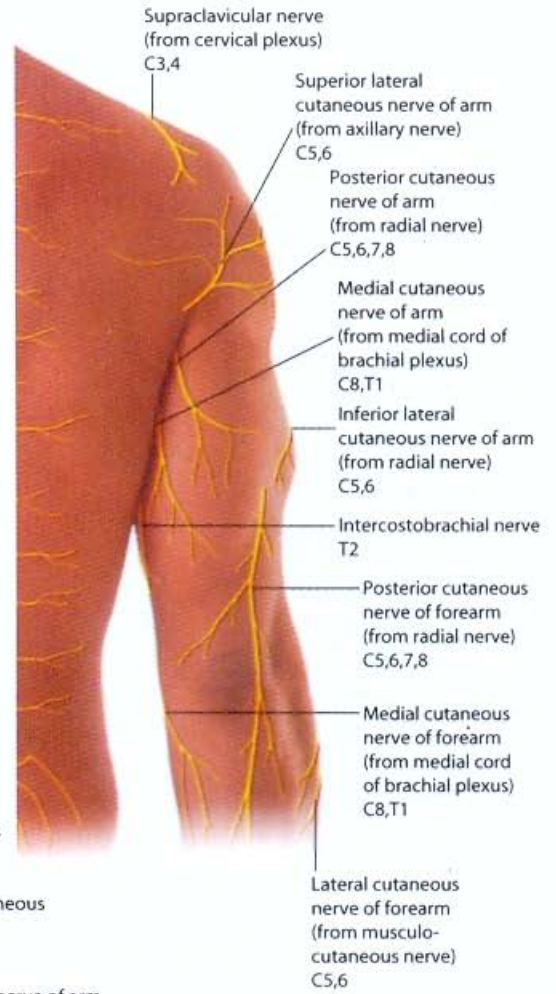


Areas of distribution of the cutaneous nerves of the arm

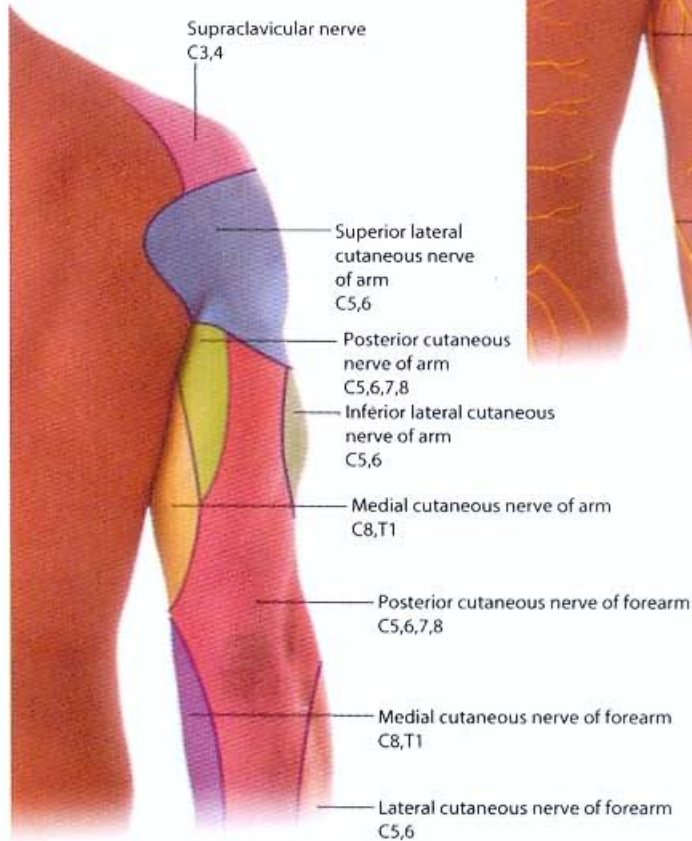
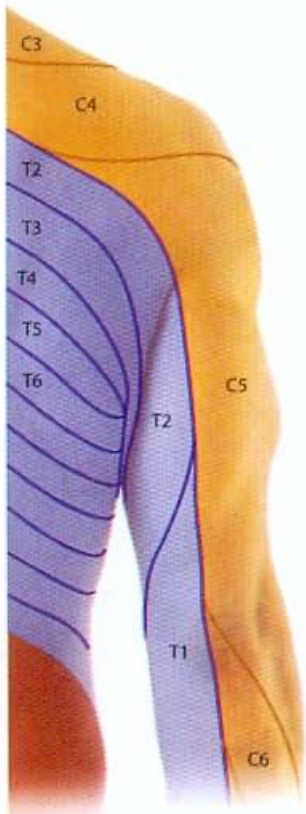


Dermatomes of the arm

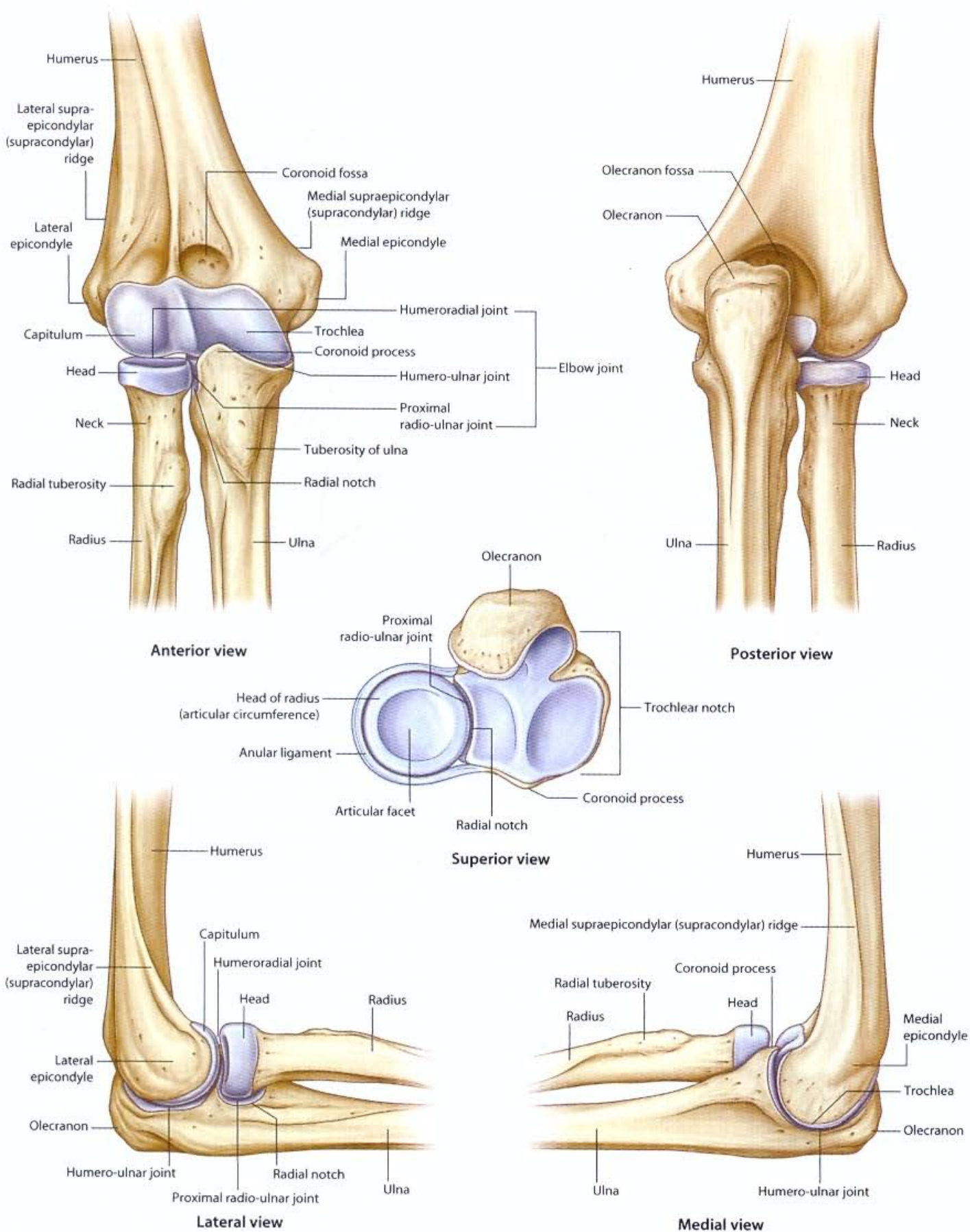
Cutaneous nerves of the arm

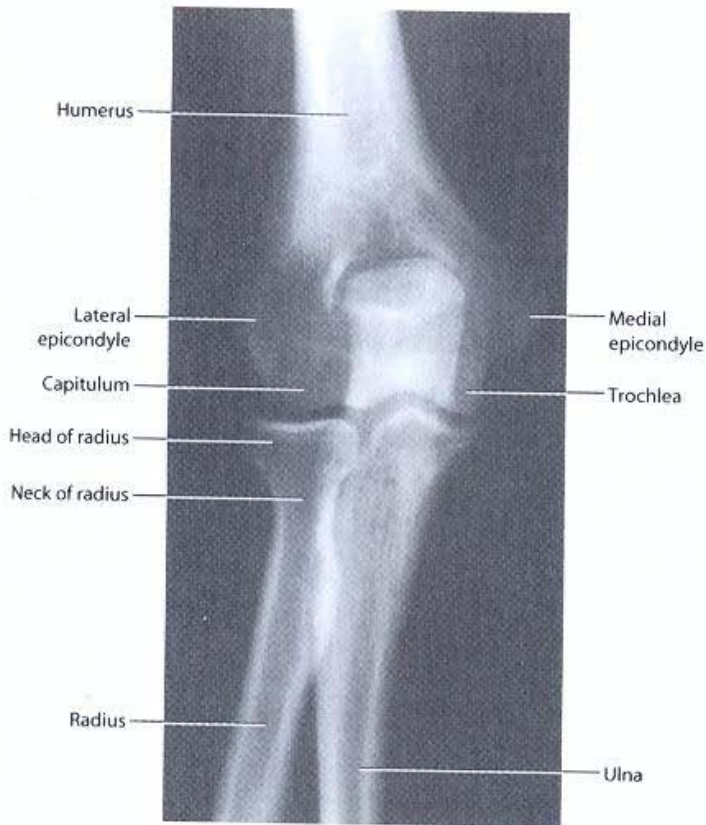


Areas of distribution of the cutaneous nerves of the arm

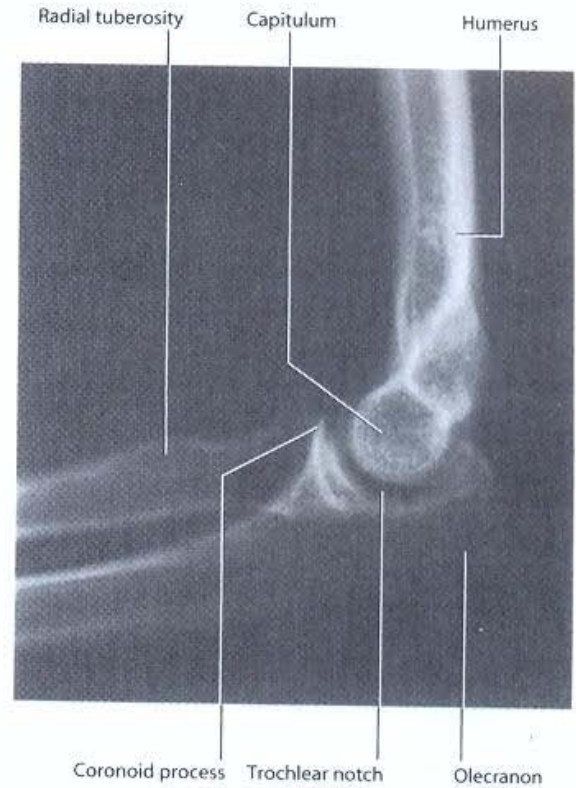


Dermatomes of the arm

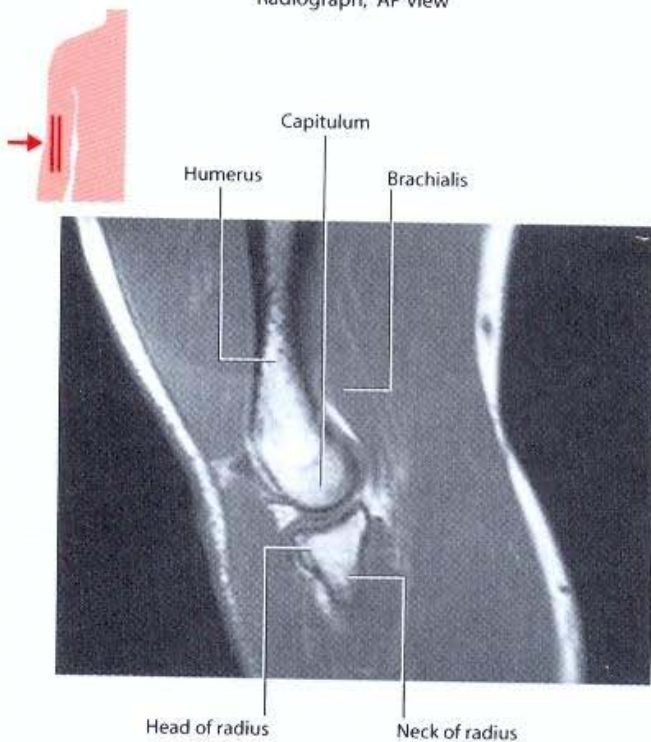




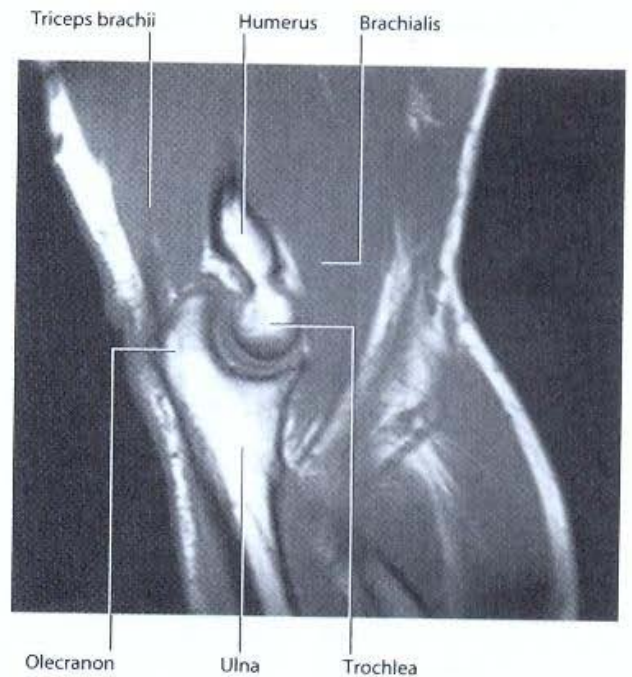
Normal elbow joint.  
Radiograph, AP view



Normal elbow joint.  
Radiograph, lateral view

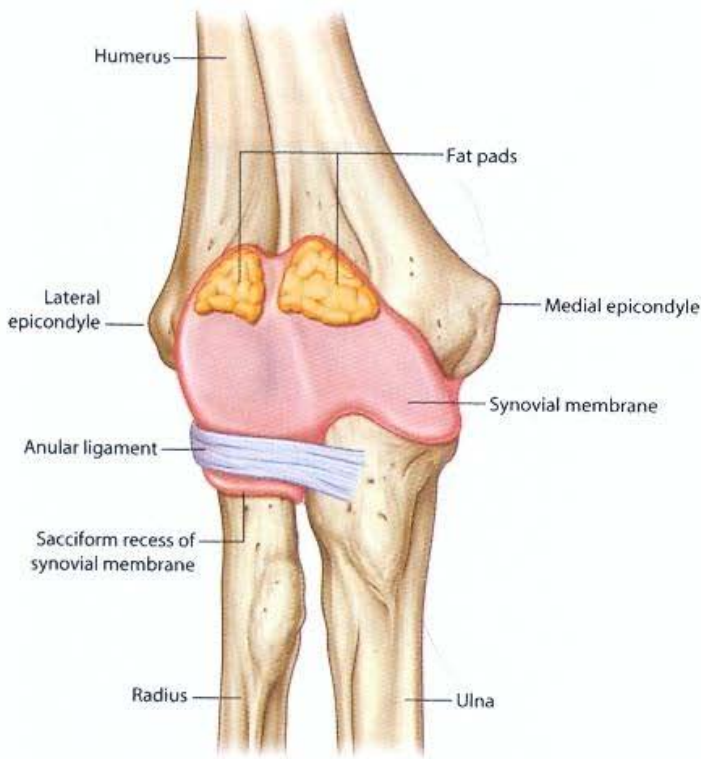


Articulation of the capitulum of the humerus and the head of the radius at the elbow joint.  
T2-weighted MR image in sagittal plane

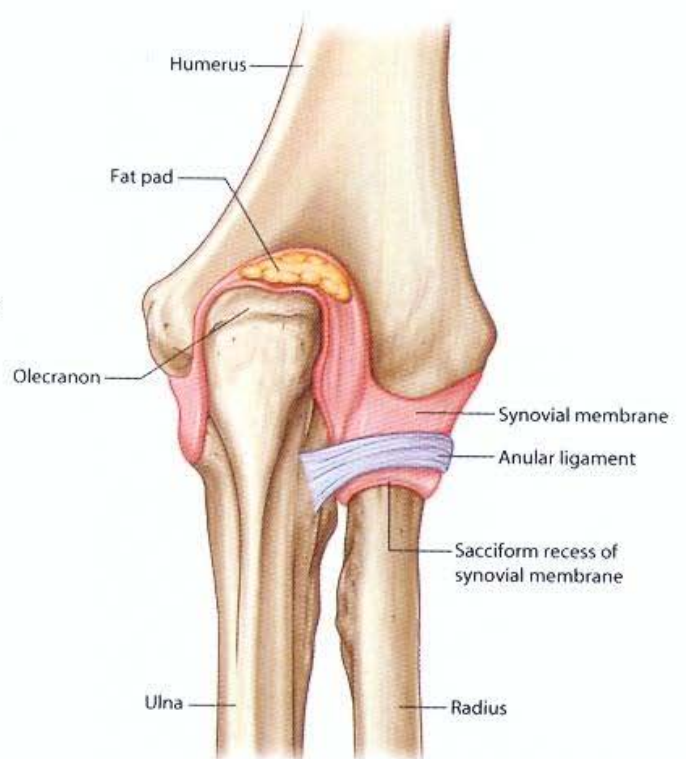


Articulation of the trochlea of the humerus and the trochlear notch of the ulna.  
T2-weighted MR image in sagittal plane

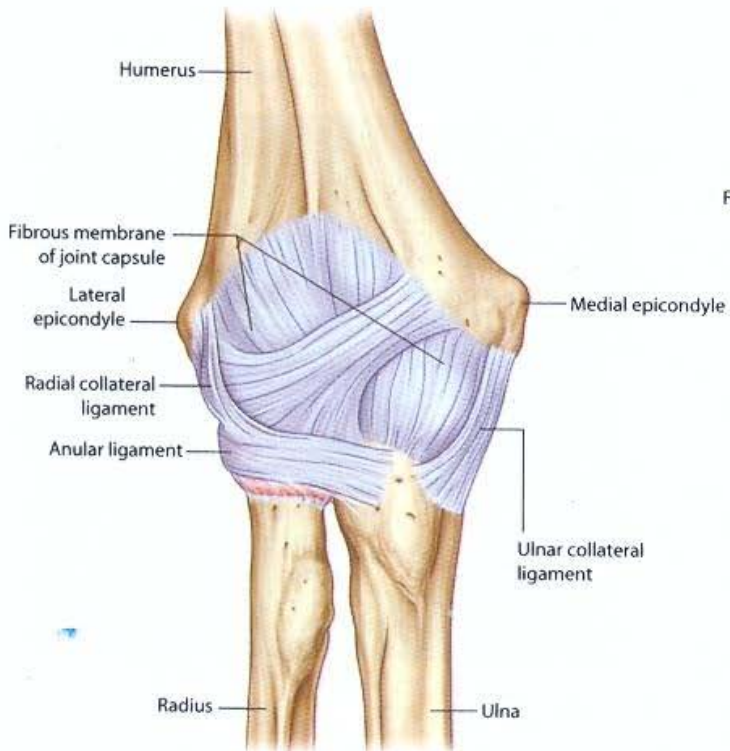
# UPPER LIMB • Elbow joint: capsule and ligaments



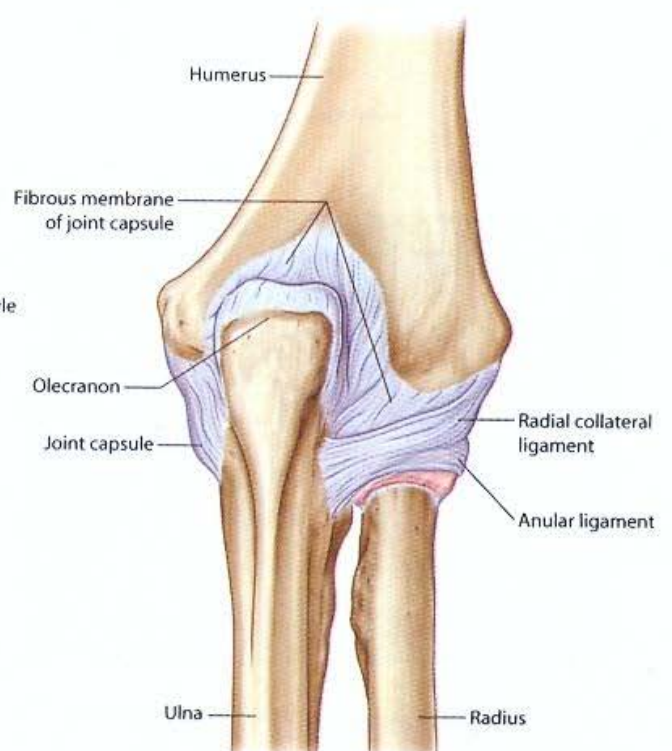
Synovial membrane of the elbow joint (anterior view)



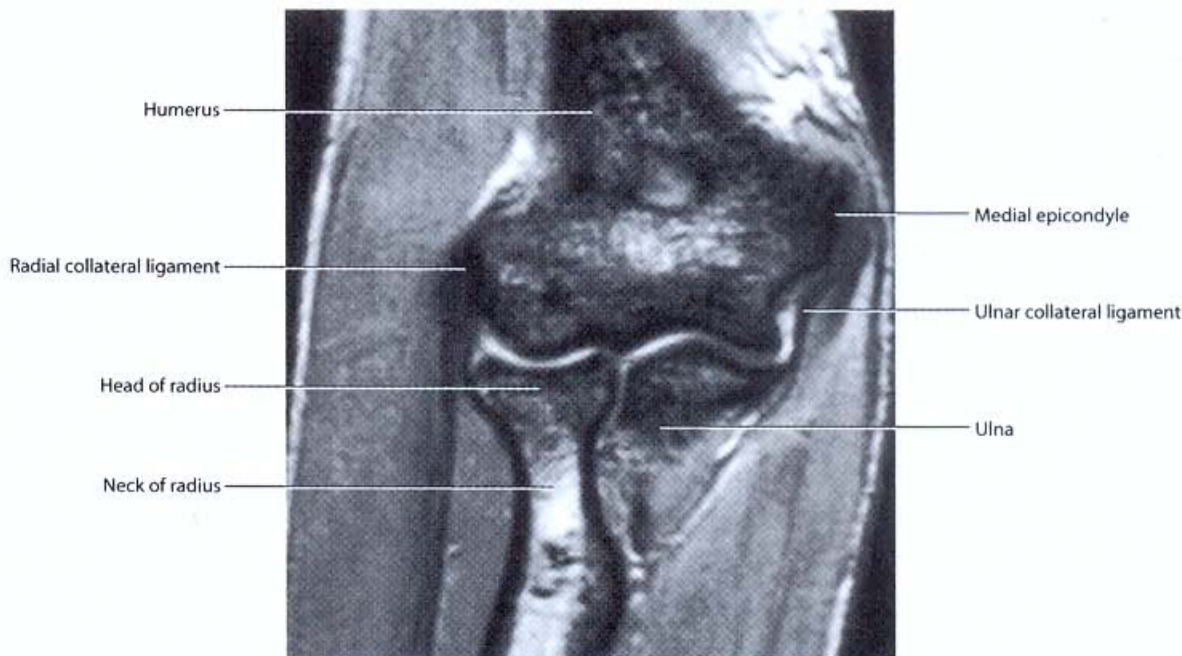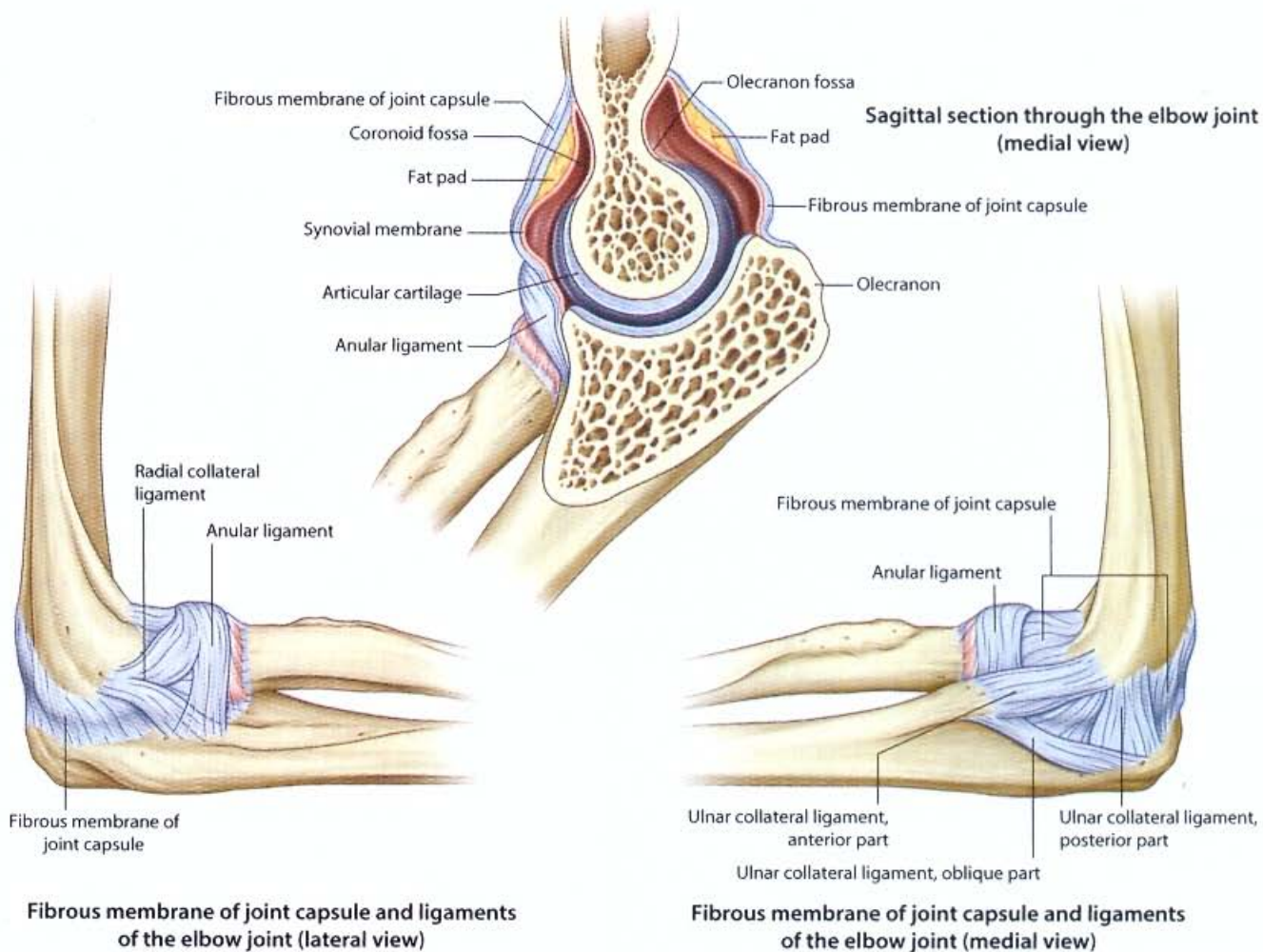
Synovial membrane of the elbow joint (posterior view)



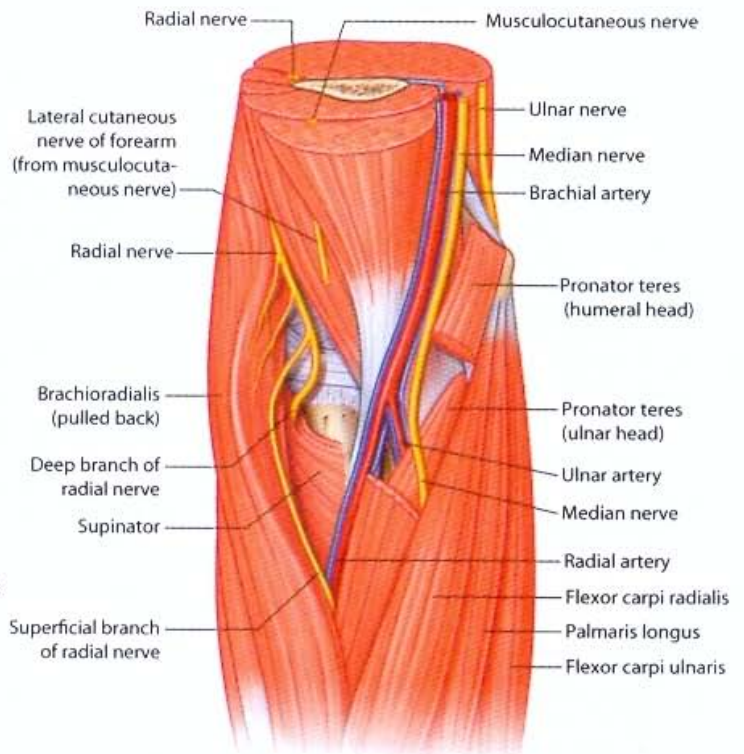
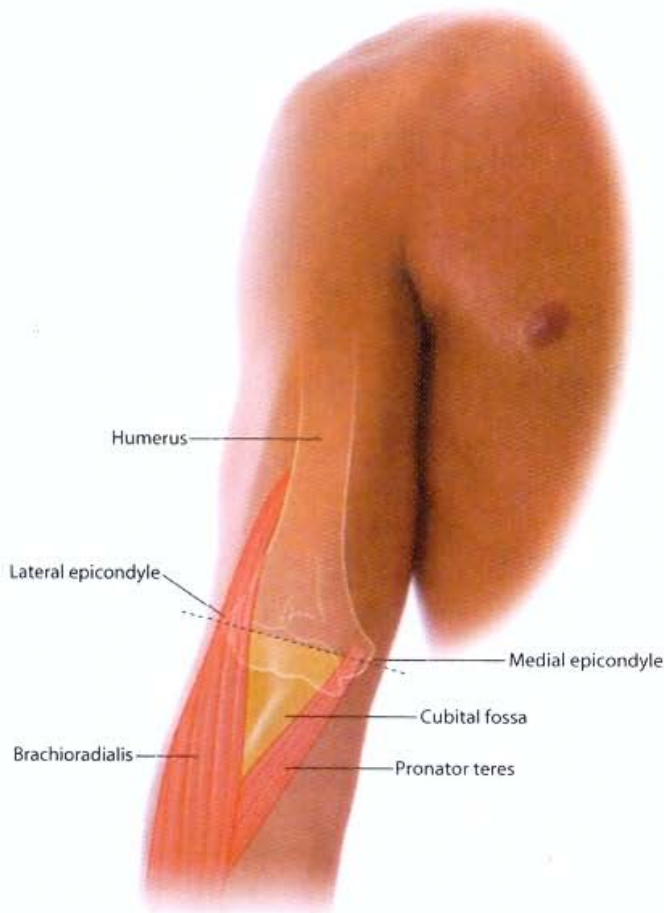
Fibrous membrane of joint capsule and ligaments of the elbow joint (anterior view)



Fibrous membrane of joint capsule and ligaments of the elbow joint (posterior view)

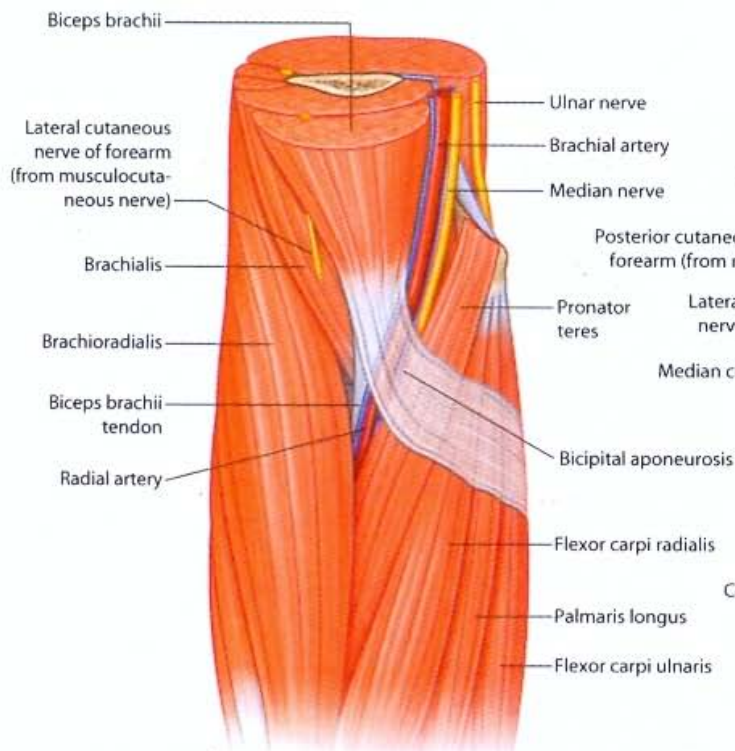


**Normal elbow joint.**  
T2-weighted MR image in coronal plane

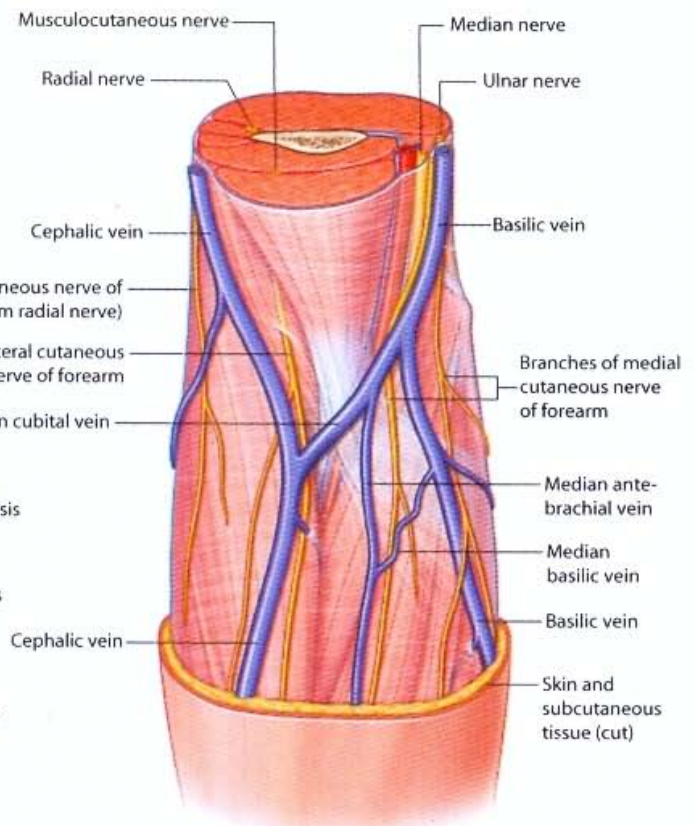


Position of the radial nerve

Margins of the cubital fossa

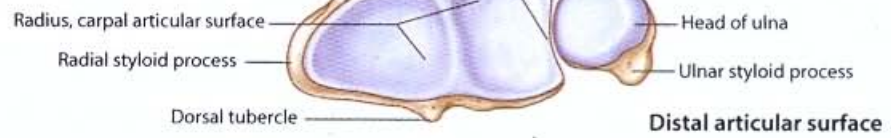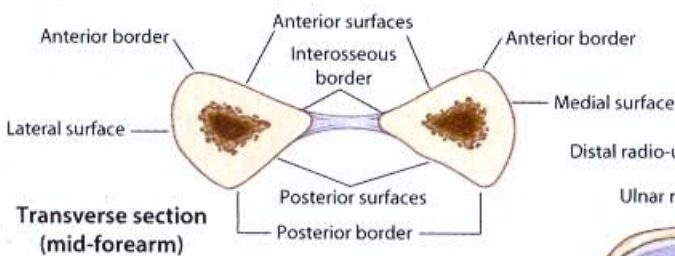
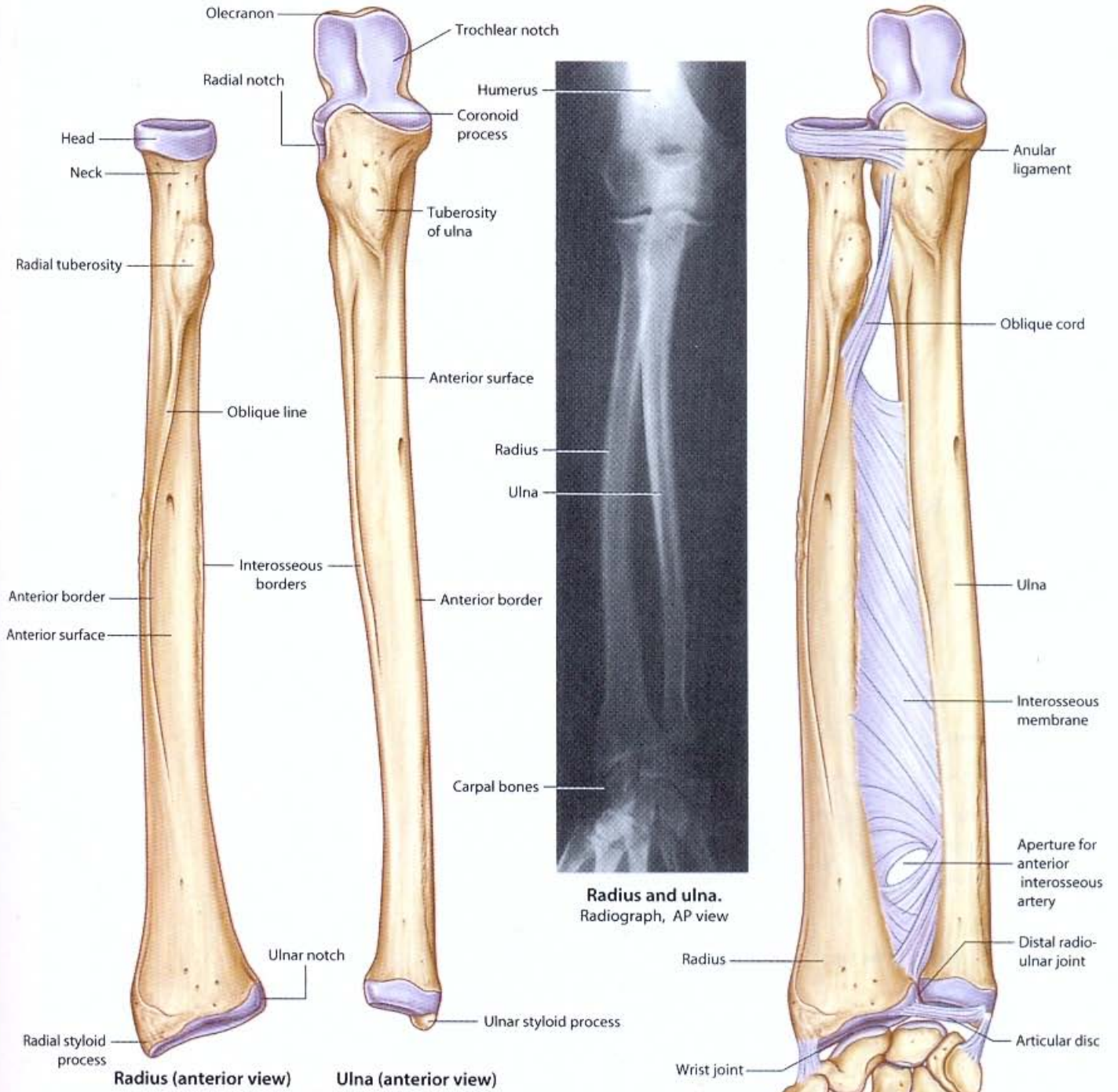


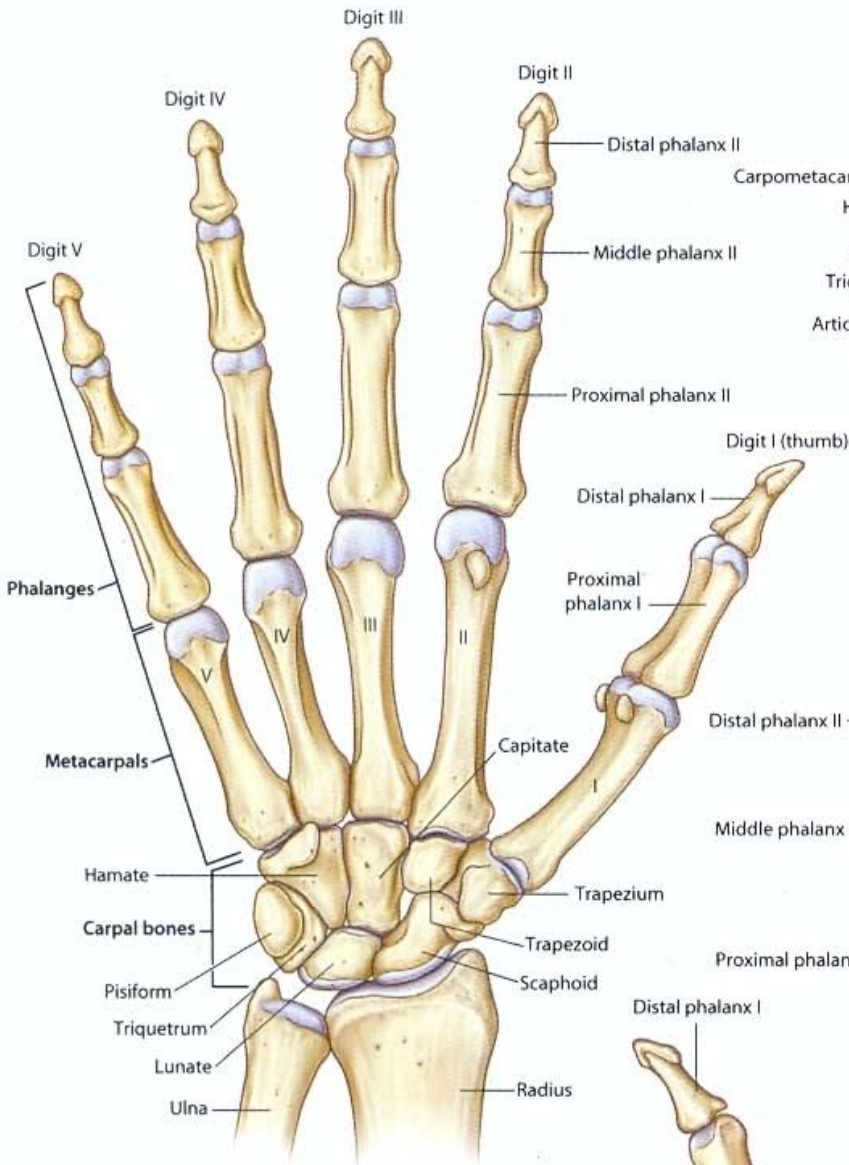
Contents of the cubital fossa



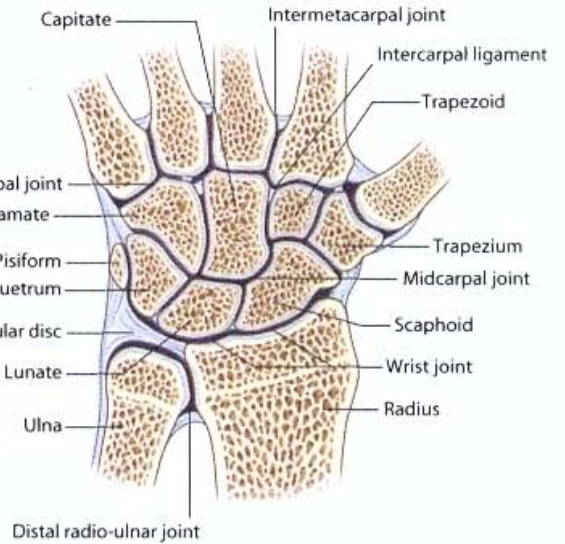
Superficial structures



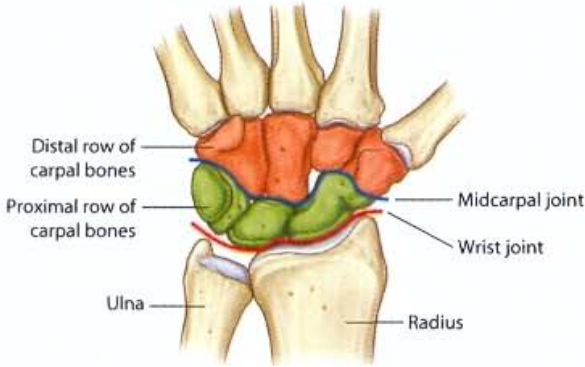




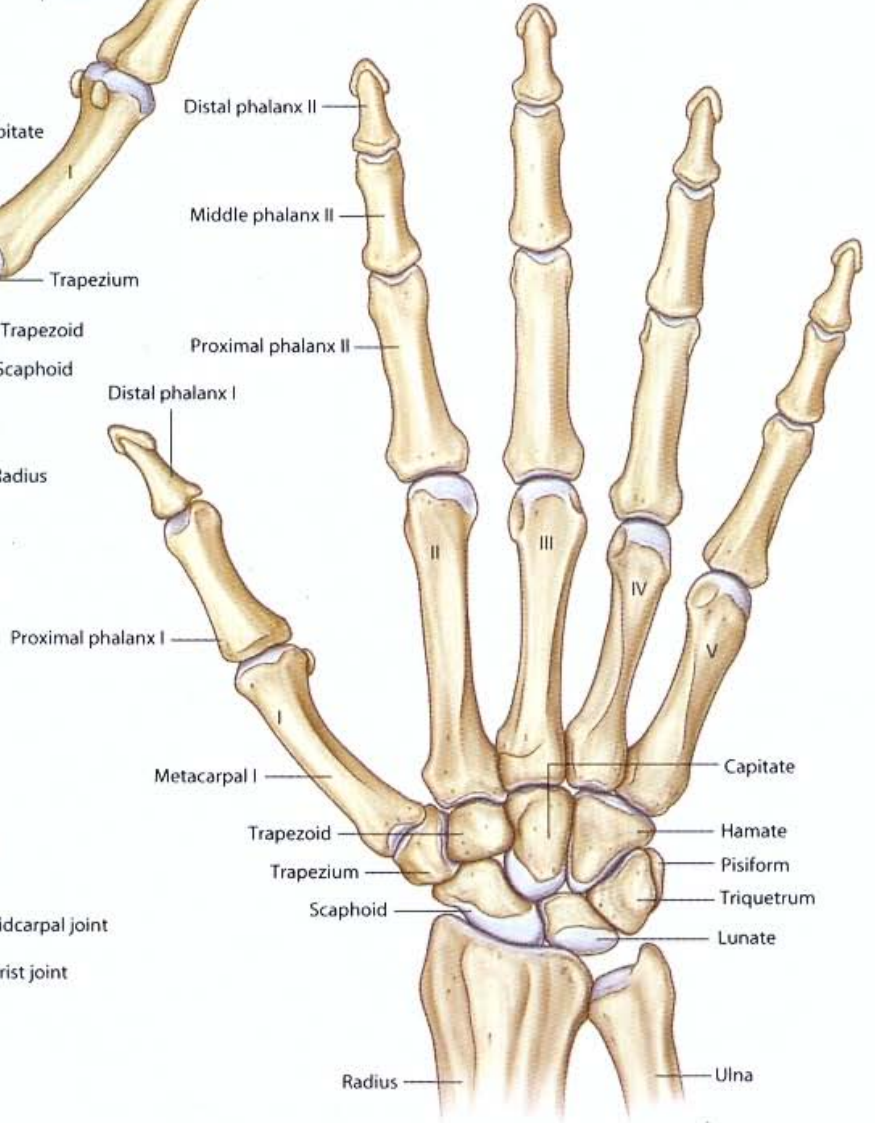
**Bones of the hand (palmar view)**



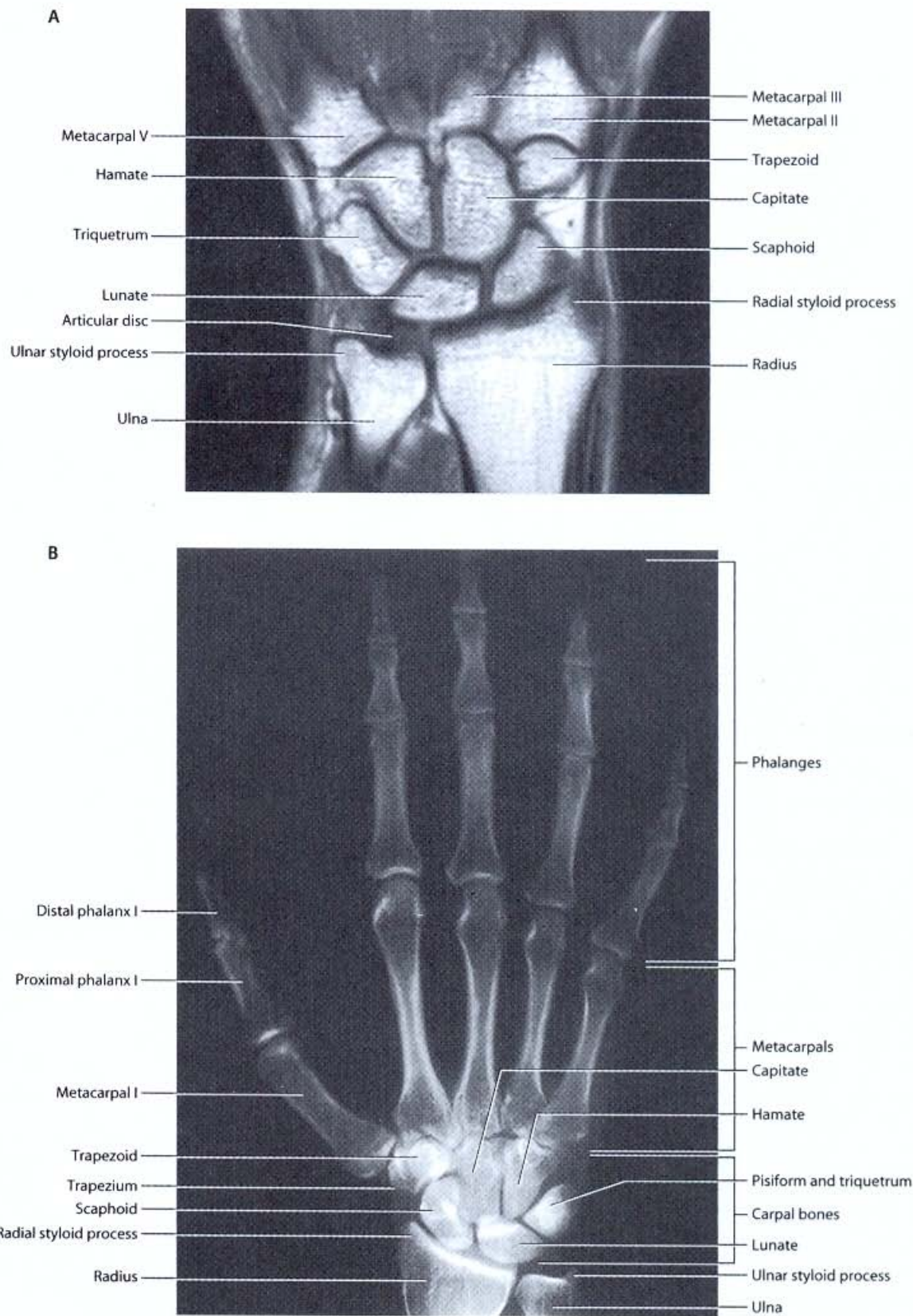
**Coronal section**



**Palmar view**



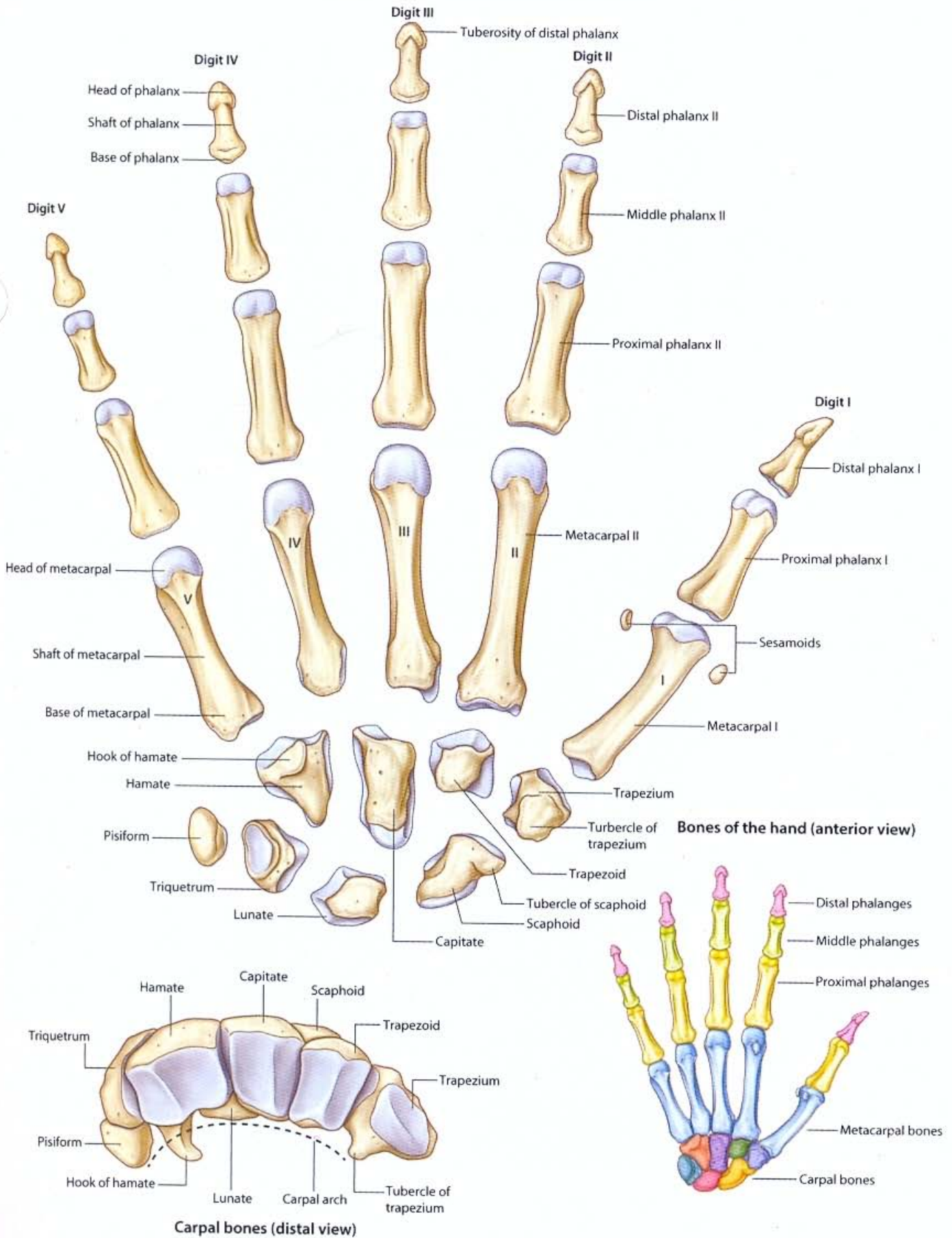
**Bones of the hand (dorsal view)**

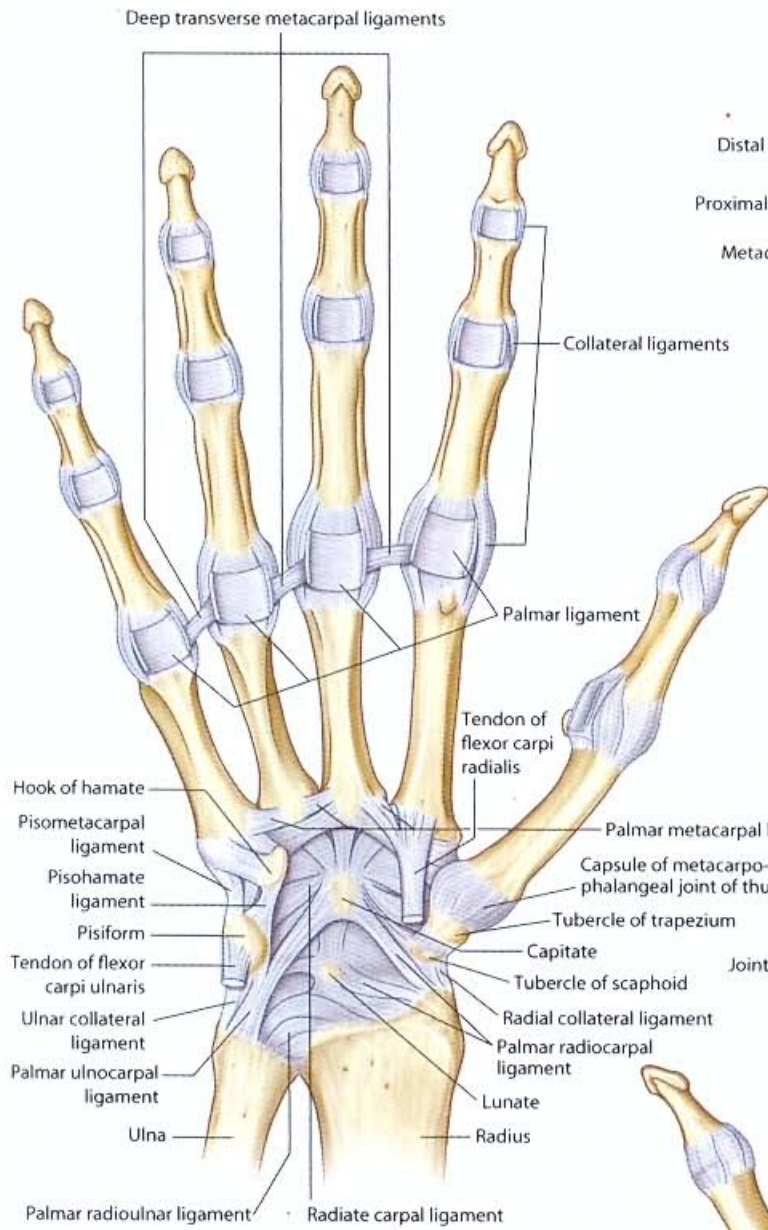


Imaging of the wrist joint, the carpal bones, and the hand.

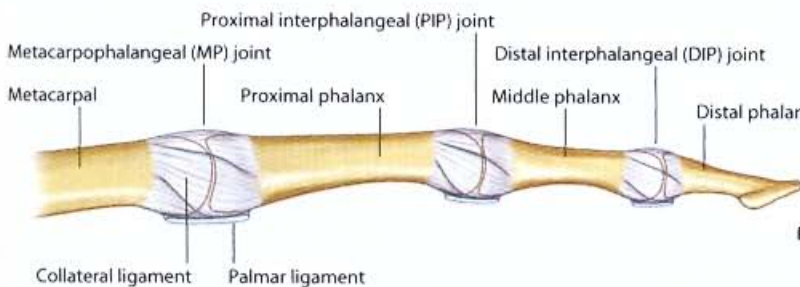
A. T1-weighted MR image in coronal plane

B. Radiograph, AP view

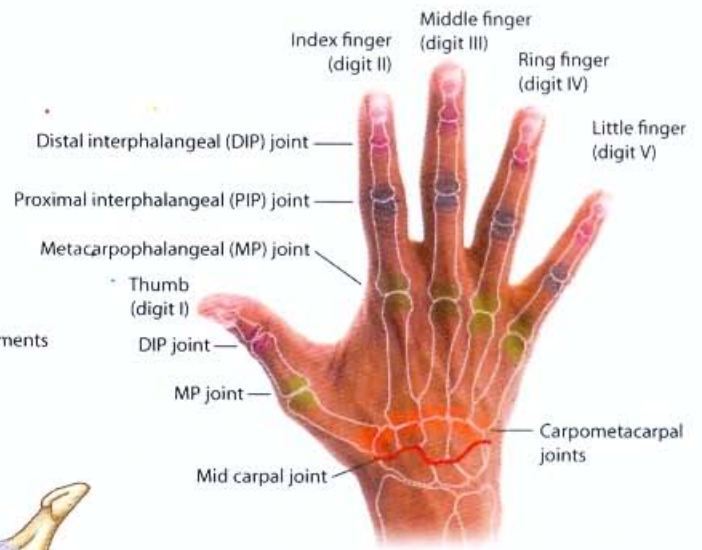




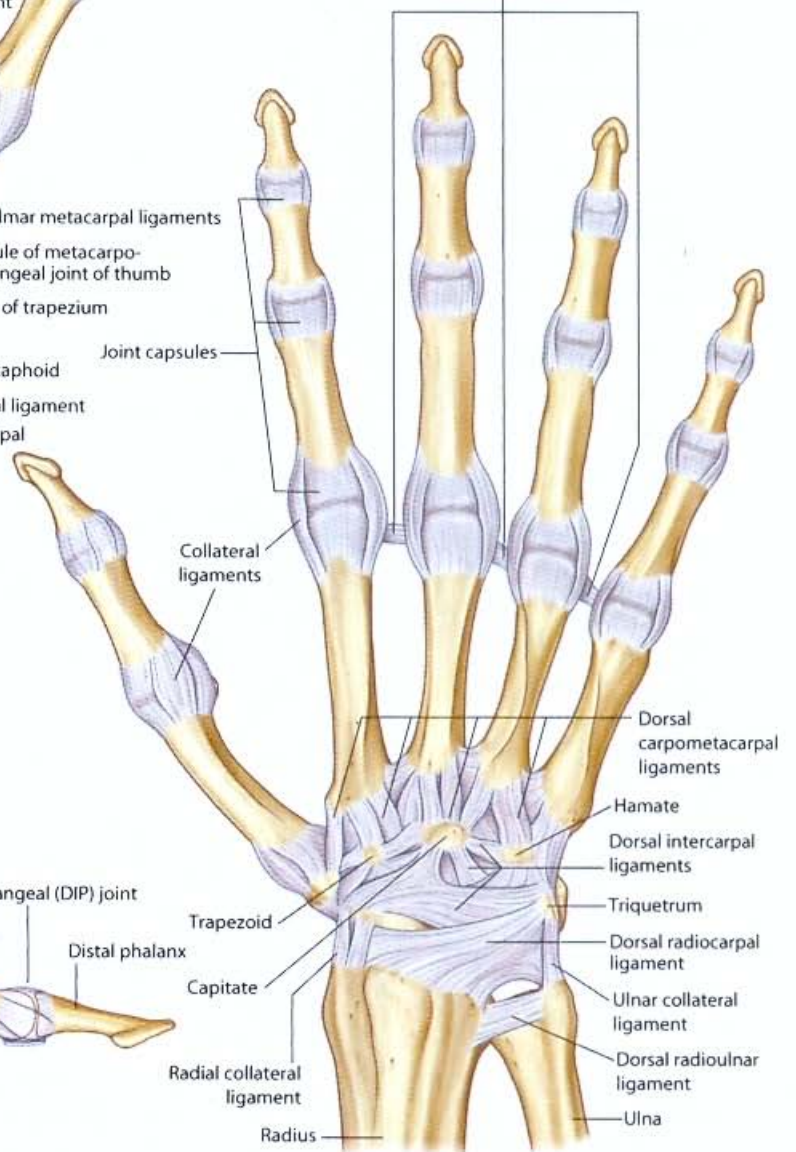
Ligaments of the hand (palmar view)



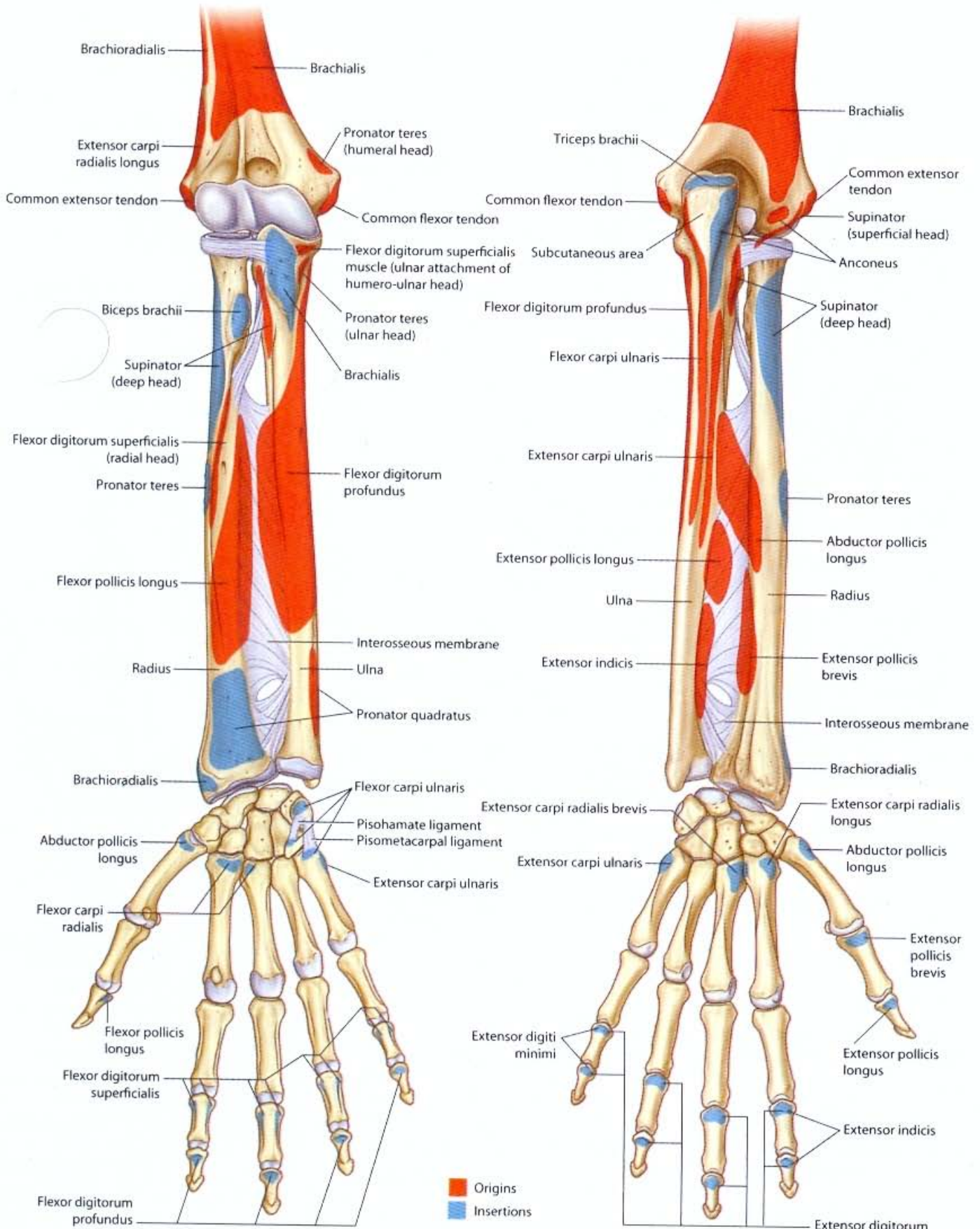
Interphalangeal joints (medial view)



Deep transverse metacarpal ligaments

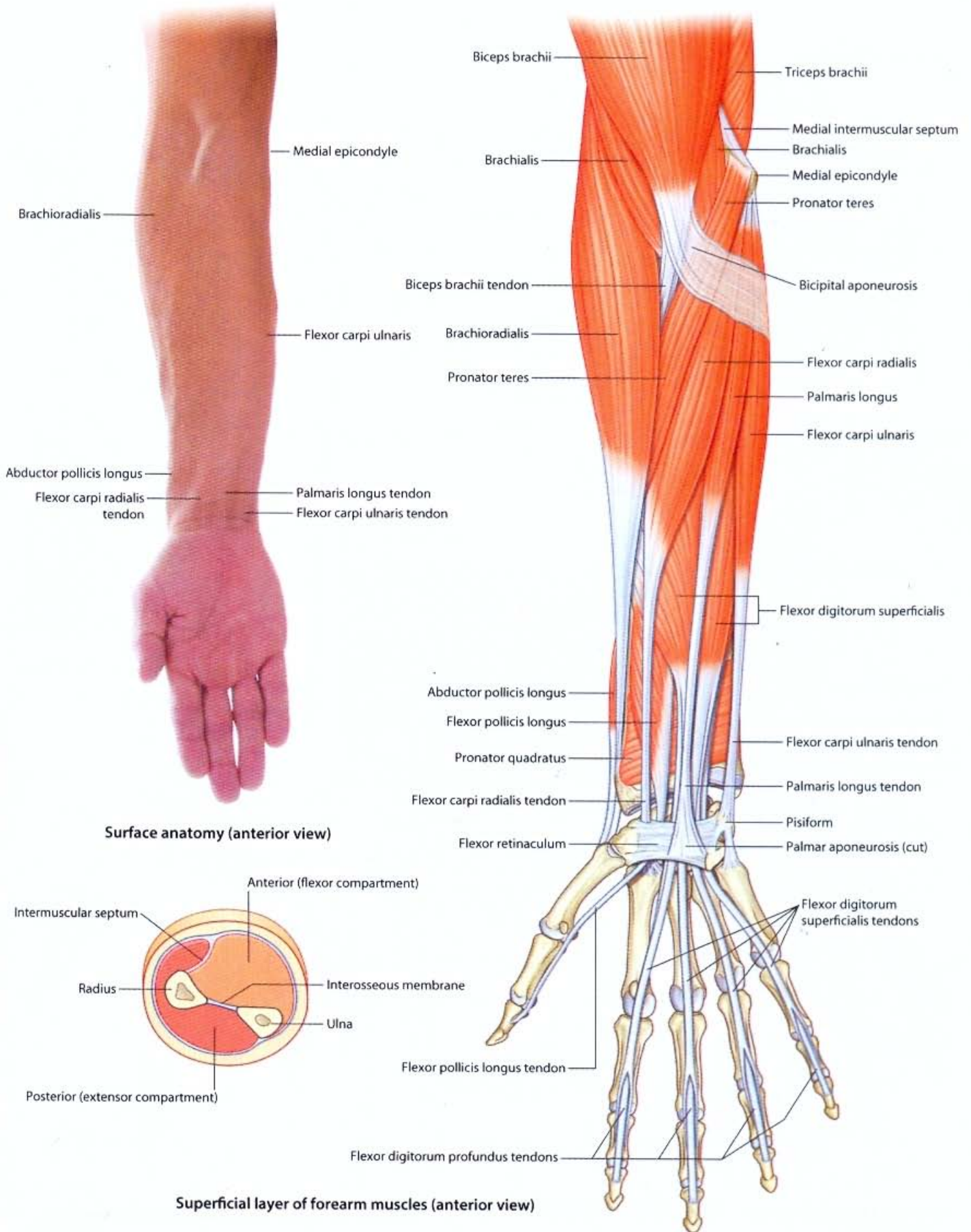


Ligaments of the hand (dorsal view)

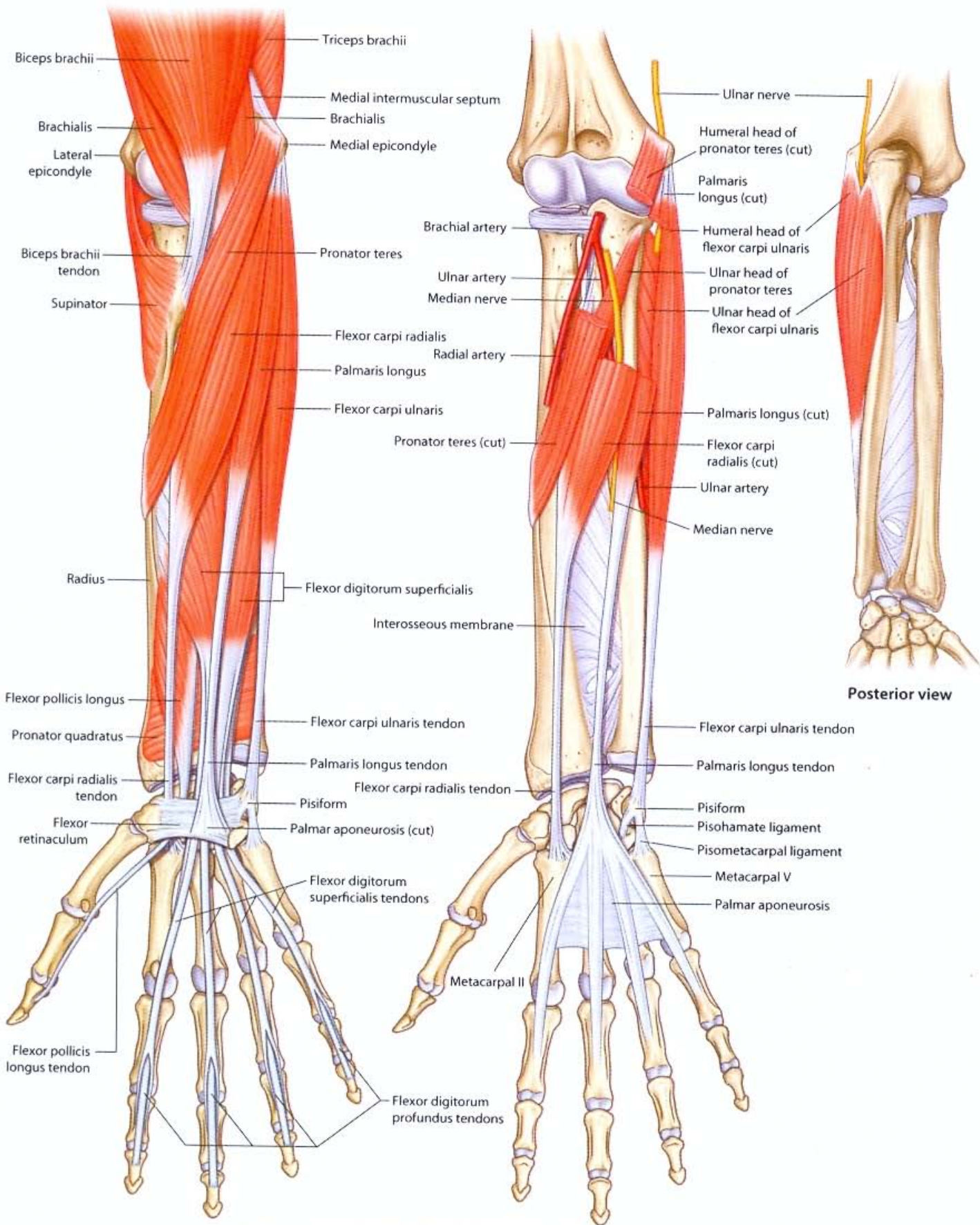


Muscle attachments of forearm (anterior view)

Muscle attachments of forearm (posterior view)

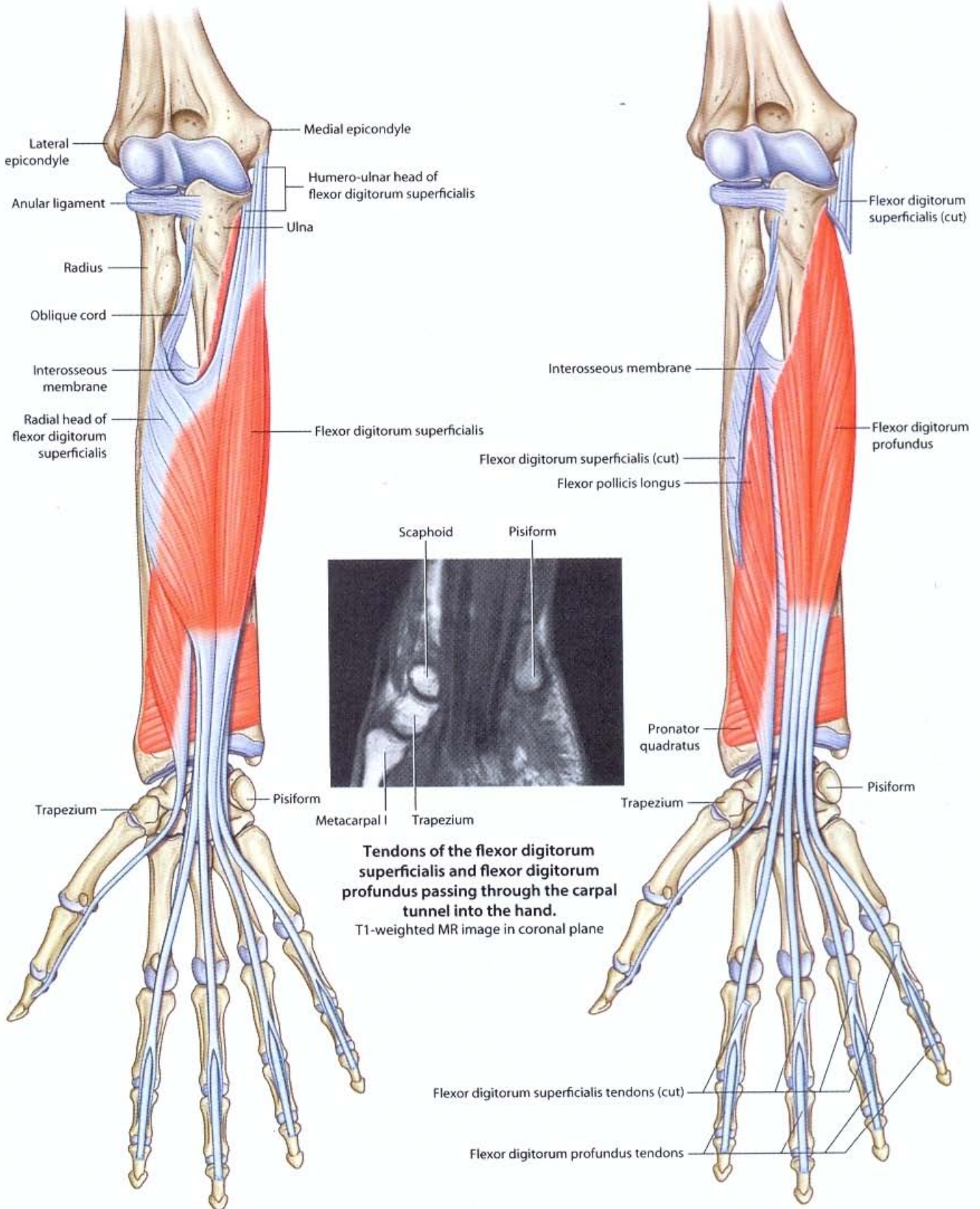


# UPPER LIMB • Anterior compartment of forearm: muscles



Superficial layer of forearm muscles (anterior view)

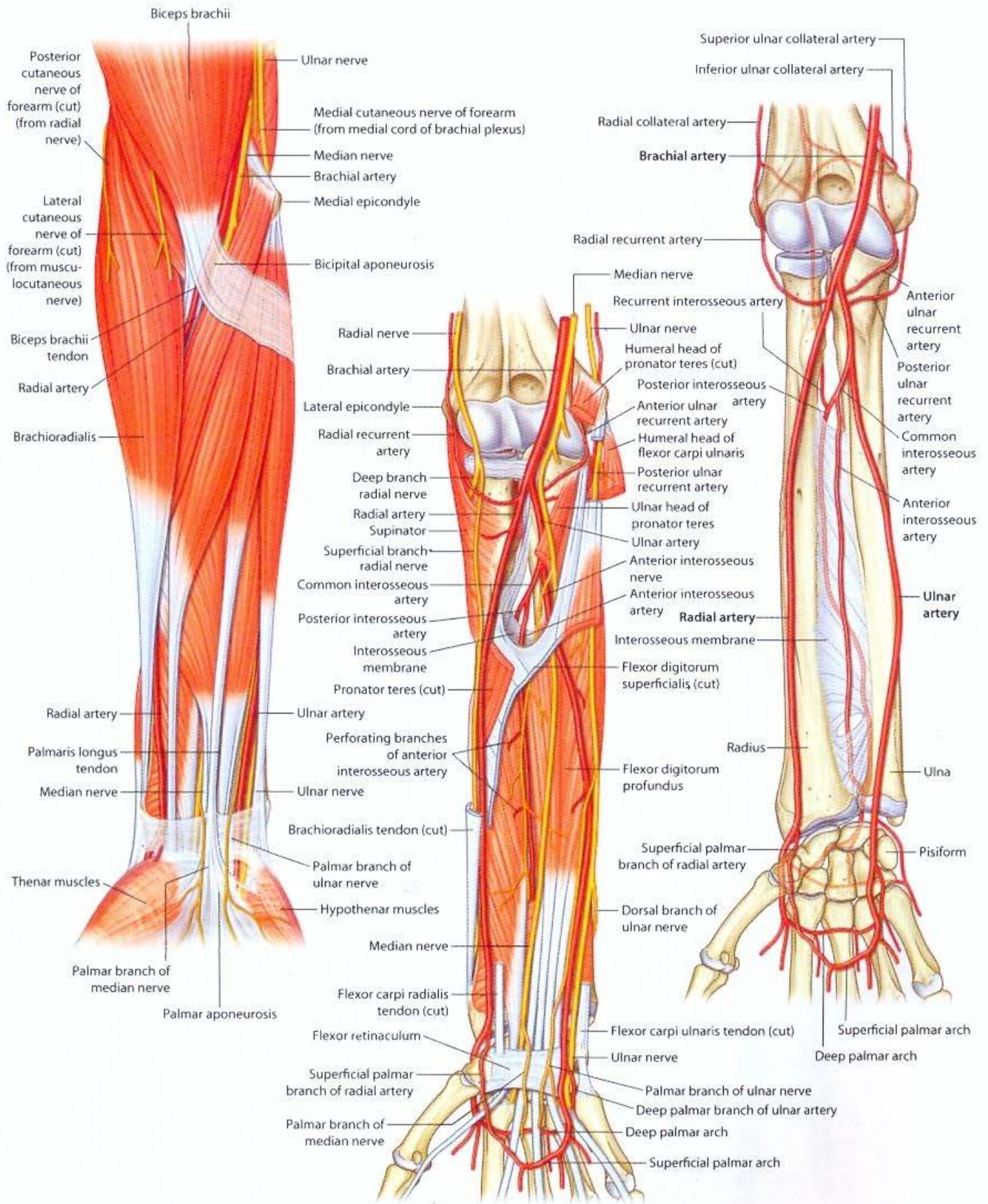




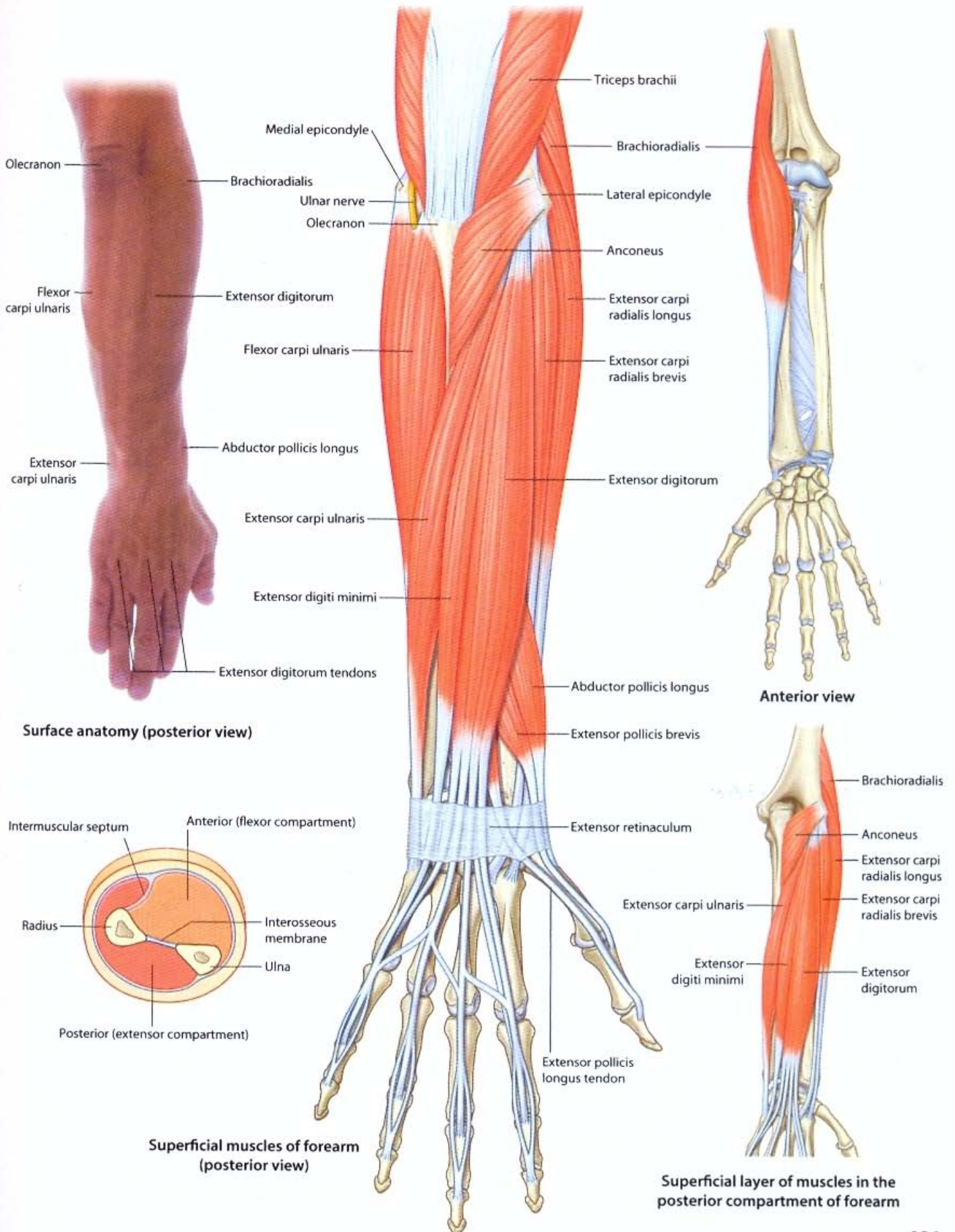
Intermediate layer of forearm muscles (anterior view)

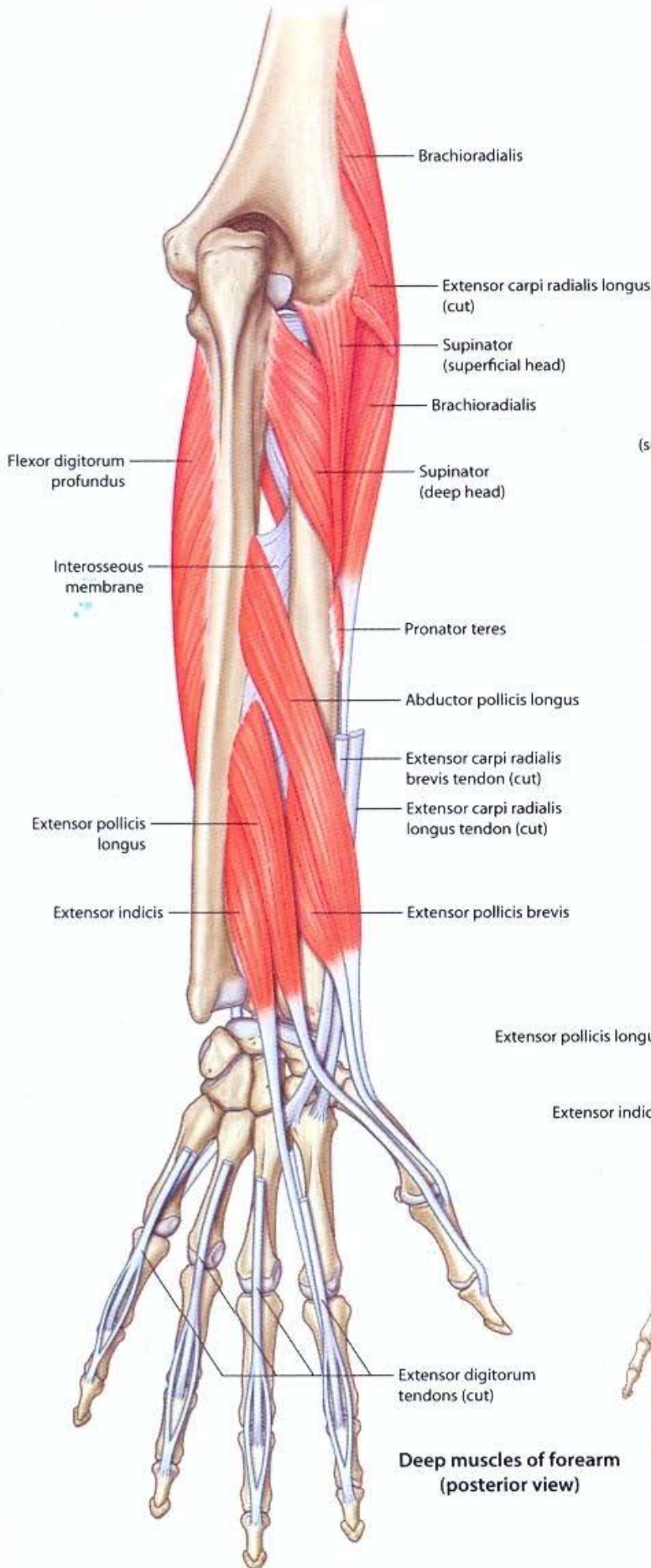
Deep layer of forearm muscles (anterior view)

# UPPER LIMB • Anterior compartment of forearm: arteries and nerves

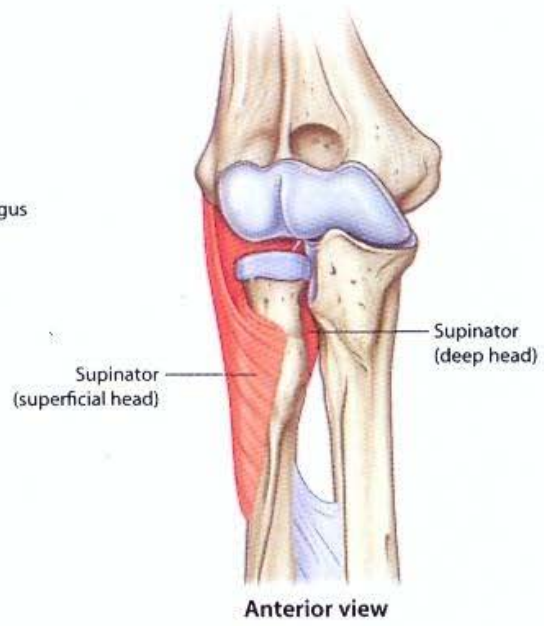


Arteries and nerves of forearm (anterior view)

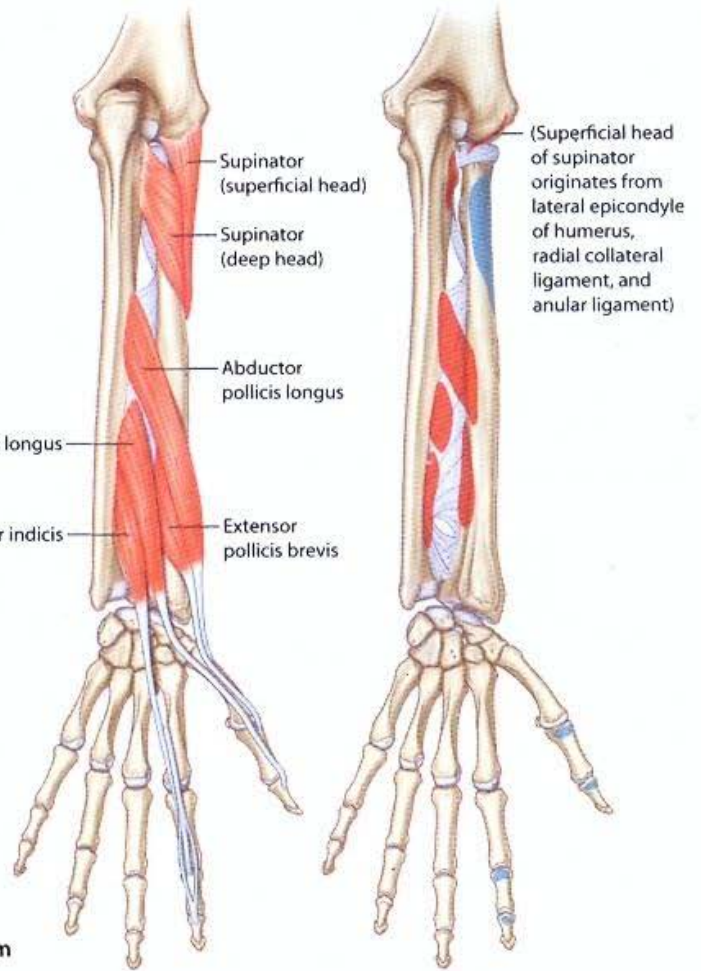




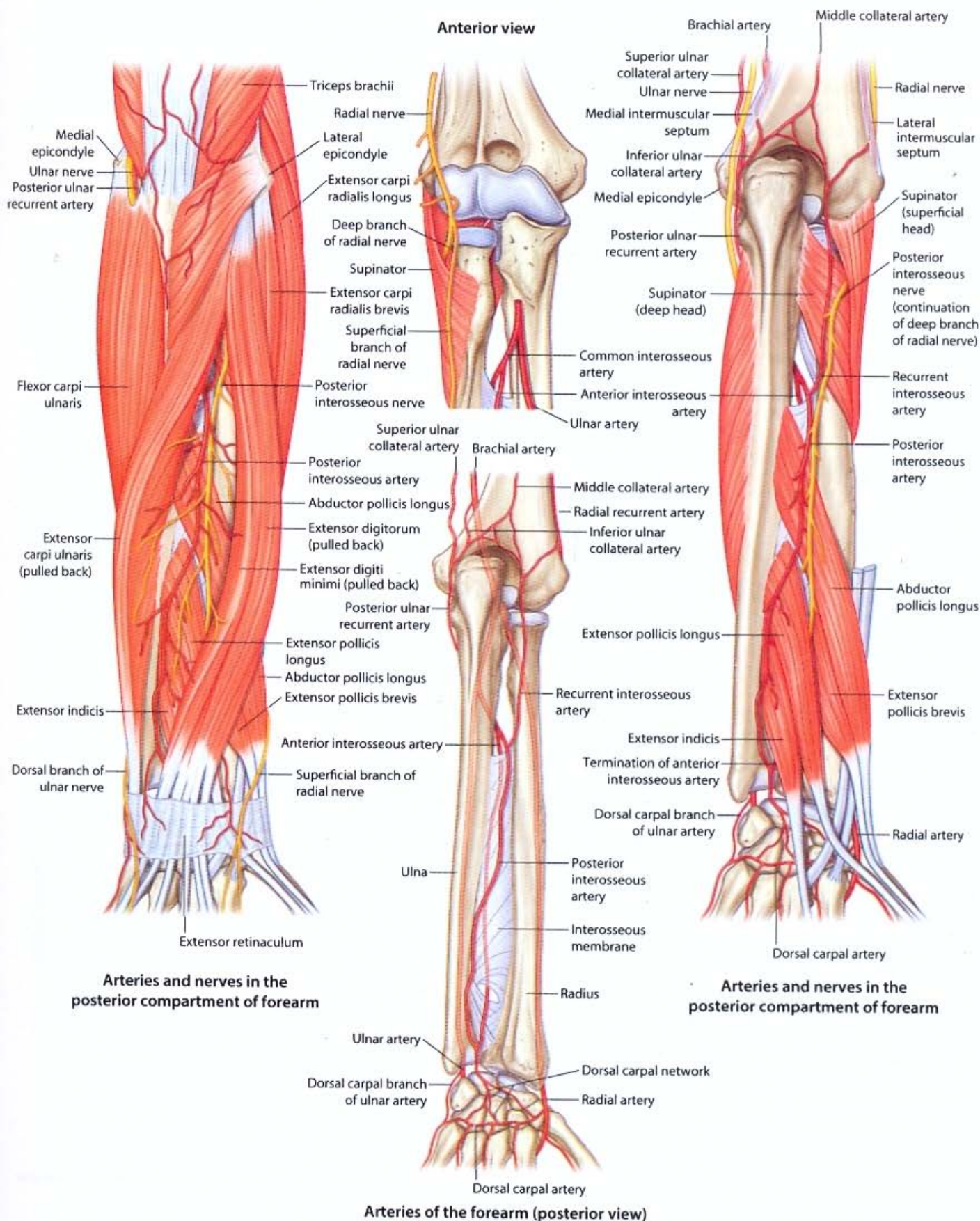
**Deep muscles of forearm (posterior view)**



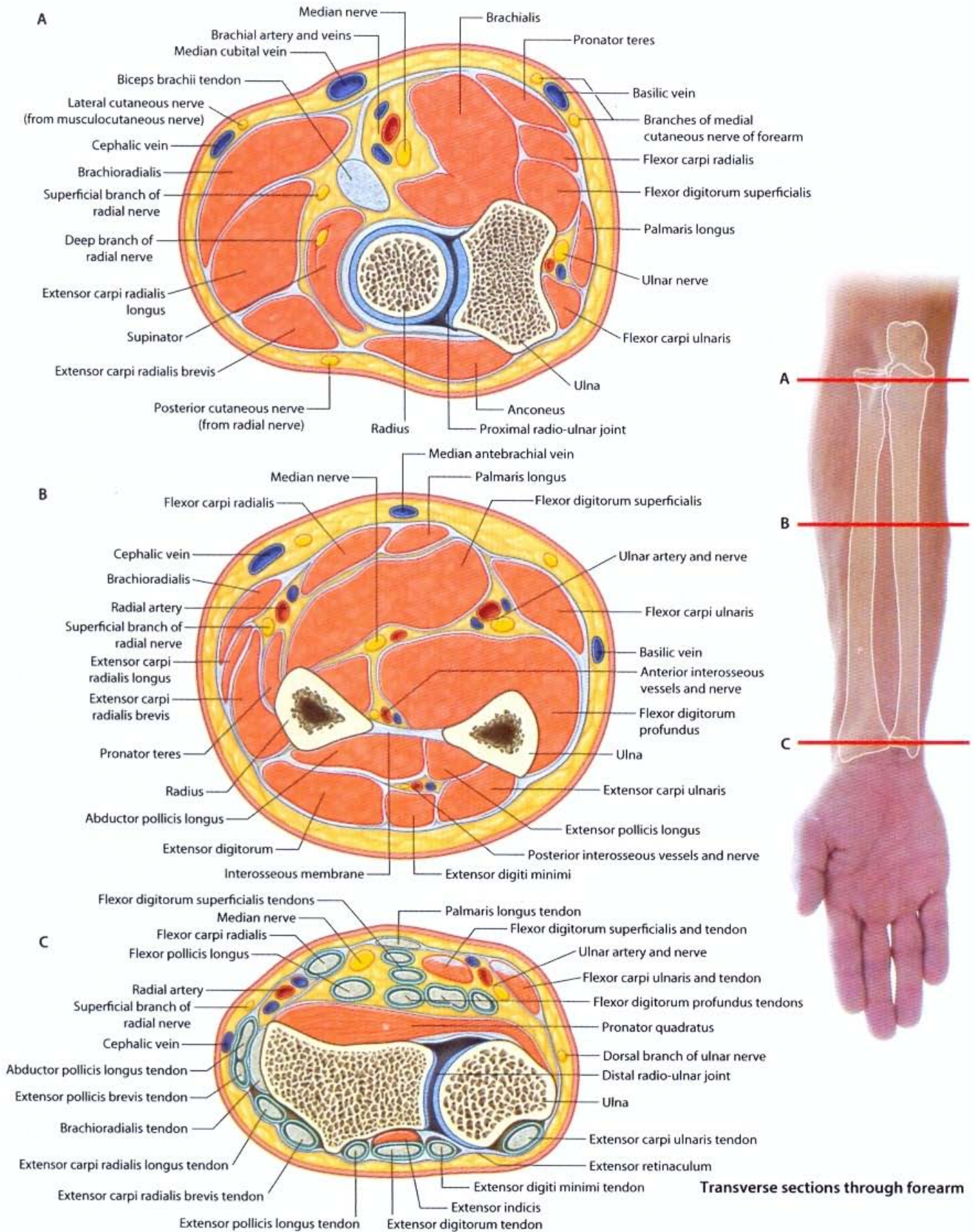
**Anterior view**




**Origin of deep layer of muscles in the posterior compartment of forearm**

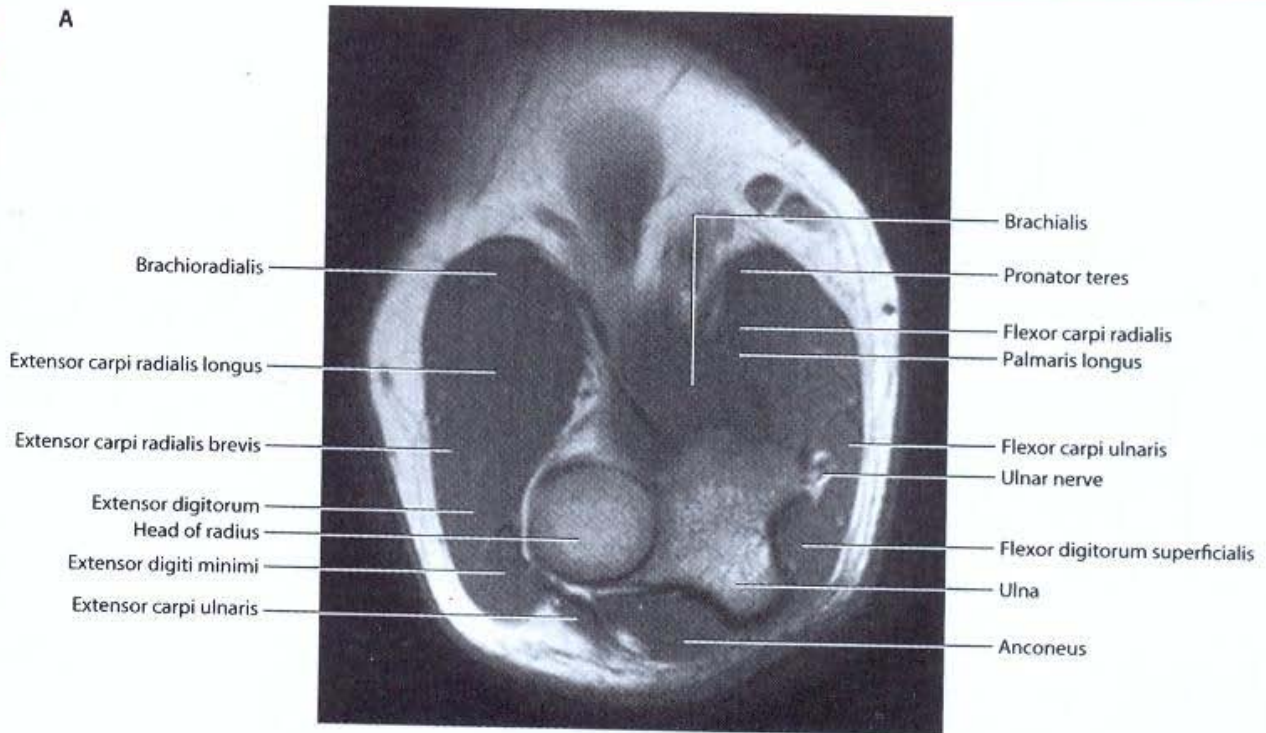


# UPPER LIMB • Transverse sections: forearm

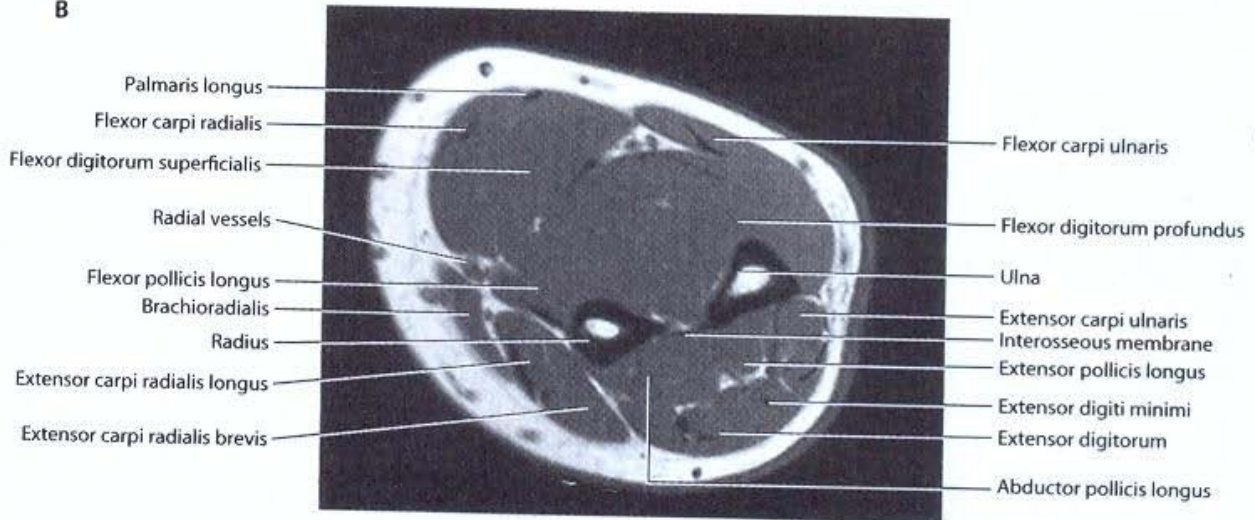




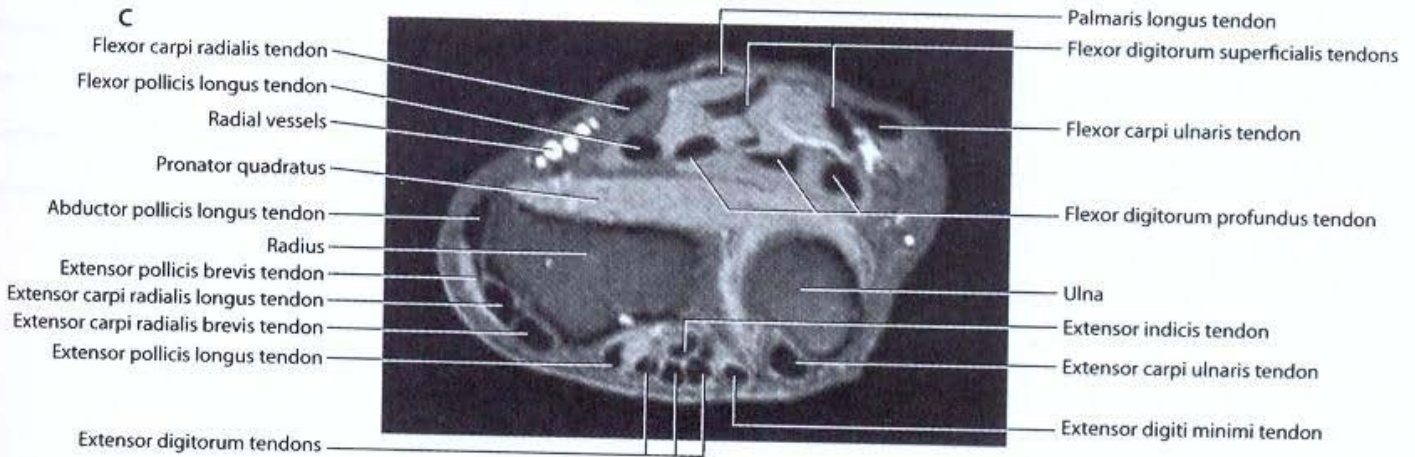
A



B



C



Transverse/axial sections through the forearm.

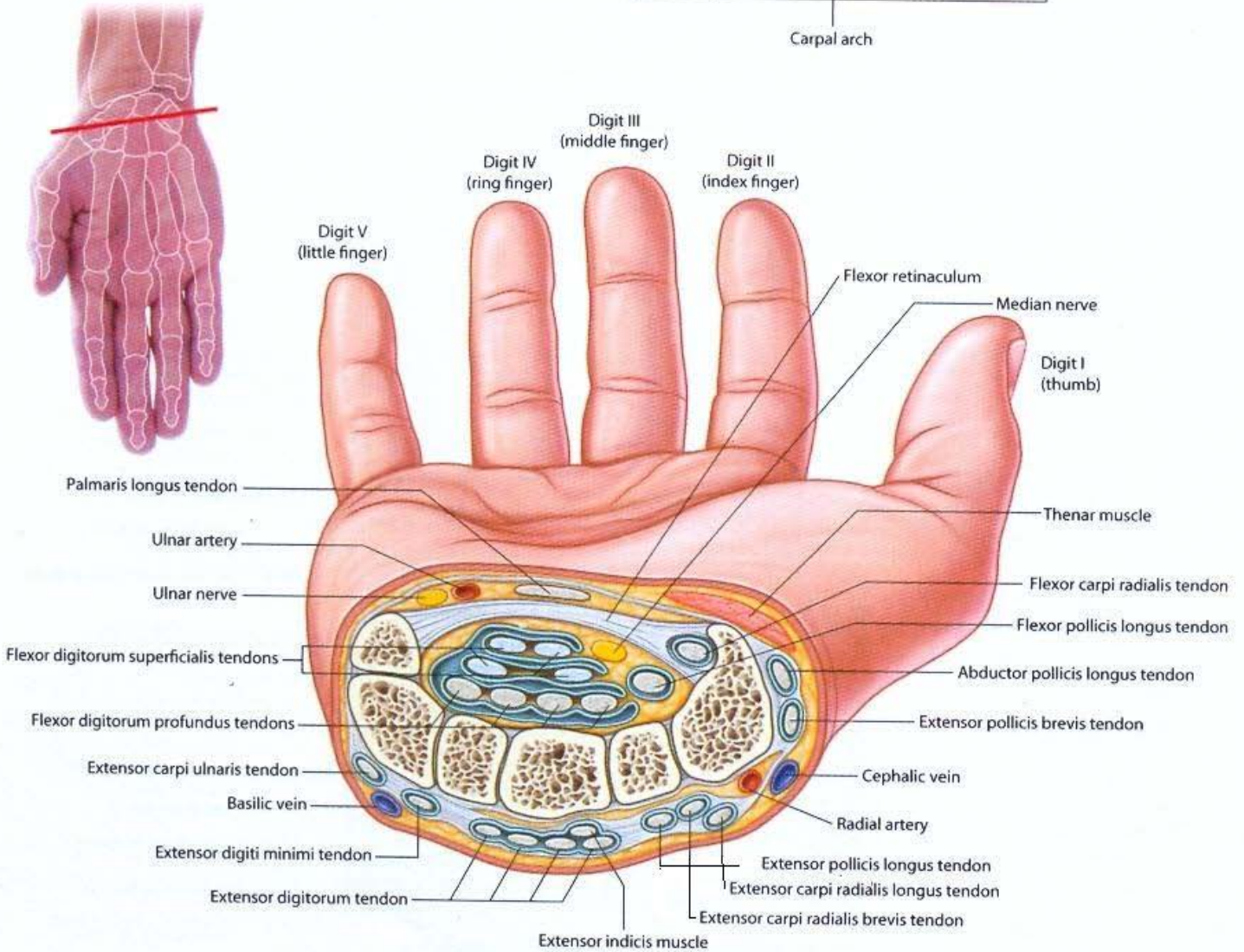
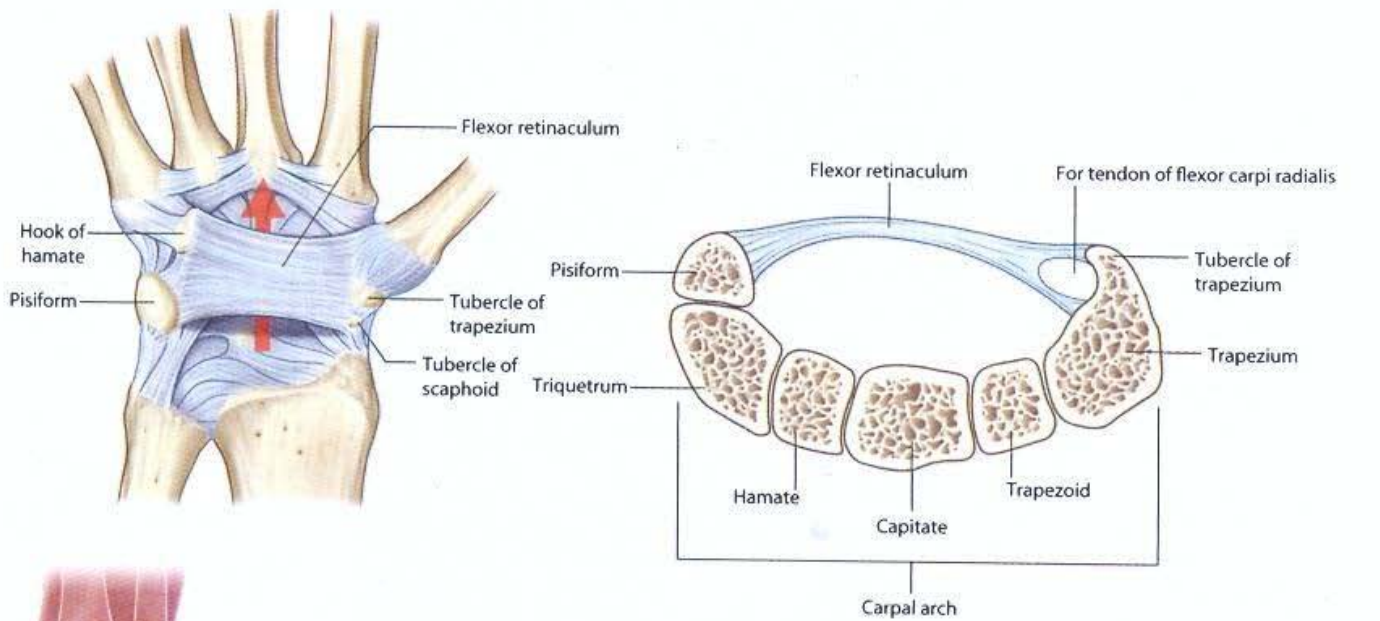
A. Proximal/upper forearm.

B. Middle forearm.

C. Distal/lower forearm.

T1-weighted MR image in axial plane

# UPPER LIMB • Carpal tunnel

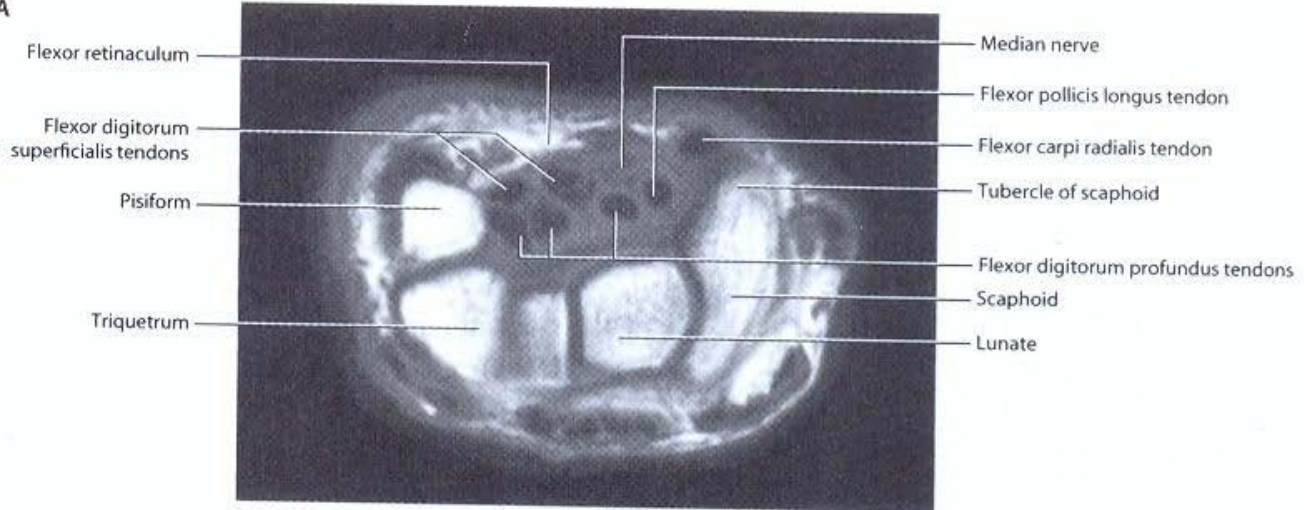


Carpal tunnel, structures and relations

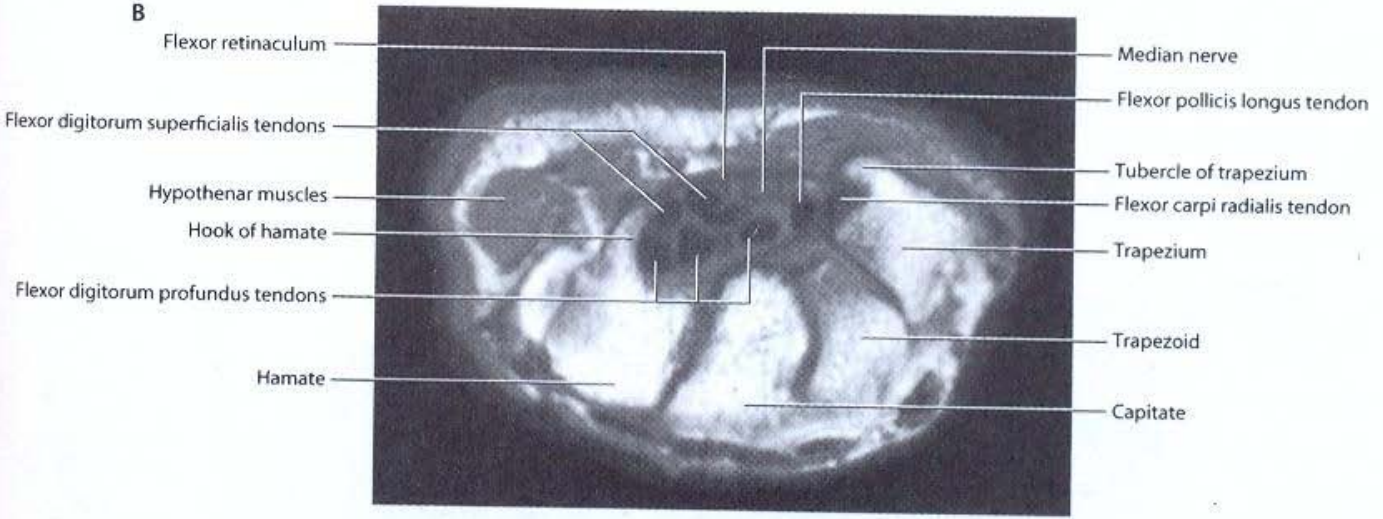




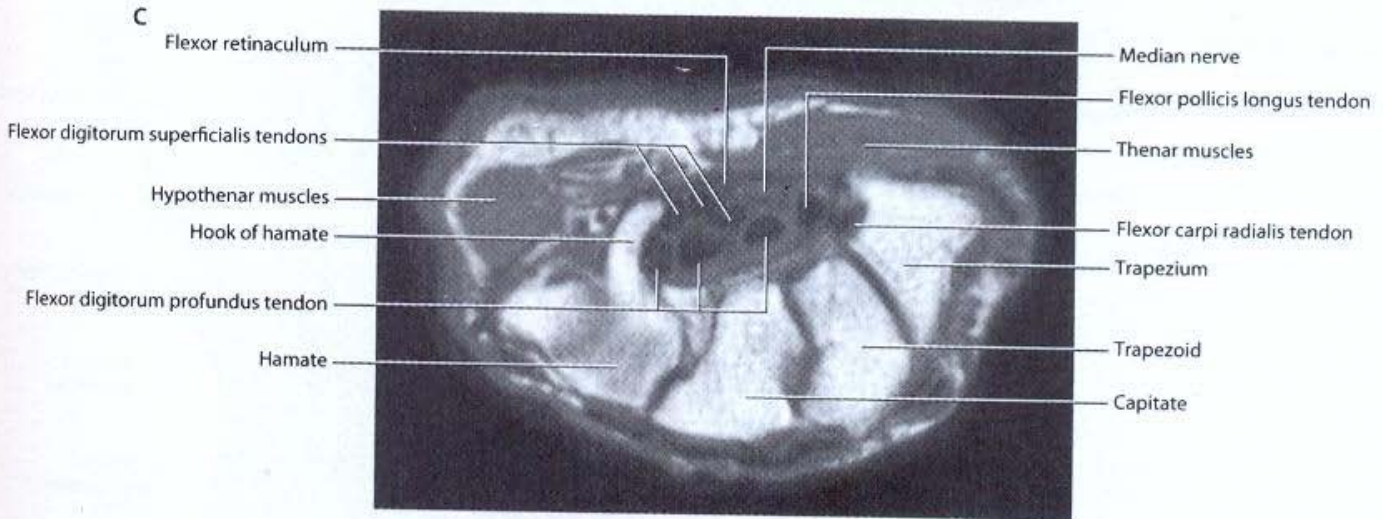
A



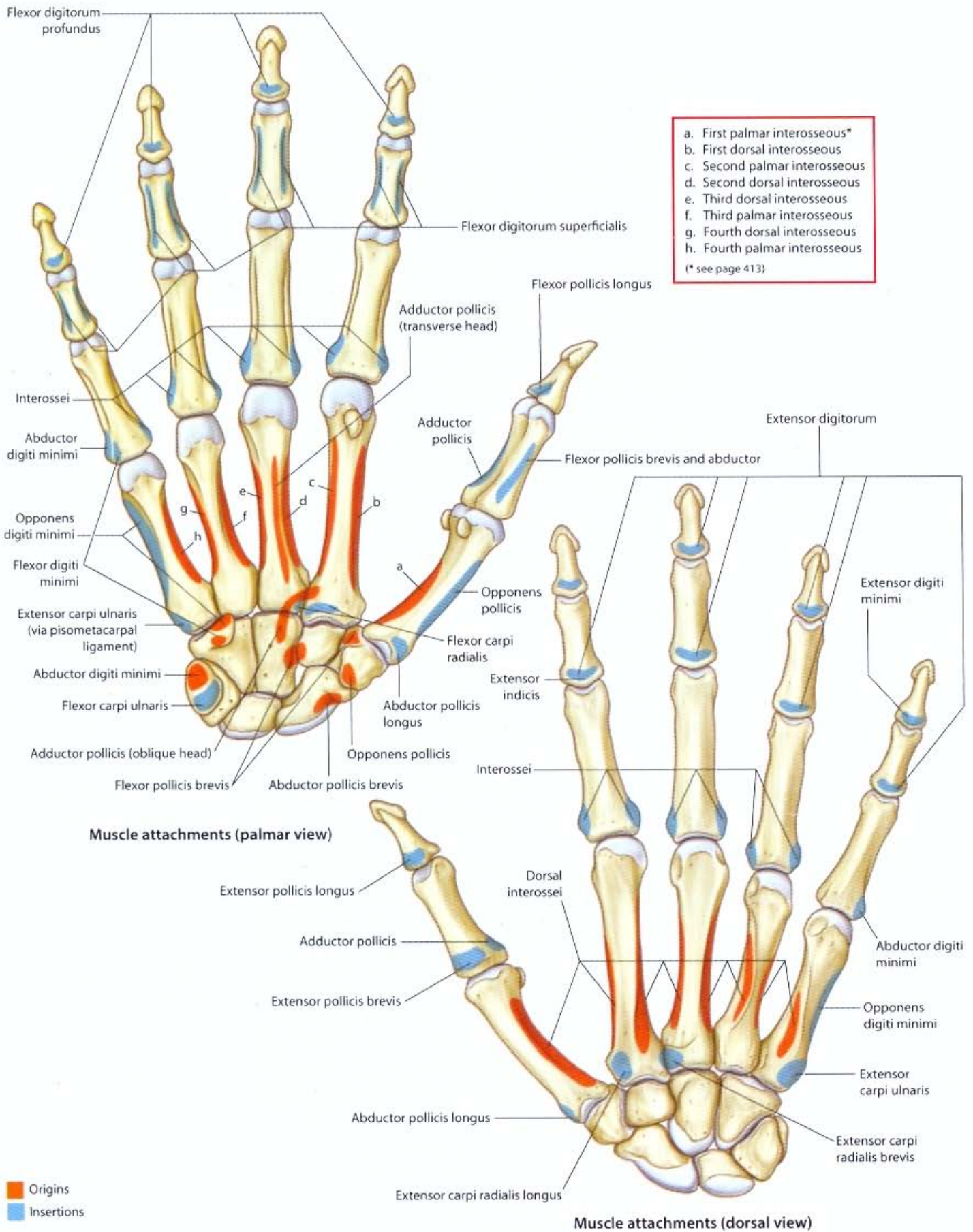
B

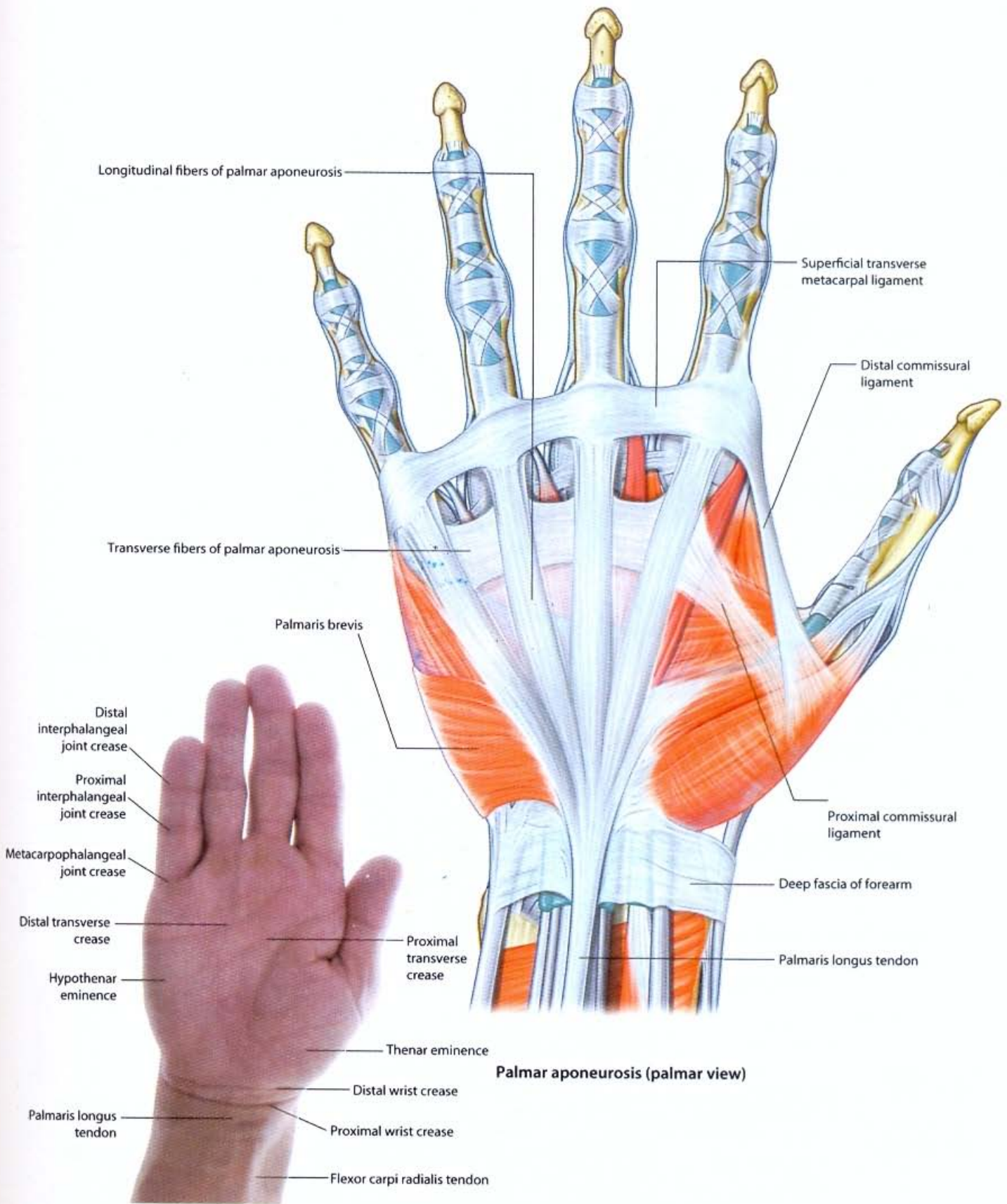


C



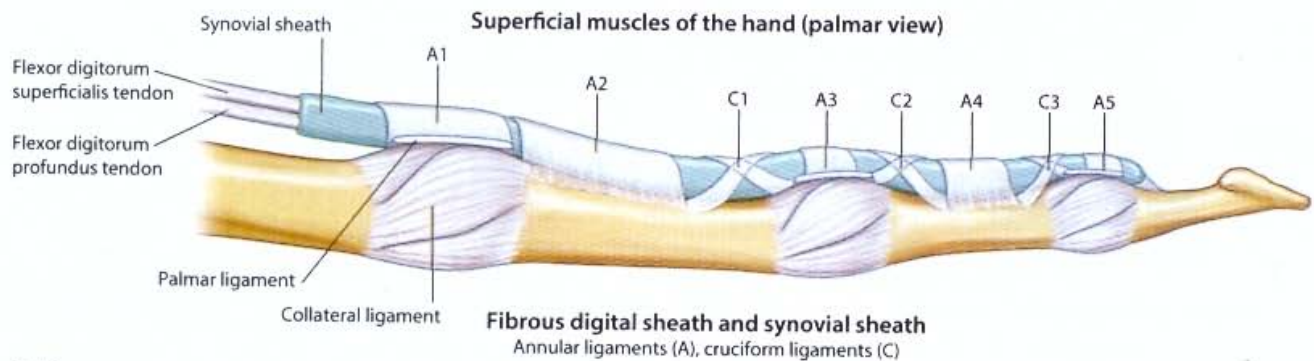
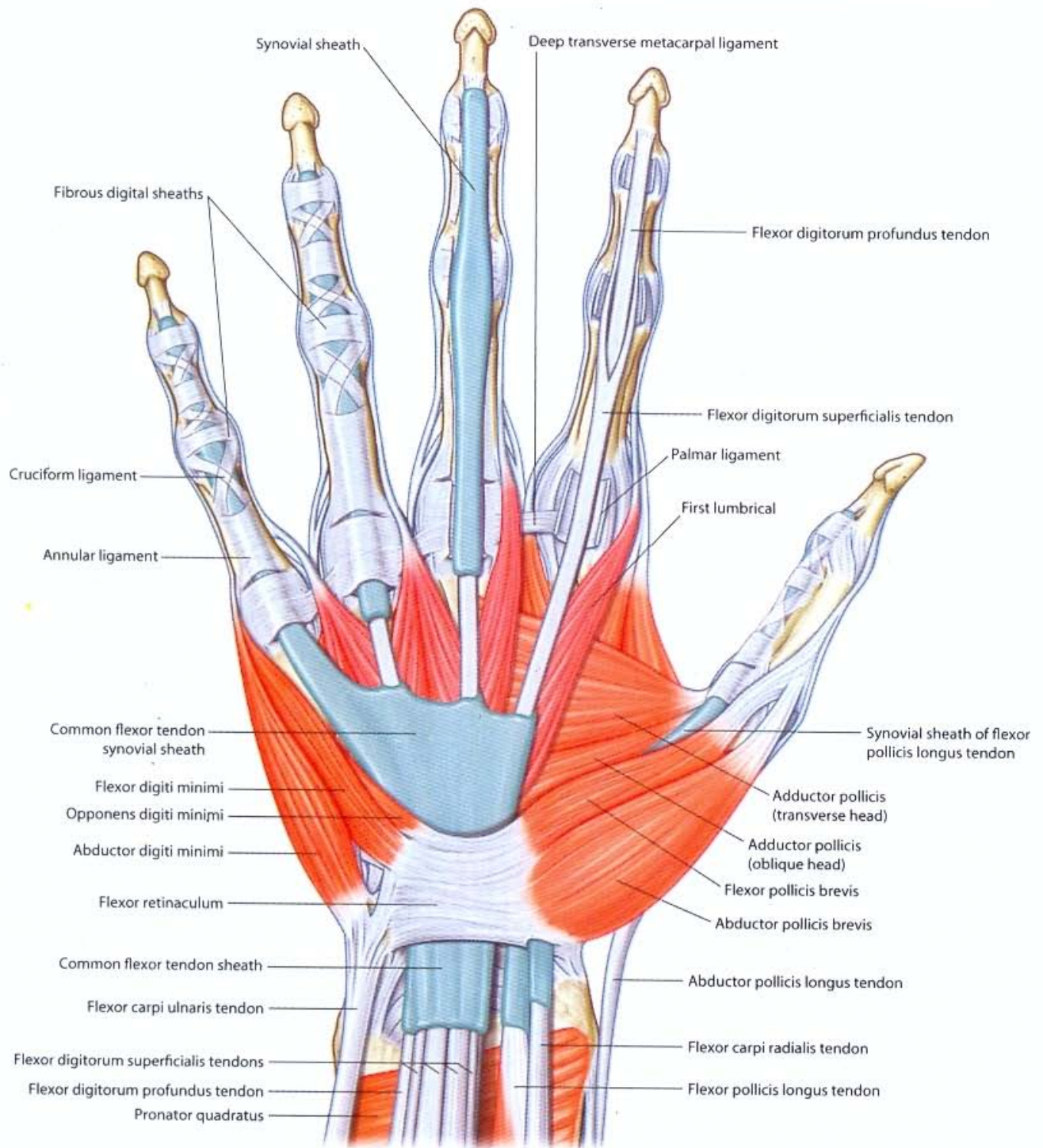
**Transverse/axial sections through the carpal tunnel.**  
**A. Proximal end of carpal tunnel.**  
**B. Middle portion of carpal tunnel.**  
**C. Distal portion of carpal tunnel.**  
 T1-weighted MR images in axial plane

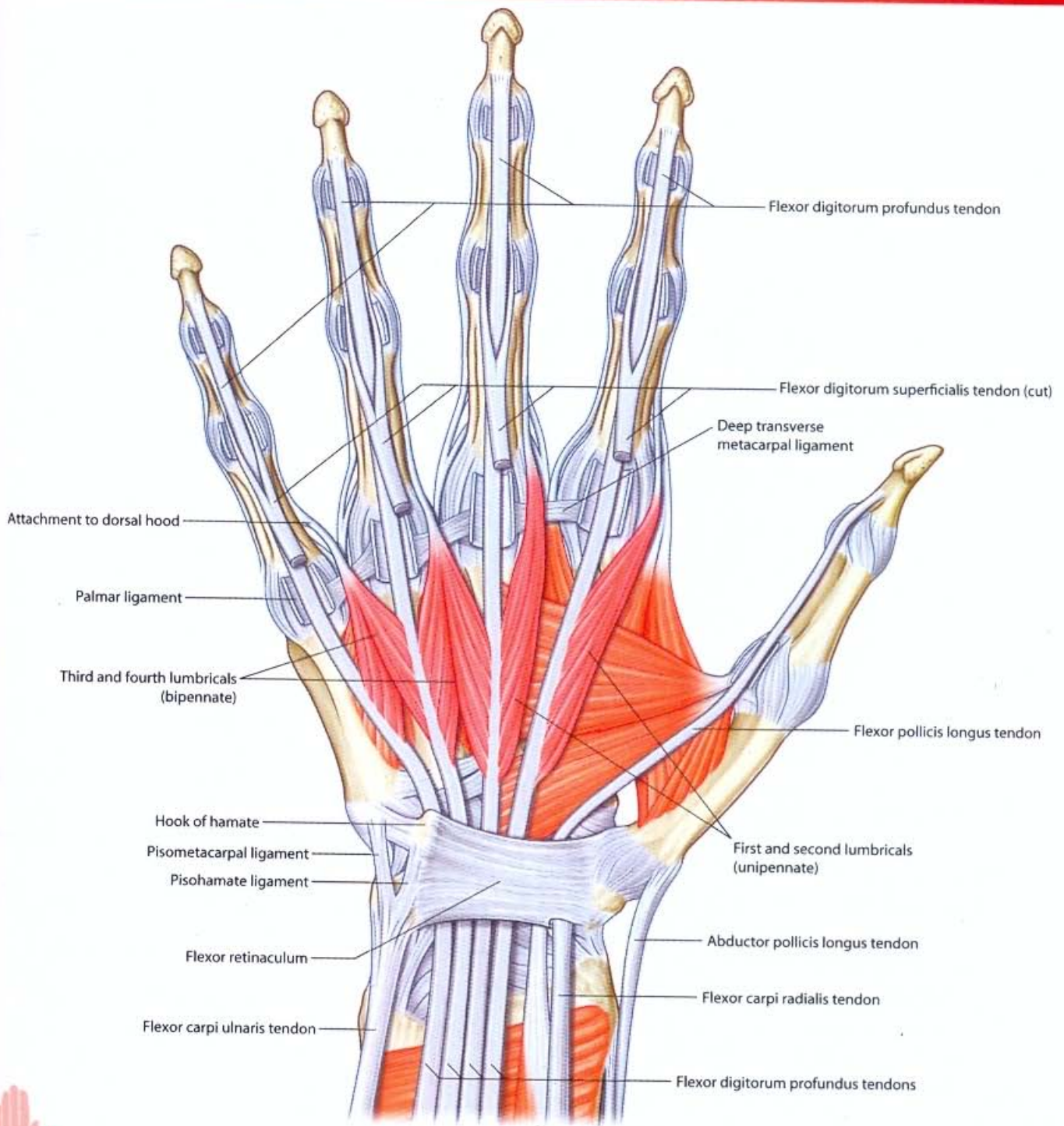




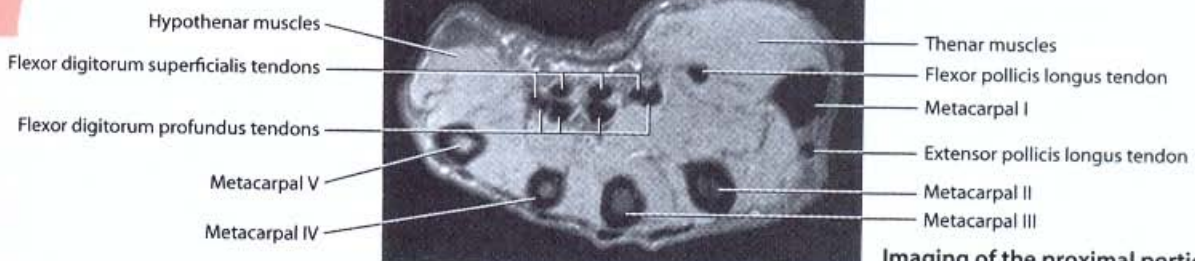
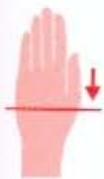
Palmar aponeurosis (palmar view)

Surface anatomy (palmar view)

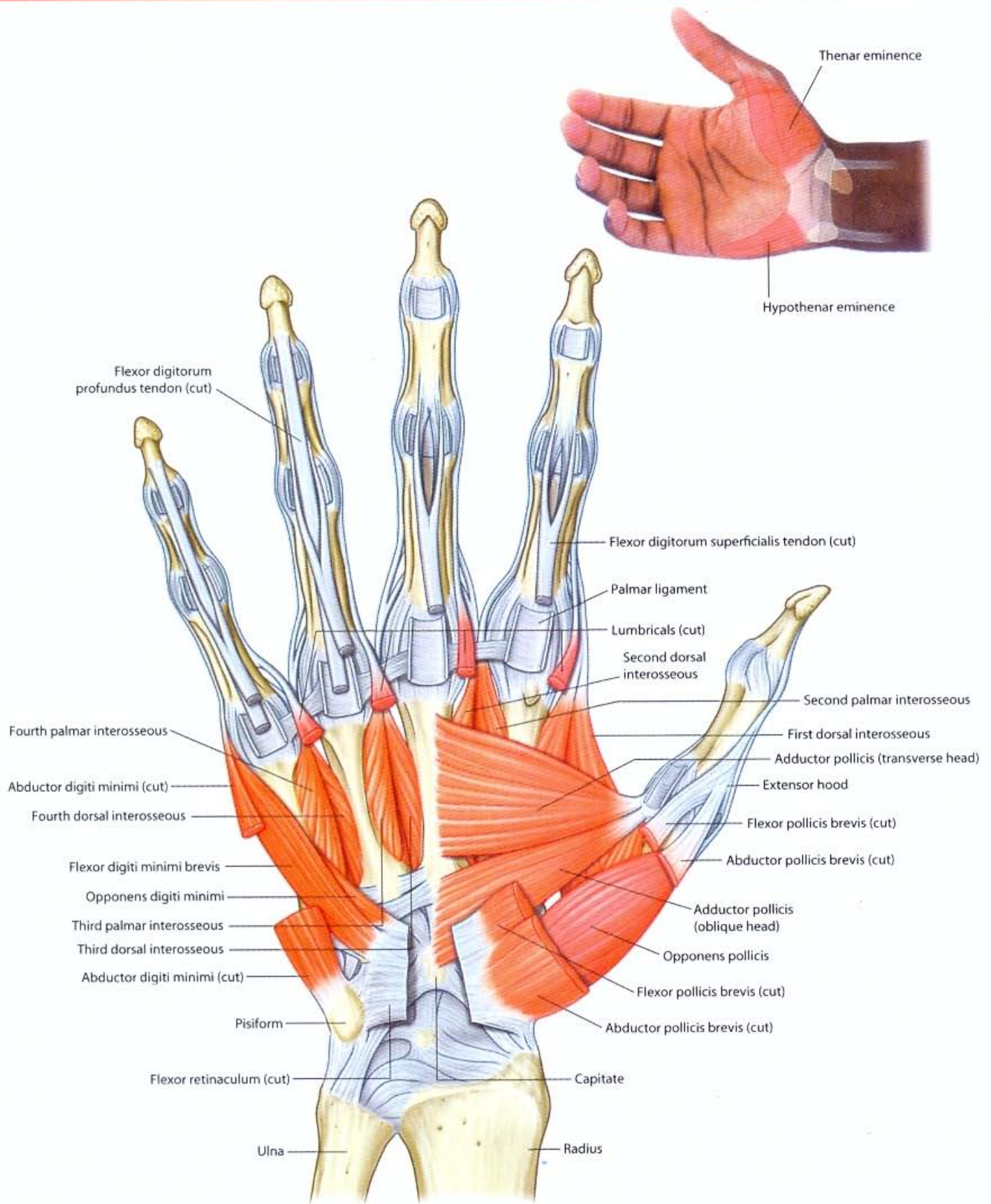




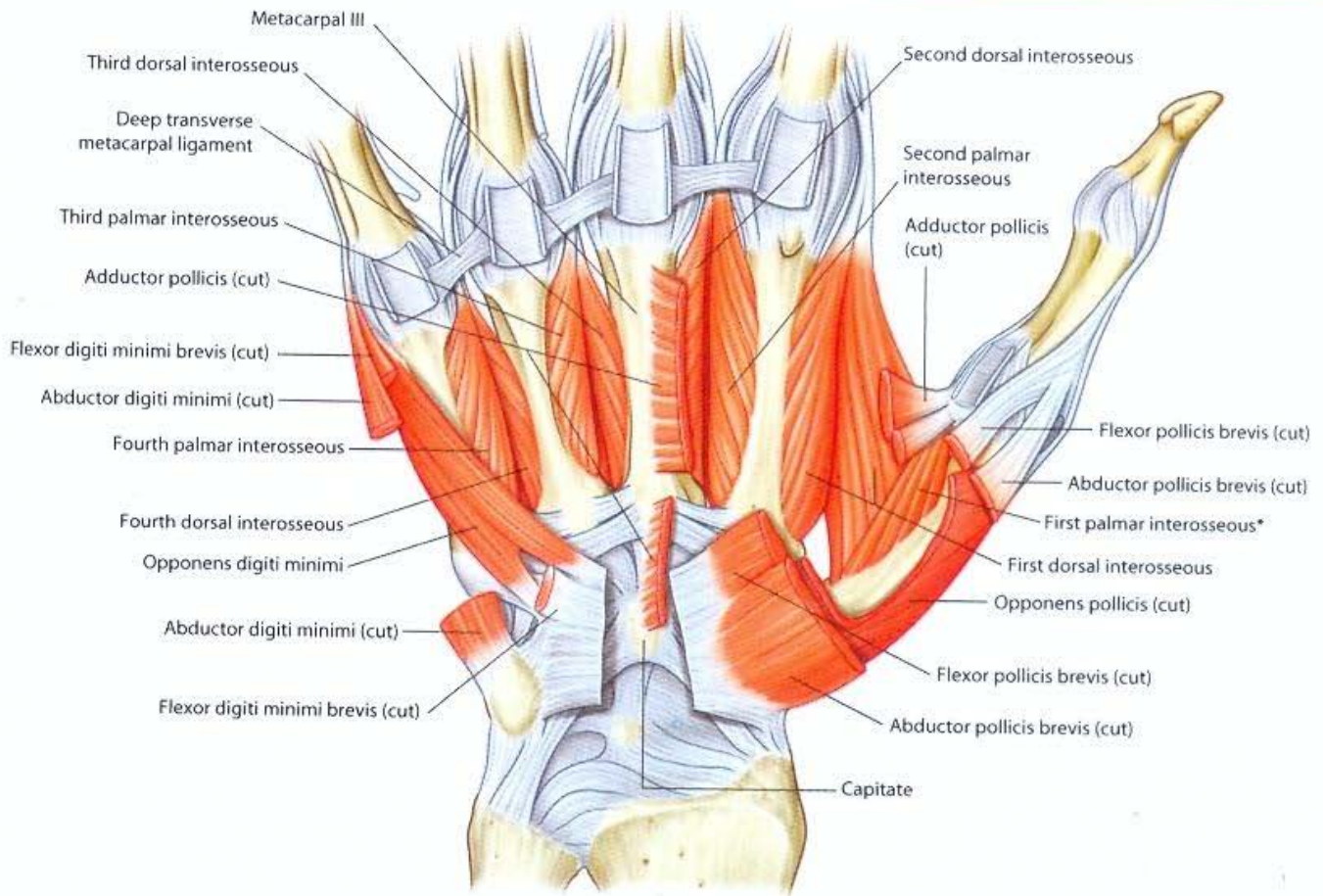
Lumbrical muscles (palmar view)



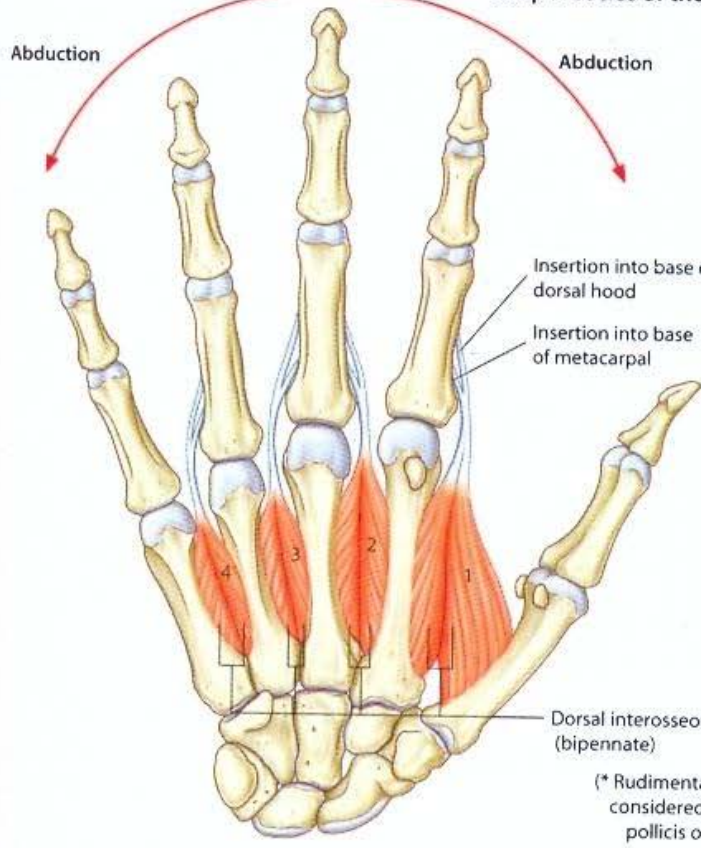
Imaging of the proximal portion of the hand. T1-weighted MR image in axial plane



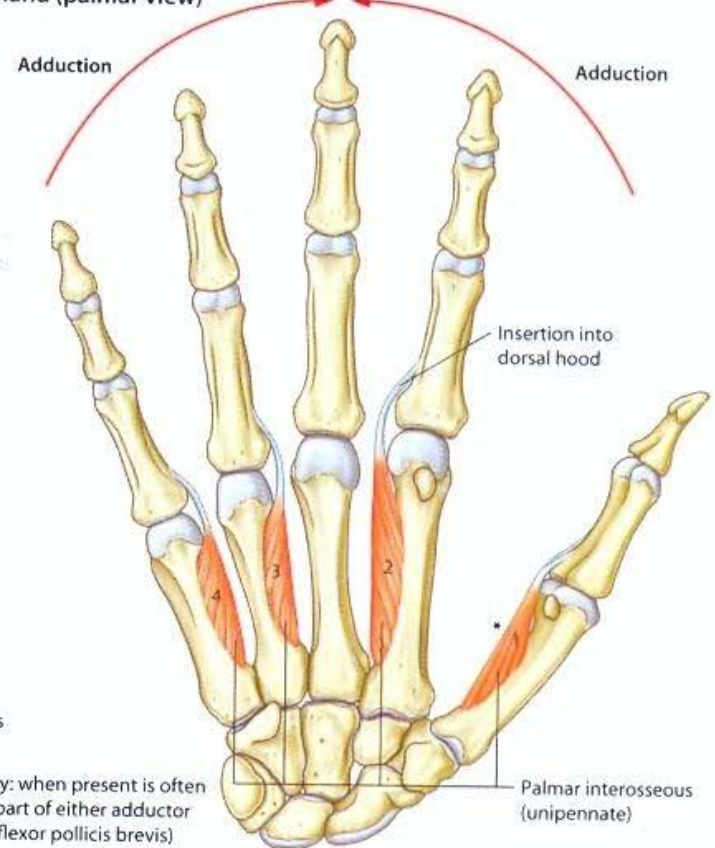
**Deep muscles of the hand (palmar view)**



Deep muscles of the hand (palmar view)

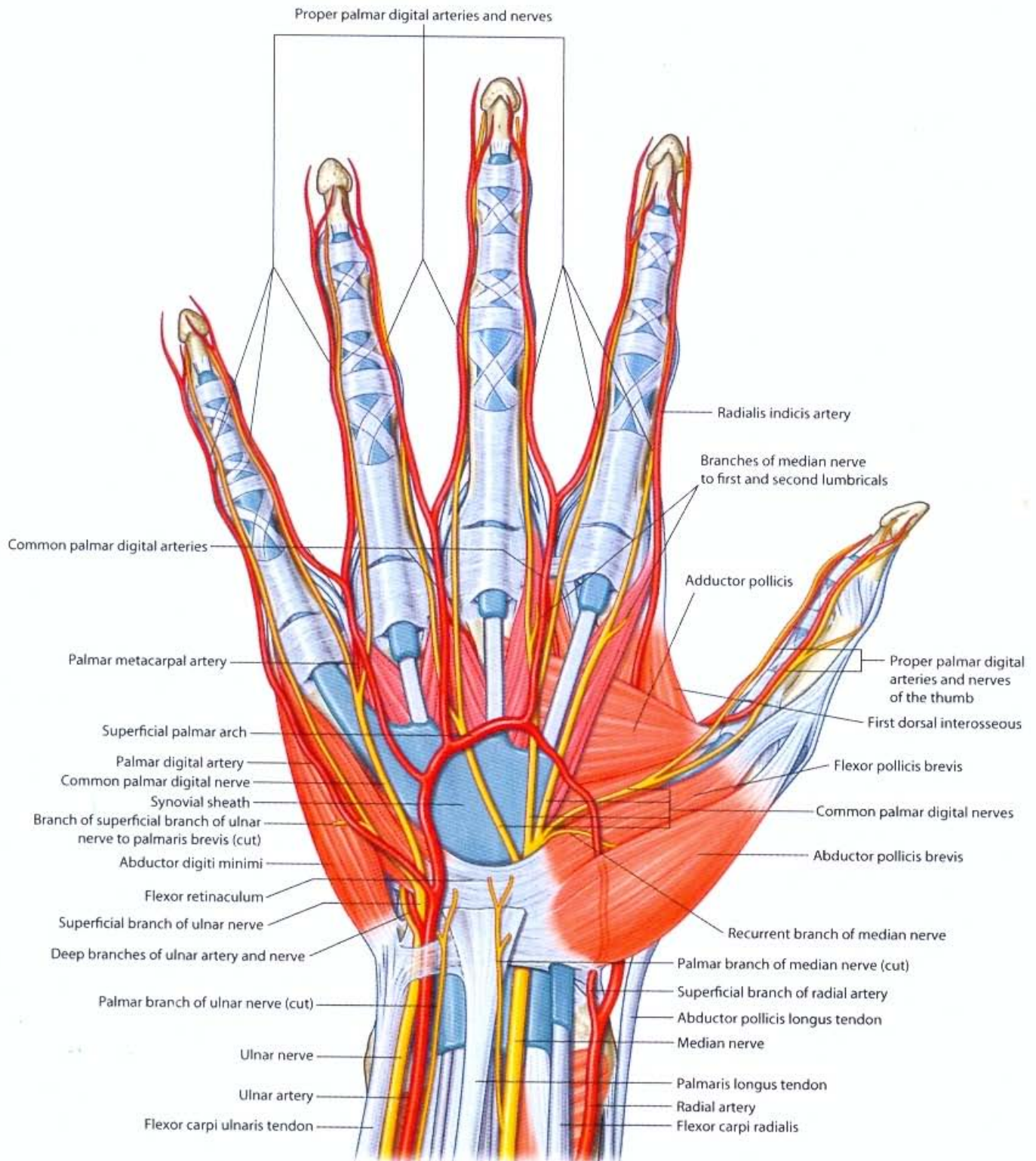


Dorsal interossei (palmar view)



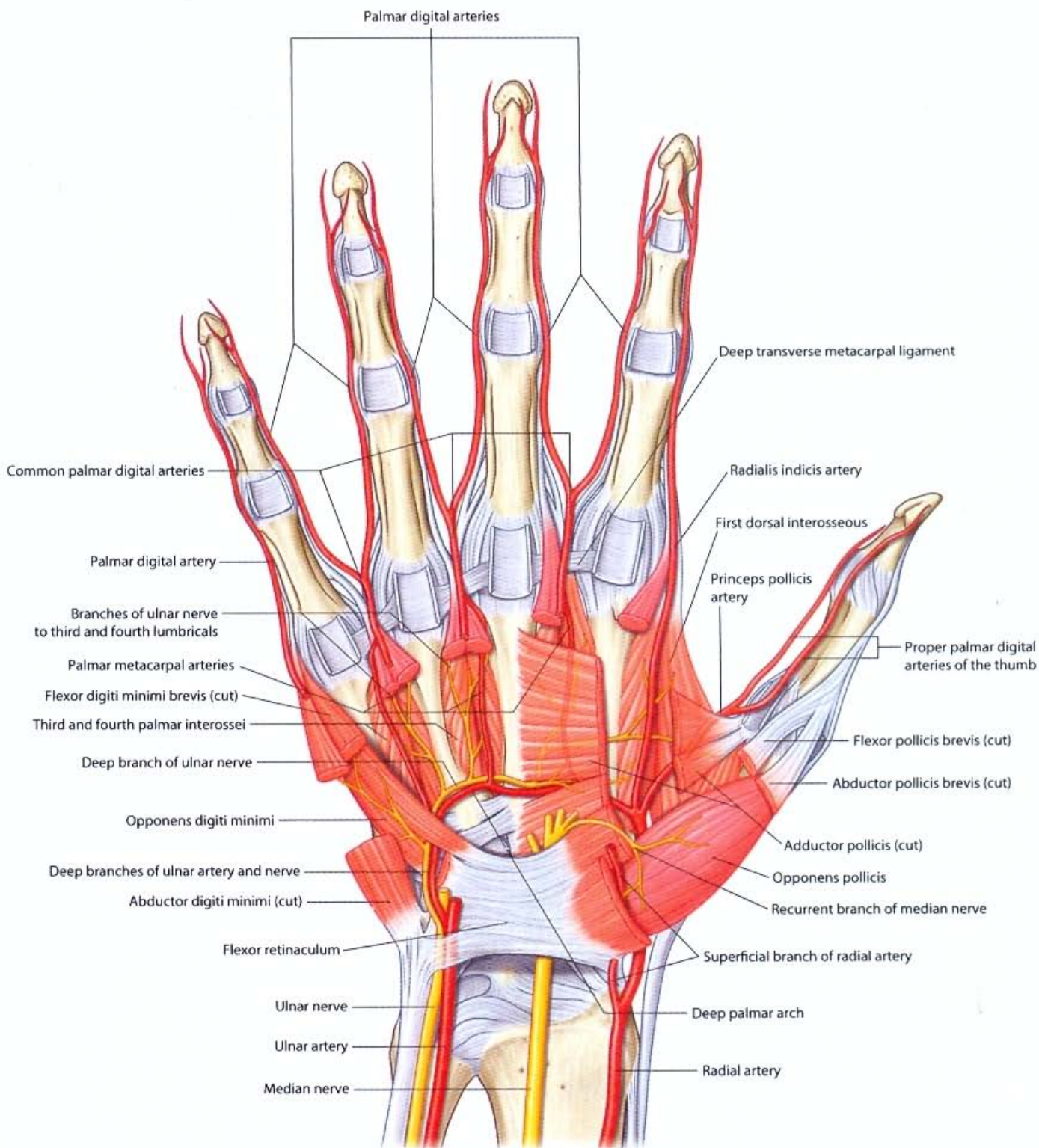
Palmar interossei (palmar view)

(\* Rudimentary: when present is often considered part of either adductor pollicis or flexor pollicis brevis)

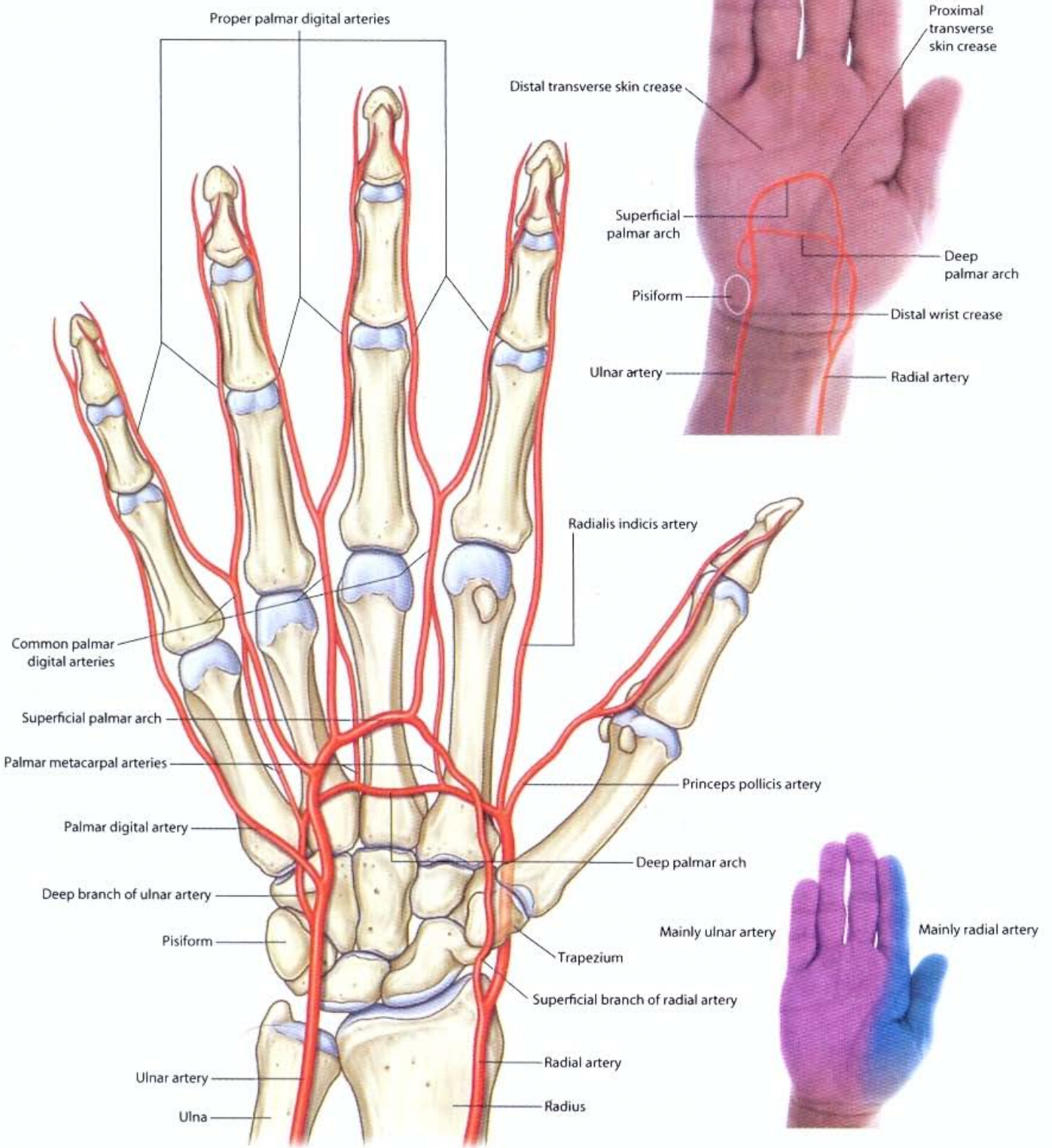


**Superficial arteries and nerves of the hand (palmar view)**

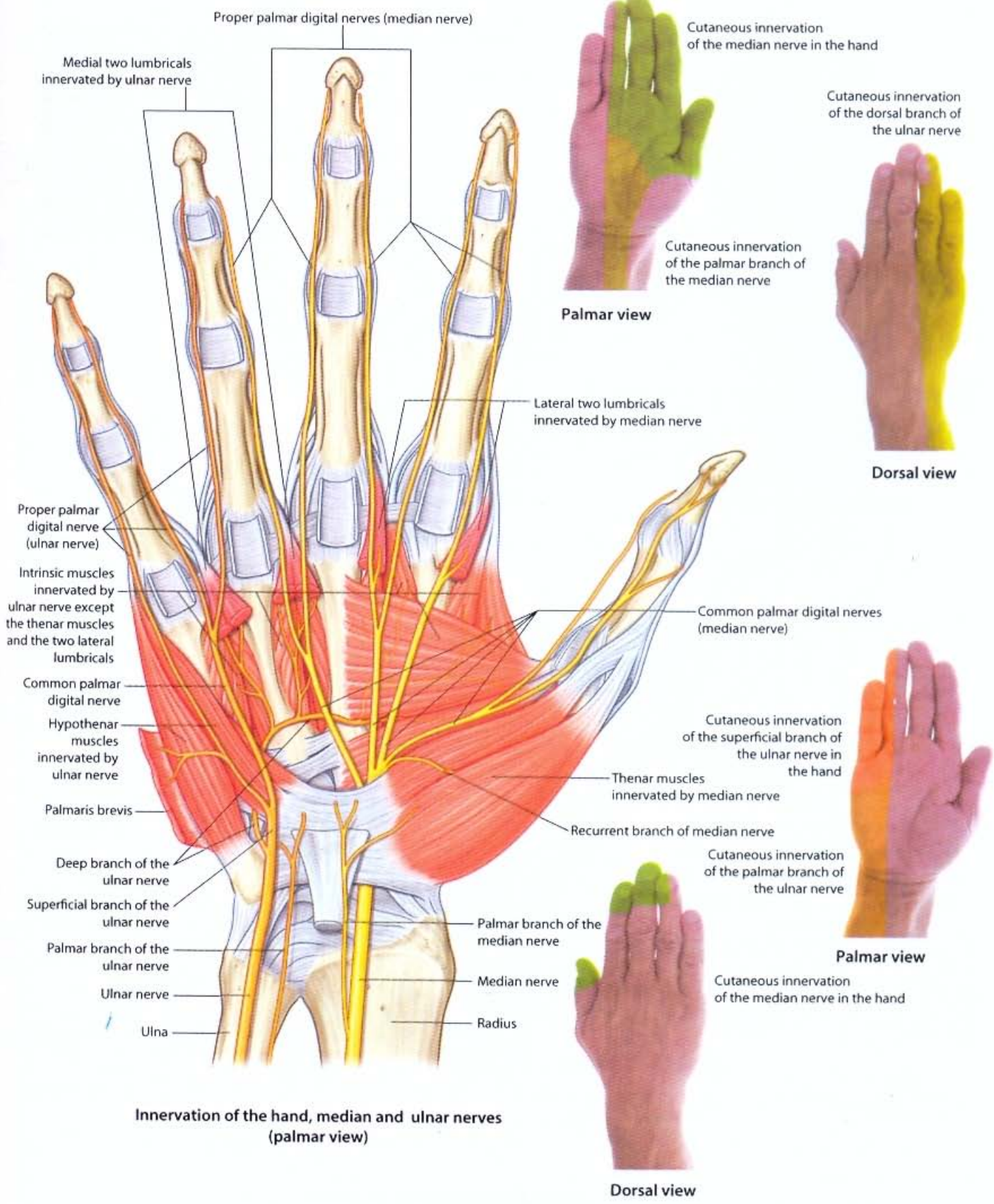




Deep arteries and nerves of the hand (palmar view)

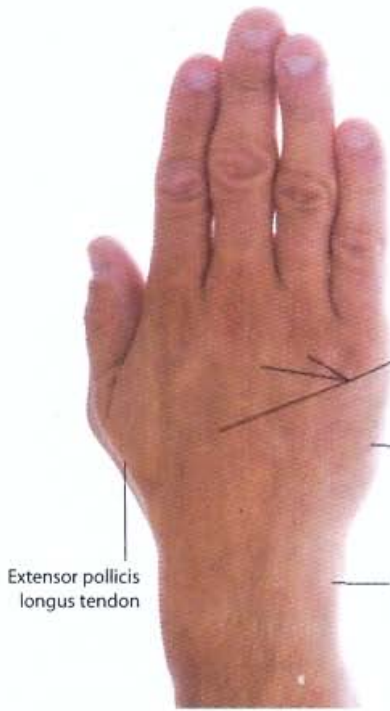
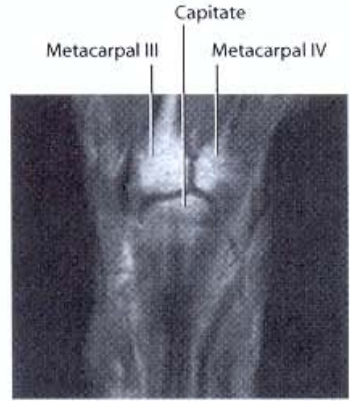


**Arteries of the hand (palmar view)**



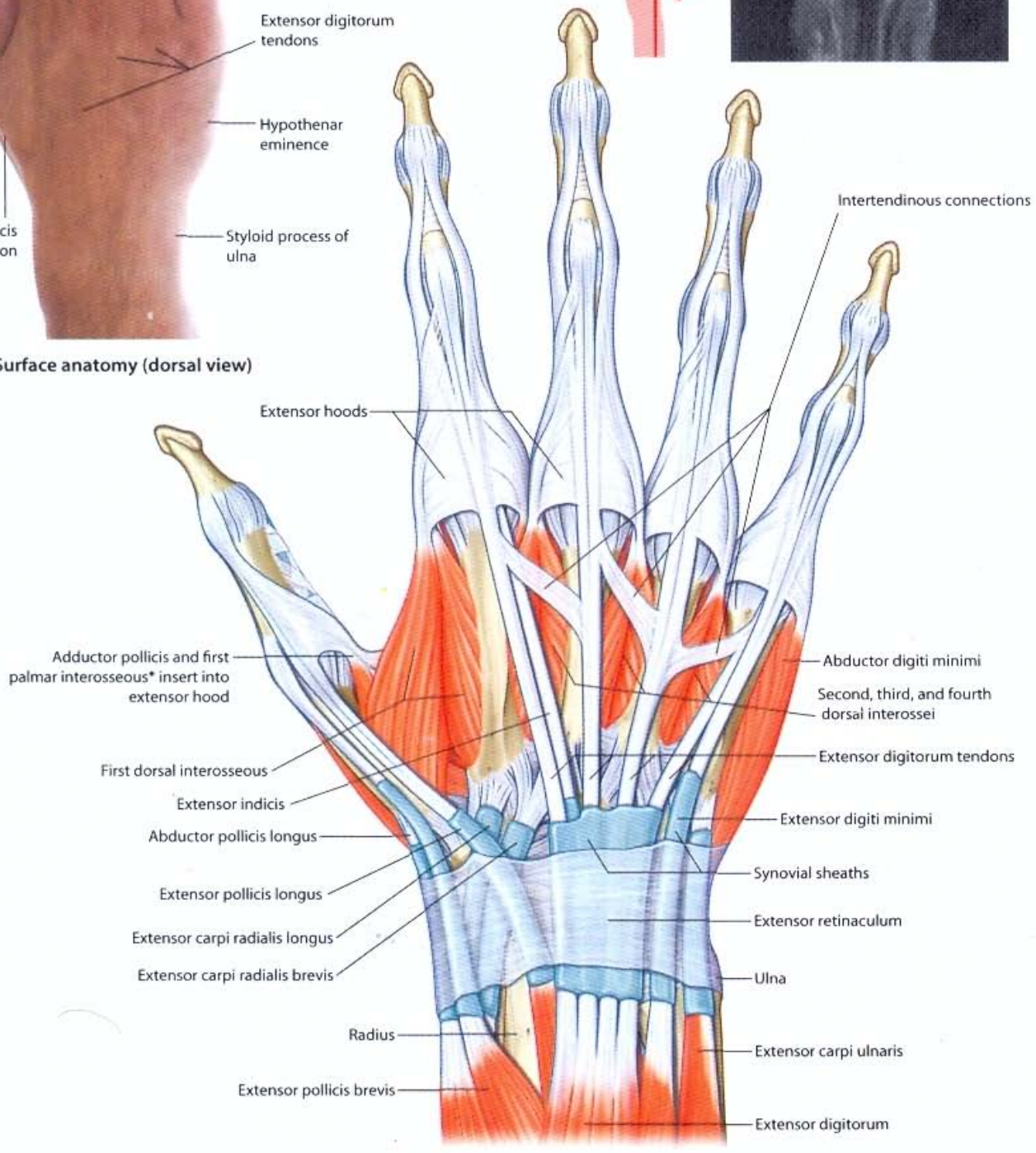
Innervation of the hand, median and ulnar nerves (palmar view)

**Tendons of the extensor muscles of the forearm crossing the wrist joint and passing onto the dorsal surface of the hand.**  
T1-weighted MR image in coronal plane

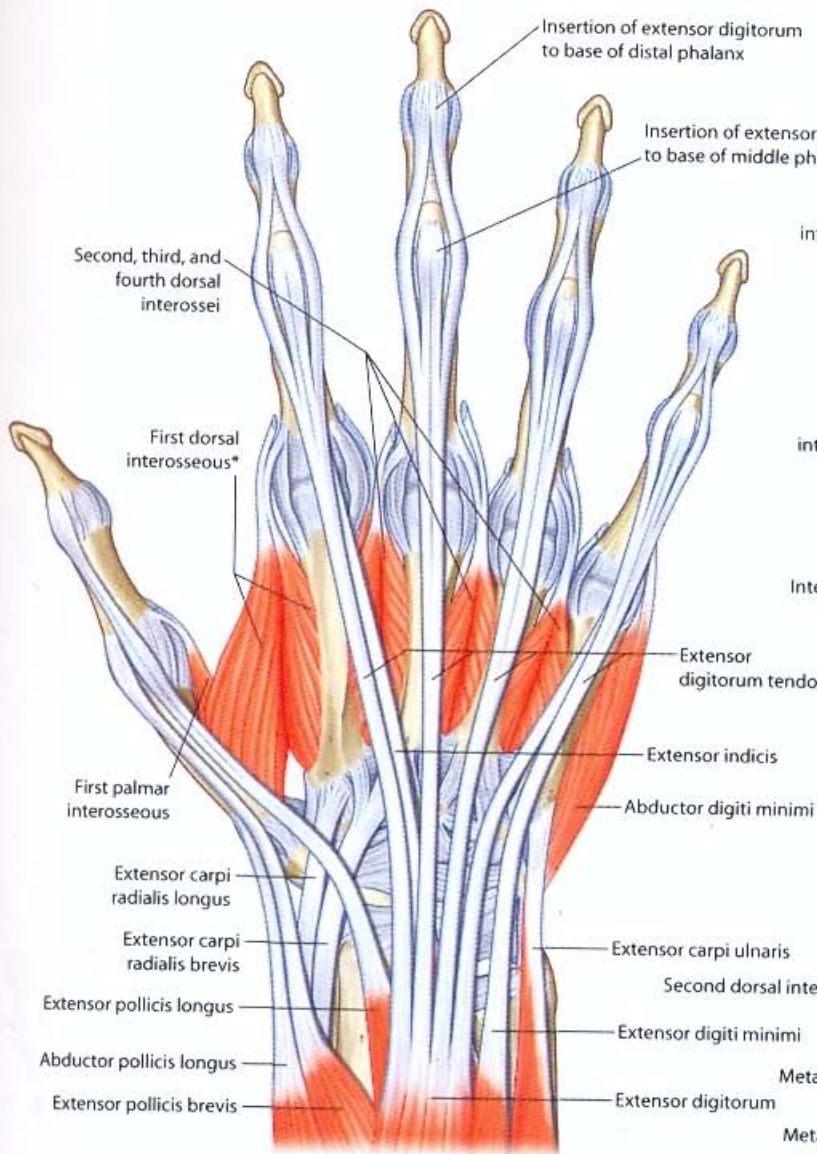


Extensor pollicis longus tendon  
Extensor digitorum tendons  
Hypothenar eminence  
Styloid process of ulna

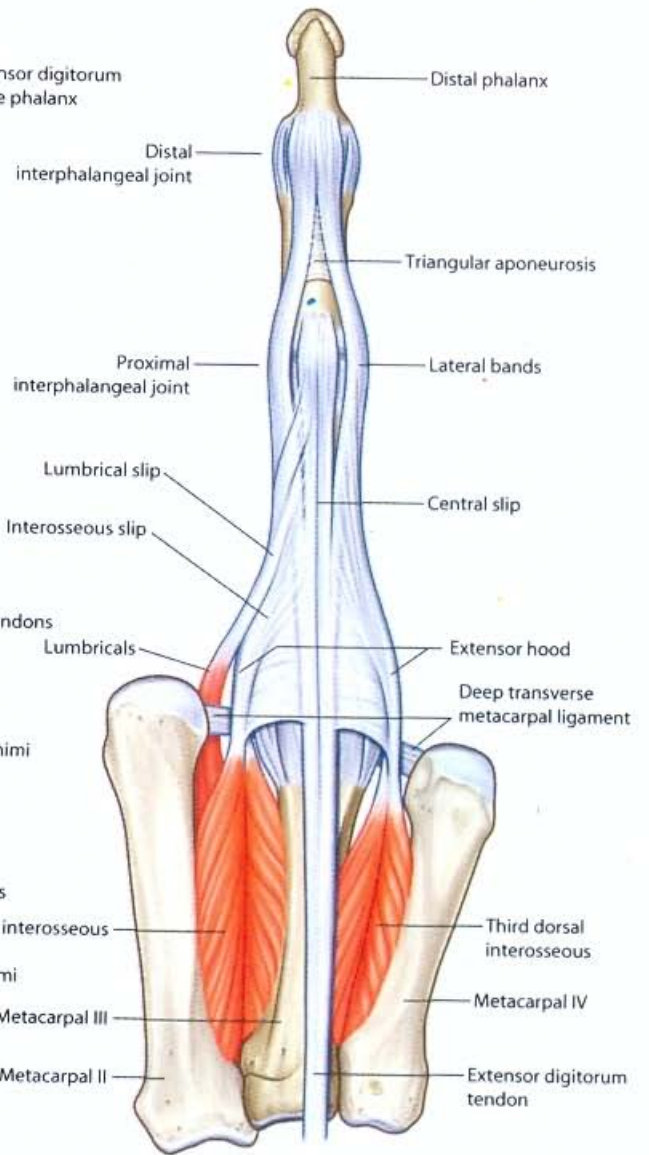
**Surface anatomy (dorsal view)**



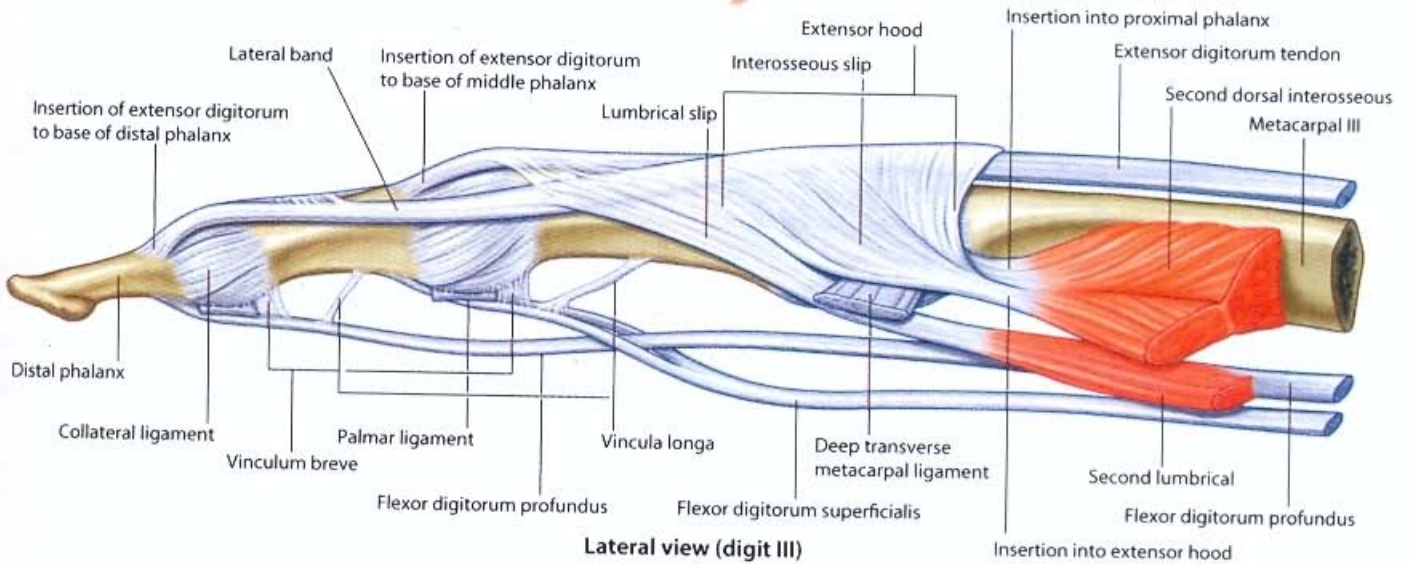
**Superficial structures of the hand (dorsal view)**  
(\* see page 413)



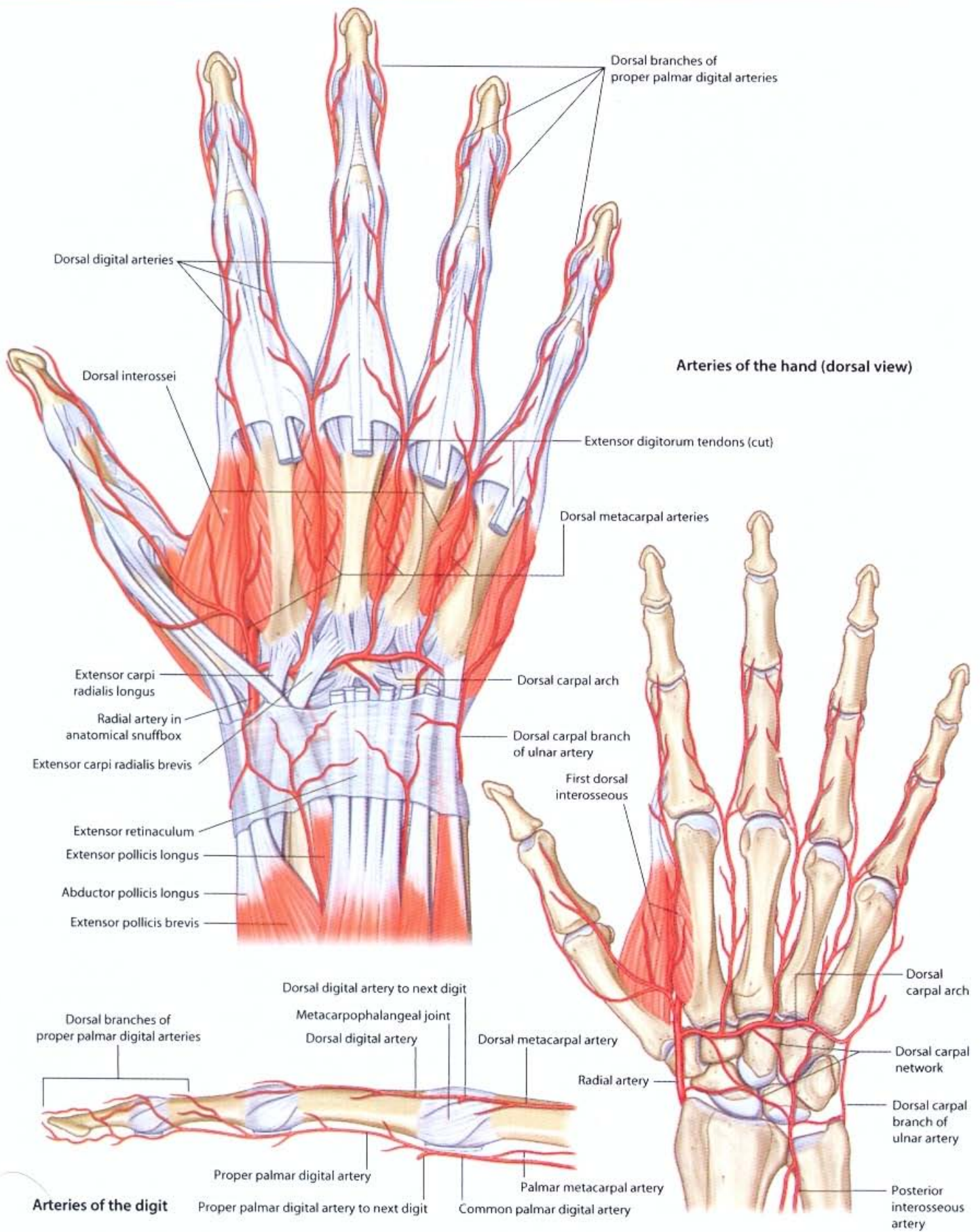
**Extensor tendons (dorsal view)**  
(\* see page 413)



**Dorsal view (digit III)**

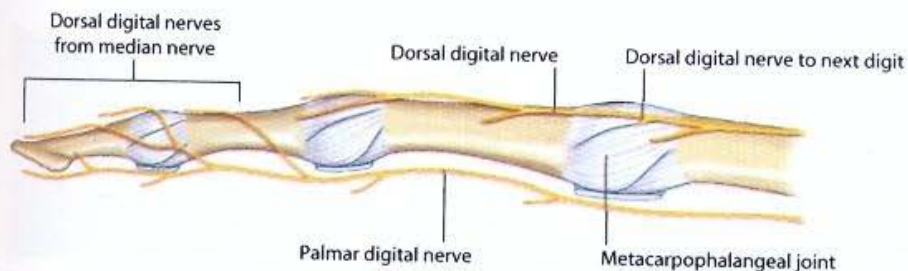


**Lateral view (digit III)**



**Arteries of the hand (dorsal view)**

**Arteries of the digit**

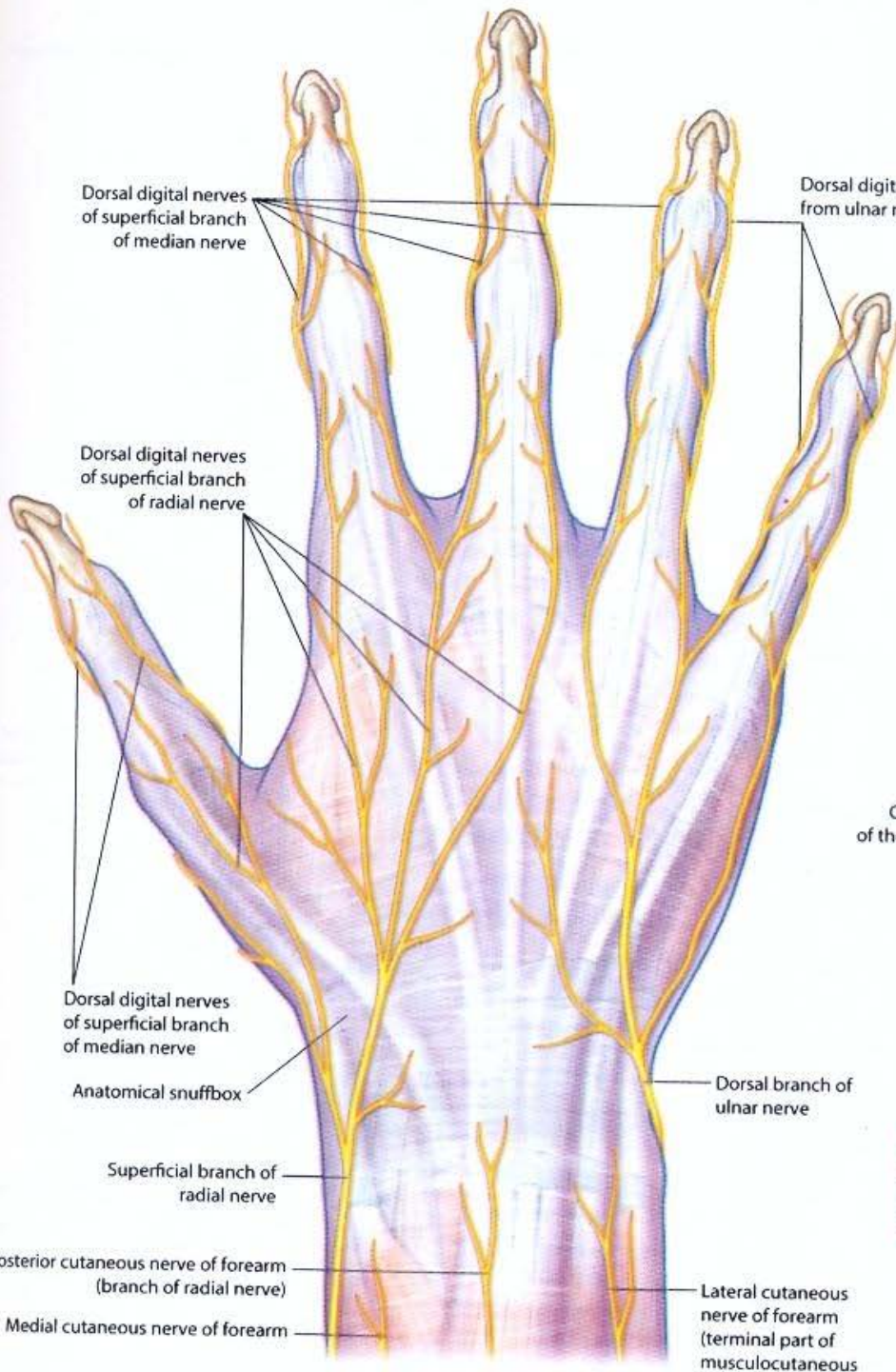


Nerves of the digit

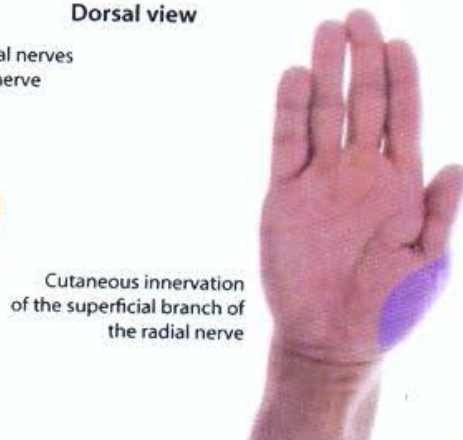


Cutaneous innervation of the superficial branch of the radial nerve

Dorsal view



Nerves of the hand (dorsal view)



Cutaneous innervation of the superficial branch of the radial nerve

Palmar view

Cutaneous innervation of the superficial branch of the median nerve

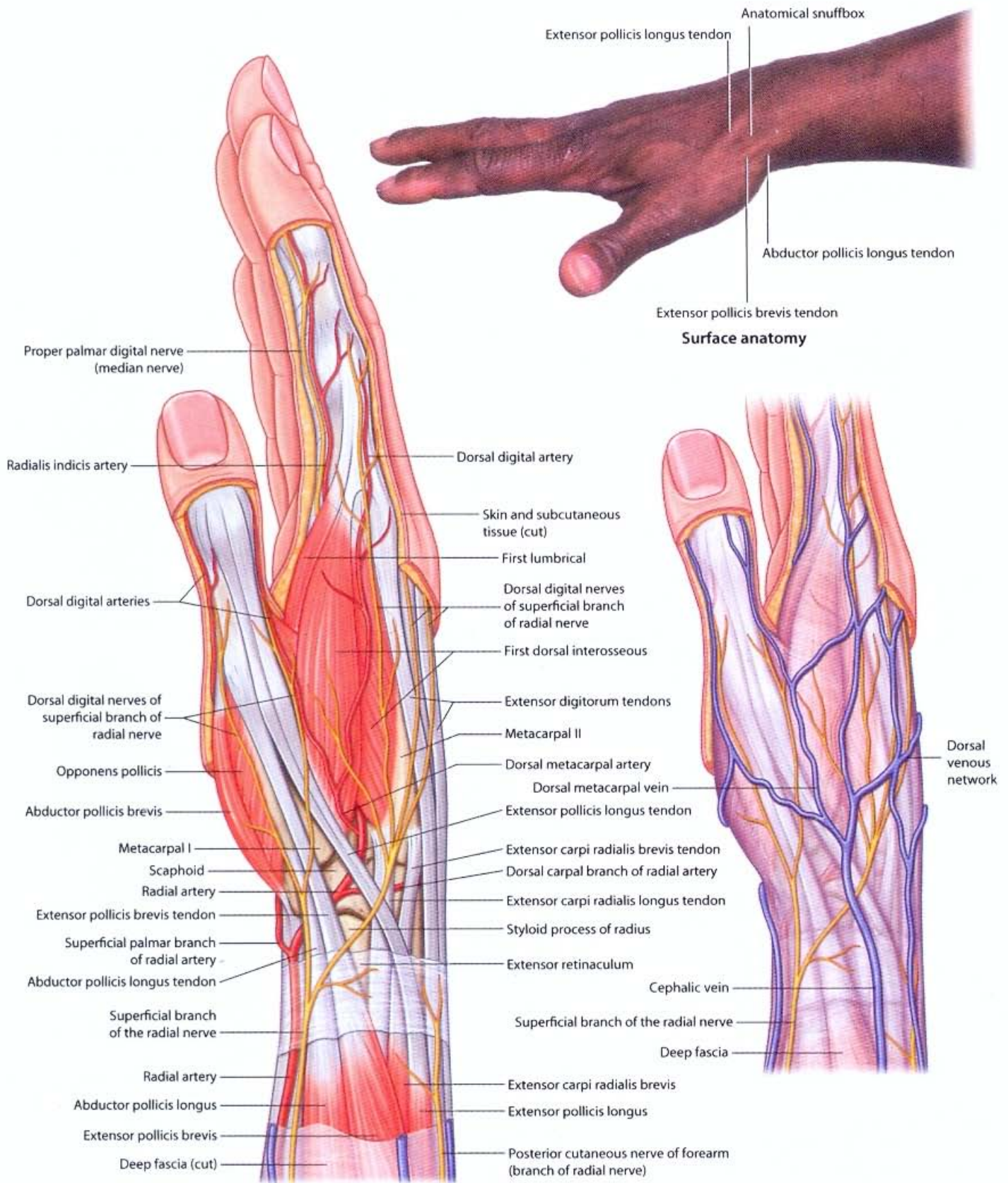


Dorsal view

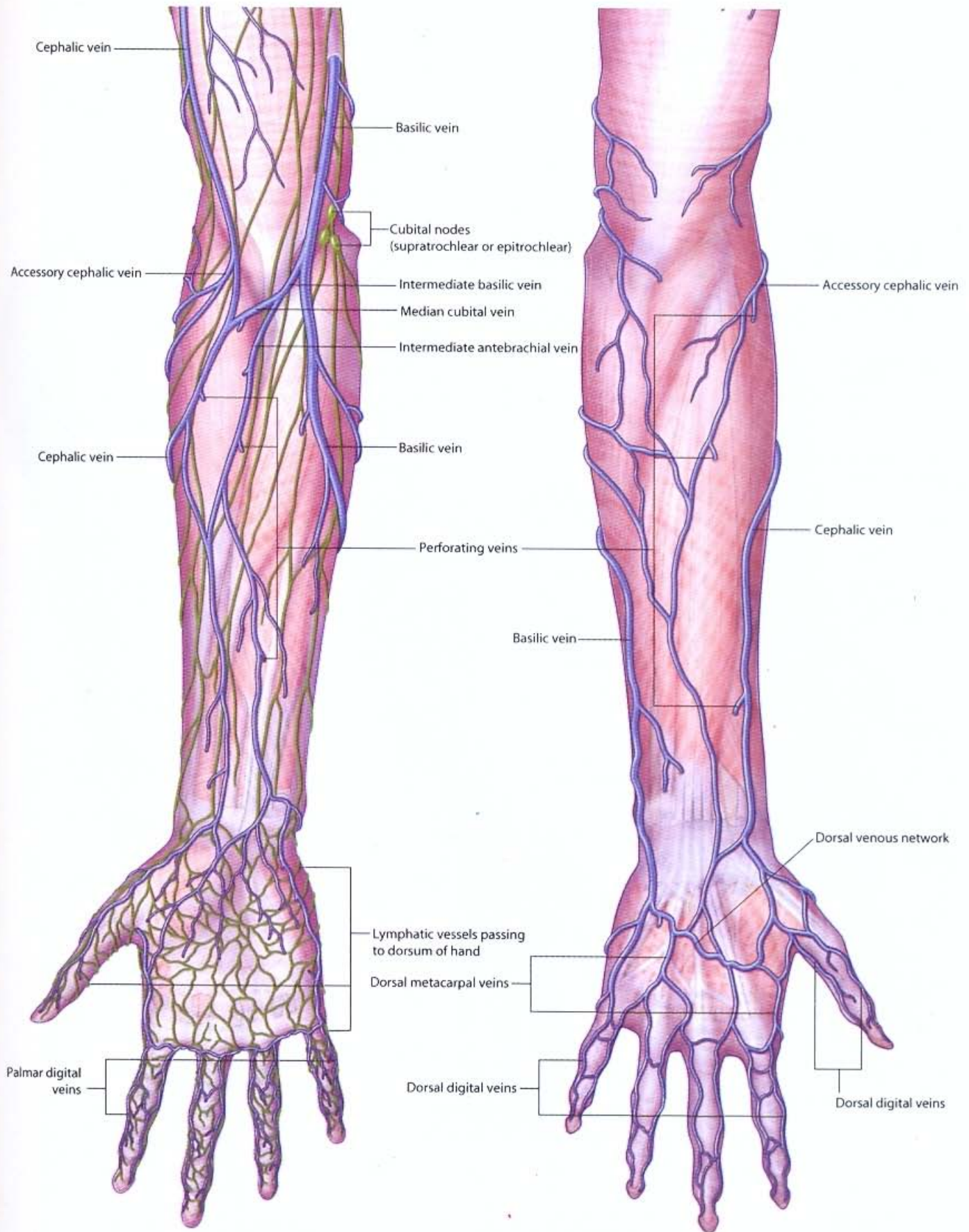


Cutaneous innervation of the dorsal branch of the ulnar nerve

Dorsal view

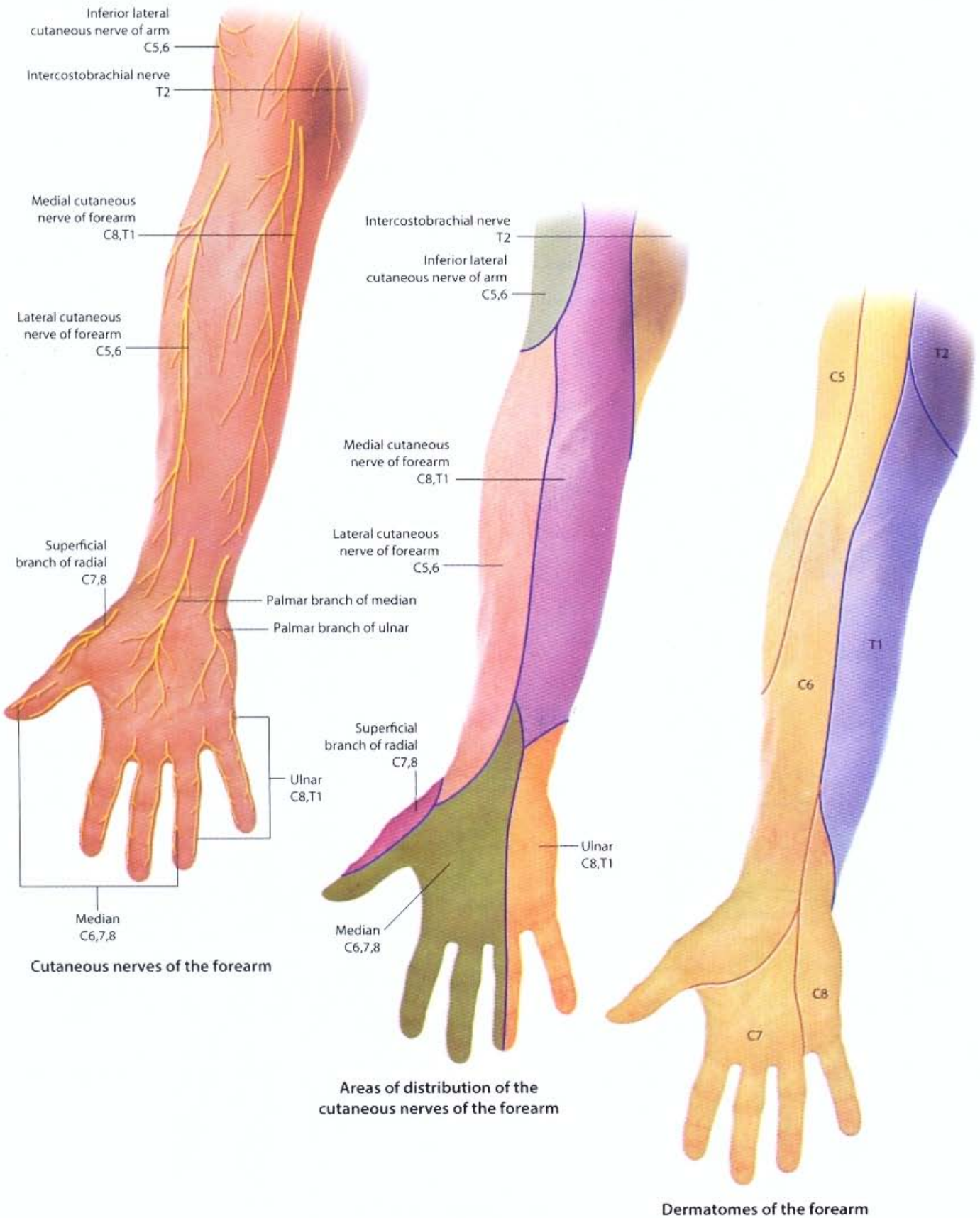


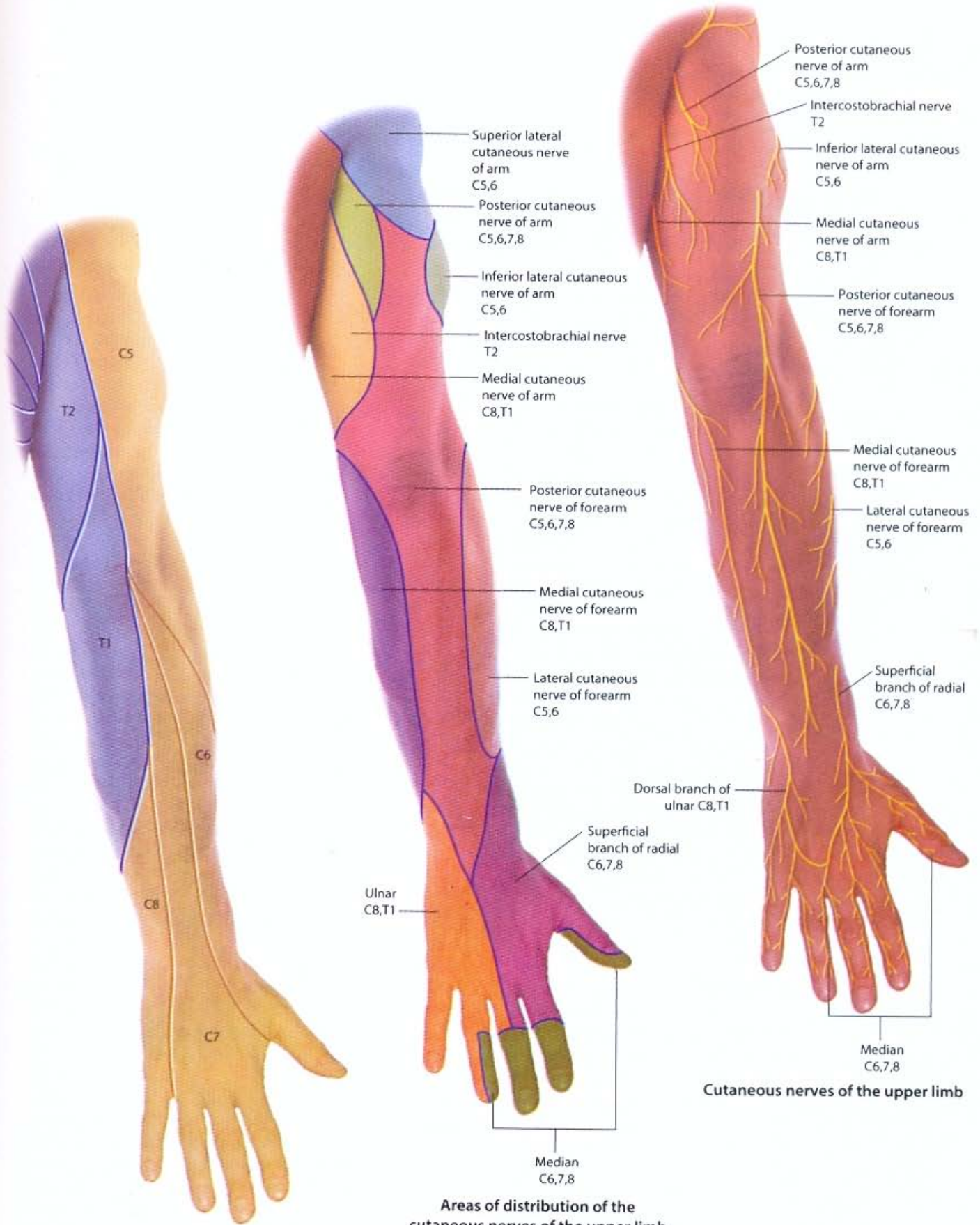




Superficial veins and lymphatics of the forearm (palmar view)

Superficial veins of the forearm (dorsal view)





Dermatomes of the upper limb

Areas of distribution of the cutaneous nerves of the upper limb

Cutaneous nerves of the upper limb